ARCHIVES OF SURGERY

EDITORIAL BOARD

DEAN LEWIS, Chicago
EVARTS A. GRAHAM, St. Louis
THOMAS CULLEN, Baltimore
HUGH CABOT, Ann Arbor, Mich.
WILLIAM DARRACH, New York City
EDWARD STARR JUDD, Rochester, Minn.

VOLUME 4
1922

PUBLISHERS
AMERICAN MEDICAL ASSOCIATION
CHICAGO, ILL.

CONTENTS OF VOLUME 4

JANUARY, 1922. NUMBER 1

Studies in Experimental Traumatic Shock: IV. Evidence of a Toxic Factor in Wound Shock. W. B. Cannon, M.D., Boston.... 1

Further Observations on the Lymphatic Origin of Cholecystitis, Choledochitis and the Associated Pancreatitis. Evarts A. Graham, M.D., and M. G. Peterman, M.D., St. Louis..... 23

Classification and Mechanism of Fractures of the Leg Bones Involving the Ankle, Based on a Study of Three Hundred Cases from the Episcopal Hospital. Astley P. C. Ashhurst, M.D., and Ralph S. Bromer, M.D., Philadelphia..... 51

Studies in Exhaustion: III. Emotion. G. W. Crile, M.D., Cleveland 130

Structural Results of Prostatectomy with Reference to Methods of Enucleation, Based on a Study of One Hundred and Thirty-Six Cases. Frank Hinman, M.D., San Francisco..... 154

Relaxed Pelvic Floor: End-Results in Sixty Cases. Elliott C. Cutler, M.D., and C. Harold Jameson, M.D., Boston..... 175

Sixteenth Report of Progress in Orthopedic Surgery. Robert B. Osgood, M.D.; Robert Soutter, M.D.; Harry C. Low, M.D.; Murray S. Danforth, M.D.; C. Hermann Bucholz, M.D.; Lloyd T. Brown, M.D., and Philip D. Wilson, M.D., Boston..... 200

MARCH, 1922. NUMBER 2

Ventriculocordectomy: A New Operation for the Cure of Goitrous Paralytic Laryngeal Stenosis. Chevalier Jackson, M.D., Philadelphia 257

Papilloma of the Larynx in Children: A Report of Eleven Cases. S. J. Crowe, M.D., and M. L. Breitstein, M.D., Baltimore..... 275

Studies in Experimental Traumatic Shock: V. The Critical Level in a Falling Blood Pressure. W. B. Cannon, M.D., and McKeen Cattell, Ph.D., Boston..... 300

Postoperative Intra-Abdominal Hernia. C. H. Mayo, M.D., and J. A. H. Magoun, Jr., M.D., Rochester, Minn..... 324

The Radical Cure of Tuberculosis of the Seminal Tract: I. Brief Survey of the Literature. H. H. Young, M.D., Baltimore..... 334

Radiohumeral Bursitis, Epicondylitis, Epicondylalgia (Tennis Elbow): A Personal Experience. R. B. Osgood, M.D., Boston... 420

Studies in Traumatic Fractures of the Cranial Bones: I. Edema of the Brain; II. Bruises of the Brain. C. W. Apfelbach, S.B., Chicago 434

MARCH, 1922—Continued

TECHNIC OF THE TREATMENT OF CARCINOMA OF THE BLADDER AND PROSTATE BY A COMBINATION OF SURGERY, ELECTROCOAGULATION, RADIUM IMPLANTATION AND ROENTGEN RAY. B. A. THOMAS, M.D., AND G. E. PFAHLER, M.D., PHILADELPHIA 451

A DETAILED BACTERIOLOGIC STUDY OF GAS GANGRENE FOLLOWING A COMPOUND FRACTURE: STUDIES ON PATHOGENIC ANAEROBES. III. CLINICAL OBSERVATIONS BY E. L. BARNEY, M.D.; BACTERIOLOGIC STUDIES BY H. H. HELLER, PH.D., SAN FRANCISCO 470

MAY, 1922. NUMBER 3

A REVIEW AND CLASSIFICATION OF BONE SARCOMAS. JAMES EWING, M.D., NEW YORK 485

THE GENERALIZED TYPE OF OSTEITIS FIBROSA CYSTICA: VON RECKLINGHAUSEN'S DISEASE. JOHN J. MORTON, M.D., NEW HAVEN, CONN 534

ACUTE HEMATOGENOUS OSTEOMYELITIS. CLARENCE L. STARR, M.D., TORONTO, CANADA 567

OPEN PNEUMOTHORAX IN ITS RELATION TO THE EXTIRPATION OF TUMORS OF THE BONY CHEST WALL. CARL A. HEDBLOM, M.D., ROCHESTER, MINN. 588

FRACTURE-DISLOCATION OF THE SPINE TREATED BY FUSION. RUSSELL A. HIBBS, M.D., NEW YORK 598

CARCINOMA OF THE LUNG: A STUDY OF ITS INCIDENCE, PATHOLOGY AND RELATIVE IMPORTANCE, WITH A REPORT OF THIRTEEN CASES STUDIED AT NECROPSY. MOSES BARRON, M.D., MINNEAPOLIS 624

COMPARATIVE RESULTS OF THE LIGATION OF THE HEPATIC ARTERY IN ANIMALS: ITS APPLICATION TO MAN. MOSES BEHREND, M.D.; H. E. RADASCH, M.D., PHILADELPHIA, AND AMMON G. KERSHNER, M.D., NORRISTOWN, PA. 661

INGUINAL HERNIA: A STUDY OF THE PRINCIPLES INVOLVED IN THE SURGICAL TREATMENT. P. W. HARRISON, M.D., BAHREIN, PERSIA 680

AN UNUSUAL CASE OF INTESTINAL OBSTRUCTION. A. MURAT WILLIS, M.D., RICHMOND, VA. 690

SEVENTEENTH REPORT OF PROGRESS IN ORTHOPEDIC SURGERY. ROBERT B. OSGOOD, M.D.; ROBERT SOUTTER, M.D.; HARRY C. LOW, M.D.; MURRAY S. DANFORTH, M.D.; LLOYD T. BROWN, M.D., AND PHILIP D. WILSON, M.D., BOSTON 693

INDEX 749

ARCHIVES OF SURGERY

VOL. 4 JANUARY, 1922 No. 1

STUDIES IN EXPERIMENTAL TRAUMATIC SHOCK

IV. EVIDENCE OF A TOXIC FACTOR IN WOUND SHOCK *

W. B. CANNON, M.D.

BOSTON

During the last four years, clinical observations and laboratory studies have added materially to our knowledge of wound shock. Summarizing old and new features of this condition it may be said that it is characterized by a low venous pressure,[1] a low or falling arterial pressure, a rapid thready pulse, a diminished blood volume,[2] a normal or increased erythrocyte count and hemoglobin percentage in peripheral blood,[3] a leukocytosis,[4] an increased blood nitrogen,[5] a reduced blood alkali,[6] a lowered metabolism,[7] a subnormal temperature, a cold skin, moist with sweat, a pallid or grayish or slightly cyanotic appearance, by thirst, by rapid respiration, often by vomiting and restlessness, and by anxiety, changing to mental dulness and lessened sensitivity. Many of these features may appear at once or as soon after the reception of the wound as the observations can be made; or they may develop only after the lapse of several hours.

---

* From the Laboratory of Physiology, Harvard Medical School.

* Previous articles in this series are: Aub, J. C.: I. The Basal Metabolism, Am. J. Physiol. **54**:388 (Dec.) 1920. Aub, J. C., and Cunningham, T. D.: II. The Oxygen Content of the Blood, Ibid. **54**:408 (Dec.) 1920. Aub, J. C., and Wu, H.: III. Chemical Changes in the Blood, Ibid. **54**:416 (Dec.) 1920.

1. Wiggers, C. J.: Am. J. Physiol. **46**:326 (June) 1918. Erlanger, J.; Gesell, R., and Gasser, H. S.: Ibid. **49**:106 (June) 1919.
2. Keith: Blood Volume in Wound Shock, English Medical Research Committee, Report Series No. 26, March 14, 1919, p. 36. Gasser, H. S.; Erlanger, J., and Meek, W. J.: Am. J. Physiol. **50**:31 (Oct.) 1919.
3. Cannon, W. B.; Fraser, John, and Hooper, A. N.: Some Alterations in Distribution and Character of Blood in Shock and Hemorrhage, J. A. M. A. **70**:527 (Feb. 23) 1918.
4. Govaerts: Ambulance de l'Océan **2**:359, 1917. Keith: Blood Volume in Wound Shock, p. 8.
5. Duval and Grigaut: Compt. rend. Soc. de biol. **71**:873, 1918. Aub, J. C., and Wu, H.: Am. J. Physiol. **54**:416 (Dec.) 1920.
6. Cannon, W. B.: Acidosis in Cases of Shock, Hemorrhage and Gas Infection, J. A. M. A. **70**:531 (Feb. 23) 1918.
7. Aub, J. C.: Am. J. Physiol. **54**:388 (Dec.) 1920.

INITIATING FACTORS IN SHOCK

The onset of early or *primary* shock is most reasonably accounted for as a consequence of some disturbance of the nervous system. A review of the evidence at hand shows that it is impossible to eliminate as a consequence of wounds a reflex relaxation of blood vessels similar to that which occurs in fainting. Indeed, as Cowell [8] has observed, fainting is, in fact, not infrequently observed after the reception of wounds. Vincent [9] likewise has seen cases of this character; but in the only instance which he describes in detail (that of a man wounded in the abdomen, who, a few minutes after being hit, manifested the syndrome of shock), the blood pressure, at the end of forty-five minutes, had risen from 60 to 90 millimeters of mercury. It is possible, then, that there may be produced by a wound an effect similar in character to fainting or syncope, but persisting for a longer period than the usual fainting spell.

British, French and American observers had occasion during the war to note that shock may begin to appear two or three hours after the wounding. It may be associated with continued bleeding, but commonly cannot be explained by hemorrhage or infection. Exposure to cold, lack of water, rough transportation, and the agitation of broken bones have been recognized as circumstances favorable to its development. These factors may later have their action increased by infection, especially by the bacilli of gas gangrene. This is *secondary* wound shock and was by far the most common form noted during the war. An analysis of the theories which have been most commonly advocated in the past, such as inhibition,[10] reduction of the carbon dioxid content of the blood (acapnia [11]), fat embolism,[12] exhaustion of nerve centers and of certain glands,[13] shows that they do not offer an adequate explanation for the onset of delayed or secondary shock. Their chief and common defect is that they fail to account for the occurrence, both in clinical and in experimental shock, of a diminution of blood volume and either a local or a general concentration of blood corpuscles. A group of theories which do take these facts into consideration, namely, those which postulate a primary vasoconstriction with a consequent capillary congestion,[14] fail in that they do not suggest

8. Cowell, E. M.: The Initiation of Wound Shock, J. A. M. A. **70**:608 (March 2) 1918.

9. Vincent: Compt. rend. Soc. de biol. **81**:887, 1918.

10. Meltzer, S. J.: The Nature of Shock, Arch. Int. Med. **1**:578 (July 15) 1908.

11. Henderson: Am. J. Physiol. **21**:128, 1908.

12. Porter: Harvey Lectures, Philadelphia, 1917-1919, p. 21.

13. Crile, G. W., and Lower, W. E.: Surgical Shock and the Shockless Operation Through Anoci-Association, Philadelphia, W. B. Saunders Company, 1920.

14. Malcolm: Tr. Med. Soc., London **32**:274, 1909. Starling, E. H.: Arch. méd. belges **71**:369 (Oct.) 1918. Erlanger, J.; Gessell, R., et al.: Am. J. Physiol. **49**:90, 151, 345, 1919; Ibid. **50**:31, 104, 119, 1919.

how a vasoconstriction would occur, capable of bringing about a reduction of blood volume. What is required is a demonstration of some factor, naturally related to the production of shock, which may so operate in the body that, when hemorrhage and infection are ruled out, the persistent low blood pressure characteristic of shock will become gradually established.

CHARACTER OF INJURIES ASSOCIATED WITH WOUND SHOCK

A primary consideration in experimental study of natural phenomena is that the phenomena reproduced under controllable conditions shall resemble as closely as possible those occurring in nature. This is a consideration which seems to have been largely neglected in experimental investigations of shock. No doubt, persistent low blood pressure can be produced by a variety of means. In support of various theories of shock, investigators have been able to duplicate certain aspects of the condition by protracted stimulation of nerves, by severe and long-continued manipulation of exposed intestines, by vigorous over-ventilation of the lungs, by repeated pushes against the stomach, by interrupting the circulation in large areas of the body, or by injecting into the blood stream relatively large amounts of oil or cream. Although such procedures cause changes similar to those which occur in natural shock, they do not reproduce the circumstances which occasion shock after ordinary wounds or injuries. Obviously, it is desirable to duplicate, so far as possible, the actual conditions which give rise to a shocklike state, and then to analyze them in order to determine what factor, or factors, among them is operative.

The typical nature of the wounds seen in cases of secondary shock may be judged from the following records made by a group working at Béthune.[15] In reading these records, it should be understood that the wounds are often made by large ragged pieces of shell moving at high velocity. When such a missile breaks the femur or the ilium, for example, it smashes and tears extensively the overlying muscles, which, in the thigh and hip, form a thick layer. In all these cases, shock was present:

CASE 1.—E. G., compound fracture of left ulna and radius, arm nearly severed, wounds of right arm and left side, abdomen opened, intestine and omentum protruding.

CASE 2.—C. P. H., shell wounds of right thigh with fracture of the femur, and shell wounds of left arm with fracture of the humerus, wounds of the face.

CASE 3.—G. D., wounds of the left arm with fracture, left leg with fracture, flesh wounds of the right thigh and abdomen.

CASE 4.—G. J. H. H., shell wounds of right ankle, of left leg with fracture, and of the muscles of the buttock.

---

15. Cannon, W. B.: Acidosis in Cases of Shock, English Medical Research Committee, Report Series No. 25, Dec. 25, 1917, pp. 86-88.

CASE 5.—H. J. H., bursting shell broke right femur, left tibia and fibula, and injured right arm.

CASE 6.—A. J. R., extensive wounds of both legs, left foot and left arm.

CASE 7.—W. G., wounds of buttock with fracture of ilium, also wounds of right foot.

CASE 8.—P. K., fracture of left femur (much comminuted) and right tibia.

CASE 9.—W. A. T., wounds of buttock and perineum, muscles below the buttock torn across and smashed in both legs.

CASE 10.—G. K., wounds of both arms, left thigh, left foot, compound fracture of the right thigh.

CASE 11.—R. C., compound fracture of right femur, multiple shell wounds, left femur, buttock and chest.

CASE 12.—A. H., multiple shell wounds; large wound of the left loin involving the gluteal muscles, fracture of the pelvis, extensive wound of right calf muscles and the muscles of the left thigh and left calf, and numerous wounds in back and chest.

The general character of war wounds is well described by Wallace and Fraser:[16]

The tissues of the wound are crushed and lacerated, and there are widespread contusion and effusion of blood into the surrounding parts. The neighboring blood vessels are often pulped and thrombosed, and as a result of the interference with the blood supply whole areas of tissue may afterward die and slough away. In these wounds, muscle appears to be affected more than any other tissue; it becomes a mass of dark brown crushed matter without any evidence of striation or vitality. One cannot fail to be impressed by the enormous destruction which even a small fragment of shell will produce, a degree of destruction which is apparently quite out of keeping with the size of the fragment; the exaggerated damage depends on the enormous velocity at which the fragments are traveling.

EXPERIMENTAL EVIDENCE OF A TOXIC ORIGIN OF SECONDARY WOUND SHOCK

After spending the summer of 1917 at a casualty clearing station in Béthune, I went to London and worked for three months with Bayliss in an experimental study of shock. At first, we were interested in the question as to whether the acid known to be developed in injured tissue might not be a contributory factor in the production of shock as seen in man. The traumatization which we caused induced both a reduction of blood alkali (an acidosis) and a low blood pressure (Fig. 1). Later it was shown that the acid production was not an essential factor in the complex.[17] Some other agent, therefore, must be acting. Further analysis of the mode of operation of the trauma will be deferred until the observed facts are described. These facts were estab-

16. Wallace and Fraser: Surgery at a Casualty Clearing Station, London, 1918, p. 31.

17. Acidosis and Shock, English Medical Research Committee, Report Series No. 25, October, 1919, p. 250.

lished in part by Bayliss and myself working together,[18] and in part by each of us working independently, after I was transferred to the Laboratory of Surgical Research of the American Expeditionary Forces at Dijon, France.

In order to bring about, in lower animals, a traumatization similar to that giving rise to shock in man, the thigh muscles in the anesthetized cat, while being supported by an iron block, were repeatedly struck with a blunt wedge-shaped hammer, or they were crushed by compression. The trauma usually failed to break the skin, so that infection from without was impossible. Occasionally, the femur was broken, but this had no influence on the results which were seen. After this procedure, the course of events was followed in observations on the pulse, respiration and the alkali reserve and the corpuscular volume of the blood. In Figure 1 is presented a summary of the changes seen in a typical case. An actual record of the blood pressure changes of shock produced in this way is shown in Figure 2.

As Figure 2 proves, the crushing of the muscles in one hind leg of the cat may have no immediate effect. There may be a momentary rise or fall of arterial pressure. After about twenty minutes, however (and still longer in the dog), the pressure begins to fall. And after about an hour, the pressure has usually fallen to 80 millimeters of mercury, or even lower, i. e., to a shock level. There it may persist for several hours. In other words, the general bodily condition resembling shock is produced by duplicating the circumstances which induce shock in man. The only noteworthy difference is the presence of anesthesia (urethane). That this is not a determining factor is shown by the use of a controllable anesthetic, such as ether, which may be lightened as the animal falls into deeper and deeper insensibility. The lessening of the ether concentration under these circumstances does not improve the circulation.

The fall of pressure after traumatization might be regarded as due to loss of blood and lymph into the damaged tissues, for there is always considerable swelling of the injured region. This suggestion was tested, however, by removing *postmortem,* with symmetrical cuts, the two hind legs, one normal, the other injured, and weighing them. The difference of weight which, in some instances, was only 10 per cent.

---

18. For early reports of these observations, see: Cannon, W. B.: Med. Bull. Med. Research Soc., Am. Red Cross, Paris, April, 1918, p. 426; Compt. rend. Soc. de biol. **81**:850, 1918. Bayliss, W. M.: Intravenous Injection in Wound Shock, New York, Longmans, Green & Co., 1918. Cannon, W. B., and Bayliss, W. M.: Note on Muscle Injury in Relation to Shock, Report of a Special Committee on Surgical Shock, English Medical Research Committee, March 14, 1919, p. 19. Bayliss, W. M.: Further Observations on the Results of Muscle Injury and Their Treatment, Ibid., p. 23. Cannon, W. B.: Some Characteristics of Shock Induced by Tissue Injury, Ibid., p. 27; Mil. Surgeon **44**:494 (May) 1919.

of the estimated blood volume, would not represent enough extravasated blood to account for the fall of pressure. It must be admitted, of course, that loss of blood by extravasation, even when slight, may play a rôle in the subsequent development of the low pressure.

The widespread effect in the organism induced by the trauma might be due to nervous impulses. Such impulses on passing to the central

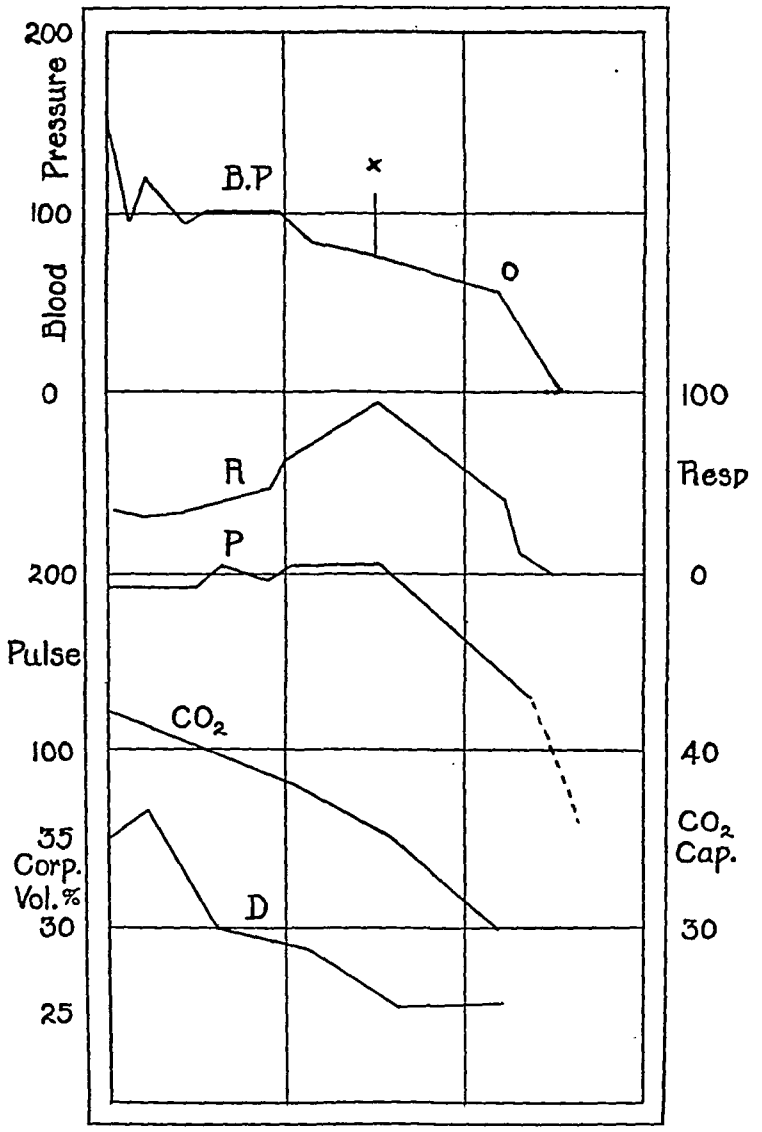

Fig. 1.—Record of changes in the blood pressure, respiration, pulse and carbon dioxid capacity (alkali reserve) of the plasma after injury of the flexor muscles in the thigh; urethane anesthesia. At *X*, asphyxia caused the rise of blood pressure indicated; at *O*, no rise in asphyxia.

nervous system might so affect it as to produce reflex inhibition of the vasoconstrictor center, as has been suggested above for the initiation of primary wound shock. Is such the case? The nature of the experiment permits securing evidence on this point. It is only necessary to

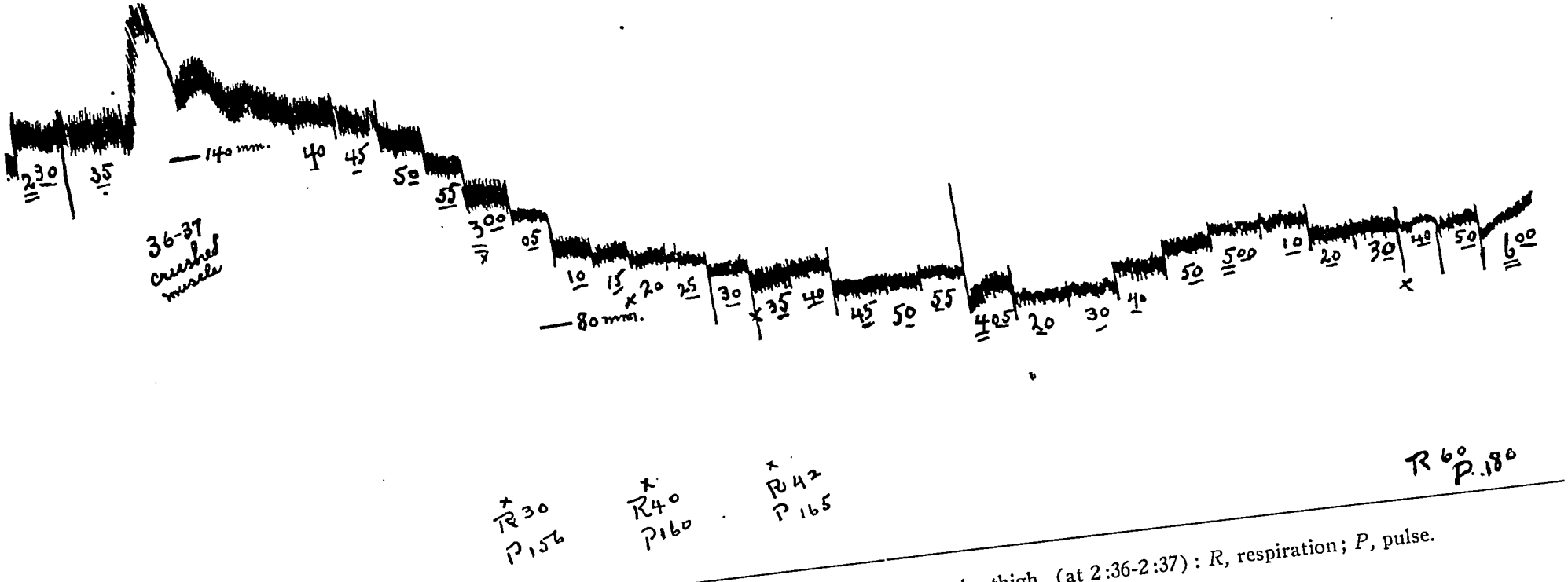

Fig. 2.—Typical fall of arterial blood pressure after crushing muscles of the thigh (at 2:36-2:37): *R*, respiration; *P*, pulse.



Fig. 3.—Fall of blood pressure after muscle injury (10:02-10:03), though the nerves to the injured limb had been cut; rise of blood pressure to the original level after closing (at 11:41) the blood vessels to and from the injured region: *R*, respiration; *P*, pulse.

transect the spinal cord above the lumbar plexus or to sever all nerves of the limb which is to be injured, in order to disconnect the region from the central nervous system. When this has been done and the denervated muscles are traumatized, events occur similar to those seen after trauma when the nerves are intact (Fig. 3). From this evidence it is clear that there is no essential relation between the production of shock and an excessive stimulation of the central nervous system.

The gradual fall of blood pressure, again, might be interpreted as due to depression or exhaustion of the central nervous system, with gradual loss of vasoconstrictor tone. That this is not true was shown by tests performed by Cattell in the Harvard laboratory. He used the method described by Bartlett, in which the rate of inflow of a fluid at constant pressure through the femoral artery of one hind limb was determined

SUMMARY OF RESULTS SHOWING PERFUSION TIME FOR 1 C.C. OF PHYSIOLOGIC SODIUM CHLORID SOLUTION IN RELATION TO BLOOD PRESSURE IN MUSCLE INJURY SHOCK

Experiment	Control Perfusion Time, Seconds	Maximal Perfusion Time, Seconds	Period After Injury, Hours	Percentage Increase	Perfusion Time at End, Seconds	Perfusion Time After Death, Seconds	Original Blood Pressure, Mm.	Blood Pressure at Maximal Constriction, Mm.
8	5.2	12.9	0.75	144	4.7	...	140	90
9	2.3	3.3	1.0	43	2.9	1.8	130	16
10	1.4	2.4	4.0	71	...	1.2	140	74
12	1.2	2.7	4.5	125	1.1	0.8	130	68
14	0.8	1.5	1.5	87	1.0	0.5	130	60
15	1.3	3.7	1.25	185	...	1.3	120	72
16	1.6	4.0	3.5	150	...	...	135	78
18	2.7	4.0	4.5	48	...	...	125	65
19	1.5	2.5	6.0	66	...	1.1	135	42
20	1.4	2.5	...	78	...	...	130	92
21	1.0	1.7	3.0	70	0.9	0.6	130	60
Average	1.85	3.74	3.0	102	2.1	1.0	131	65

at intervals during the development of shock produced by injury of the other hind limb. The inflow cannula was always placed in a side branch of the femoral artery, so that when injections were not being made, a clip on the main trunk could be removed to permit the leg to receive its natural blood supply. In Cattell's tests, about 3 c.c. of physiologic sodium chlorid solution was allowed to run into the artery while the time was being recorded with a stop watch. In a few instances in which perfusion was interfered with by small clots forming in the vessels, the experiments were discarded. The condition of the vessels was checked by inflow determinations after death, when, if there is no obstruction, the rate will be greatly increased. In the accompanying table is a summary of the results. The figures represent the time in seconds for the entrance of 1 c.c. of fluid, and in each case they are the average for at least three determinations. Invariably, there was a gradual increase in the time (i e., decrease in the rate) of inflow after muscle injury, usually starting within the first hour and reaching a

maximum in from two to four hours. At this time of maximum constriction, the blood pressure had already fallen to a shock level, the average pressure for the series of experiments being 65 millimeters of mercury. After this, a dilation occurred which continued until death and was accompanied by a further fall of blood pressure. As already stated, the perfusion rate was still further increased after death. A curve showing the general relation between the blood pressure and peripheral response is given in Figure 4, which illustrates the averages of six experiments which were carried on over a period of four hours or more. From these results, it is apparent that the low pressure initiated by muscle injury is not primarily due to a loss of vasomotor tone or to a dilation of the blood vessels. In other words, this form of shock is not the consequence of any form of exhaustion. This conclusion is similar to that reached by Erlanger, Gesell and Gasser for shock produced by manipulation of the intestines and by occlusion of the aorta.

It might be supposed, further, that the local injury, especially when the femur is broken, would permit a sufficient amount of fat to be liberated to cause the pressure to fall. In several instances, careful examination of the lungs was made by expert pathologists, Louis B. Wilson and Henry W. Cattell; but in no instance was there evidence of any accumulation of fat. Furthermore, there was no twitching or disturbance of respiration or other sign which might indicate that fat had passed through the pulmonary capillaries into the central nervous system. The fall of pressure, therefore, cannot be attributed to fat embolism.

Although there was usually a change of respiration in the direction of greater rapidity and lessened amplitude, this was not characteristic of the period immediately after the trauma, but developed as the blood pressure fell. Commonly, the respiration became slower toward the end (Fig. 1). The absence of hyperpnea for some time after the injury, although the carbon dioxid capacity of the plasma was falling, and the later rapid and shallow breathing, which, since it was superficial, was not such as to induce a washing out of carbon dioxid from the blood, rule out acapnia as a cause of the lowered blood pressure. This conclusion was confirmed by producing shock by muscle injury, though the breathing was kept uniform by artificial means.

If the low blood pressure resulting from local trauma is not due to loss of blood into the injured region, or to reflex vasodilation, or to depression or exhaustion of the vasoconstrictor center, or to fat emboli, or to acapnia, the connection between the local damage and the general bodily state may reasonably be looked for in the remaining great connecting system—the circulation. There may be given off from the damaged tissue into the flowing blood or lymph material, which, when

carried to the rest of the body, proves toxic and disturbs the control of the walls of the vessels in such a way as to lower arterial pressure. This idea can readily be tested. The blood vessels of the leg (the iliac artery and vein) are tied and the muscles are then crushed. In the experiment recorded in Figure 5, the blood vessels of the leg were tied before the muscles were smashed, and the ligatures were left in place for thirty-three minutes after the trauma. The record shows that there was no drop of blood pressure during this period, although the arterial pressure usually begins to fall in the cat about twenty minutes after the injury. As soon as the blood flow was restored, however, the pressure promptly fell to a low level. This phenomenon can be explained

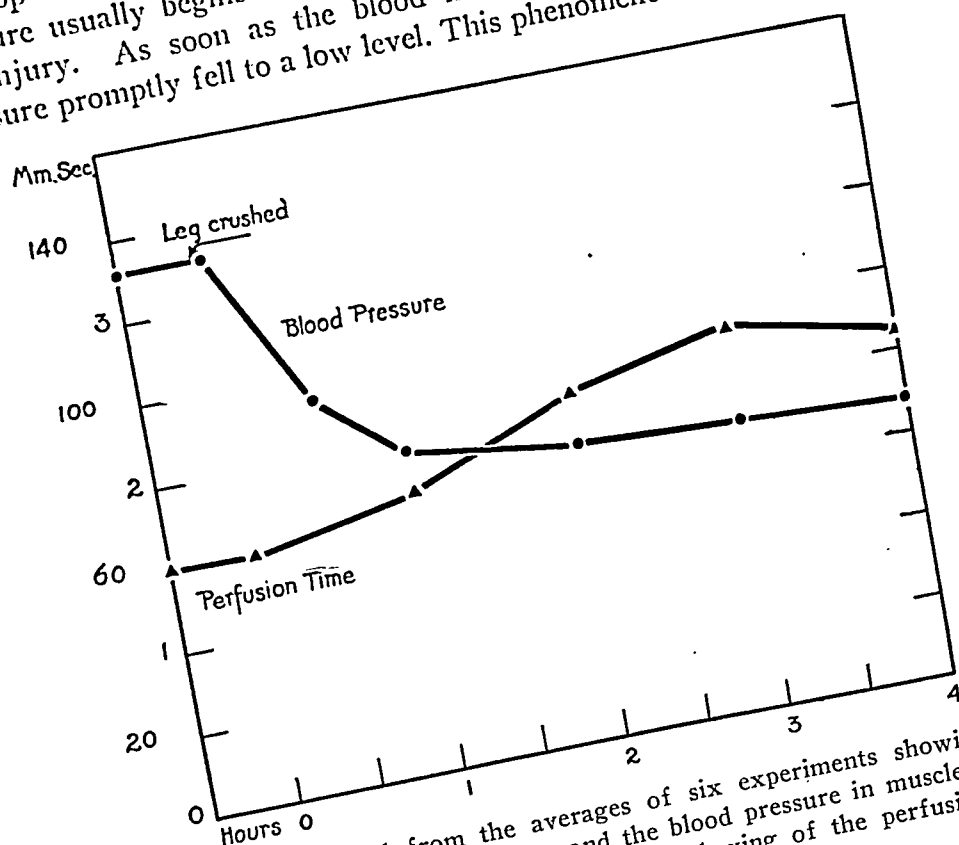

Fig. 4.—Curve plotted from the averages of six experiments showing the relationship between the perfusion rate and the blood pressure in muscle injury shock. As the blood pressure falls, there is a slowing of the perfusion rate indicating an increased tone of the arterioles.

on the supposition that when the blood is again allowed to flow a pressure-lowering substance passes, by way of the circulation, from the traumatized region to the rest of the body. The inference just set forth received support from experiments in which the muscle was injured; and, while the pressure in consequence was falling, the vessels of the leg (the iliac artery and vein) were closed. As shown in Figure 3, occlusion of the vessels may be followed by a progressive rise of pressure to the normal level. If the injury is not great, the blood pressure, after falling for a while, may spontaneously be restored. The

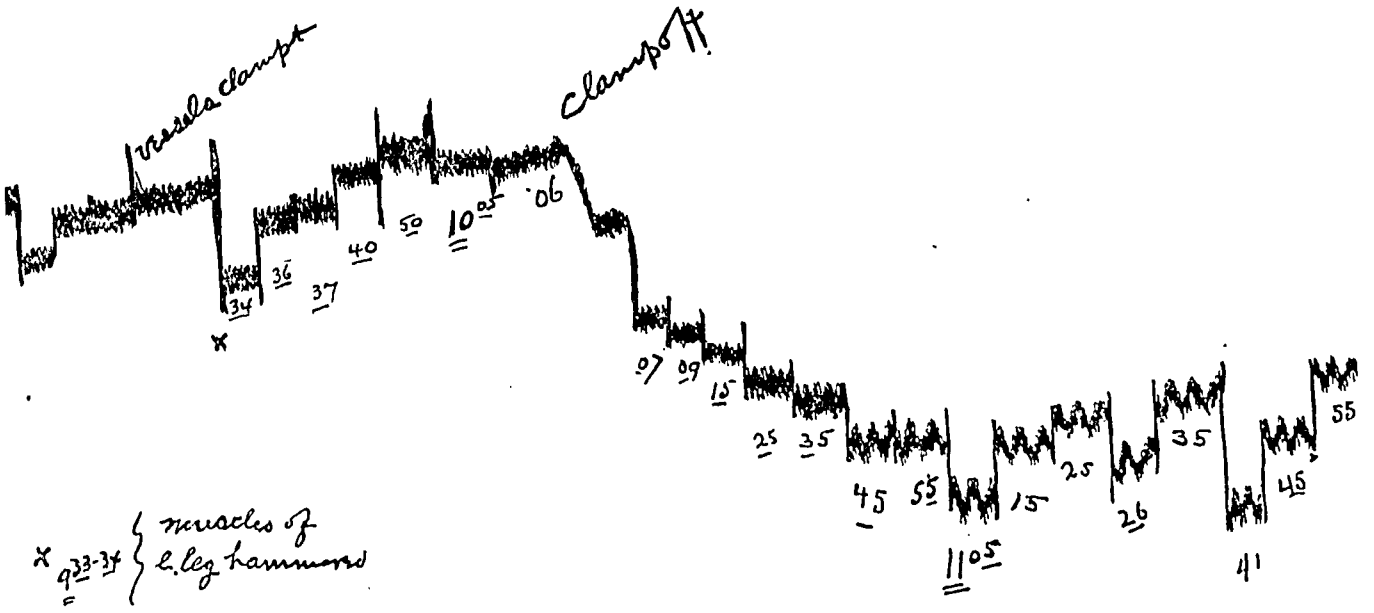

Fig. 5.—Failure of blood pressure to fall at the usual time after muscle injury (at 9:33-9:34) if the blood vessels to the injured region have been tied; on restoration of the blood flow (at 10:06), the pressure promptly falls.

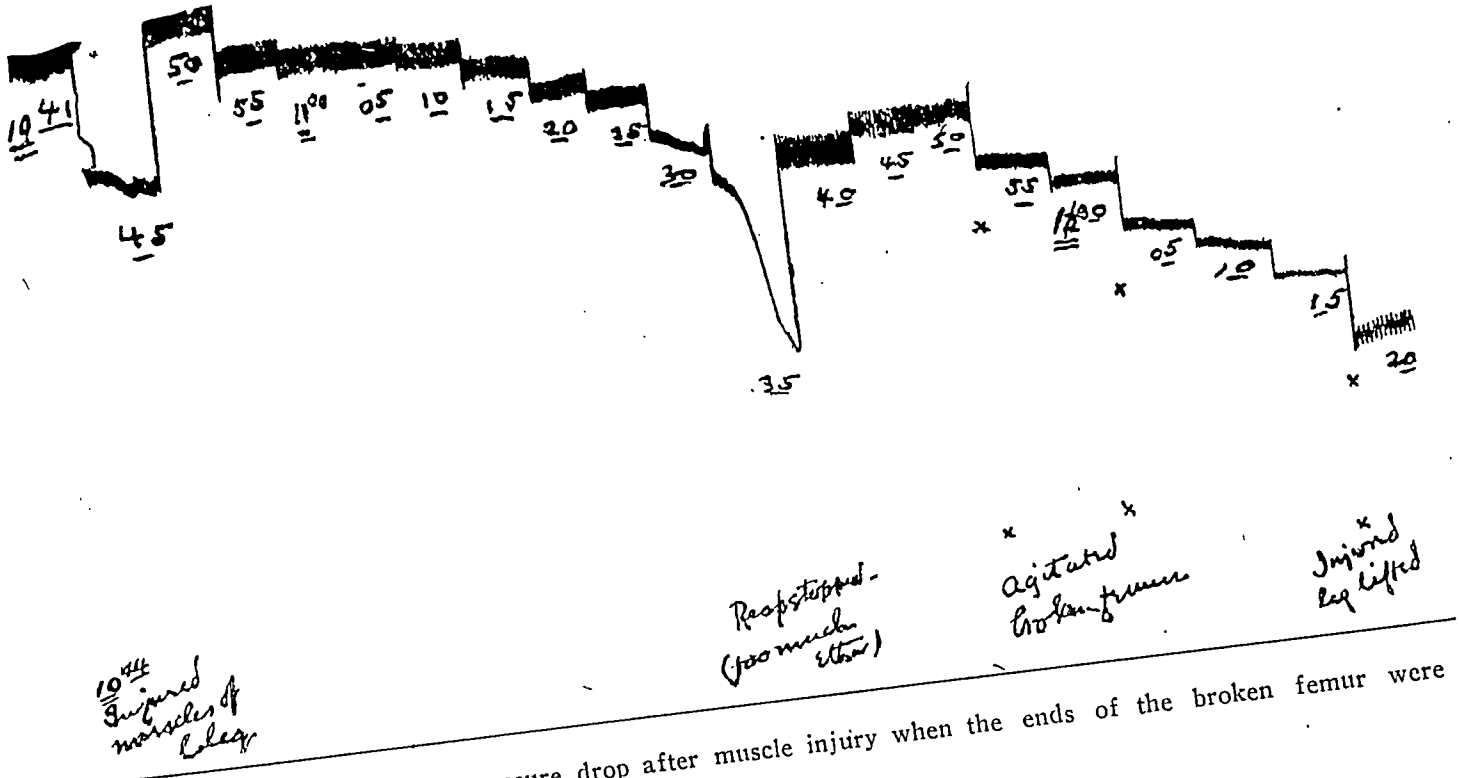

Fig. 6.—Increased rate of pressure drop after muscle injury when the ends of the broken femur were moved in the damaged tissues at x and x.

evidence indicates, therefore, that whatever may be the substance originating in the damaged tissues, it is fairly promptly changed in the body or eliminated, so that its effect is not permanent.

Further confirmation of the inference that a pressure-lowering material is given off from injured tissue was obtained by massage of the traumatized region. The result was a further drop in pressure. In Figure 6 is presented the record of blood pressure as it was falling after a smashing of the thigh muscles with fracture of the femur. At the points marked *x*, the fragments of the bone were moved in the damaged soft parts. The records taken shortly thereafter showed a greater drop than usual. The practical bearing of these observations on the importance of immobilizing bony fragments is obvious.

Other experimental work has led to the same conclusion that Bayliss and I reached in our experiments. In a recent publication, Turck[19] has declared that the consequences of cell necrosis brought about in various ways affect the whole organism in such a manner as to give rise to some of the symptoms of shock. In June, 1918, he reported experiments[20] on injury to the thigh muscles, that were similar to those performed by Bayliss and myself in January, and referred to in March and April of that year.[21] Unfortunately, his experiments were not accompanied by blood pressure records; and commonly, the injection of what he called "shock-toxins" was followed by rapid death of the animal rather than by the production of shock. In November, 1917, Delbet,[22] impressed by the similarity between traumatic shock and the shocklike conditions accompanying peritonitis, raised the question whether intoxication did not play a rôle in certain forms of traumatic shock, whether shock was not, in fact, the result of absorption of toxins arising from disorganized and bruised tissues. Delbet and Karajonopoulos,[23] in July, 1918, reported the effects of injecting into guinea-pigs and rats the products of autolysis of crushed muscles. They found that these substances were highly toxic, sometimes making animals comatose a few seconds after intraperitoneal injection. Respiration was accelerated; the reaction to noise disappeared; the animal became immobile, and in a variable time died—effects attributed by Delbet to disturbances of the nervous system. These experiments revealed a toxic material in muscle autolysates; but it did not produce detailed analogies to the state of shock in human beings. Delbet's view that toxic substances arise from autolytic disintegration of

19. Turck: Med. Rec. **95**:472 (March 22) 1919.
20. Turck: Med. Rec. **93**:927 (June 1) 1918.
21. Bayliss, W. M.: J. Physiol. **52**:17, 1918. Cannon, W. B.: Med. Bull., Med. Research Soc., Am. Red Cross, Paris, April, 1918, p. 426.
22. Delbet: Bull. et mém. Soc. de chir. **43**:2121, 1917.
23. Delbet, P., and Karajonopoulos: Bull. Acad. de méd. **80**:14 (July 2) 1918.

muscles was questioned by Vallée and Bazy,[24] who noted that autolytic ferments of muscles are slow in action. They expressed doubt whether autolysis would result in a toxin sufficiently abundant or active to induce shock, and suggested that bacteria and possibly leukocytes might induce proteolytic changes capable of hastening the production of poisonous material.[25] It seems unnecessary to assume that tissue disintegration should be carried far in order to evoke, when injected, a fall of blood pressure. As long ago as 1903, Vincent and Sheen [26] proved that watery extracts of a variety of tissues, when injected into the blood stream would cause a drop of arterial tension, and Perret,[27] in 1909, proved that fluid pressed from raw meat ("myoserum") was highly toxic when injected intravenously.

AN EXPLANATION OF TRAUMATIC TOXEMIA

Explanation of the shock-producing effect of substances which may arise from injured tissue has its beginnings in classic experiments in the history of physiology. Nearly thirty years ago Heidenhain [28] demonstrated that the injection of "peptone" into the circulation would cause an increased production of lymph, persistent low blood pressure and a notable concentration of the blood. These are changes which Starling,[29] in 1894, attributed to increased capillary permeability, especially in the liver.

In 1919, Dale and Laidlaw [30] called attention to a reduction of blood pressure which can be induced by the injection of extremely minute amounts (1 or 2 mg. per kilogram in the anesthetized animal) of histamin, a substance derived from the amino-acid histidin by removal of carbon dioxid. Later, attention was called to the shocklike character of the changes which histamin occasions.[31] The arteries are constricted (the early constriction of arteries in shock may be due, in part, to the action of toxic substances), there is oligemia, a reversed ratio of corpuscles to plasma, and failure of the cardiac output.[32] If the chest is opened, the heart is seen beating regularly; but its chambers contain little blood.[33] The arteries and veins likewise contain little blood.

24. Vallée and Bazy: Bull. et mém. Soc. de chir. **44**:707, 1918.
25. Vallée and Bazy: Bull. et mém. Soc. de chir. **44**:708, 1918.
26. Vincent and Sheen: J. Physiol. **29**:254, 1903.
27. Perret: Trav. du lab. de Richet **6**:91, 1909.
28. Heidenhain: Arch. d. f. ges. Physiol. **49**:252-254, 1891.
29. Starling: J. Physiol. **17**:39, 1894.
30. Dale and Laidlaw: J. Physiol. **61**:318, 1910.
31. Dale and Laidlaw: Memorandum Upon Surgical Shock and Some Allied Conditions, English Medical Research Committee, February, 1917.
32. Dale, Laidlaw and Richards: Traumatic Toxemia, English Medical Research Committee, Report Series No. 26, March, 1919, p. 9.
33. Dale, Laidlaw and Richards: Traumatic Toxemia, p. 10.

Moreover, by the use of vital red, Dale [34] demonstrated that a considerable part of the blood passes out of currency. It appears, therefore, that since the blood is not in arteries and veins, it must be concentrated in capillary areas. Dale reports that the bowel shows a diffuse dusky congestion and that the smallest venules are rendered visible on its surface by their content of dark blood—a condition similar to that observed by Erlanger and his collaborators [14] in the various forms of shock which they produced. By direct microscopic examination after the injection of histamin, Hooker [35] and also Rich [36] have shown that a large number of capillaries, previously not seen, become clearly defined because dilated and filled with blood. Dale and Richards [37] have further analyzed the action of histamin. The low pressure resulting from it is not due to relaxation of the arterioles. It is apparently due to a series of changes in which dilation of the capillaries and pooling of blood within them, poisoning of their endothelial walls so that they are abnormally permeable, escape of plasma through these walls into the tissue spaces, and consequent concentration of the corpuscles [38] are the main features. This thickening of the blood would accentuate the tendency for it to gather in the small vessels.

The great significance of these observations by Dale, Laidlaw and Richards is that the action of histamin may reasonably be regarded as typifying the action of a large class of poisonous protein derivatives—products of partial digestion, of bacterial action, and of tissue extraction. In 1909, Popielski [39] called attention to the depressor action of organ extracts and showed that "vasodilatins" could be extracted from practically all tissues. In 1911, Barger and Dale [40] proved that histamin was present in the mucosa of the small intestine, in Popielski's "vasodilatins," and also in commercial peptone. Recently, Able and Kubota [41] have adduced evidence that histamin is a widely distributed constituent of animal tissues, organ extracts and enzymatic products, whether derived from animal or vegetable proteins. In all probability, histamin is not the only constituent of tissue extracts and tissue digests capable of lowering blood pressure. Hanke and Koessler,[42] for example, have shown that typical peptone shock can be produced by injecting peptone from which histamin is absent. We may follow Dale, therefore, in

34. Dale, Laidlaw and Richards: Traumatic Toxemia, p. 11.
35. Hooker, D. R.: Am. J. Physiol. **54**:49 (Nov.) 1920.
36. Rich: J. Exper. Med. **33**:287 (Feb.) 1921.
37. Dale and Richards: J. Physiol. **52**:144, 1918-1919.
38. Dale, Laidlaw and Richards: Traumatic Toxemia, p. 12.
39. Popielski: Arch. f. d. ges. Physiol. **128**:191, 1909.
40. Barger and Dale: J. Physiol. **41**:499, 1911.
41. Abel, J. J., and Kubota, S.: J. Pharm. & Exper. Therap. **12**:297 (June) 1919.
42. Hanke, M. T., and Koessler, K. K.: J. Biol. Chem. **43**:567 (Sept.) 1920.

regarding histamin as a type of the toxic substances derived from protein material. Although proof is still lacking that a substance, like histamin in character, is actually given off into the blood stream when the tissues are severely damaged, the effects of local tissue injury (influencing the rest of the body solely through the circulation) and the effects induced by histamin are so similar that the supposition has a high degree of probability. In both conditions, there is a fall of blood pressure. In both, there is a reduction of blood volume. In both, there is, at least in the early stages, a concentration of the blood (Fig. 1). In both, slight hemorrhage results in markedly increasing the shocklike effect. It is a matter of considerable interest that proteolytic bacteria, such as those producing gas gangrene, induce, in muscles, chemical changes, which, according to Zunz,[43] are accompanied by the production of histamin. Extracts of such muscles are highly toxic and rapidly depress the circulation.[44] The association of "shock" with gas infection can thus be accounted for.

The view that secondary shock is due to action of toxins arising in injured tissue places it, as Dale [45] has pointed out, in the same general category with anaphylactic shock, for that likewise is probably the consequence of poisoning by protein cleavage products. The shocklike condition produced by toxic substances arising from intestinal obstruction which Whipple and his collaborators [46] have done so much to elucidate, becomes also closely related to traumatic shock, for chemical study led them to the conclusion that the poisonous agent developed in a closed intestinal loop belongs to the primary proteoses. It is conceivable, furthermore, that the results of methods used by other investigators to produce shock, such as pinching the intestine, as employed by Githins, Kleiner, Meyer and Meltzer,[47] or interfering with the circulation, as practiced by Janeway and Ewing [48] and by Erlanger and his group,[49] may be accounted for on the basis of a toxin production. Bayliss and I [18] found that after the blood flow had been wholly shut out from the hind limbs for an hour, restoration of the circulation resulted in a sharp fall of blood pressure. And Dale [32] proved that if the blood vessels of the fore limb are rendered sensitive to the action of histamin by denervation, letting the blood flow through the hind

43. Zunz: Compt. rend. Soc. de biol. **82**:1079, 1919.

44. Report of the Shock Committee, English Medical Research Committee, Report Series No. 25, October, 1918, p. 265.

45. Dale: Proc. Roy. Soc., B **91**:133, 1920:

46. Whipple et al.: J. Exper. M. **17**:286, 307, 1913; Ibid. **19**:144, 166, 1914; Ibid. **23**:123, 1916.

47. Githins, Kleiner, Meyer and Meltzer: Proc. Soc. Exper. Biol. & Med. **16**:3, 1918.

48. Janeway and Ewing: Ann. Surg. **59**:158, 1914.

49. Erlanger, J., and Gasser, H. S.: Ann. Surg. **19**:389 (April) 1919.

limbs after it had been shut out for some minutes is followed not only by dilation of the vessels of the hind limbs, but also, as in histamin injection, by dilation of the vessels of the sensitized fore limb as well. Since changes in the direction of death and cell disintegration are induced when the circulation is cut off from a region—changes which are accelerated by trauma— the suggestion seems reasonable that the methods mentioned above, used by other investigators to cause shock, likewise involved toxin production.

It should not be supposed that smashed muscle is the sole source of toxic material. Pinching the intestine, as stated above, will induce shock; and I have found that crushing the tips of two or three lobes of the liver may be effective also. Possibly, substances given off by extravasated blood are likewise depressive to the circulation; at least, the injection of blood just previous to its coagulation causes a sharp drop of blood pressure.

CLINICAL EVIDENCE FOR TRAUMATIC TOXEMIA

Aside from the experimental evidence which has resulted in the building up of a theory of traumatic toxemia as a cause of shock, there are also clinical observations which extended over approximately the same period as the experimental studies, and which, quite independently, led to the same conclusion. For the clinical studies which developed and gave support to the theory of toxemia as a cause of secondary wound shock, great credit should be awarded to Quénu, professor of clinical surgery in the Medical Faculty of the University of Paris. As early as 1916, having repeatedly noted in his military service the relation between the occurrence of shock and the attendant gross damage of tissue, he began to suggest to various surgeons in the French army the desirability of securing clinical data regarding the possible presence of a toxic factor in the production of traumatic shock. In December, 1917, the observations of Rouhier, one of his former interns, were reported by Quénu; and during 1918, a series of papers were presented to the Société de chirurgie in Paris by Quénu and others—Moulinier, Santy, Marquis, La Croix, Bertein and Nimier, Rouhier and Soubeyran—which brought striking confirmation of the ideas which had been expressed. Since an excellent summary of these papers has been made by Quénu,[50] it will be unnecessary to report them here in detail. For present purposes, a brief outline of the clinical evidence that secondary shock is a traumatic toxemia will suffice.

1. Secondary shock, or what the French call "shock primitif," does not appear immediately after the receipt of wounds, as a large number of observers have testified; and therefore it is not of the nature of a

50. Quénu: Rev. de chir. **56**:204, 1918.

nervous effect. Furthermore, the state is commonly well established before infection; and therefore it is not of bacterial origin.

2. Secondary shock is characteristically observed in association with extensive damage of muscles or with multiple wounds [51] scattered over the body. This contention of Quénu is supported by the studies at Béthune and by the observations of McNee, Sladden and McCartney,[52] who described cases in which, without injury to bones or to any vital structure or organ, there was extensive laceration of muscle, accompanied by such severe shock that most of the patients died in spite of treatment. In the case of multiple wounds the large number of small areas of damage would obviously be in sum the equivalent of destruction of a considerable mass in one region. The increase of undetermined nitrogen in the urine and of total nonprotein nitrogen, as well as residual nitrogen, in the blood of shock patients [5] may be accounted for as a consequence of the absorption of material from the traumatized area, and also, perhaps, as the effect of tissue damage done by circulating toxins.

3. Everything that favors absorption at the region of injury is favorable to the development of shock. Thus, in the observations reported by Quénu,[51] the development of shock is most severe when the region of damage communicates with the exterior by only a small orifice. The negative aspect of this evidence is presented by cases in which a large fleshy mass, along with the skin which covers it, is carried away by a missile; in such instances, shock is slight or wholly absent.[53]

4. Anything that delays or checks absorption from the injured region delays the development of shock; but if there is a sudden romoval of the check, serious results follow. In support of this point, Quénu [54] cites an incident observed by Rouhier:

A man with a crushed foot was brought in with a tourniquet placed very tightly below the knee. The leg was tense, dark-colored and full of blood; but there was no sign of shock. Rouhier performed a conservative operation and then removed the tourniquet. Three hours after the operation, the patient was in a state of intense shock.

Gregoire [55] has reported the analogous case of a lieutenant caught in a dug-out after a shell burst. His left thigh was compressed between two logs. Thus, he remained for twenty-four hours, alert, guiding the efforts of those

51. Quénu: Rev. de chir. **56**:270, 1918.

52. McNee, Sladden and McCartney: Observations on Wound Shock, Especially with Regard to Damage of Muscle, English Medical Research Committee. Report Series No. 26, March, 1919, p. 35.

53. Quénu: Rev. de chir. **56**:271, 1918.

54. Quénu: Rev. de chir. **56**:272, 1918.

55. Gregoire, cited by Quénu: Rev. de chir. **56**:272, 1918.

who were delivering him. His general condition was good; but he was pale, with a pulse small and rapid and a slightly accelerated respiration. There was no wound; the foot, leg and knee, however, were purplish and cold; above the knee there were two deep hollows formed by the pressure of the logs. Some hours after his rescue, the officer became restless; and, although treatment for shock was undertaken, he died thirty-two hours after the pressure was removed from the leg. There was no indication of nervous depression and no bleeding in this case. The shock appeared on permitting the circulation to return to the damaged tissue.

Five cases similar to these were reported to me from various surgeons in the hospitals of the American Expeditionary Forces in France. One instance was especially striking: A tourniquet had been in place on the upper arm for an uncertain period; but the wound in the wrist was so slight that the surgeon proceeded to clean it and take off the compression. The patient was in good condition before the tourniquet was removed. A short time thereafter, however, he went into profound shock and died. It is obvious that the state developed in these human cases was quite like that developed experimentally by Janeway and Ewing, by Erlanger and his collaborators, and by Bayliss and myself, when a continued low blood pressure was induced by interference for several hours with the circulation to a considerable part of the body.

The converse of the foregoing observations is seen when after a very severe wound the region is isolated by a tourniquet and the limb is amputated proximal to, and without removing, the tourniquet. Rouhier [56] reports a case of this type in which no shock appeared either before or after the operation.

5. Suppression of the injured region, if not too long delayed, causes shock to disappear. Much evidence in support of this statement might be cited. I had occasion to note such cases at Béthune; and Quénu and Rouhier [57] have described in detail instances of the rapid disappearance of shock after cutting away traumatized tissue. McNee, Sladden and McCartney [52] have declared that when a quick amputation of a lacerated region is possible, "the operation is commonly followed by a remarkable and maintained improvement, so rapid and striking as to appear a direct sequel to the removal of the damaged limb." And they cite the case of a wounded man who was too shocked to allow any movement whatever, and in whom a similar good result was obtained by tying a tourniquet as tightly as possible around the limb which was so badly smashed that amputation was seen to be inevitable if the patient survived. The observations of Santy [58] on the effects of

56. Rouhier, cited by Quénu: Rev. de chir. **56**:272, 1918.
57. Quénu and Rouhier: Rev. de chir. **56**:273, 1918.
58. Santy, cited by Quénu: Rev. de chir. **56**:233, 234, 1918.

delaying operation on the severely wounded confirm on a larger scale the foregoing individual instances. In a series of seventy-nine cases of nontransportable wounded soldiers, in which the time between the receipt of the wounds and the surgical treatment was known, the mortality was only 11 per cent. when the operation was performed in the first three hours. It rose to 37 per cent. when there was a delay of between three and six hours (though infection is not marked until after six hours), and was 75 per cent. in the eighth and ninth hours. These figures vividly illustrate what may reasonably be expected if time is given, both for the disintegration of damaged tissue and the absorption of toxic material.

The foregoing experimental and clinical testimony, most of which was gathered only in the last two years of the war, gives a quite new turn to ideas regarding the nature of shock. In this connection, the argument of Groeningen,[59] written in 1885 in support of the nervous origin of shock, is of interest. He pointed out that shock is more frequent after shell wounds and crushing accidents than after cuts and stabs; more frequent with large missiles than with rifle bullets; more frequent with amputations and resections near the trunk than distant from it; more frequent in operations which expose a large rather than a small surface, and more frequent with a prolonged operation than with a short one. All these considerations, he cited as showing that violent stimulation and shattering of nerves are the occasion for shock. It is clear, however, that they may quite as well be instanced as the conditions which are most favorable for causing the death of considerable masses or areas of tissue (thus liberating toxic agents) and for rendering the organism sensitive to the action of such agents.

In the development of our conception of the effects of extensive burns, there has been an evolution of ideas similar to that which has occurred with regard to traumatic shock. Forty years ago, Sonnenberg[60] attributed death from burns to a reflex depression of vasomotor tone. Modern studies[61] have shown that there is, as in shock, a great increase in the number of erythrocytes, i. e., a concentration of the blood and an enormous mobilization of leukocytes. The suggestion of recent writers[62] is that here too, death, when delayed, is the outcome

59. Groeningen: Ueber den Shock, Wiesbaden, 1885.

60. Sonnenberg: Deutsch. Ztschr. f. Chir. **9**:138, 1877; Virchows Arch. f. path. Anat. **80**:381, 1880.

61. Becker and Schnitz: Klinische und chemische Beiträge zur Pathologie der Verbrennung, Mitt. a. d. Grenzgeb. d. Med. u. Chir. **31**:416, 1919. Weiskotten, H. G.: Histopathology of Superficial Burns, J. A. M. A. **72**:259 (Jan. 25) 1919.

62. Bardeen: Bull. Johns Hopkins Hosp. **9**:137, 1898. Eyff: Centralbl. f. d. Grenzgeb. d. Med. u. Chir. **4**:428, 1901. Pfeiffer: Virchows Arch. f. path. Anat. **180**:367, 1905. Vogt: Ztschr. Exper. Path. u. Pharm. **11**:191, 1912.

of an intoxication, probably by protein derivatives set free from the area of tissue destruction. The present conception seems to be that not only the shock following burns, but also the delayed shock consequent on severe trauma, is properly placed in the same category with other forms of general depression of bodily functions and defective circulation due to the setting free of toxic material in the body.

FURTHER OBSERVATIONS ON THE LYMPHATIC ORIGIN OF CHOLECYSTITIS, CHOLEDOCHITIS AND THE ASSOCIATED PANCREATITIS *

EVARTS A. GRAHAM, M.D., AND M. G. PETERMAN, M.D.
ST. LOUIS

The most common conceptions of the pathogenesis of infections of the gallbladder and bile tracts are based on four assumed possibilities: (1) descending infection from the liver by bacteria carried down in the bile, (2) ascending infections from the duodenum up the common bile duct, (3) hematogenous infections of the gallbladder and ducts, and (4) a spreading infection through the wall of the gallbladder from an inflamed contiguous organ. Of these possibilities, it is only the last two which take into serious consideration the actual infection of the deeper layers of the wall of the gallbladder, despite the fact that microscopic examinations of gallbladders removed at operation, at least those which we have studied, demonstrate that there are inflammatory changes not merely in the mucosa but also in the deeper layers and that usually these changes are more pronounced in the deeper layers. The other two possibilities are concerned only with the entrance of organisms into the lumen of the gallbladder, and they do not explain their entrance into its walls. They assume also that contact infection of the mucosa of the gallbladder occurs easily and frequently. But there is no direct evidence to support the idea that cholecystitis occurs, except perhaps occasionally, merely as a result of the entrance of bacteria into the lumen of the gallbladder; and there is much evidence, both clinical and experimental, that such infections are probably rare.

This evidence consists of a number of facts: (1) In experiments on ten dogs in which large amounts of pathogenic colon bacilli were injected into the normal gallbladder, no cholecystitis was produced sufficient to be demonstrable by gross appearance or clinical signs, except in one case. In order to produce it with any degree of regularity, it was necessary either to obstruct the outflow from the gallbladder by ligation of the cystic duct or to injure the blood supply by ligation of the cystic artery. In this connection a statement by Meyer, Neilson and Feusier [1] is of interest. These authors state:

---

* Part of this paper was read before the American Surgical Association, Toronto, June 15, 1921.

* From the Department of Surgery, Washington University School of Medicine.

1. Meyer, K. F.; Neilson, N. M., and Feusier, M. L.: The Mechanism of Gallbladder Infections in Laboratory Animals. J. Infec. Dis. 28:456 (May-June) 1921.

It is generally known from the studies of Cushing and from our own, that typhoid bacilli introduced directly into the cystic bile of dogs disappear rapidly and that a cholecystitis can only be produced by considerable injury of the wall, or by placing a foreign body in the gallbladder (Marxer).

(2) Bacteria probably gain access to the gallbladder by being carried down in the bile from the liver in most, if not in all, cases of bacteriemia; yet cholecystitis is comparatively rare in such conditions. Rolleston [2] states that "in typhoid fever the bacilli are always present in the gallbladder, but cholecystitis is comparatively infrequent." Osler [3] states that cholecystitis occurred in only nineteen of his series of 1,500 cases. (3) Theoretically, the mere presence of bacteria within the lumen of the gallbladder should be of no more significance in producing cholecystitis than that the presence of bacteria in the urine should imply an inflammation of the urinary bladder. It is well known that bacteria are frequently passed in the urine in large amounts without the coincidence of cystitis, especially in typhoid fever.

If the assumption is correct that the wall of the gallbladder beneath the mucosa is involved in most cases of cholecystitis, then it would seem reasonable to discard the idea of the serious importance of contact infections of the mucosa by organisms within the bile, particularly in view of the evidence outlined above. How then may an infection originate in the wall? It is obvious that in general only two routes are available for the transmission of organisms to the wall. One of these is the blood stream and the other is the lymph stream.

In 1909, Koch [4] demonstrated clumps of bacilli in the wall of a gallbladder and concluded that typhoidal cholecystitis is due to capillary embolism. In the same year, also, Chiarolanza,[5] working under Koch's direction, came to the same conclusion. Rosenow [6] has particularly emphasized the idea of the hematogenous origin of cholecystitis. Meyer and his collaborators,[1] in their exhaustive article on the mechanism of gallbladder infections, report experiments on 500 rabbits in which they attempted to produce a condition analogous to the human typhoid carrier state. They consider that the findings of Koch and Chiarolanza of bacterial emboli in the wall of the gallbladder during

2. Rolleston, H. D.: Diseases of the Liver, Gallbladder and Bile-Ducts, New York, the Macmillan Company, 1912, p. 608.

3. Osler, William: Practice of Medicine, 1905, p. 83.

4. Koch, J.: Typhusbazillen und Gallenblase, Ztschr. f. Hyg. u. Infectionskrankh, **62**:1, 1909.

5. Chiarolanza: Experimentelle Untersuchungen ueber die Beziehungen der Typhusbazillen zu der Gallenblase und der Gallenwegen, Ztschr. f. Hyg. u. Infectionskranskh, **62**:12, 1909.

6. Rosenow, E. C.: The Etiology of Cholecystitis and Gallstones and Their Production by the Intravenous Injection of Bacteria, J. Infec. Dis. **19**:527 (Oct.) 1916.

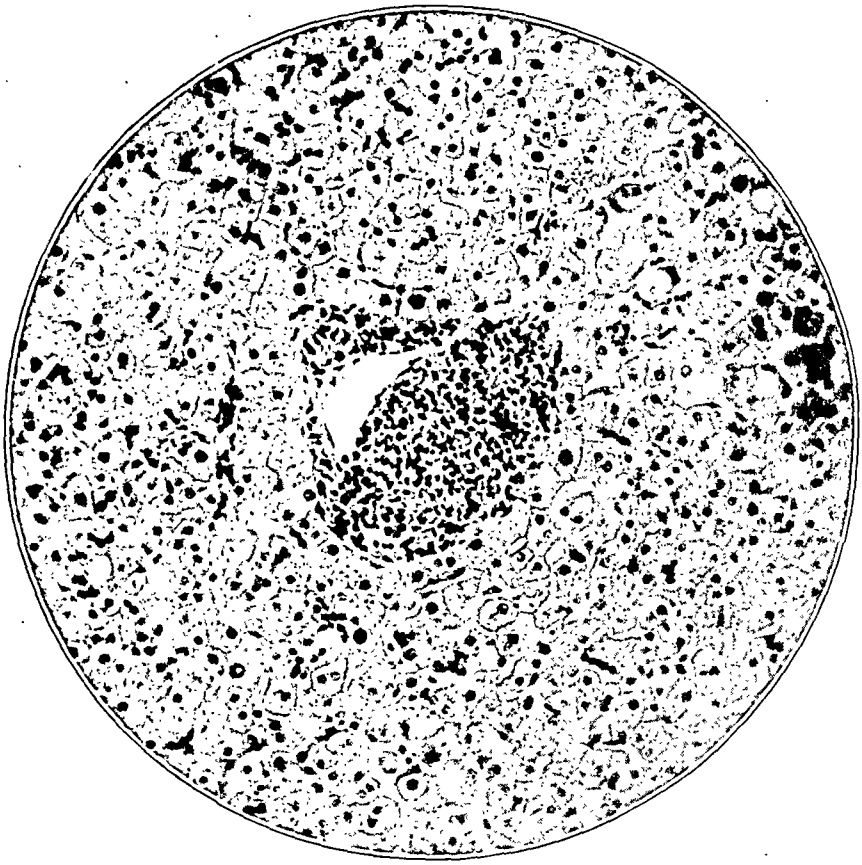

Fig. 1.—A common type of hepatitis occurring in association with a subacute cholecystitis. The periportal sheaths are densely infiltrated with leukocytes, chiefly of the polymorphonuclear variety. From a study of small pieces of liver removed at operation in cases of cholecystitis, either with or without stones, it has been noted that some degree of hepatitis is a constant accompaniment of cholecystitis.

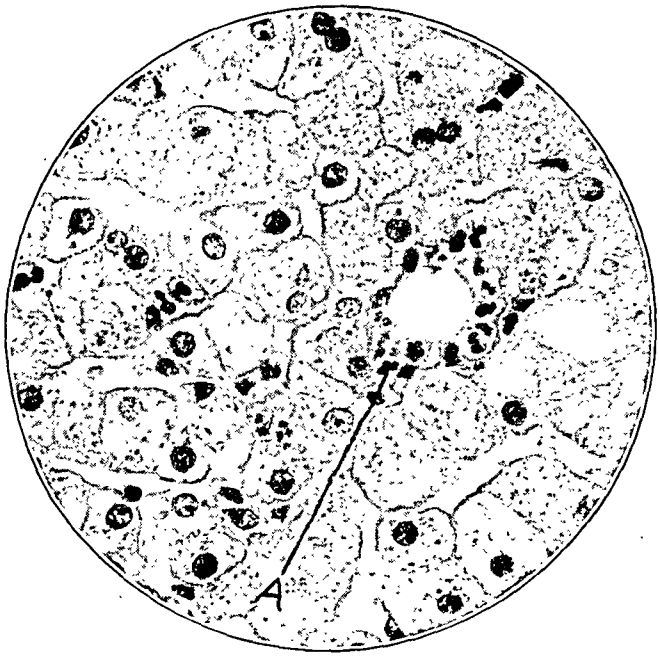

Fig. 2.—Higher power magnification of another part of the same liver showing accumulation of polymorphonuclear leukocytes around a small bile duct, indicated by line marked *A*.

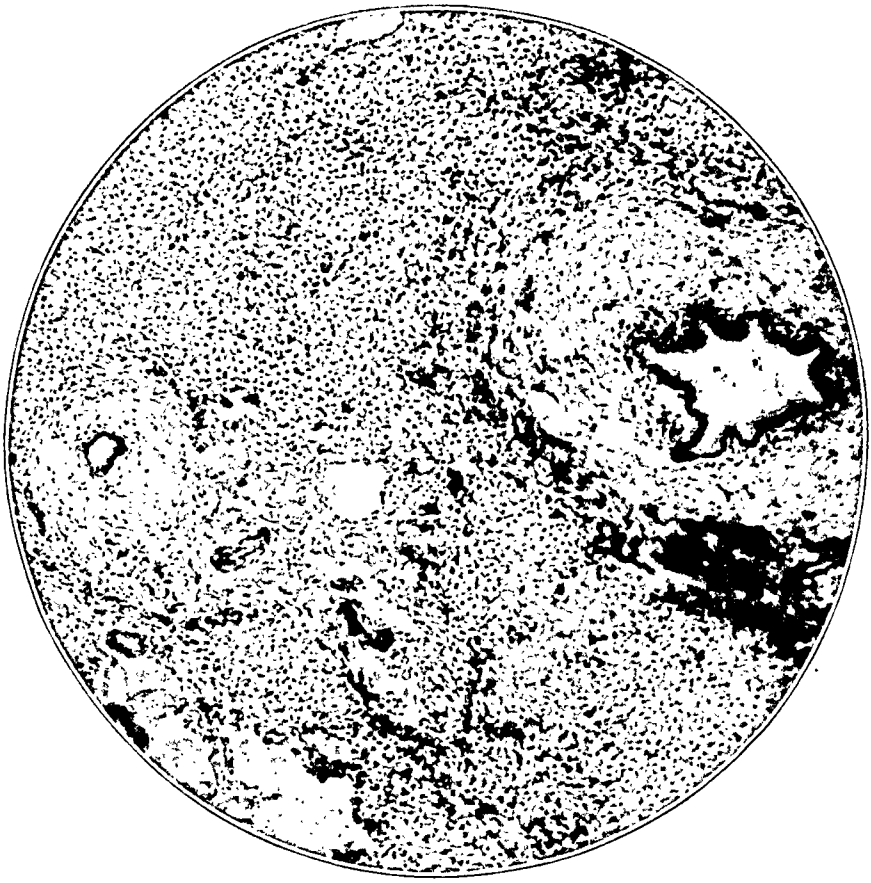

Fig. 3.—Chronic hepatitis (biliary cirrhosis) in a woman who had a history of gallbladder trouble extending over a period of fifteen years. Jaundice had never been present; therefore, there had been no biliary obstruction. At operation, stones were found in the gallbladder. The marked thickening of the small bile ducts is strikingly evident.

Fig. 4. —Gallbladder removed at operation in case of cholecystitis without stones. Deep in the fibromuscular layers at a considerable distance from the mucosa were found collections of polymorphonuclear leukocytes, designated by lines marked *A*. These are usually much more conspicuous in the deeper layers than in the mucosa. Normally, the mucosa contains large numbers of round cells (lymphocytes).

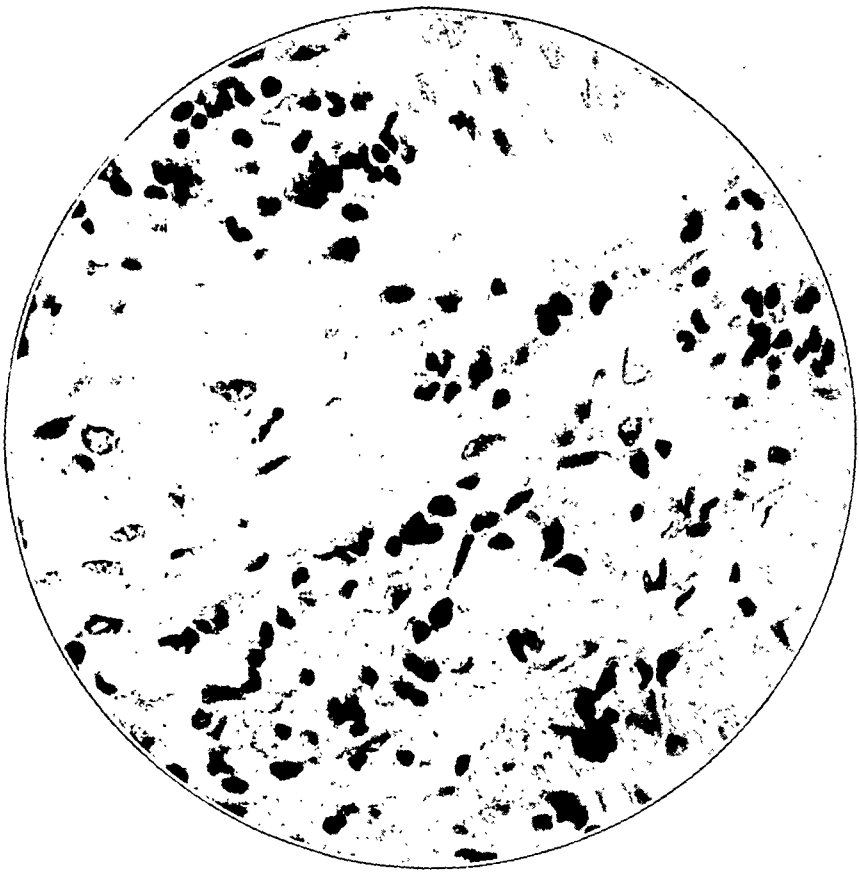

Fig. 5.—Higher magnification of same gallbladder as shown in Figure 4. The leukocytic infiltration shown here is deep in the wall of the gallbladder at a considerable distance from the mucosa.

Fig. 6.—Another human gallbladder from case of cholecystitis without stones; wall extensively infiltrated with leukocytes; mucosa relatively intact.



Fig. 7.—High power magnification of Figure 6 showing polymorphonuclear leukocytes far out in the wall of the gallbladder.

Fig. 8.—Another human gallbladder; cholecystitis without stones; mucosa relatively intact, but in outer layers of wall there is rather extensive leukocytic infiltration.

typhoid to be "exceptionally rare" and concerned with an "exceedingly severe and unique form of typhoid cholecystitis." They arrive at this conclusion partly because in their own experiments, even after the intravenous injection of enormous doses of typhoid bacilli (8,000 to 24,000 million), only about one third of the rabbits presented histologic evidence of an infection through the terminal capillaries of the mucosa, and also because, as they state, examination of human gallbladders in cases of death from typhoid shows a capillary embolism only occasionally. They are inclined, however, to consider very seriously, especially in the rabbit, the possibility of contact infection of the mucosa of the gallbladder by bacteria carried down in the bile from the liver, and they hold the opinion that deep infections of the wall are frequently the result of a spread of the infection from the mucosa. In human typhoid carriers, they consider that "the embolic infection of the gallbladder wall plays an insignificant rôle." They state, furthermore, that "a condition analogous to that found in man apparently exists in the guinea-pig. The microscopic and cultural study of a limited number of gallbladders derived from infected guinea-pigs convinces us that the wall is rarely, and then only slightly, infected through the bile." This then seems to constitute another argument against the frequency of contact infection of the gallbladder in man. There can be little doubt apparently that cholecystitis not infrequently is hematogenous in origin; but yet we do not believe that an explanation based on this idea is sufficient for most cases of spontaneous cholecystitis, especially those which are not typhoidal in origin. The well known, striking tendency of cholecystitis to be associated with appendicitis and other inflammatory lesions of the portal system must be something more than a coincidence. Birch-Hirchfeld,[7] in 1895, considered that organisms were carried to the liver and from there to the gallbladder by the bile. Since then, the "hematohepatogenous" idea of the origin of cholecystitis has been a popular one. But, as we have already shown, the idea of a contact infection of the mucosa of the gallbladder has very little to support it, at least so far as its being a frequent occurrence in man. Furthermore, it is difficult to explain the association of appendicitis and other portal infections with cholecystitis on the basis of a hematogenous infection of the wall of the gallbladder, because there is no direct path from the appendix to the gallbladder by way of the blood stream. The entire arterial supply of the gallbladder comes from the hepatic artery. The cystic artery supplies most of the blood; but there are in addition a few small branches of the hepatic artery which reach the gallbladder through its attachment to the liver. The veins of the gallbladder all empty into the portal vein. If organisms, therefore, are to be carried from the appendix to the gallbladder by the blood stream, they must

7. Birch-Hirchfeld: Quoted by Meyer et al, Footnote 1.

either travel through the whole systemic circulation back through the hepatic artery to the gallbladder or there must be a retrograde passage of them from the liver into the gallbladder through the tributaries of the portal vein. If the first alternative were correct, then there would be no more reason for cholecystitis to be associated with appendicitis than with infections elsewhere in the body, as the hand for example. The second alternative is based on the slender support of a comparatively rare possibility, a retrograde thrombosis, or at least a retrograde pylephlebitis.

There is, however, one route between the appendix and gallbladder which is comparatively direct and easy to understand, and that is a "hematolymphatic" route. Sudler [8] has shown a very intimate lymphatic connection between the liver and gallbladder through the attachment of the gallbladder to the liver. This is shown in Figure 34, which is taken from his article. We have repeated some of Sudler's experiments and have confirmed his idea of the general arrangement and anastomosis of the hepatic and cholecystic lymphatics. The lymph vessels of the gallbladder may be seen after injections of such a substance as Prussian blue into the portal vein. Conversely, also, injections made into the wall of the gallbladder not only follow the lymphatics into the liver in the interlobular sheaths but also may be seen to pass along the lymphatics of the common duct and into the pancreas. An infection of the liver, therefore, would tend to spread to the gallbladder by way of the lymphatics, and conversely an infection of the gallbladder would tend to spread not only to the liver but also along the common duct to the pancreas. In this respect, infections in this region would merely follow the rule of infections elsewhere in the body. We should expect to find evidence, therefore, that in cases of cholecystitis there is also an associated inflammation in the liver.

In 1918, one of us [9] showed in a series of cases in which small pieces of the liver were removed at operation for cholecystitis that microscopic evidence of hepatitis existed in every case. The inflammation was chiefly in the interlobular sheaths and appeared to be a pericholangitis. This location of inflammatory changes is in harmony with the idea of a lymphangitis, for it is here that the hepatic lymph vessels are chiefly situated.[10] In another paper, we [11] showed that in the

8. Sudler: The Architecture of the Gallbladder, Bull. Johns Hopkins Hosp. **12**:126, 1901.

9. Graham, E. A.: Hepatitis: A Constant Accompaniment of Cholecystitis, Surg., Gynec & Obst. **26**:521 (May) 1918.

10. Mall, F. P.: On the Origin of the Lymphatics in the Liver, Bull. Johns Hopkins Hosp. **12**:146, 1901.

11. Peterman, M. G.; Priest, W. S., Jr., and Graham, E. A.: The Association of Hepatitis with Experimental Cholecystitis and Its Bearing on the Pathogenesis of Cholecystitis in the Human, Arch. Surg. **2**:92 (Jan.) 1921.

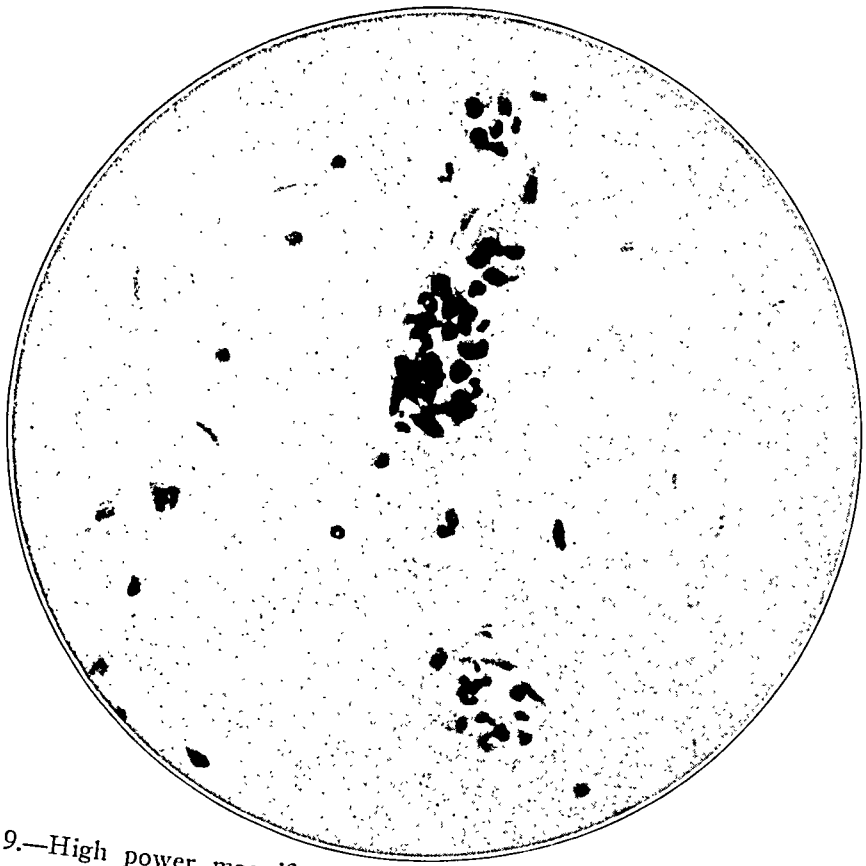

Fig. 9.—High power magnification of another human gallbladder showing small accumulations of polymorphonuclear leukocytes far out in the wall.

Fig. 10.—Cholecystitis with stones; whole wall, including mucosa, markedly inflamed.

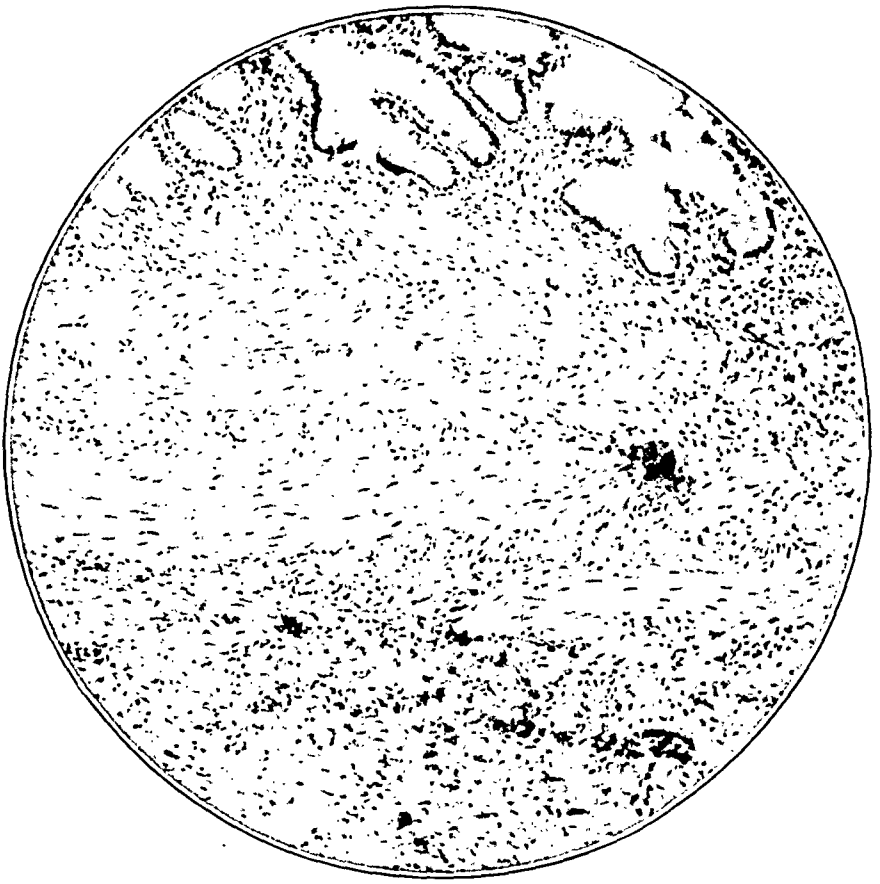

Fig. 11.—Cholecystitis without stones; mucosa relatively normal, but leukocytic infiltration in outer layers of wall.

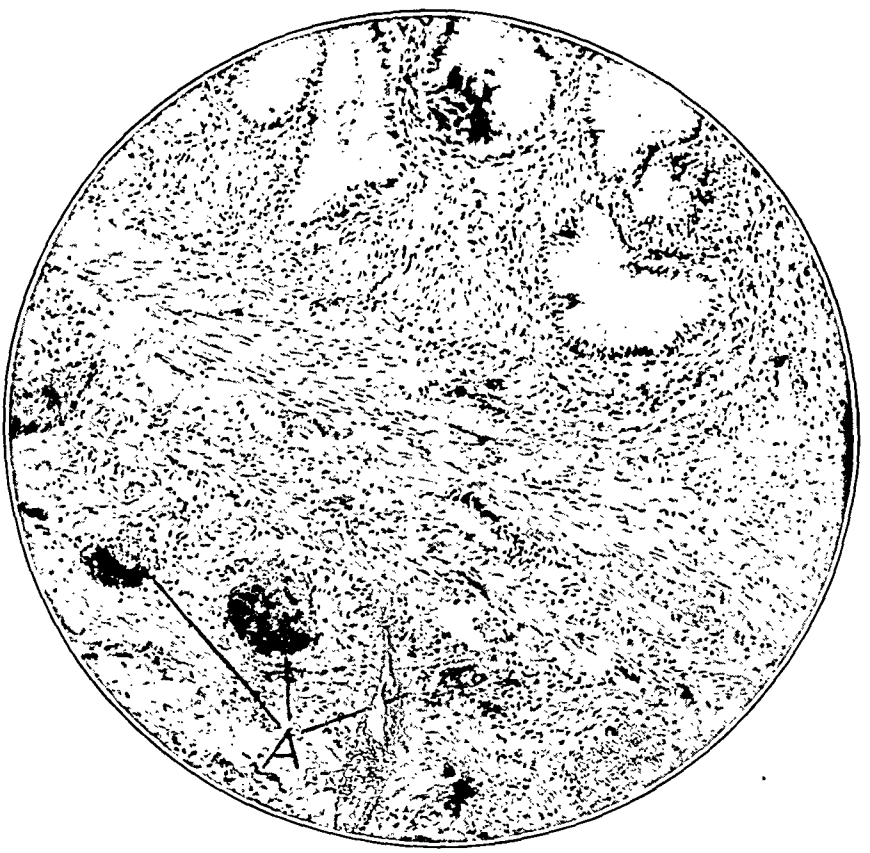

Fig. 12.—Cholecystitis without stones; normal mucosa but rather large collections of leukocytes (both polymorphonuclears and round cells) in deeper layers of wall, designated by lines marked *A*.

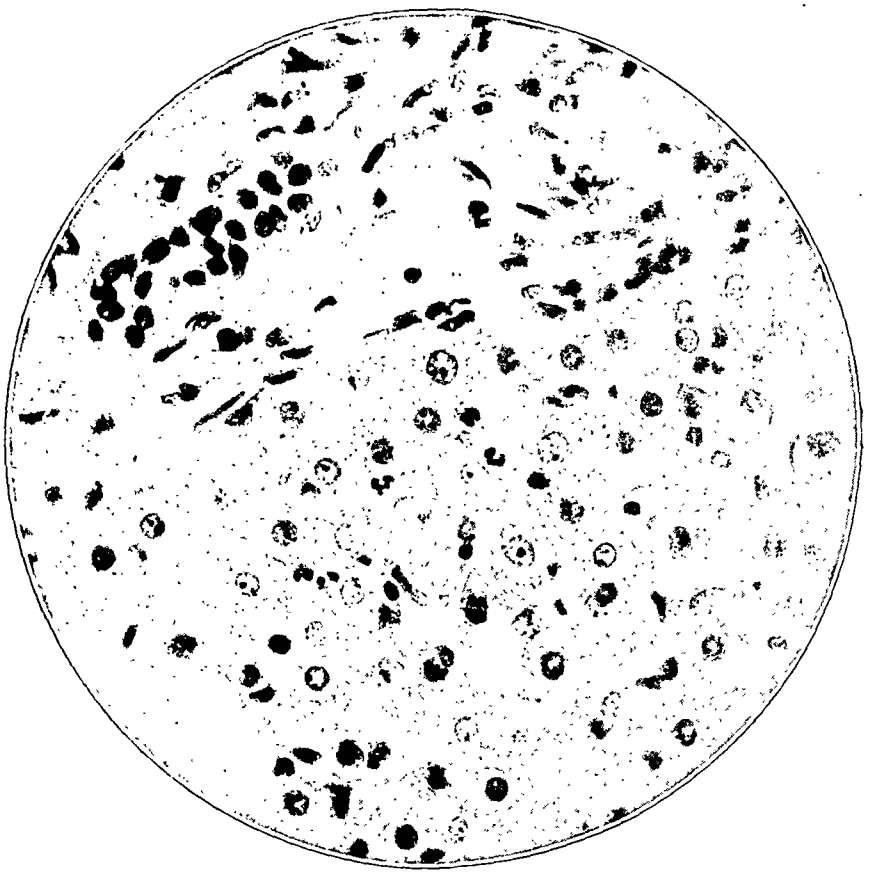

Fig. 13.—Hepatitis in association with chronic appendicitis; piece of liver removed at operation for chronic appendicitis; no evidence of cholecystitis. Note polymorphonuclears in lobule near its periphery.

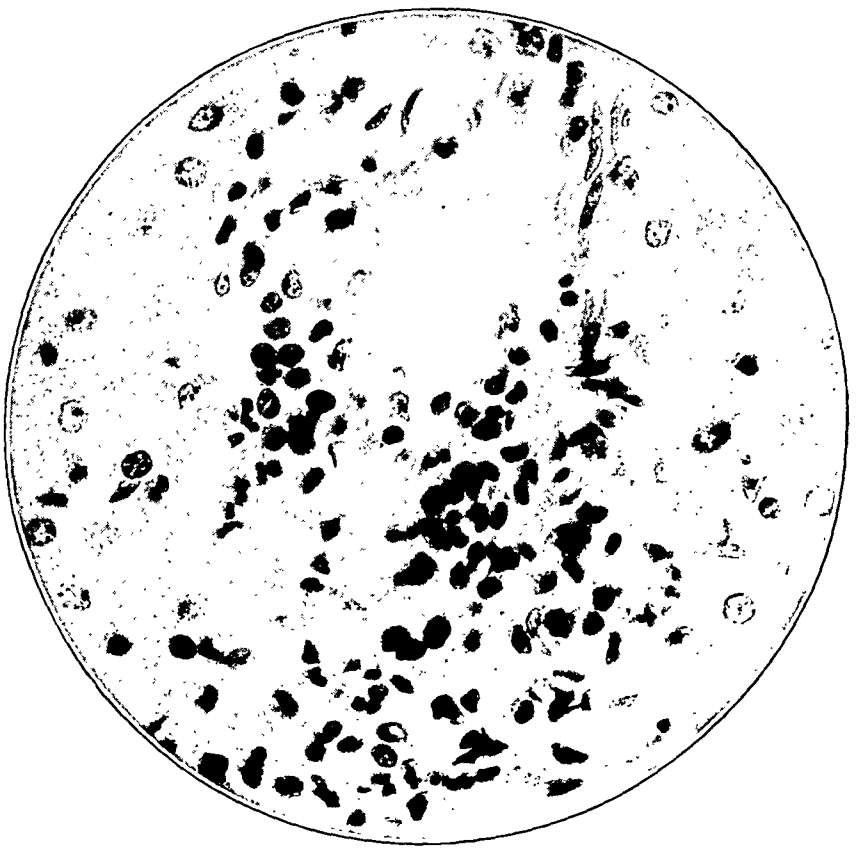

Fig. 14.—Hepatitis with chronic appendicitis, showing leukocytic infiltration in interlobular tissue; piece of liver removed in another case of chronic appendicitis; no evidence of cholecystitis.

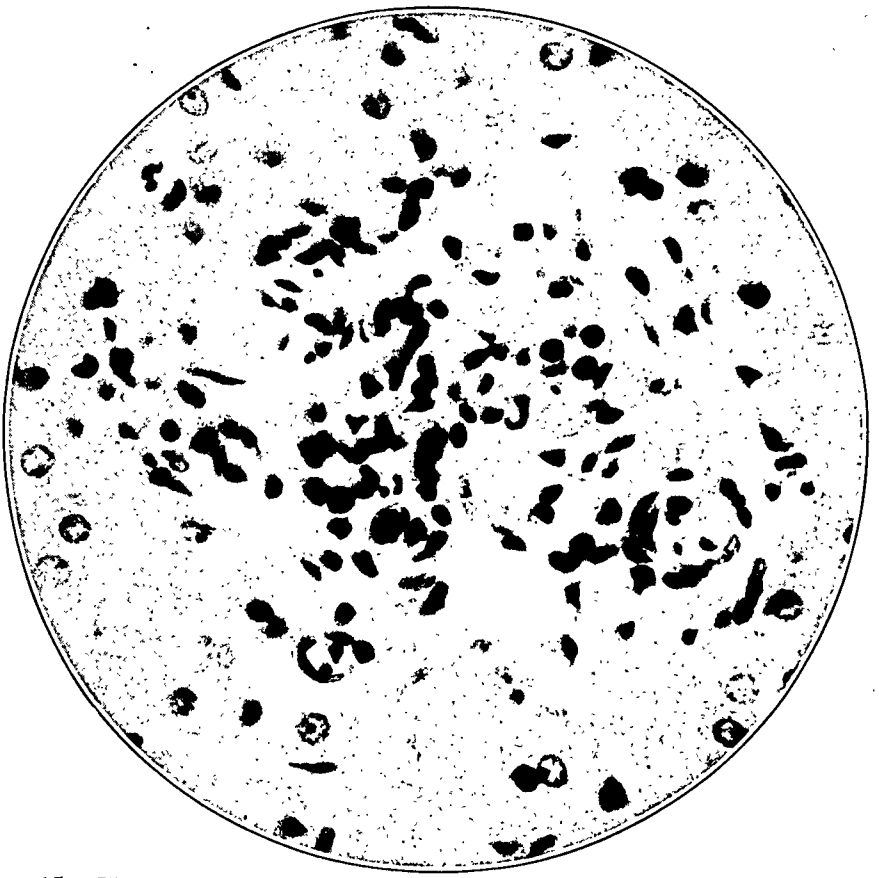

Fig. 15.—Hepatitis with chronic appendicitis; periportal leukocytic infiltration; piece of liver removed at operation for chronic appendicitis; no evidence of cholecystitis.

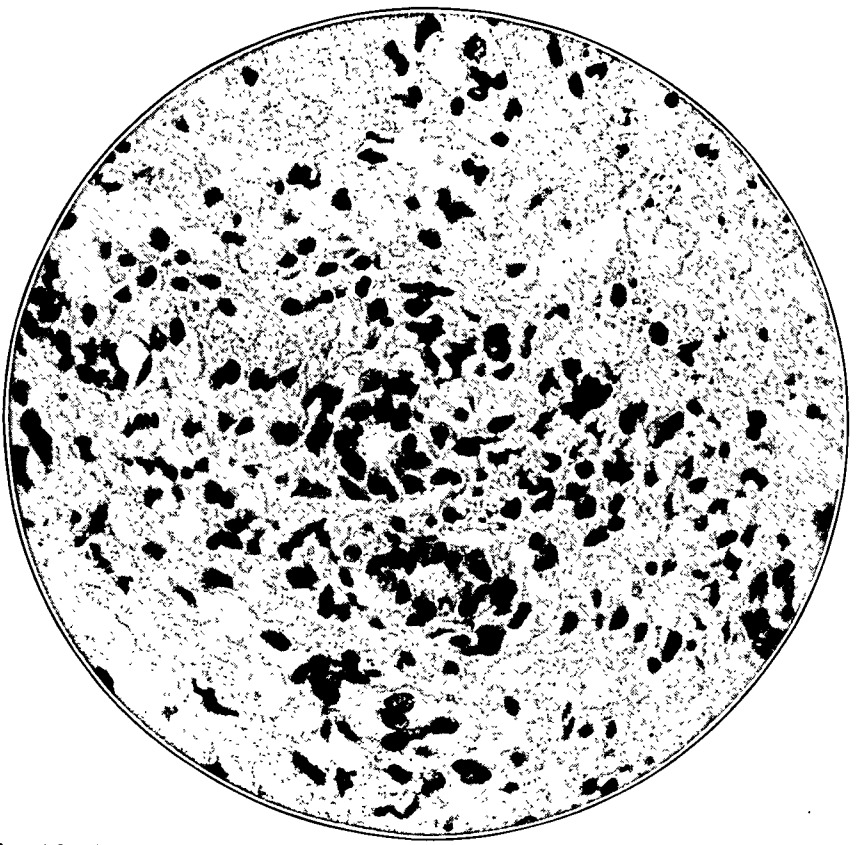

Fig. 16.—Experimental hepatitis by injection of portal vein with *Staphylococcus aureus* (Dog 1); marked periportal infiltration with polymorphonuclear leukocytes.

dog experimental cholecystitis is constantly accompanied by a hepatitis of the same sort as already observed in man. It is interesting that when this occurs secondarily to the production of a cholecystitis the right lobe of the liver is very much more affected than the left lobe, and the most marked changes of all are in the right lobe near the gallbladder. This all seems to indicate that the spread of the infection to the liver from an already inflamed gallbladder must occur through the lymphatics rather than through the veins, because in the latter instance, since the veins are tributaries of the portal vein, a more even distribution of the infection through the liver would be expected. The possibility of the establishment of a vicious circle between an infected gallbladder and the liver, whereby each may reinfect the other through the lymphatics, becomes readily apparent. This finding of the constancy of a hepatitis in association with cholecystitis has been confirmed recently by Judd,[12] who states, "A review of our studies inclines us to believe with Graham that cholecystitis rarely exists without hepatitis." In our original paper, to which reference has already been made, it was said that in a series of thirty consecutive cases coming to operation for gallbladder disease an enlargement of the liver was noted in 87 per cent. Subsequent observations have not borne out this high percentage, and we are forced to the conclusion that the actual percentage of noticeable enlargement of the liver is very much smaller than the figure given.

If we are to explain the frequent association of appendicitis with cholecystitis on the basis of a primary infection of the liver from the appendix, by way of the portal vein, and of a cholecystitis resulting from that secondarily, by way of a lymphatic spread from the liver to the gallbladder, then obviously it would seem necessary to find evidence of hepatitis in association with appendicitis. Recently, in a few cases which came to operation for chronic appendicitis, we removed small pieces of the liver for examination. Three of the accompanying photomicrographs (Figs. 13, 14 and 15) show areas of infiltration in the liver (both polymorphonuclears and round cells). In none of the cases represented here was there any evidence, either clinical or at operation, of cholecystitis. This fact seems important since in consequence the existing hepatitis could hardly be assumed to have been secondary to a cholecystitis. We have frequently noted slight liver tenderness in association with chronic appendicitis and have considered the sign of some importance in diagnosis. The question may arise as to why cholecystitis did not occur in the cases of hepatitis with appendicitis illustrated here. The answer is, of course, difficult, but perhaps the intensity of the hepatitis was not sufficient.

12. Judd, E. S.: Relation of the Liver and Pancreas to Infection of the Gallbladder, J. A. M. A. **77**:197 (July 16) 1921.

It is interesting that even those who favor the idea of the contact infection of the mucosa of the gallbladder by bacteria carried in the bile from the liver, the so-called "hematohepatogenous" theory, are forced to assume some degree of inflammation of the liver preceding the infection of the gallbladder. This question is discussed at some length by Meyer and his collaborators who state that "dosage, virulence and *lesions* [italics ours], and not the secretory, detoxifying activity of the liver, are the prerequisites for the passage of bacteria from the blood to the bile capillaries. . . . The conception of a purely mechanical passage deserves little consideration." Wyssokowitch [13] and also Blachstein [14] considered liver necroses prerequisites for the infection of the biliary passages in typhoid. If it is granted then that some degree of inflammation of the liver must be present before the bile can be infected, it seems only reasonable to assume that in many cases the infection will spread by means of the lymphatics and will therefore involve the gallbladder wall. Meyer states that "from an experimental standpoint the lymphatic route is of no importance," but yet he says that "in the course of peritonitis or other abdominal infections (appendicitis), streptococci can be transported through the lymphatics to the biliary passages," and again, "the so-called ascending route of infection is in all probability due to an invasion of bacteria through the lymphatics." He also states that in about 1 per cent. of the rabbits and guinea-pigs used there was a spontaneous cholecystitis due to *Bacillus coli,* streptococci or staphylococci. In these cases, "occasionally the bile appeared to be normal while the histologic picture exhibited a low-grade infection of the lymphatics of the mucosa and subserosa."

We believe that there is quite a little confusion about what is meant by the biliary lymphatics. Meyer and his collaborators speak of them as if they were entirely extrahepatic, and apparently they do not recognize that the extrahepatic lymphatics are continuous with those within the liver. This is the common conception of the lymphatics of the biliary tract. Sudler's important work is too little known. As a matter of fact, we do not see why nearly all the results on experimental cholecystitis cannot be just as easily interpreted on the basis of a lymphatic infection of the wall as on the idea either that there has been a contact infection of the mucosa or an infection of the wall directly through the blood stream. We admit, however, the possibility of infection through both of the latter means; but we are inclined to believe that the idea of a lymphatic origin secondary to a hepatitis explains the majority of cases of cholecystitis in man better than any other.

We have stated elsewhere that if a suitable substance, such as Prussian blue, be injected into the wall of the gallbladder, its course

13. Wyssokowitch: Quoted by Meyer et al, Footnote 1.
14. Blachstein: Quoted by Meyer et al., Footnote 1.

Fig. 17.—Experimental cholecystitis from Dog 1 by injection of portal vein; extensive inflammation of wall; mucosa relatively unaffected.

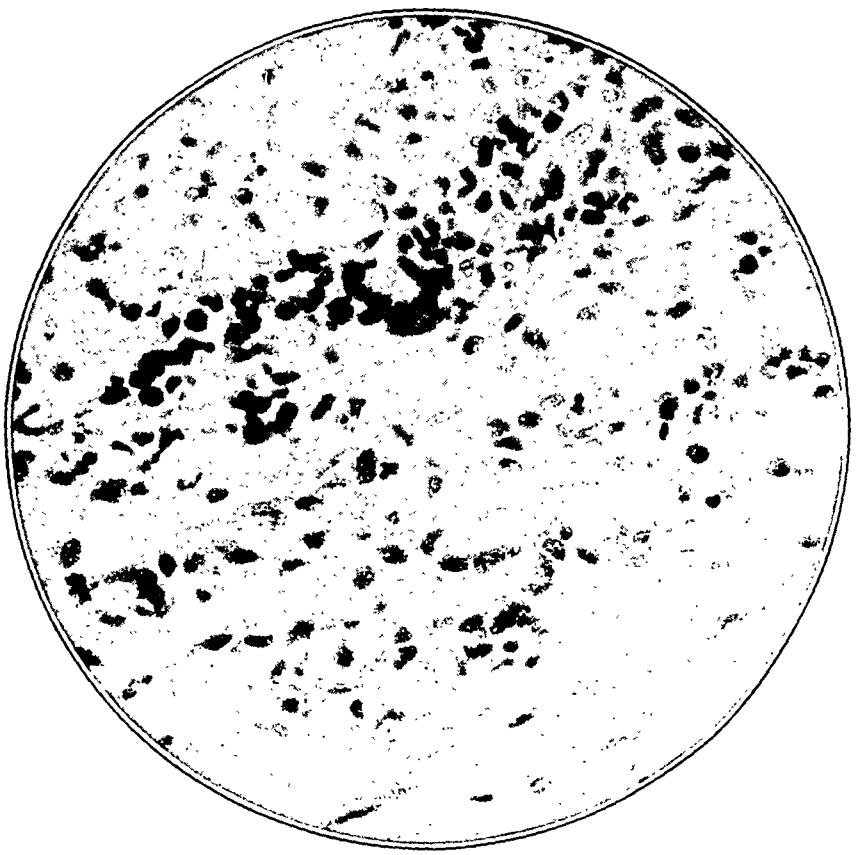

Fig. 18.—Higher power photomicrograph of specimen shown in Figure 17, showing leukocytic infiltration of wall of gallbladder.

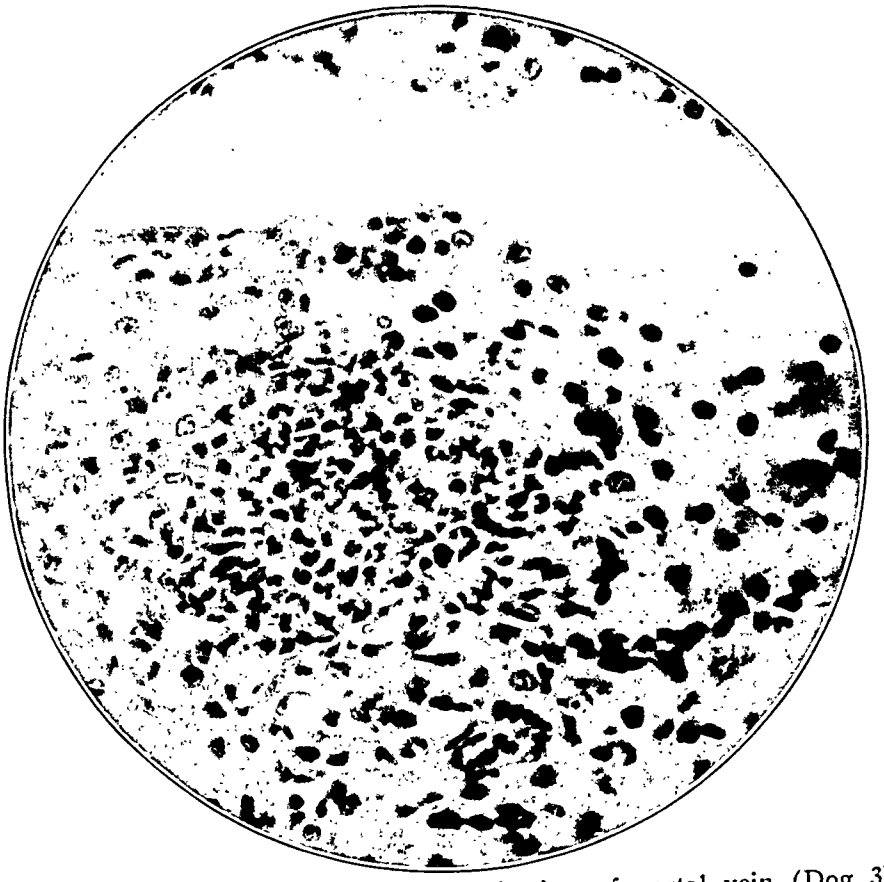

Fig. 19.—Experimental hepatitis by injection of portal vein (Dog 3).

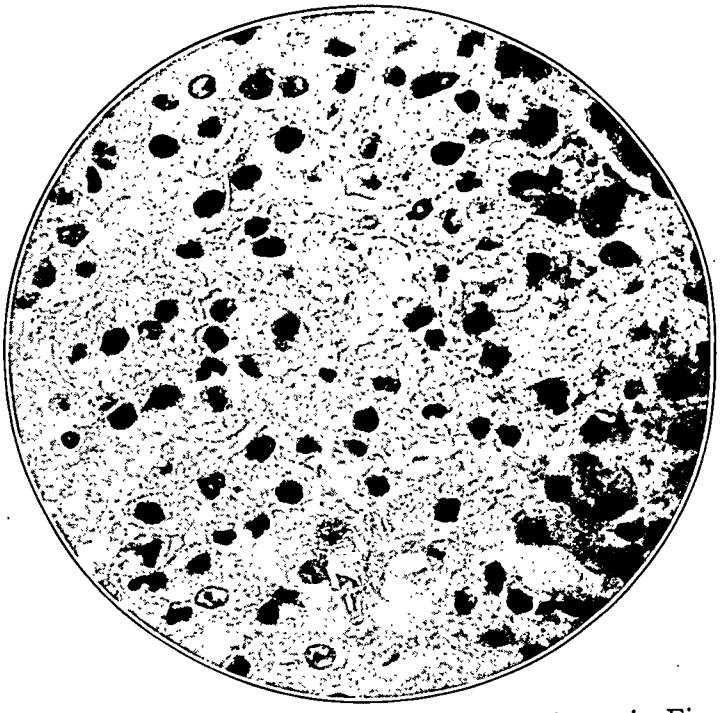

Fig. 20.—Another section from same liver as shown in Figure 19.

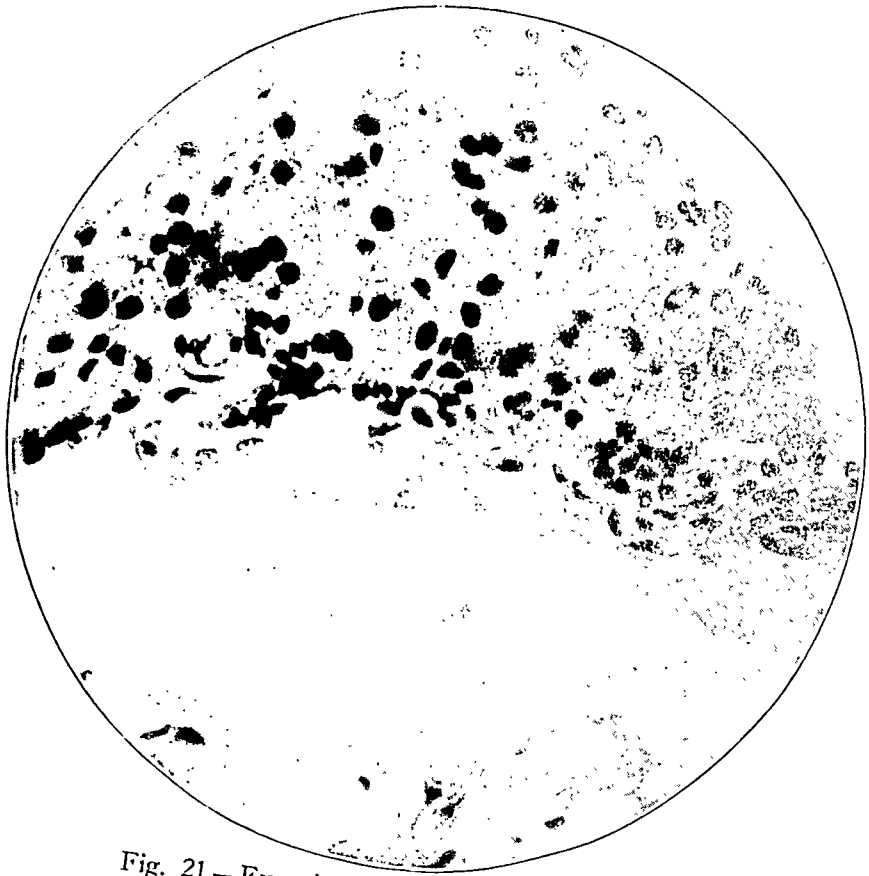

Fig. 21.—Experimental hepatitis (Dog 6).



Fig. 22.—Experimental hepatitis (Dog 7); polymorphonuclear leukocytes scattered throughout whole lobule.



Fig. 23.—Cholecystitis in same dog (Dog 7); polymorphonuclear leukocytes scattered throughout wall of gallbladder.

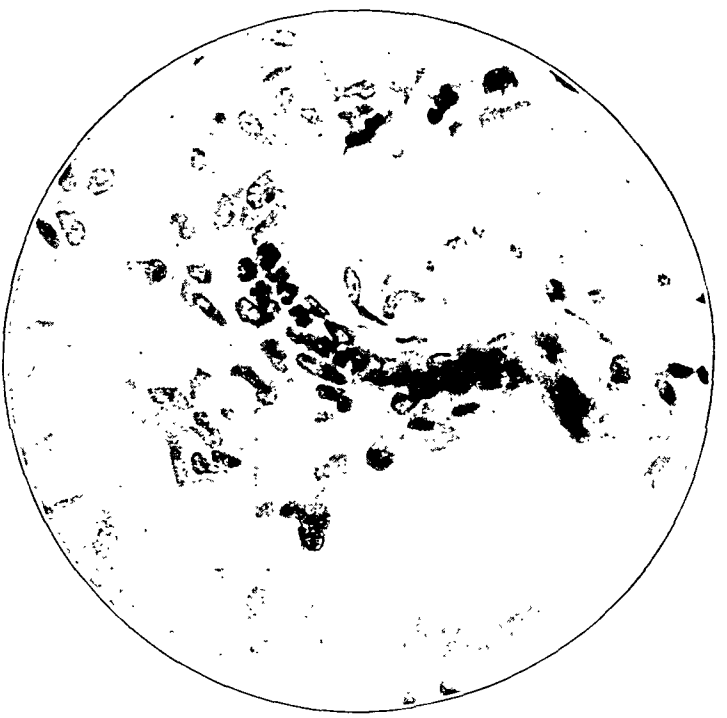

Fig. 24.—Same experiment as in Figure 23; polymorphonuclear leukocytes in deeper layers of wall of gallbladder.

may be followed through the lymphatics down along the common duct and into the head of the pancreas. For years, Deaver [15] has strongly advocated the lymphatic origin of the chronic interstitial pancreatitis which is so common an accompaniment of cholecystitis. Maugeret,[16] in 1908, wrote a thesis on this subject which offers much evidence in support of the possibility of the lymphatic spread to the pancreas. Archibald [17] has raised questions with regard to the lymphatic route theory and has sought to explain the pancreatitis on a basis of an influx of bile into the pancreatic ducts in a manner similar to Opie's [18] classical explanation of the origin of acute hemorrhagic pancreatitis. Deaver and Sweet [15] have replied to these objections of Archibald's in their recent article.

In animal experiments, we have obtained results which we believe tend to support the idea of the lymphatic origin not only of cholecystitis but also of inflammation of the common duct and of the pancreas. These experiments have consisted of several types and will be reported in full by one of us (Peterman), in an article soon to appear. Two types are of particular interest here because of their special bearing on the idea of the lymphatic origin of cholecystitis and its complications. One of these groups of experiments has already been reported [11] and referred to above. It consisted in the production of hepatitis secondary to experimental cholecystitis, induced by direct inoculation of rather large amounts of organisms into the lumen of the gallbladder after ligation of the cystic duct and artery. The hepatitis produced conformed to that which had already been seen in cases of cholecystitis in man, and, for the reasons given above, it was considered as most probably representing a lymphatic spread to the liver. The other type of experiment consisted in the production of hepatitis, cholecystitis, choledochitis and pancreatitis by portal vein injections. It was felt that if cholecystitis and its common complications could be interpreted on the basis of a lymphatic spread from a liver in which the periportal spaces were the seats of inflammation, then it should be possible often in a single experiment to produce by injection of the portal vein a simultaneous hepatitis, cholecystitis, choledochitis and pancreatitis. Not only has it been possible to do this repeatedly; but the types of lesion found have agreed with those which occur in spontaneous cases in

15. Deaver, J. B., and Sweet, J. E.: Prepancreatic and Peripancreatic Disease: With a Consideration of the Anatomic Basis of Infection from the Gallbladder to the Pancreas, J. A. M. A. **77**:194 (July 16) 1921.

16. Maugeret, R.: Cholécyste—Pancréatite, Thesis, Paris, G. Steinheil, 1908.

17. Archibald, E.: The Experimental Production of Pancreatitis in Animals as the Result of the Resistance of the Common Duct Sphincter. Surg., Gynec. & Obst. **28**:529 (June) 1919.

18. Opie, E. L.: Diseases of the Pancreas, Philadelphia, J. B. Lippincott & Co., 1903.

man. It has been possible also after the injections to demonstrate the infecting organisms in the liver, in the wall of the gallbladder, in the wall of the common duct and in the pancreas. The same results occurred regardless of whether the injections were made into the main trunk of the portal vein or into one of its radicles, as the appendix vein. We believe, therefore, that the results obtained are comparable to the cases of cholecystitis in man which may be considered as following appendicitis or some other lesion of the portal system.

The experiments were conducted on seven normal dogs. After anesthetization and preparation of the skin, a median laparotomy incision was made. The portal vein was exposed at its origin, and from 4 to 6 c. c. (depending on the size of the animal) of *Staphylococcus aureus* (twenty-four hour broth culture) was injected into the portal vein, and the abdomen was closed. These animals were observed daily, and four of them were killed and examined at necropsy, from two to six days afterward. Three of the dogs were given an additional injection of hemolytic streptococci because apparently they had not been much affected by the first injection of staphylococci. From two to five days after the second injection, these dogs were killed and necropsies performed. In two additional experiments, injections of streptococci were made into a radicle of the portal vein corresponding to the appendix vein in man, and similar results were obtained to those following the injections into the portal vein itself.

In a second set of experiments in which six rabbits were used, sections were stained and examined for bacteria after injecting streptococci into the portal vein. The cystic duct, including the cystic artery, was ligated in order to eliminate the possibility of the passage of bacteria down from the liver in the bile and also to reduce to a minimum the possibility of the injected organisms reaching the gallbladder wall by way of the blood stream. After ligation of the cystic artery, the only way by which the organisms could reach the gallbladder by the blood would be either through the few small branches of the hepatic artery which pass through the attachment of the liver to the gallbladder or by a retrograde thrombosis of the portal vein into the cystic veins (which are its tributaries). In order to minimize the latter possibility, the animals were killed and examined at intervals of one, two, twelve, twenty-four and forty-eight hours, respectively, after being injected. Except perhaps in the last instance, it was felt that the time intervals were too short to permit a retrograde thrombosis. Streptococci were found in all of the last four rabbits, not only in the liver and the wall of the gallbladder but also in the pancreas. The common duct was not searched. Results of an identical sort were obtained in three other rabbits in which the injection was made into a vein corresponding to the appendix vein in man. The only exceptions,

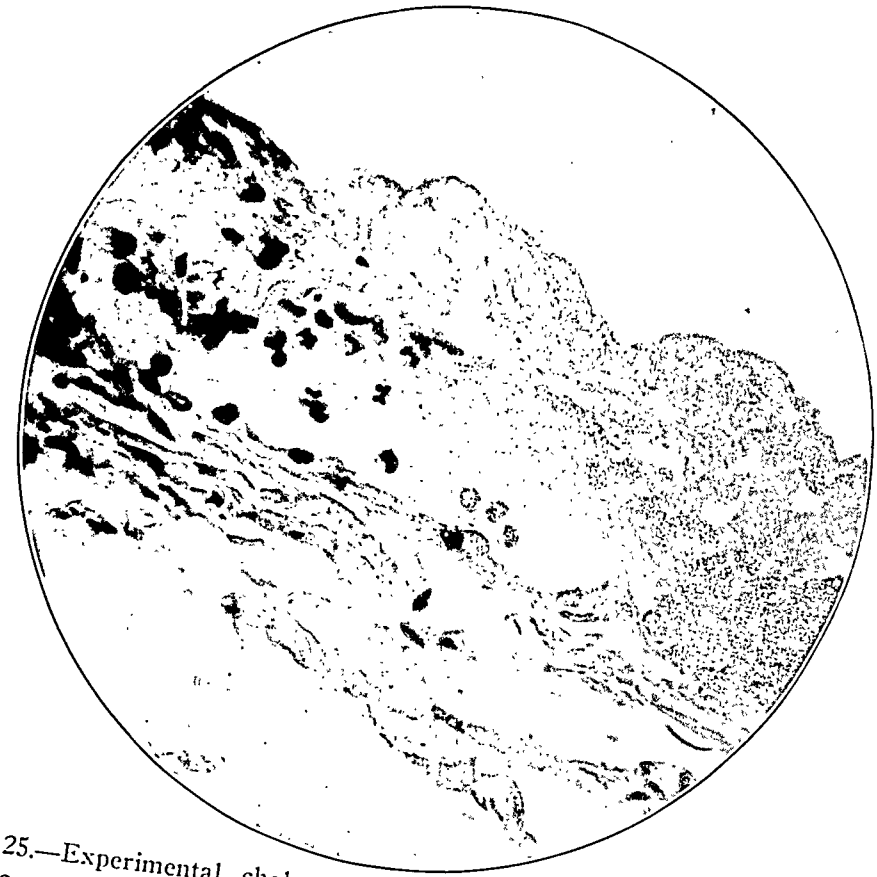

Fig. 25.—Experimental cholecystitis (Dog 7). This shows apparently a lymphatic vessel in the outer layer of the gallbladder containing polymorphonuclear leukocytes and presenting other evidence of acute inflammation.



Fig. 26.—Experimental choledochitis by portal vein injection; extensive leukocytic infiltration of wall (Dog 3).

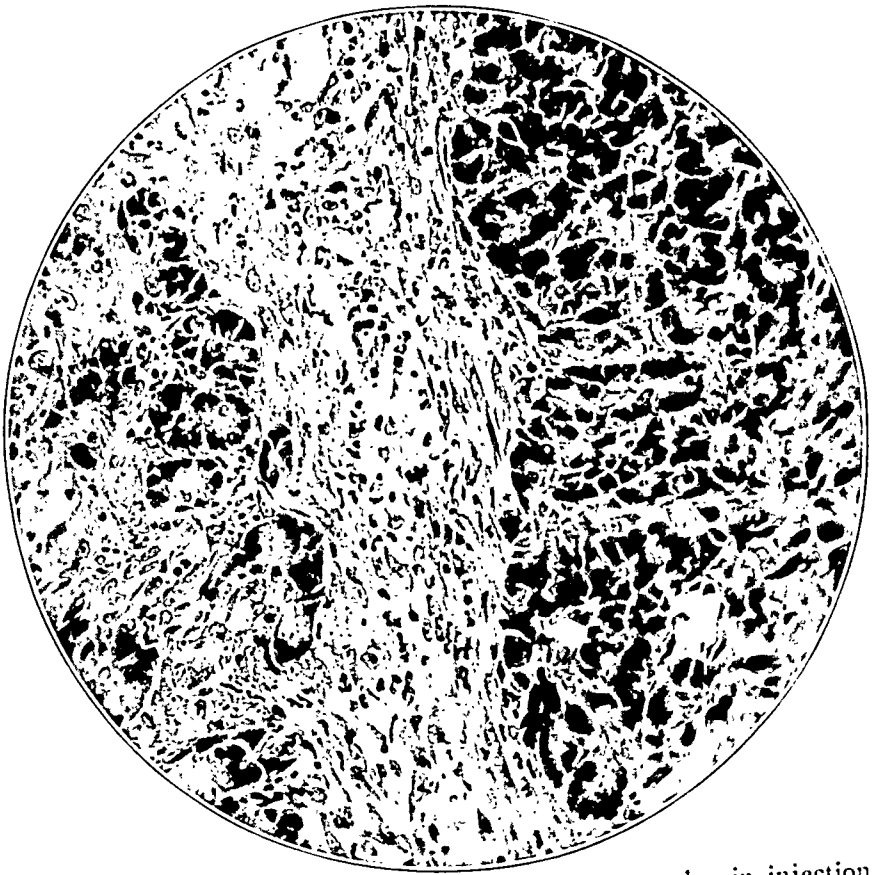

Fig. 27.—Experimental interstitial pancreatitis by portal vein injection (Dog 1); many leukocytes, chiefly polymorphonuclear, in trabeculae of pancreas.

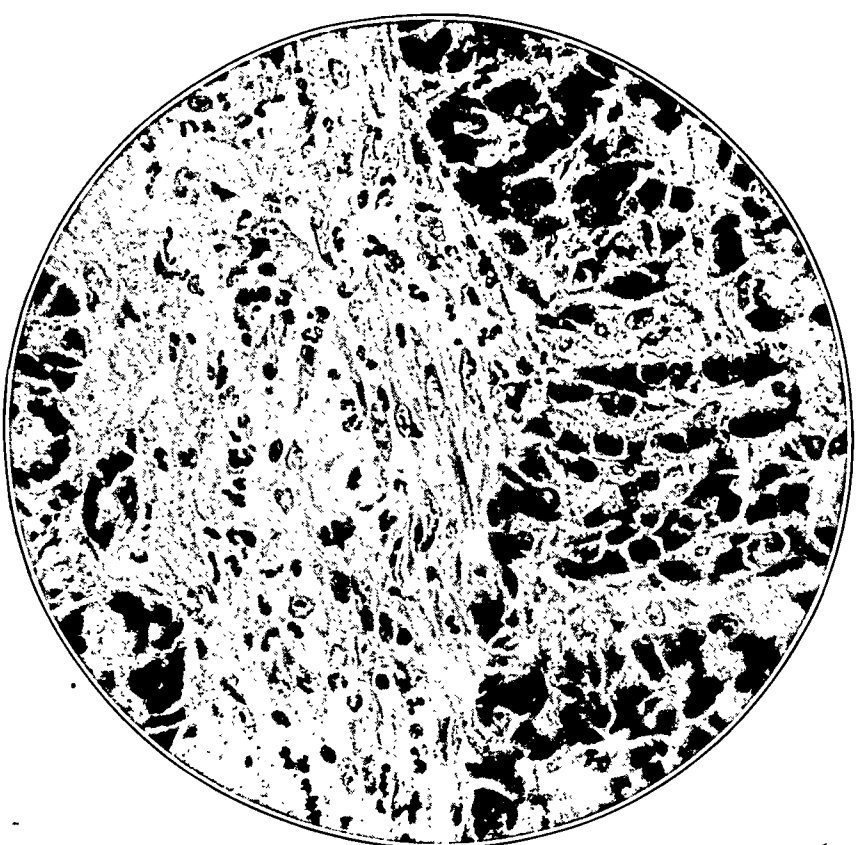

Fig. 28.—Experimental interstitial pancreatitis (Dog 2); marked preponderance of polymorphonuclear leukocytes over other cells in trabeculae.



Fig. 29.—Experimental hepatitis in rabbit; portal vein injection with streptococci; demonstration, two hours later, of organisms in liver near attachment to gallbladder.



Fig. 30.—Experimental hepatitis in another rabbit after portal vein injection with streptococci; twelve hours later organisms found in liver near its attachment to the gallbladder.

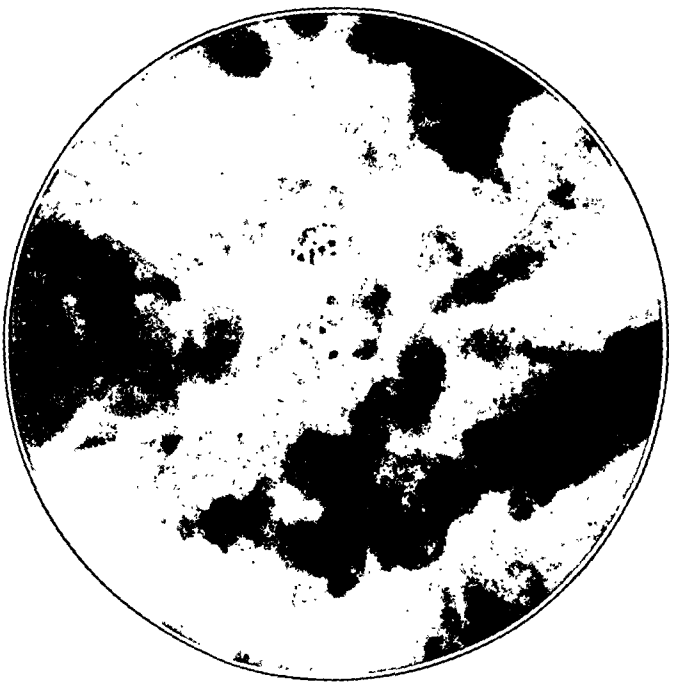

Fig. 31.—Experimental cholecystitis in rabbit; injection of portal vein after ligation of cystic duct and cystic vessels; two hours later organisms found in wall of gallbladder.



Fig. 32.—Experimental cholecystitis in another rabbit; organisms demonstrated in wall twelve hours after portal vein injection.

therefore, were in the rabbits which were killed one and two hours, respectively, after the injections. It seems to us that these findings harmonize well with what would be expected on the assumption that the organisms reached the gallbladder wall from the liver through the lymphatics in the attachment of the gallbladder to the liver, because apparently there was no other route of access available. Even if they came through the very doubtful route of the few small branches of the hepatic artery which pass through the attachment of the gallbladder to the liver, one would have to assume that they had passed through the circuit of the systemic circulation after leaving the liver and had come back through the hepatic artery. Each rabbit was injected with 2 c.c. of a twenty-four hour broth culture of hemolytic streptococci.

PROTOCOLS

EXPERIMENT 1.—Five c. c. of a twenty-four hour broth culture of *Staphylococcus aureus* was injected into the portal vein of Dog 1. The dog was killed six days after the injection.

Necropsy Findings.—Liver: It was somewhat swollen, a grayish-blue, and the edge was rounded. Microscopic: There was extensive diffuse hepatitis, but the most marked infiltration of polymorphonuclears was in the interlobular sheaths.

Gallbladder: It was bound to the liver by adhesions. Microscopic: There was marked inflammation, with polymorphonuclears scattered throughout the wall. The mucosa was also involved, but the epithelium was practically intact.

Common Duct: Acute inflammation was marked. The entire wall was infiltrated with polymorphonuclears and marked vascular dilatation.

Pancreas: There was rather extensive infiltration of the trabeculae of connective tissue with polymorphonuclear leukocytes and a few red cells. There was no parenchymatous necrosis, but acute interstitial pancreatitis existed.

EXPERIMENT 2.—Four c. c. of *Staphylococcus aureus* and four days later 6 c. c. of *Staphylococcus aureus* was injected into Dog 2. The dog was killed three days after second injection.

Necropsy Findings.—Liver: It was dark and edematous. Microscopic: There were marked fatty changes, especially in the center of the lobules. There was moderate infiltration of the periportal tissues with leukocytes, mostly polymorphonuclears, extending up into parenchyma.

Gallbladder: It was pale and adherent to the liver. Microscopic: There was extensive acute inflammation, with marked infiltration of the wall with polymorphonuclears, most pronounced in the outer layers, and marked vascular dilatation. The epithelium was practically normal. Staphylococcus was demonstrated in the walls.

Pancreas: There was marked polymorphonuclear infiltration of the connective trabeculae, and acute interstitial pancreatitis.

EXPERIMENT 3.—Five c. c. of *Staphylococcus aureus* and three days later a second injection of 2 c. c. of hemolytic streptococci were injected in Dog 3, which was killed five days after the second injection.

Necropsy Findings.—Liver: There were several scattered abscesses. Microscopic: There were moderate fatty changes, and very extensive infiltration of polymorphonuclear leukocytes throughout the whole liver but evidently begin-

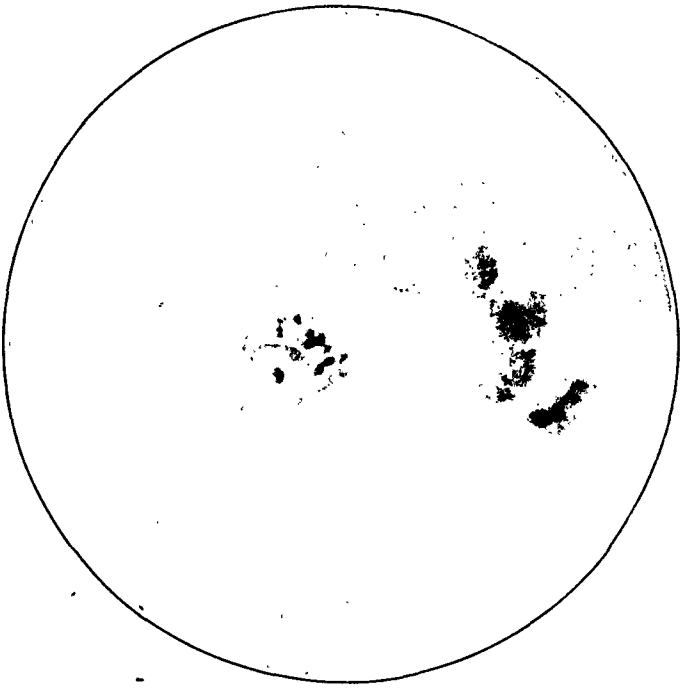

Fig. 33.—Experimental pancreatitis in rabbit; demonstration of organisms in pancreas twelve hours after injection of portal vein.

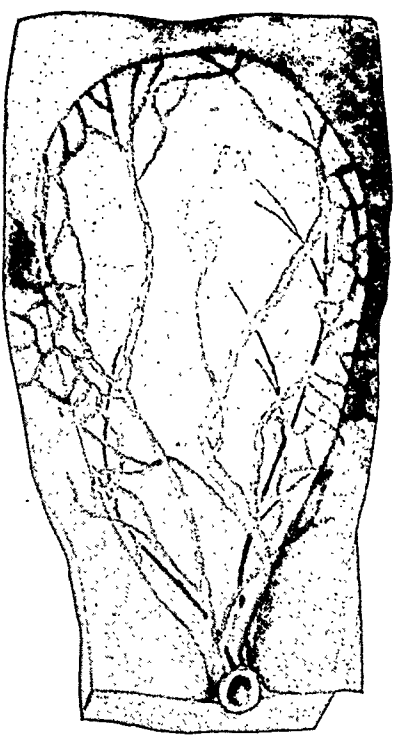

Fig. 34.—Anastomosis between lymphatics of gallbladder and liver (taken from Sudler). The extensive communication between the lymphatics of the liver and gallbladder is seen particularly at the sides of the gallbladder.

ning at the periphery of each lobule. In places there were marked accumulations of polymorphonuclear leukocytes and some mononuclear cells around the interlobular veins. There was very marked infiltration of polymorphonuclear cells beneath the liver capsule.

Gallbladder: It was adherent to the liver. The wall was gray. Microscopic: There was moderate infiltration of the wall with polymorphonuclear leukocytes and round cells, especially at the site of attachment between the liver and gallbladder.

Common Duct: The wall was extensively infiltrated with leukocytes. The mucosa was ulcerated.

Pancreas: There was polymorphonuclear infiltration into the trabeculae (moderate).

EXPERIMENT 4.—Five c. c. of *Staphylococcus aureus* and three days later a second injection of 2 c. c. of hemolytic streptococcus were injected into Dog 4, which was killed two days after second injection.

Necropsy Findings.—Liver: There was no gross change. Microscopic: There was diffuse hepatitis but again it was more marked at the peripheries of the lobules and in the interlobular tissues.

Gallbladder: It was adherent to the liver. The wall was grayish-pink. Microscopic: There was rather marked leukocytic infiltration of the wall, especially in the outer layers and more particularly in the aspect of the gallbladder away from the liver (that part covered by peritoneum). This is where most of the lymphatics are (Poirier and Charpy). Mucosa was not particularly affected.

Pancreas: The same type of lesion as already described under earlier experiments was found here.

Dogs 5, 6, and 7 showed lesions essentially similar to those already described. Dog 5 received 3 c. c. of hemolytic streptococcus three days after an initial injection of 5 c.c. of staphylococcus. In Dogs 6 and 7 there were fibrinous adhesions between the gallbladder and the liver.

SUMMARY

In many cases, probably in a majority, cholecystitis represents a direct extension to the wall of the gallbladder from a liver already inflamed. The hepatitis usually begins and is most marked in the interlobular, or periportal, tissues; and it is apparently due to infection brought to the liver by the portal vein, and, more rarely perhaps, by the hepatic artery. A pericholangitis then occurs, and because of the intimate anastomosis between the lymphatics of the intrahepatic and extrahepatic biliary systems a direct extension into the wall of the gallbladder takes place as well as into the common duct and the pancreas. From the antecedent hepatitis, therefore, a cholecystitis, choledochitis and pancreatitis can be understood to occur if in the consideration of inflammations in this locality we apply the well known fact concerning inflammation in general, namely, that it extends by way of the lymphatics. We believe that the ideas expressed in this article explain more readily than any others heretofore offered the frequent and well recognized association of biliary tract infections with

lesions of the portal system (appendicitis, peptic ulcer, typhoid fever, suppurating hemorrhoids, etc.). It has been shown also that hepatitis may follow the experimental production of cholecystitis by direct inoculation of organisms into the gallbladder. This possibility suggests that, frequently perhaps, a vicious circle between the gallbladder and liver is established whereby each may reinfect the other; and it forcibly emphasizes the desirability of cholecystectomy rather than cholecystostomy because by this means the vicious circle can most readily be broken. The ideas here expressed also furnish added evidence of the necessity of treating, in addition to the gallbladder, any coexisting lesions of the portal system.

While the opinion is expressed here that many, and perhaps the majority of, cases of cholecystitis represent a lymphatic spread from the liver, we recognize also that some are doubtless hematogenous in origin, some perhaps are contact infections from bacteria carried down in the bile and a few perhaps may have originated in an ascending infection of the common duct through its lymphatics or have been due to a chance contact of a gallbladder with an inflamed contiguous organ.

NOTE.—Since writing this article we have seen an article by George P. Muller on the "Pathology of Cholecystitis" (Brooklyn M. J. 19:11, 1905) in which he suggested in 1904 the lymphatic origin of cholecystitis. He states, "It is reasonable, therefore, to conclude that infection from the portal vein may reach the gallbladder through the superficial collecting lymphatics as well as from the bile." He apparently considers this rather a rare occurrence, however, as he states:

> Clinically, attention has been called by Ochsner and others to the association of gallstones and appendicitis, but in the rather extensive series of gallbladder operations performed by Dr. Deaver, we have found but one case in which the bile infection might be directly traceable to a diseased appendix, while upon the other hand in several thousand operations upon the appendix the connection is quite as limited.

CLASSIFICATION AND MECHANISM OF FRACTURES OF THE LEG BONES INVOLVING THE ANKLE

BASED ON A STUDY OF THREE HUNDRED CASES FROM THE EPISCOPAL HOSPITAL *

ASTLEY P. C. ASHHURST, M.D., AND RALPH S. BROMER, M.D.
PHILADELPHIA

ANATOMIC AND SURGICAL STUDY

By Dr. Ashhurst

Pott, Dupuytren, Cooper, Maisonneuve, Tillaux, Hönigschmied, Stimson, Destot, Chaput, Quénu—and shall I not add Scudder, Cotton, Roberts and Speed? What can any one say more, at this late day? And yet the fact remains that there is no entirely satisfactory classification of ankle fractures in existence, and that many points of the mechanism of their production still are in dispute. I say there is no entirely satisfactory classification of these fractures in existence, because that which is the best, being the most scientific and complete, namely that of Quénu, is less a classification than a catalog; and because his strict adherence to an anatomopathologic classification, and his stern rejection of the historical pathogenetic classification, compel him to place side by side lesions in no sense related, except that the fracture lines happen to be similar, and to separate widely other lesions which, though presenting very dissimilar lines of fracture, nevertheless represent only different degrees or stages, or merely variants, of one and the same lesion.

It is perhaps unnecessary to argue the desirability of classification; for without classification, the relation of one lesion to another can be neither remembered nor understood in any department of knowledge; and comprehension is a prerequisite for intelligent memory and for rational diagnosis and treatment.

HISTORICAL

Si chirurgien expérimenté que vous soyez, ne sautez pas ces premières pages. Elles sont indispensables, mais fatigantes à lire: mieux vaut remettre à un autre jour cette besogne ardue que de l'entreprendre mal disposé.—Farabeuf.

Pott [1] (1769) described a fracture which doesn't exist, and Dupuytren [2] (1819) commended him for his acute observation and fidelity

* Read before the American Surgical Association, June 14, 1921.

1. Pott: Some Few General Remarks on Fractures and Dislocations, London, 1769, p. 57.
2. Dupuytren: Ann. méd.-chir. d. hôp. et hosp. civ. de Paris, 1819, p. 1.

to nature. Cooper [3] (1822), more sensible than either, merely recounted what he had seen, avoided speculation about what he had not seen, and was silent on subjects about which he had no knowledge. Maisonneuve [4] (1840) and Tillaux [5] (1872) studied the mechanism by experiments on the cadaver, and though they were both correct, they came to different conclusions; and Tillaux thought his work had entirely invalidated that of Maisonneuve. Hönigschmied's [6] (1877) experiments on cavaders (125 in all) may be said to have carried this means of investigation to its limit; and though subsequent students, including myself, have repeated such experiments, it is evident that this method of investigation has many limitations, as it is impossible to reproduce in the cadaver the falls which living patients suffer and the muscular tension to which their limbs are constantly subjected.

Stimson's [7] study, in 1892, was the last one of importance before the advent of the roentgen ray; and it was Destot [8] (1911) who first of all published extensive observations of ankle fractures illustrated by, and based on, roentgenographic studies. It is strange that no English writer since Cooper has made a special study of fractures at the ankle, and that with the exception of Stimson, already mentioned, no American surgeon has made a particular study of the subject, though Scudder, Cotton, Roberts and Kelly, and Speed have discussed it at greater or less length in their textbooks on fractures. It is evident, however, to any attentive student of the subject that most of the recent writers, if not, indeed, all, demonstrate by their statements that they have not themselves read, or at any rate have not read with understanding, the works of their predecessors—especially of Dupuytren, Cooper, Maisonneuve and Tillaux. Most surgeons think they know what they mean by a "Pott's fracture," but as I said before, there is little use in knowing much, or anything, about a type of fracture which does not exist.

What is Pott's fracture? Let Mr. Percivall Pott tell in his own words (1769).[9]

---

3. Cooper: Treatise on Dislocations and Fractures of the Joints, London, 1822.

4. Maisonneuve: Arch. gén. de méd. **1**:165, 433, 1840.

5. Tillaux, cited by Gosselin: Bull. de l'Acad. de méd., Paris, Series 2 **1**: 817, 1872.

6. Hönigschmied: Deutsch. Ztschr. f. Chir. **8**:239, 1877.

7. Stimson: New York M. J. **55**:701, 1892.

8. Destot: Traumatismes du pied et rayons-x, Paris, 1911.

9. It should be borne in mind that Pott is discussing the importance of treating fractures of the leg bones in the flexed position (the limb resting on its outer surface with the knee bent), and hence that he speaks of fractures of the fibula only incidentally.

"The limb most commonly preserves its figure and length . . . if the fibula only be broken, in all that part of it which is superior to letter *A* in the annexed figure" (Fig. 1), "or in any part of it between its upper extremity, and within two or three inches of its lower one. . . . I have already said . . . that the support of the body and the due and proper use . . . of the joint of the ancle depend almost entirely on the perpendicular bearing of the tibia upon the astragalus, and on its firm connection with the fibula. If either of these be perverted or prevented, so that the former bone is forced from its just and perpendicular position on the astragalus, or if it be separated by violence from its connection with the latter, the joint of the ancle will suffer a partial dislo-

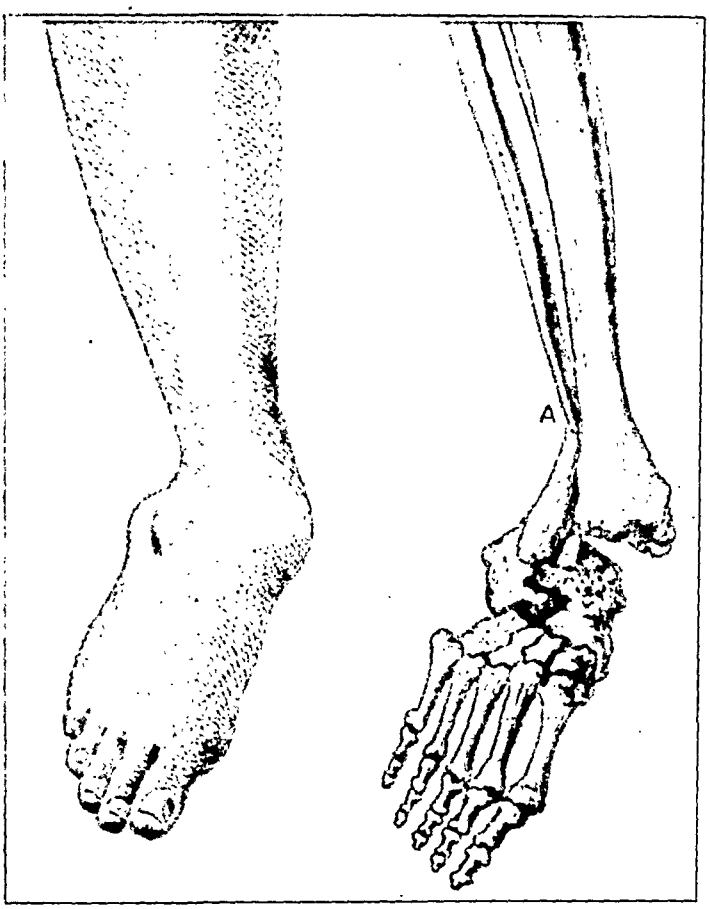

Fig. 1.—Illustration from Pott's work, "Some Few General Remarks on Fractures and Dislocations," London, 1769, facing p. 69.

cation internally; which partial dislocation cannot happen without not only a considerable extension or perhaps laceration of the bursal ligament of the joint, which is lax and weak, but a laceration of those strong tendinous ligaments which connect the lower end of the tibia with the astragalus and os calcis, and which constitute in great measure the ligamentous strength of the joint of the ancle.

"This is the case when, by leaping or jumping, the fibula breaks in the weak part already mentioned, that is, within 2 or 3 inches of its lower extremity. When this happens, the inferior fractured end of the fibula falls inward, toward

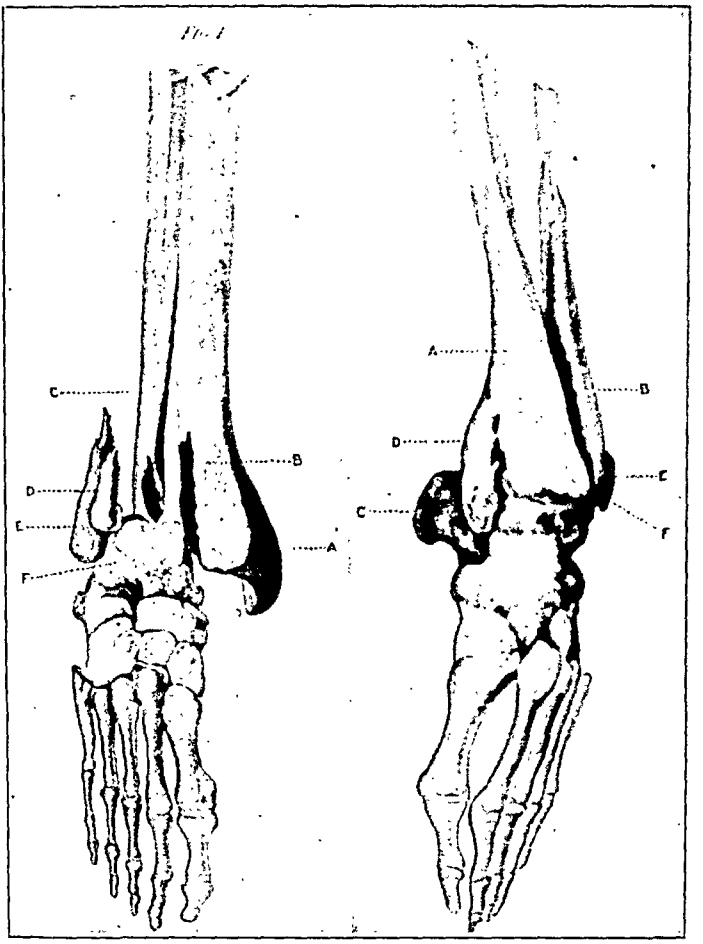

Fig. 2.—Illustrations from Cooper's "Treatise on Dislocations and Fractures of the Joints," London, 1822, Plate XVI, Figs. 1 and 2. "Fig. 1 shows the dislocation of the tibia inwards at the ankle-joint: *A*, the malleolus internus of the tibia thrown on the inner side of the astragalus; *B*, a portion of the tibia split off; *C*, fibula broken; *D*, the broken portion of the tibia adhering by ligament to the fibula; *E*, the malleolus externus of the fibula, with the broken portion of the tibia adhering to it, and *F*, astragalus thrown outwards. Fig. 2 shows the dislocation of the tibia outwards, at the ankle-joint: *A*, the tibia; *B*, the fibula; *C*, the os calcis; *D*, fracture of the tibia at the malleolus internus, which has become reunited; *E*, extremity of the fibula broken, and, *F*, tibia thrown on the outer side of the articulatory surface of the astragalus, to which it is anchylosed."

altered, that instead of performing their appointed actions, they all contribute to the distortion of the foot, and that by turning it outward and upward." (Note that there is not a word of posterior displacement, and that this is not shown in the plate, here reproduced as Figure 1.)

This description, and the accompanying illustration, call for several remarks. It is to be noted, first, that Pott's fracture, as described and pictured by himself, is a primary, nearly transverse, fracture of the fibula, attended by a subsequently produced "partial dislocation" of the

Fig. 4.—Transverse section of leg through inferior tibiofibular joint, showing fibula lodged in its groove formed by the anterior and posterior tubercles of the tibia. Note the obliquity of the intermalleolar axis, forming an angle of 30 degrees with the axis of motion of the ankle joint, which is nearly transverse. Note that the anterior tubercle projects laterally much farther than the posterior, so that in anteroposterior roentgenograms its shadow much overlaps that of the fibula. (From a preparation in the laboratory of operative surgery, University of Pennsylvania.)

ankle joint internally. Second, the fracture of the fibula occurs at, or below, the point marked *A* in the illustration ("within 2 or 3 inches of its lower extremity"); and the upper end of the lower fragment is described as falling in against the tibia, while the external malleolus is turned outward. Third, there then is supposed to occur rupture of

the ligaments below the internal malleolus, with a partial dislocation of the tibia inward, off the trochlea of the astragalus, as the latter bone turns outward, around a more or less anteroposterior axis. Now, such a fracture of the fibula does not occur as a type, as may be readily verified by the examination of any series of roentgenograms or post-mortem specimens; and if it did occur, it would be impossible for the upper end of the lower fragment to fall in against the tibia, for the

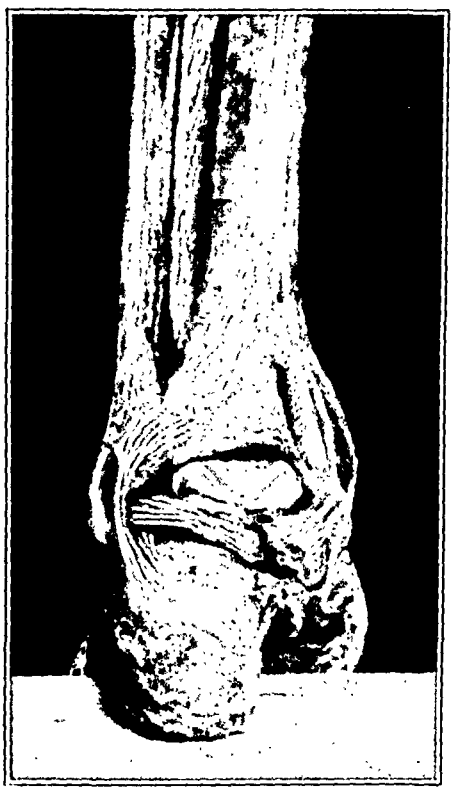

Fig. 5.—Posterior view of the ankle joint, all structures removed except the bandlike ligaments. Note the interosseous membrane, its fibers passing downward from the tibia to the fibula, the similarly directed fibers of the posterior inferior tibiofibular ligament; the middle band of the external lateral (fibulo-calcanean) ligament; the posterior band of the external lateral ligament (fibulo-astragalar ligament) attached to the lateral tubercle of the astragalus; the posterior fibers of the internal lateral ligament, and the posterior surface of the internal malleolus grooved for the tendon of the tibialis posticus. (From a preparation in the laboratory of operative surgery, University of Pennsylvania.)

reason that the fibula is already closely applied to the tibia at the point described. There is barely room to insert the blade of a scalpel between the bones at a point 3 inches (7.5 cm.), or less, above the tip of the fibula.

It was the particular merit of Dupuytren to systematize the teaching of various pioneers, such as Pott (1769), Bazille [10] (1771), Bromfeild [11] (1773) and Pouteau [12] (1783), who had recognized, as fractures, lesions which had been regarded by former generations as dislocations; and it is to Dupuytren's memoir on "The Fracture of the Lower End of the Fibula"[13] that surgery is principally indebted for its understanding of all these ankle fractures. It is true that Gosselin (1872) reproached Dupuytren with having propounded his theories of mechanism merely by means of his reasoning, and not on a basis of clinical observations or cadaveric experiments (though Dupuytren made a number of the latter, and presented records of 207 patients with ankle fractures). But there is much justification for Dupuytren's [14] statement that the mechanism detailed by patients cannot be relied on, since it is well known that in dislocations of the shoulder, for instance, they all will say the injury resulted from a fall on the point of the shoulder (because that is where they feel the pain), whereas the state of their elbow or hand proves quite the contrary. Similarly, I have known a patient with an ankle fracture badly united in abduction (fibular flexion) to assert that it was produced by adduction (tibial flexion), because her heel was prominent beneath the internal malleolus just after the accident; not realizing that the heel had been brought into that position by outward displacement of the point of the foot, the astragalus turning around the long axis of the leg.

Now it is to be noted that Dupuytren, who commended Pott for his accurate delineation of the typical fracture of the lower end of the fibula, was evidently of the belief that the typical fracture which he himself was describing was the same as that of Pott; and that this is still the opinion of the French is manifest from a footnote of

---

10. Bazille: Mém. sur les sujets proposés pour le prix de l'Acad. Roy. de Chir., Paris **4**:563, 1778.

11. Bromfeild: Chirurgical Observations and Cases, London **2**:78, 1773.

12. Pouteau: Oeuvres posthumes, Paris **2**:267, 1783.

13. This memoir was said by Nélaton (Eléments de path. chir., Paris **1**:810, 1844) to have been read by Dupuytren in 1813 before the Académie de sciences. However, I have searched the "Procès-verbaux des séances de l'Académie des sciences" (Paris **5**:1812-1815) and find no reference to such an event; and Quénu (Rev. de Chir. **45**:5 (Footnote 2) 1912) states that he has had the original records of the Academy searched page by page, without finding any trace of Dupuytren's Memoir; and says that "until further information" he will consider as "mémoire princeps" the appearance of the essay in the "Annuaire medico-chirurgicale des hôpitaux et hospices civiles de Paris," 1819, p. 1. The essay is most easily accessible where first reprinted, in the second edition of Dupuytren's "Leçons orales" (Paris **1**:275, 1839).

14. Dupuytren: Leçons orales de clinique chir., Ed. 2, Paris **1**:328, 1839.

Quénu,[15] in which he says that the French mean by Dupuytren's fracture precisely what the English mean by Pott's. So that it is somewhat confusing to have J. Hutchinson, Jr.,[16] and some recent writers name and illustrate as Dupuytren's fracture a lesion which Dupuytren [17] encountered only once in more than 200 cases, and which consisted in a fracture of the fibula, rupture of the tibiofibular ligaments, and displacement upward of the astragalus along the fibular side of the tibia. As it is a fact that the fracture at the ankle most

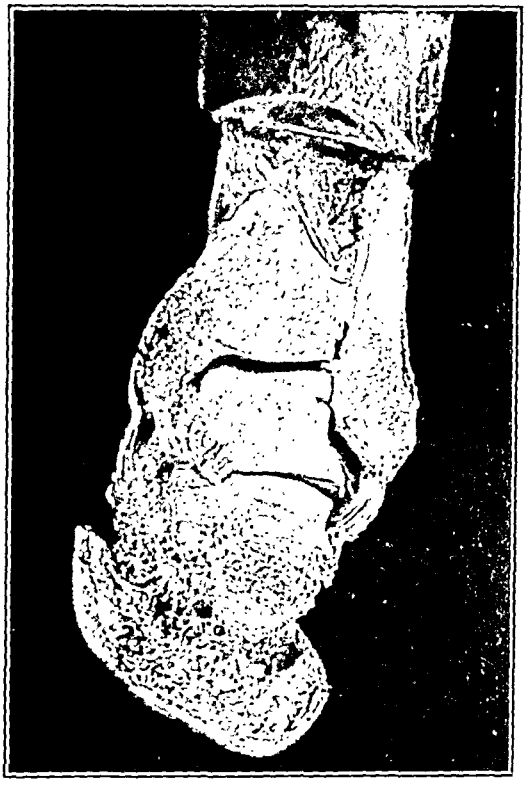

Fig. 6.—Frontal section of the ankle joint. Adduction causes tension on external lateral ligament and if forced will tear off the external malleolus.

often seen, and therefore the most typical fracture, is that first described accurately by Maisonneuve (1840),[18] it is safe to assume that both

15. Quénu: Rev. de chir. **46**:367 (Footnote 2) 1912.

16. Hutchinson: Tr. Path. Soc., London **39**:238, 1887-1888.

17. Dupuytren: Footnote 14, p. 368.

18. Though, unfortunately, it is not known by his name, which is attached to a fracture produced experimentally by him on the cadaver, but which he never saw clinically. The most frequent and most typical fracture the French now call the "low Dupuytren" to distinguish it from the true Dupuytren or Pott fracture, which they name "Dupuytren type."

Pott's and Dupuytren's descriptions applied to this fracture and not to the rather hypothetic type they thought they were describing.

However, there is a typical, though rare, fracture at the ankle which corresponds closely enough to the original illustration of Pott to make it worthy of being called by his name; it is a typical "flexion fracture" (Biegungsbruch) of the fibula, usually 8 cm. (3¼ inches) or *higher* above the tip of the external malleous, accompanied by fracture of the internal malleolus and almost invariably by rupture of the inferior



Fig. 7.—Frontal section of the ankle joint. Abduction causes tension on internal lateral ligament and will rupture this or fracture the internal malleolus before outward pressure on the external malleolus will fracture the latter or cause diastasis between tibia and fibula. (This specimen and that shown in Figure 6 are from a preparation in the laboratory of operative surgery, University of Pennsylvania.)

tibiofibular ligaments, permitting a diastasis between tibia and fibula. It is such a fracture as is illustrated in Fgure 26; and may well be called Pott's fracture, even though Pott in his own description placed the seat of the fibular fracture too low, and ignored the fracture of the internal malleolus and the tibiofibular diastasis.

Cooper [3] (1822) did not get away from the idea of the paramount importance of the dislocation of the tibia in these lesions (nor, it may

be remarked, did Malgaigne, Hamilton, Treves, or Stimson, many years later); and he described the fractures as mere incidents. But any modern surgeon will find it difficult to bring forth as extensive a list of severe ankle lesions as that recorded by Cooper, though he can easily excel Cooper in the number of lesions which (owing to the absence of deformity) can be certainly recognized only with the aid of the roentgen ray.

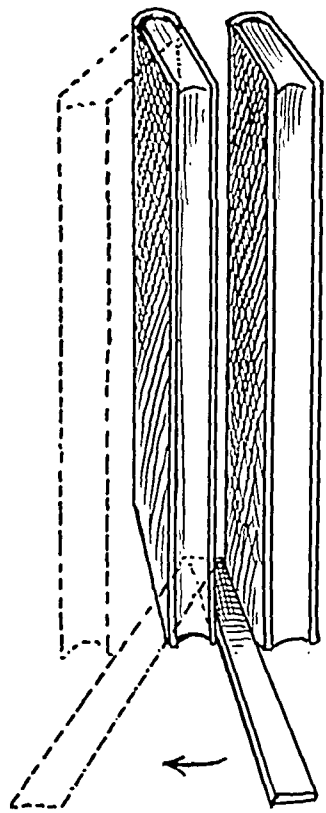

Fig. 8.—An illustration of Maisonneuve's explanation of fracture of the external malleolus by outward rotation of the foot around the axis of the leg. The books represent the malleoli and the ruler represents the foot. See page 100.

Cooper describes succinctly, but accurately, the following main groups of lesions; and scarcely one additional type has been discovered since, even with the aid of roentgenography:

1. *Simple Dislocation of the Tibia Inward.*—In this case there is a fracture of the fibula, two inches above its tip, carrying with it an attached fragment of the tibia;[19] the lower end of the upper fragment of the fibula rests on top of the

19. This is the "intermediate fragment" known to the French as the "third fragment of Tillaux," who produced it frequently in his cadaveric experiments.

astragalus,[20] and the tibia with the internal malleolus intact descends on the median surface of the astragalus. (This is illustrated in Figure 1 of Plate 16 of Cooper's monograph, first edition, 1822, and is reproduced here as Figure 2. The figure was copied by Vidal de Cassis[21] in his second edition [1846] as Figure 53 and the lesion was for many years known in France by his name; until Quénu recently called attention to the fact, quite clearly stated by Vidal, that the illustration was copied from Cooper.) This, says Cooper, is the most frequent of the dislocations of the ankle. It corresponds probably to the form now known to the French as the "low Dupuytren" fracture, though in the latter type, which is very frequent, there is very seldom any intermediate fragment detached from the tibia.



Fig. 9.—Oblique fracture of the fibula through the inferior tibiofibular joint, produced by an osteotome: in the first figure the foot is in the anatomic position; in the second it has been rotated outward around the axis of the leg, which is the only motion that will cause separation of the fragments. See page 101.

2. *Simple Dislocation of the Tibia Forward.*—In this case there is a fracture of the fibula, three inches above its tip; the internal lateral ligament is partly lacerated; the tibia and upper fragment of the fibula advance forward, and the tibia rests on the upper surface of the scaphoid and internal cuneiform. In

20. Richet (Unión méd. **20**:142, 1875) described such a case in which the astragalus was penetrated by the upper fragment of the fibula. Roentgenograms in anteroposterior view often show such an appearance, but the lateral views I have seen have always demonstrated that the fibula was behind, or very rarely in front of, the astragalus. Richet's lesion was demonstrated at necropsy.

21. Vidal de Cassis: Traité de pathologie externe, Ed. 2, Paris **2**:394, 1846.

partial dislocation of the tibia forward, the articular surface of the tibia is divided in two: the anterior part rests on the scaphoid and the posterior on the astragalus. The fracture of the fibula (as shown in Plate 17, Figs. 1 and 2, of Cooper's monograph, reproduced here as Figure 3) runs obliquely up and back, through the inferior tibiofibular joint. Thus there is here accurately described the posterior marginal fragment of the tibia, which many recent writers think they were themselves the first to discover after the introduction of roentgenography (Destot, Chaput, Cotton, Sear, etc.).

3. *Simple Dislocation of the Tibia Outward.*—This, says Cooper, is the most dangerous of the three, for it is produced by greater violence, etc. The internal

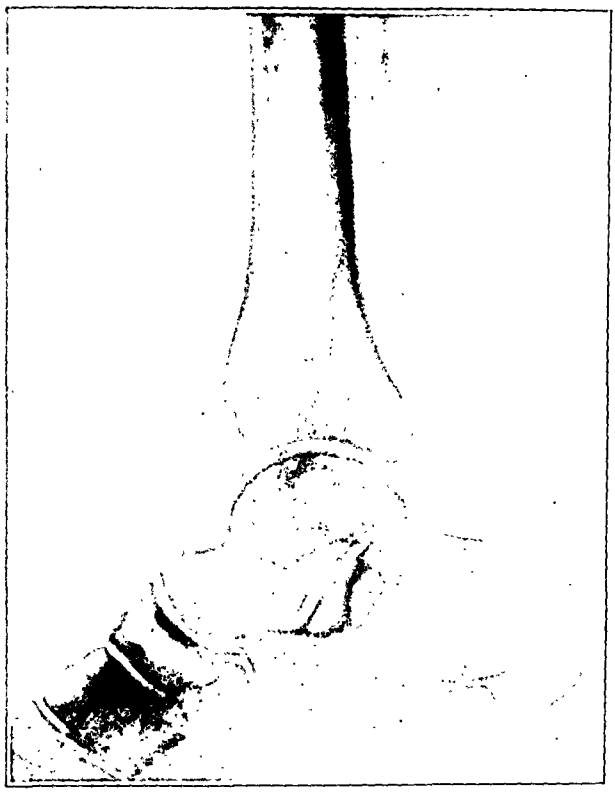

Fig. 10.—Mixed oblique fracture of the lower end of the fibula: the first lesion resulting from external rotation (A, I); occurs as isolated lesion in 25 per cent. of all cases of fracture of the ankle; as combined lesion, in 61 per cent. Usually invisible in anteroposterior views.

malleolus is obliquely fractured and separated from the shaft of the bone; the fractured portion sometimes consists only of the malleolus; at other times, the fracture passes obliquely through the articular surface of the tibia, which is thrown forward and outward on the astragalus before the external malleolus. The astragalus is sometimes fractured, and the lower extremity of the fibula is broken into several splinters. The internal and external lateral ligaments are usually intact; but if the fibula is not broken, the external lateral ligaments are ruptured. (Note that there is here described the "fracture by adduction" with a splitting off of a greater or less portion of the medial surface of the tibia—illustrated in Figure 2, from Cooper—a lesion which Tillaux thought had not before his time been observed by any surgeon).

Under the heading "Fractures of the Tibia and Fibula Near the Ankle Joint" (p. 353), Cooper describes a fracture of the fibula from two to three inches above the ankle joint (that is, not at a point from two to three inches above the tip of the external malleolus, but at the point where occurs the fracture called by Pott's name), produced by falling laterally while the foot is confined in a deep cleft; and a fracture of the tibia, in which the fracture line runs either obliquely down and in, toward the internal malleolus (i. e, the

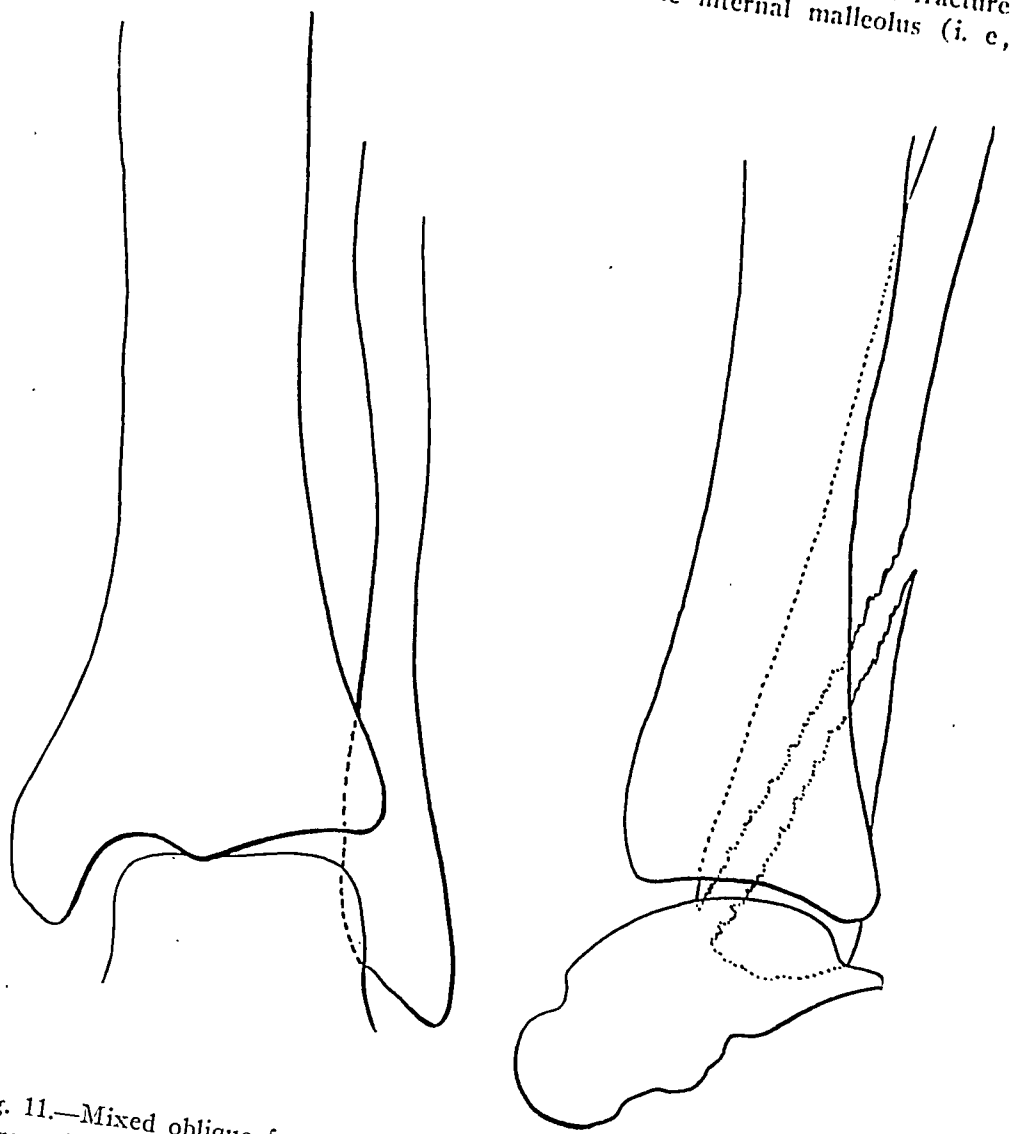

Fig. 11.—Mixed oblique fracture of the fibula, with great obliquity. In these fractures, the obliquity may be great or slight; but the line of fracture is always higher on the posterior than on the anterior border of the fibula, and in 84 per cent. of the cases, the anterior end of the fracture line is between the tip of the malleolus below and the level of the articular surface of the tibia above. In 8 per cent. of the cases, the anterior end of the fracture line passes through the fibula at the level of the anterior tubercle of the tibia, and in 8 per cent. its anterior end is above this level (in which circumstances the tubercle is detached or there is diastasis). All tracings here reproduced were made directly from the roentgenograms.

ordinary spiral fracture of the shaft low down) or obliquely from 1 or 2 inches above the internal malleolus down and out into the ankle joint (i. e., the ordinary splitting fracture of the median part of the articular surface, usually dependent on a primary fracture of the fibula, and forming a less advanced degree of the fracture by adduction already described by Cooper as an outward dislocation of the tibia).

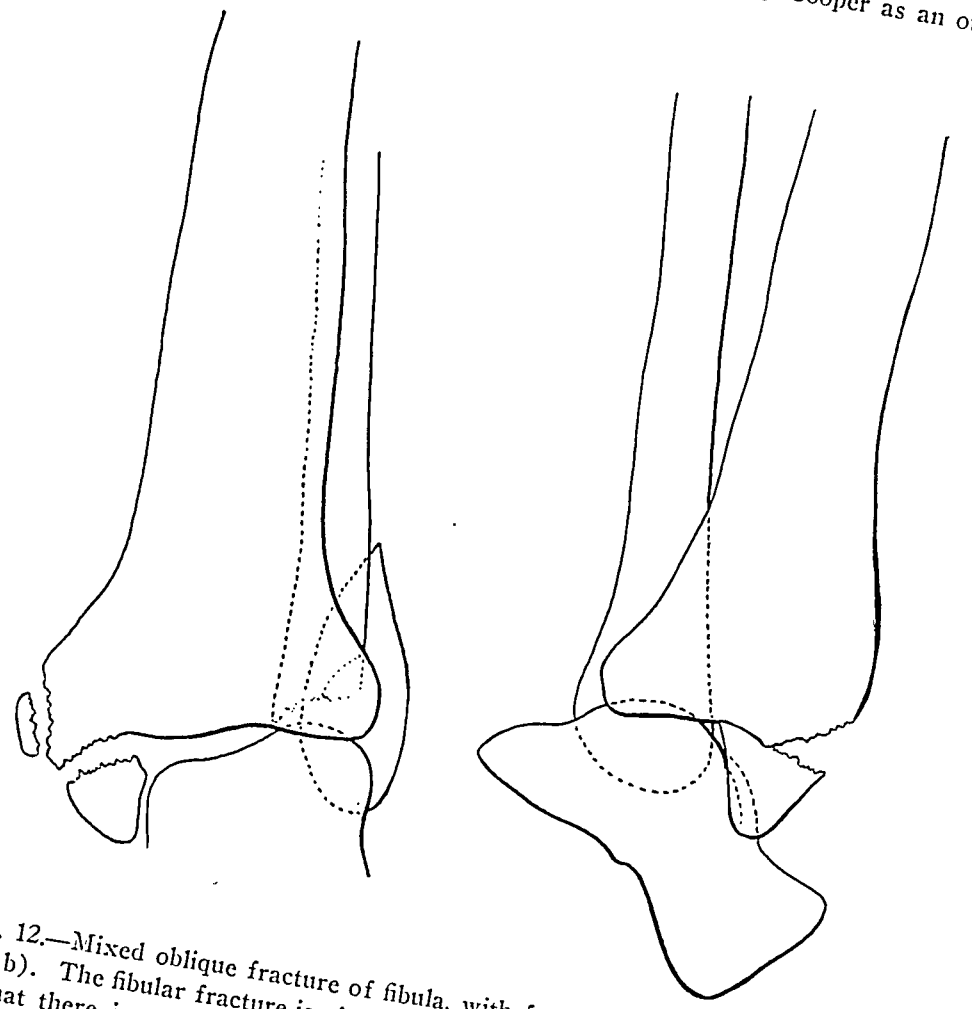

Fig. 12.—Mixed oblique fracture of fibula, with fracture of internal malleolus (A, II, b). The fibular fracture is visible only in the anteroposterior view (rare). Note that there is considerable lateral displacement of the astragalus, but that the posterior displacement is only apparent, not real, being due to the external rotation of the foot.

After Cooper, Maisonneuve [4] (1840). In a most remarkable essay, which has been ignored by most subsequent writers, Maisonneuve threw more light on the subject of ankle fractures than has any one since.

Up to that time, as he says, two theories prevailed to explain the mechanism of fractures of the lower end of the fibula: (1) by adduction, by which means the tip of the external malleolus was torn off; this was thought by Dupuytren

to be the most frequent variety,[22] and (2) by abduction, when, from pressure upward and laterally by the astragalus on the external malleolus, the latter was forced outward until the fibula broke at its weakest point, namely, entirely above the malleolus, that is, in the region described by Pott; this fracture being usually accompanied by a secondarily produced fracture of the internal malleolus or rupture of the internal lateral ligament. The second variety was thought by everybody, except Dupuytren, to be the most frequent.

Now Maisonneuve proposed another mechanism, which he believed explained the production of the most common type of fracture: this was simple deviation of the point of the foot outward, that is, external rotation of the foot in the

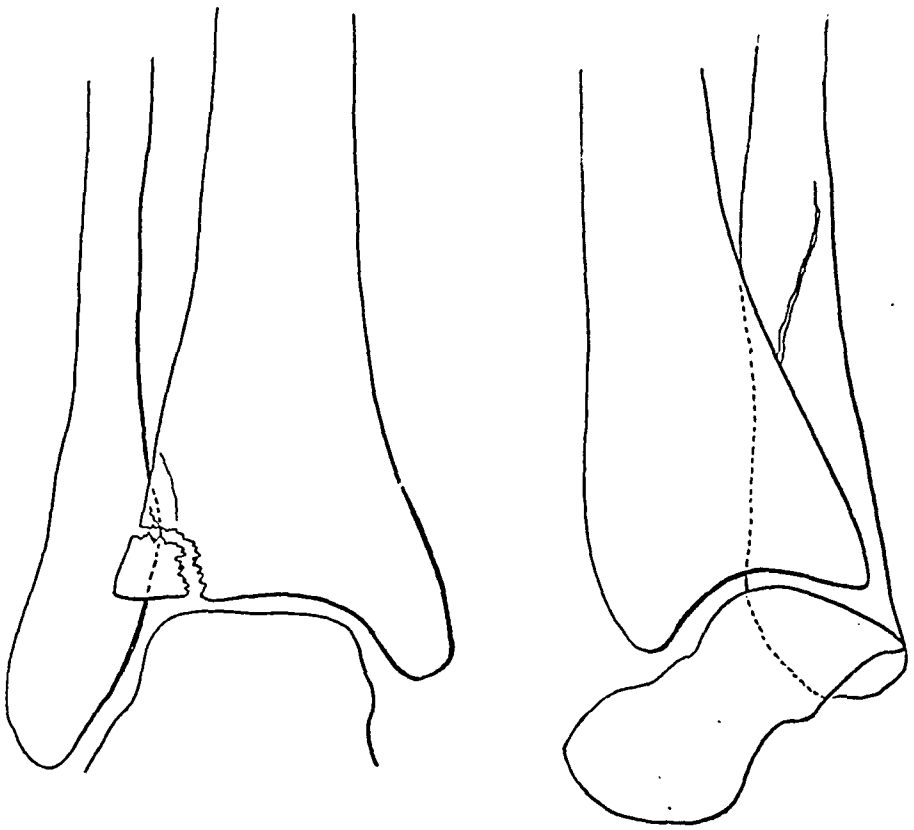

Fig. 13.—Mixed oblique (incomplete) fracture of fibula, complicated by, and subsequent to, avulsion of the anterior tubercle of tibia.

22. Dupuytren contended that the usual fracture which he described (and which he thought corresponded to that shown in Pott's illustration) was produced by a primary tearing off of the external malleolus when the foot turned so that the patient stepped on the outer edge of the sole; and that the rupture of the internal lateral ligament or fracture of the internal malleolus was produced secondarily by the patient's attempts to walk: whereupon, the external malleolus being already broken, the foot was forced into valgus; but he stated that when fracture of the fibula followed a turning outward of the foot, the internal malleolus broke first and the fibula only secondarily (Footnote 14, p. 327).

tibiofibular mortise around a vertical axis. In one recent necropsy, he had found an oblique fracture of the fibula, the line of fracture beginning on the anterior surface of the external malleolus 4 cm. above its tip and extending upward and backward to a point on the posterior surface of the fibula 8 cm. above the tip of the external malleolus. And he found that precisely this fracture was readily produced in the cadaver by the mechanism of outward rotation as above mentioned, whenever the tibiofibular ligaments held firm.

So far as I can ascertain, Maisonneuve was the first, and I might say almost the only, writer up to the present day to appreciate properly

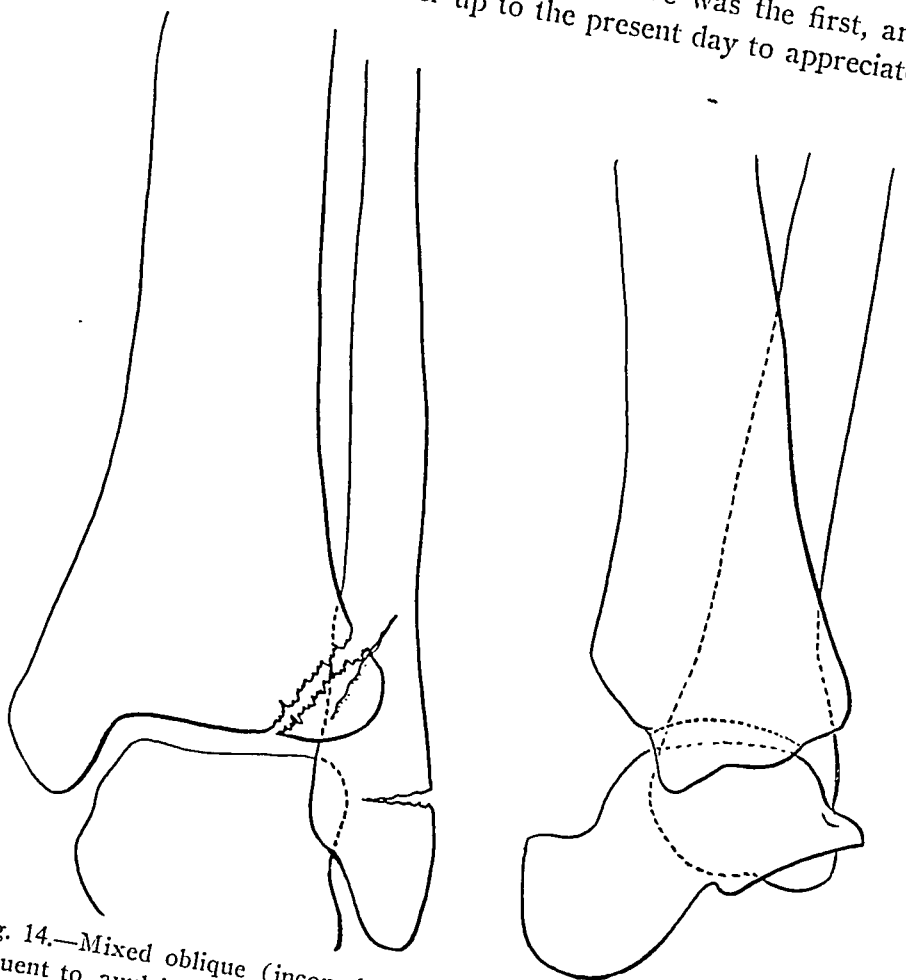

Fig. 14.—Mixed oblique (incomplete) fracture of fibula complicated by, and subsequent to, avulsion of anterior tubercle of tibia.

the importance of the inferior tibiofibular ligaments in the mechanism and classification of ankle fractures; and to recognize the great frequency of the oblique fracture of the fibula. This fracture, he found, was always the first lesion following external rotation of the foot, and occurred without any ligamentous injury. If the external rotation of the foot were continued far enough, the internal lateral ligament would rupture, or often the internal malleolus would be pulled off.

The resulting deformity, he found, was precisely the picture drawn by Dupuytren (*"coup de hache,"* etc.); and all of these phenomena disappeared when the position of the foot was corrected. If the inferior tibiofibular ligaments break, during this external rotation of the foot around the long axis of the leg, there occurs a greater or less diastasis of the inferior tibiofibular joint; and if the movement still continues, the fibula breaks not at the usual site, but in its upper third, or at least in its middle third. It is to this fracture of the fibula in its upper third, produced after diastasis of the inferior tibiofibular joint has occurred,

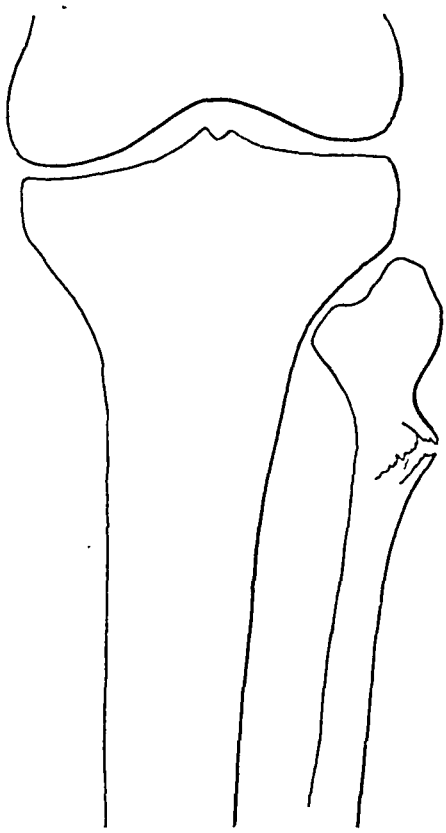

Fig. 15.—Incomplete fracture of fibula below its head (A, I, Variant), apparently from compression in its long axis (see pp. 103 and 107). No bone lesion at ankle. There was a history of a fall down three steps while carrying a load of 100 kilograms on the back. Injury occurred so quickly the patient did not know whether he turned his ankle or struck the side of his leg against the marble steps. Pain was so great that he had to be brought to the hospital by a patrol wagon. Examination showed fracture in the upper third of the left fibula (crepitus and deformity). The ankle was swollen over the external malleolus.

that the name of Maisonneuve's fracture has been attached; though he never encountered such a case clinically.

Maisonneuve's chief contribution was his recognition of the oblique fracture of the lower end of the fibula as the first stage of a lesion

frequently including also a fracture of the internal malleolus or a rupture of the internal lateral ligament; and it is a pity that his name is not applied to this very frequent fracture rather than to one of the utmost rarity. Moreover, he was no doubt correct, as I have previously intimated, in believing that this was the lesion whose clinical signs were described by Dupuytren, and that the latter erroneously thought these

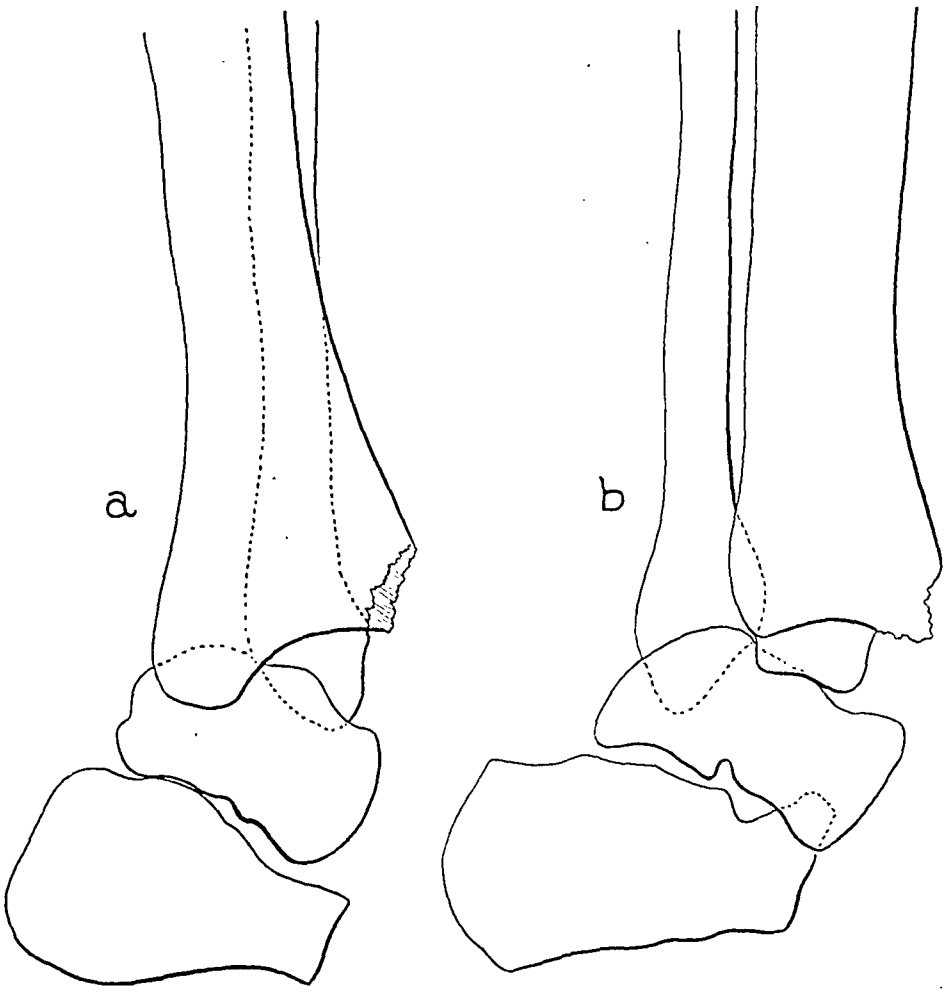

Fig. 16.—Diastasis with displacement of fibula behind tibia. The anterior tubercle of tibia has been torn off and accompanies the fibula, which is not fractured. Diastasis by external rotation (mechanism described by Huguier [49]): (*a*) anteroposterior view, and (*b*) lateral view before reduction. See also Figure 17 (A, I, complication) and page 103.

cases were such as had been depicted by Pott. Maisonneuve's chief, and almost his only, error, as it seems to me, was his failure to appreciate that a lesion did exist, consisting of a fracture well above the inferior tibiofibular joint, associated with fracture of the internal malleolus

or rupture of the internal lateral ligament, and that this type of fracture, though rare, was yet much less rare than a fracture of the fibula in its upper third or even in its middle third.

After Maisonneuve, Tillaux [5] (1872). Tillaux did not distinguish in his cadaveric experiments between abduction (fibular flexion) of the foot and the same movement combined with slight outward rotation (i. e., around the long axis of the leg). Abduction, he found, caused (*a*) rupture of the internal lateral ligament or tearing off of the internal

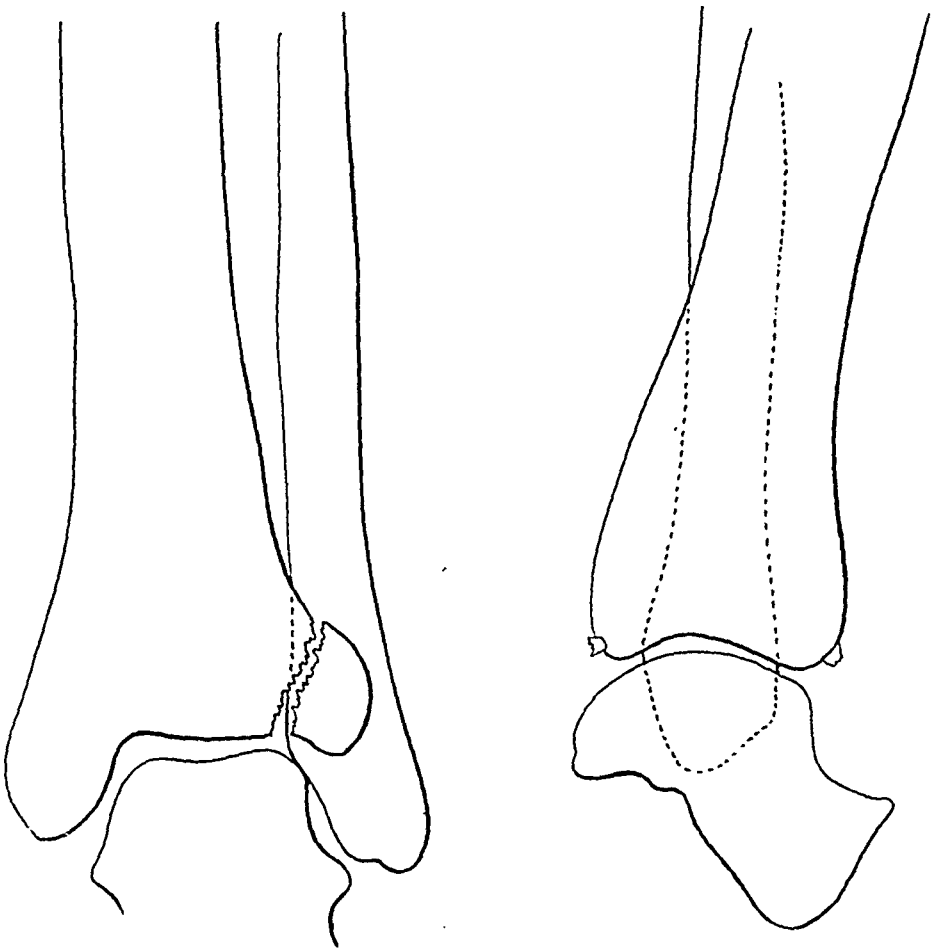

Fig. 17.—Same case as that shown in Figure 16, after reduction. Fracture of anterior tubercle of tibia clearly seen.

malleolus, or (*b*) the same lesions plus fracture of the fibula above the inferior tibiofibular ligaments, or 6 to 7 cm. above its tip; the tibiofibular ligaments may not rupture, but the degree of rupture of these ligaments determined the degree of the displacement; and he found the fibula could not be broken in abduction movements unless the internal malleolus or the internal lateral ligament had been previously broken. He also called particular attention to the great frequency of a fragment

of bone torn off the lateral border of the tibia by the inferior tibiofibular ligaments; this fragment has since been known to the French as the "third fragment of Tillaux" (remember it had been described and illustrated by Cooper and by Vidal de Cassis).[23]

It is thus seen that while Maisonneuve minimized the mechanism of pure abduction, Tillaux magnified it out of all reason; for the fact remains that the vast majority of fractures are not of the type produced experimentally by Tillaux by abduction (and which correspond rather to the original type with which Pott and Dupuytren thought they had to deal), but are of the type produced experimentally by Maisonneuve by external rotation. In his description of the results of adduction (tibial flexion), Tillaux agreed with his predecessors and successors (the results are noted below under the account of Hönigschmeid's experiments); but he also describes a rare result of adduction which consists in a transverse supramalleolar fracture of the tibia sometimes occurring in those cases in which the fibula breaks above the inferior tibiofibular joint instead of below it (Fig. 43). This mechanism, he says, involves great strain on the superior tibiofibular joint until the fibula breaks above its malleolus; and he observed a case in life in which this transverse supramalleolar fracture (of the tibia only) was complicated by a diastasis of the *upper* tibiofibular joint. (In this connection, one of the specimens from the Mütter Museum [72] is of much interest.)

Hönigschmied [6] (1877), as already remarked, made 125 experiments on the cadaver, to determine the mechanism of ankle fractures, and

23. Souligoux (Bull. et mém. Soc. de chir. de Paris **38**:1103, 1912) described two unpublished diagrams made by Tillaux to illustrate this "third fragment:" the anterior view showed the anterior tubercle of the tibia torn off, while the posterior view showed the posterior tubercle torn off. Apparently, then, it was Tillaux's opinion that either tubercle could represent his third fragment. A larger fragment from the inferior lateral margin of the tibia may exist, known to the French as the "intermediate fragment of Verneuil," but it is quite rare. This seems to correspond to what Roberts and Kelly (the advance proof sheets of whose second edition, 1921, Dr. Roberts has very courteously sent me) describe as the "drunkard's fracture." Confusion is added to this matter by the statement of Thaon (Bull. Soc. anat. de Paris **45**:212, 1870), in presenting a necropsy specimen of a posterior marginal fracture, that he had often seen this posterior fragment in experiments made by Tillaux; and by the statements of Demoulin (Bull. et mém. Soc. de chir. de Paris **38**:1103, 1912), of Mauclaire (Bull. et mém. Soc. de chir. de Paris **38**:1141, 1912), and of Viallet (Rev. de chir. **46**: 690, 1912) that the third fragment of Tillaux may easily be mistaken in roentgenograms for a posterior marginal fragment. My own belief is that the third fragment of Tillaux is the anterior tibial tubercle and that the fragment composed of the posterior tubercle and that known as the posterior marginal fragment usually are indistinguishable.

a brief summary of them is given, as it will be necessary to refer to them frequently in the latter portions of this memoir.

1. *Plantar hyperflexion, twenty experiments.* In fourteen cases he got rupture of the internal lateral ligament and anterior fibers of the external lateral ligament; the rupture sometimes occurred from the tarsus, sometimes from the leg bones; sometimes a small fragment of bone was torn loose. In five cases (aged subjects), one or both of the malleoli were broken.

2. *Dorsal hyperflexion, twenty-one experiments,* always with previous division of the tendon of Achilles. In seventeen the internal malleolus was broken, by push of the tarsus against its tip. In two the internal lateral ligament was ruptured. In two the only lesion was in the tarsus.

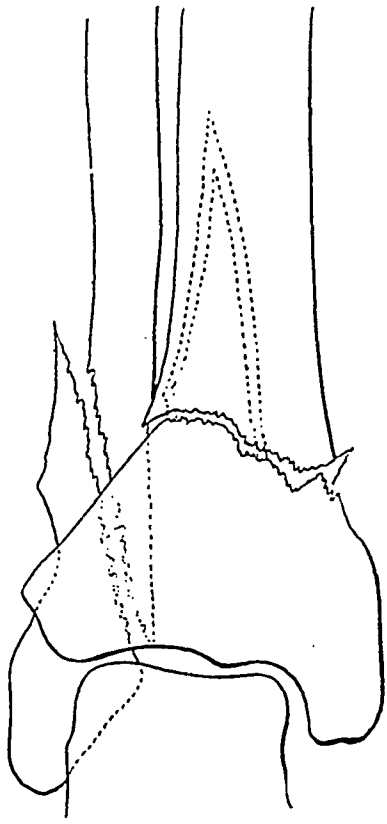

Fig. 18.—Mixed oblique fracture of fibula, internal malleolus represented by whole lower end of tibia (A, III).

3. *Tibial flexion (adduction or supination), seventeen experiments.* In all the external malleolus (five) or external lateral ligament (twelve) was broken. He never got fracture of the internal malleolus or of the tibia.

4. *Fibular flexion (abduction or pronation), twenty-two experiments.* In fifteen the internal lateral ligament or the internal malleolus broke. In seven the only lesions were in the tarsal (two) or subastragalar (five) ligaments. He never obtained a primary fracture of the external malleolus: in two cases only did it break, the lesion being a compression fracture at its tip. (If the inferior tibiofibular ligaments had previously ruptured, the weight of the patient's body, in a fall, would have fractured the fibula above these ligaments.)

5. *Inward rotation of foot around long axis of leg, twenty experiments.* In nineteen there were lesions of the ligaments (fifteen involved the tarsal ligaments, of which six involved also the external lateral ligament; while in four the external lateral ligament was alone involved). In one the anterior margin of the external malleolus was broken, evidently being torn off by the anterior fibers of the external lateral ligament. (Such a fracture had been described by Wagstaffe,[24] in 1875, and was later studied by L. LeFort[25] (1886) and by his pupil LeRoy[26] (1887).

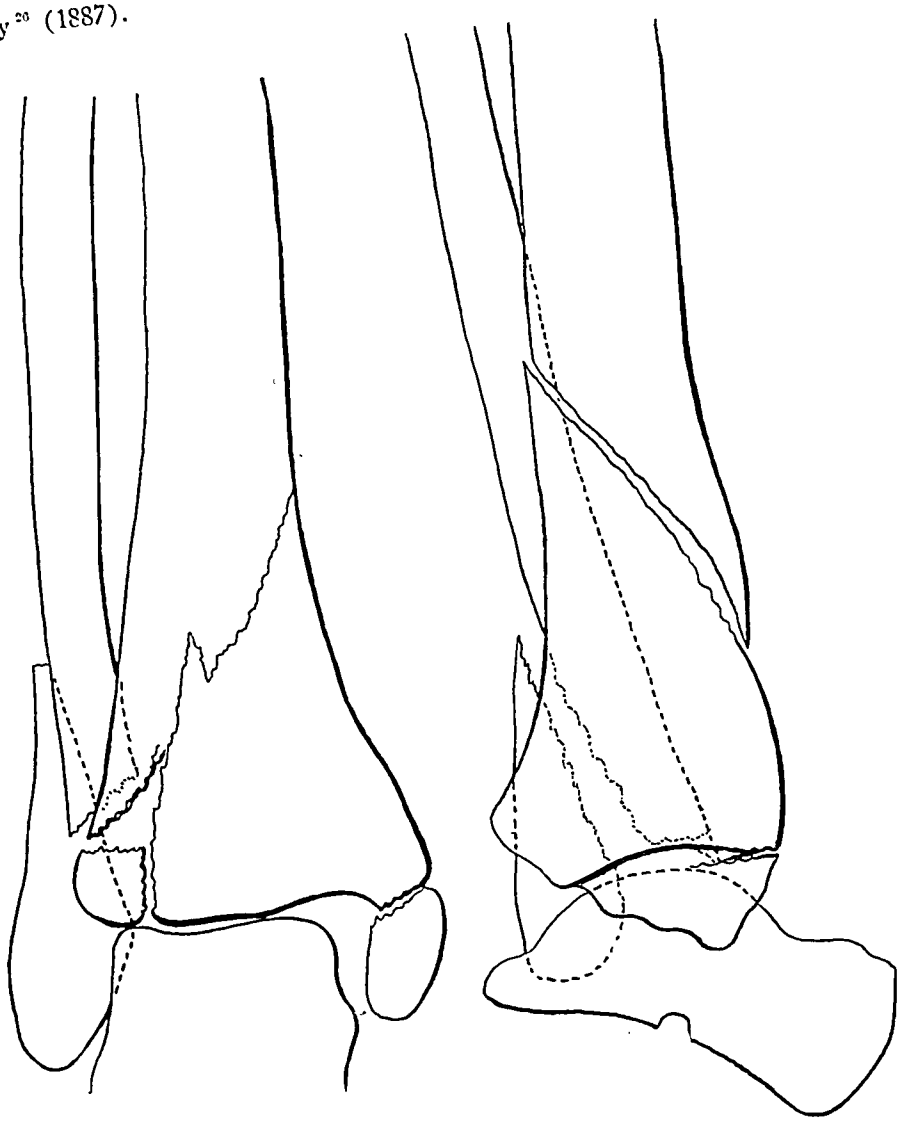

Fig. 19.—Mixed oblique fracture of fibula, with fracture of internal malleolus and of whole lower end of tibia. There is also a fracture of the anterior tubercle of the tibia (A, III).

24. Wagstaffe: Saint Thomas's Hospital Reports, London **6**:43, 1875.
25. LeFort: Bull. gén. de Thérap., Paris **110**:193, 1886.
26. LeRoy: De la fracture marginale antérieure de la malleole externe. Paris, 1887.

6. *Outward rotation of foot around long axis of leg, twenty-two experiments.*

(1) In twenty, fracture of the lower end of the fibula occurred: (*a*) in fourteen of these there was no diastasis of the inferior tibiofibular joint; in two there was rupture of the external lateral ligament with sprain fracture of the tip of the external malleolus. In seven there was only slight obliquity of the fracture line, upward and backward (four had no other lesion, three had also rupture of the internal lateral ligament). In five the line of fracture was distinctly oblique, involving more of the posterior surface of the fibula (two of these five had also rupture of the internal lateral ligament). (*b*) In six cases there was diastasis, usually detaching a small intermediate fragment from

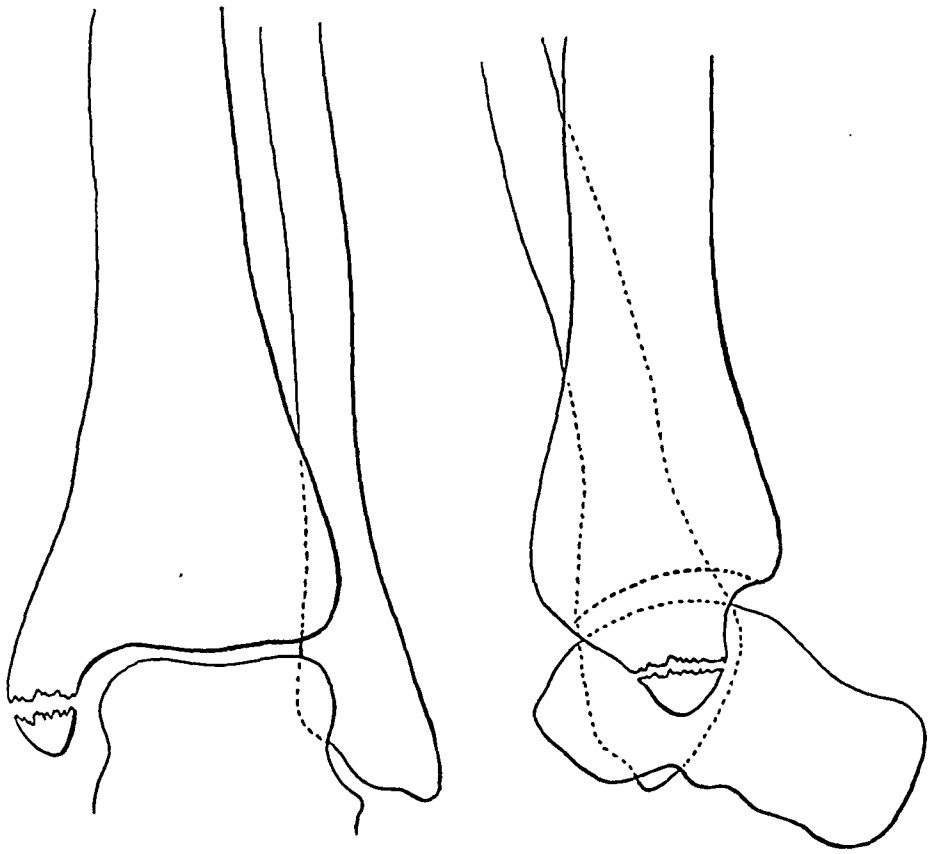

Fig. 20.—Abduction fracture, first degree (B, I): avulsion of internal malleolus. In this patient the internal malleolus extended abnormally low. This fracture occurs in 6.6 per cent. of all fractures at the ankle. All forms of the abduction type together comprise about 21 per cent. of the cases.

the tibia, and with rupture of the internal lateral ligament or fracture of the internal malleolus; in four of these six cases the fracture of the fibula was oblique upward and backward, and in the remaining two cases the fibula was broken obliquely in its upper third (i.e., Maisonneuve's fracture).

(2) In two cases diastasis occurred without fracture of the fibula.

Hönigschmied concluded that these oblique fractures of the lower end of the fibula produced during external rotation are not due, as Maisonneuve taught, to the outward pressure of the astragalus on the anterior border of the external malleolus, but to the pull exerted by the posterior band of the external lateral ligament, which tears off the posterior portion of the malleolus.

Destot, in the thesis of Bondet [27] (1899) and in his own monograph [8] (1911), attempted a physiologic classification, abandoning that based on the mechanism. He pointed out that the main function of the tibia was that of support, while the fibula acted merely as a splint along the outer side of the ankle joint to maintain the direction of the foot. Thus his classification embraces (1) those fractures which involve only the mortise, and disturb the equilibrium of the foot; and (2) those

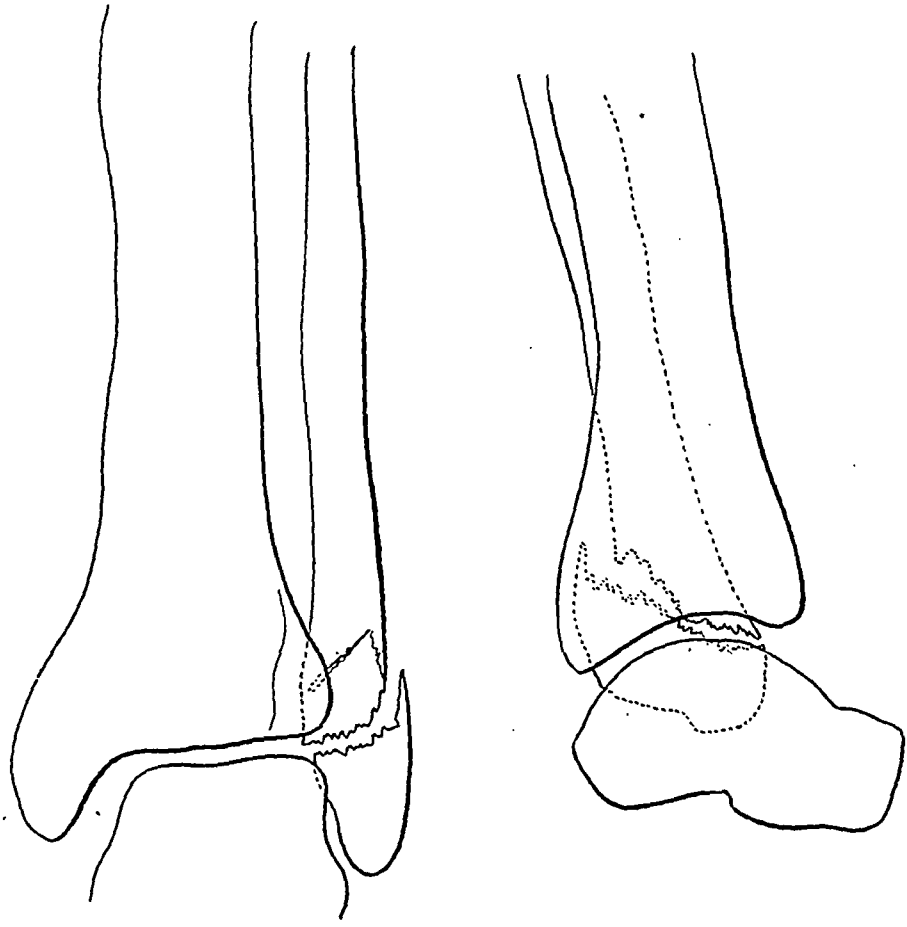

Fig. 21.—Fracture of fibula below inferior tibiofibular ligaments, with very slight obliquity, accompanied by rupture of the internal lateral ligament, as evidenced by lateral displacement of astragalus. This type of fracture is intermediate between the fracture by external rotation already discussed and the fracture by abduction. It is impossible from the roentgenogram alone to say to which of the two types such a fracture really belongs (A, I or B, I).

which involve the "pilon tibial" (the tibial "pestle") and hence compromise the support of the body. Quénu [28] (1912) addressed very severe criticisms against this classification, and, pointing out that the

27. Bondet: Thèse de Lyon, 1899.
28. Quénu: Rev. de chir. **45**:1, 211, 416, 560, 1912.

the tibiofibular ligaments act as a fulcrum, so that the fibula is bent in against the tibia above the attachment of these ligaments, and finally breaks at this point from five to eight cm. above the ankle joint; the internal malleolus often is avulsed from the tibia, at the same time; and to this combined lesion the name of Pott's fracture is given." (Ashhurst: Surgery, Philadelphia, 1914, p. 380.)

"What is a Pott's fracture? . . . It is a fracture of the lower end of the fibula that is produced by the foot turning outward when the injury is sustained. What happens when the foot turns outward? The external surface of the astragalus presses against the tip of the external malleolus, and the fibula

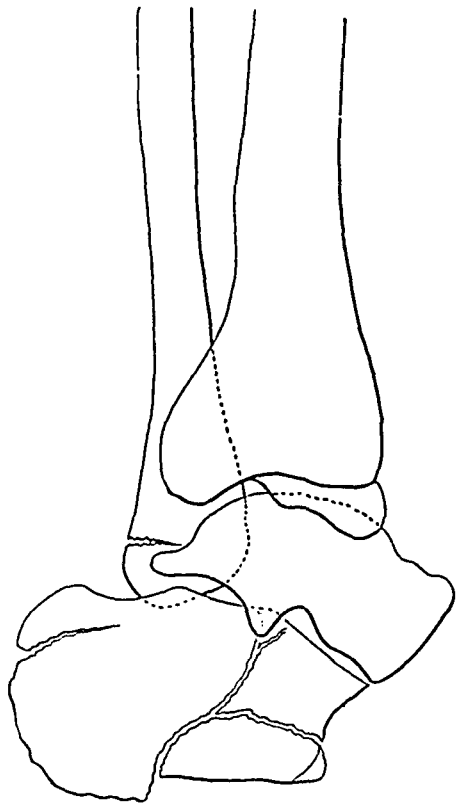

Fig. 23.—Crush fracture of calcaneum permitting fracture of external malleolus by compression. See page 99.

breaks primarily. If the interosseous ligament is strong, the fibula breaks within the first two and one-half inches above the tip of the external malleolus, otherwise only the tip of the fibula is broken off on a line with the tibio-astragaloid articulation, as in the case before us today. In a typical Pott's fracture the fibula fractures higher up.

"Next occurs a fracture of the internal malleolus, due to traction on the internal lateral ligament or rupture of the ligament. Then, as the pressure is continued with the foot everted and the weight of the patient's body is brought to bear on the foot, what happens? The astragalus is crowded up against the

tibiofibular articulation, and, acting as a wedge, forces apart the tibia and fibula and splits or tears the interosseous ligament." [31]

"The mechanism of Pott's fracture consists first in forcible eversion of the foot until the outer surface of the astragalus is driven against the fibular malleolus; secondly, in fracture of the shaft of the fibula, usually above the inferior tibiofibular joint, the unyielding interosseous ligament acting as a fulcrum; thirdly, by a continuation of the vulnerating force, the acute supero-external border of the astragalus develops as a wedge and is driven upward between the tibia and fibula until it springs the joint by lacerating the interosseous membrane." [32]

Cotton [33] (1910) describes all "eversion fractures" as Pott's fractures, and, though he points out the inaccuracy of this term, does not dwell particularly on their mechanism, merely quoting Stimson's account already given.

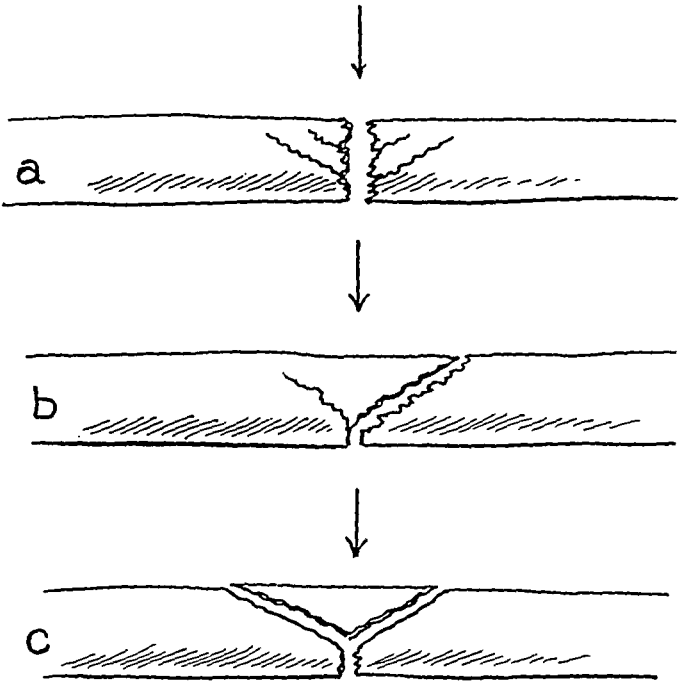

Fig. 24.—Messerer's diagram illustrating the mechanism of fracture by bending (Biegungsbruch) or flexion: (*a*) minute examination always shows in fractures apparently transverse delicate lines diverging from the main fracture and extending backward toward the surface of the bone which has been compressed or flexed, and away from the surface of extension; (*b*) an oblique fracture represents one of these diverging lines which has become a complete fracture; (*c*) very frequently a wedge-shaped fragment is detached, with its base on the compression (concave) surface and its apex toward that of extension (convex surface). See Figures 25, 26, 28, 29, 35, 36.

31. Murphy: Surgical Clinics, Philadelphia **3**:2, 1914.
32. Murphy: Surgical Clinics, Philadelphia **1**:620, 1916.
33. Cotton: Dislocations and Joint Fractures, Philadelphia, 1910, p. 545.

Roberts and Kelly[34] (1916), in describing "fracture by eversion and abduction," say the mechanism is first fracture of the internal malleolus or rupture of the internal lateral ligament; "as the force continues the astragalus is forced against the external malleolus, fixing the latter, at the same time the weight of the body falling outward carries with it the leg and the fibula; the fibula is checked by the astragalus [Do they mean that the external malleolus is kept from moving inward as the body of the fibula moves outward?] and kept attached to the tibia by the tibiofibular ligament; either the latter ruptures or a line of fracture occurs at the weakest point of the fibula just above the point of attachment of the tibiofibular ligament. It is here that the fixed portion

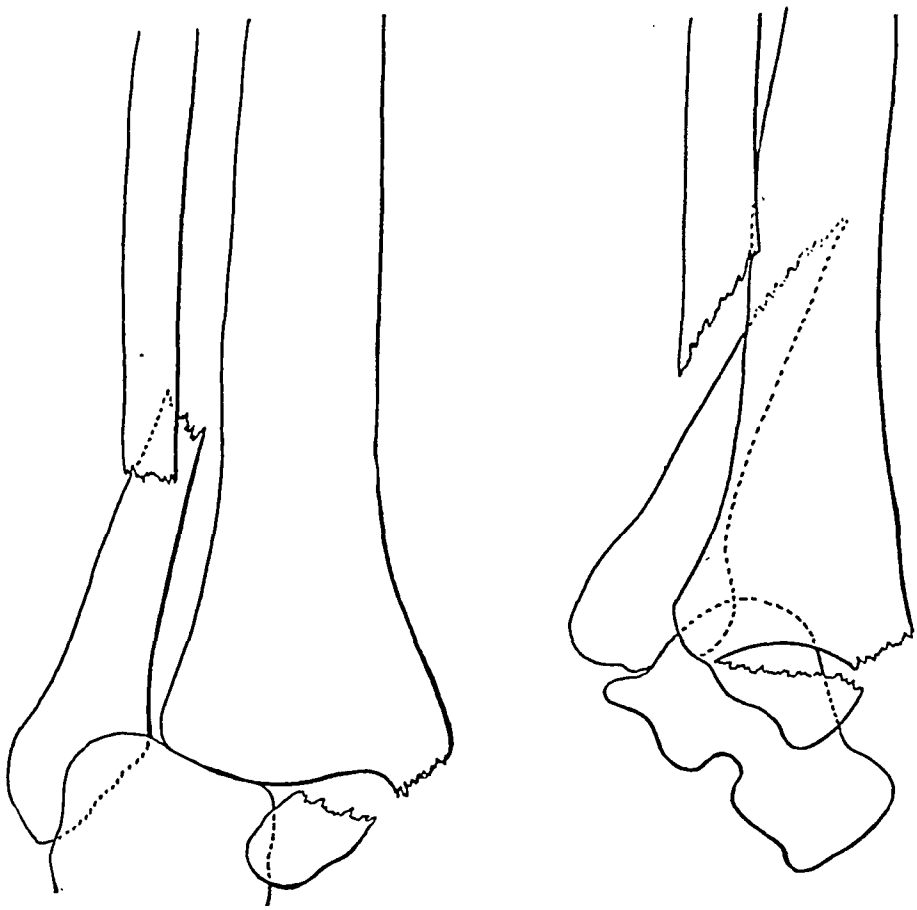

Fig. 25.—Fracture by abduction, second degree (B, II, b) (Pott's fracture, Dupuytren type): a primary fracture of the internal malleolus or rupture of the internal lateral ligament, followed by diastasis (with or without an intermediate fragment), finally succeeded by fracture of the fibula above the inferior tibiofibular joint by bending (Biegungsbruch).

of the fibula meets the potential moving upper portion, and fracture occurs about 2 to 2¼ inches above the malleolus. The line of fracture of the fibula depends to a great extent on whether the fall is directly outward, or whether some torsion of the tibiotarsal joint occurs at the moment of fracture."

34. Roberts and Kelly: Treatise on Fractures, Philadelphia, 1916, p. 580.

On page 590, they describe another (?) mechanism: "In addition to the mechanism described under fibular fracture, there is the effect due to the weight of the body being applied simultaneously with the violence causing the supramalleolar fracture of the fibula; by this force the outer trochlear surface of the astragalus is carried sharply against the outer portion of the articular surface of the tibia, by external rotation and abduction of the foot, so that either the tibiofibular ligament must give way or the outer edge of the tibia be broken away from the shaft. Dislocation upward of the astragalus between the tibia and fibula may occur."

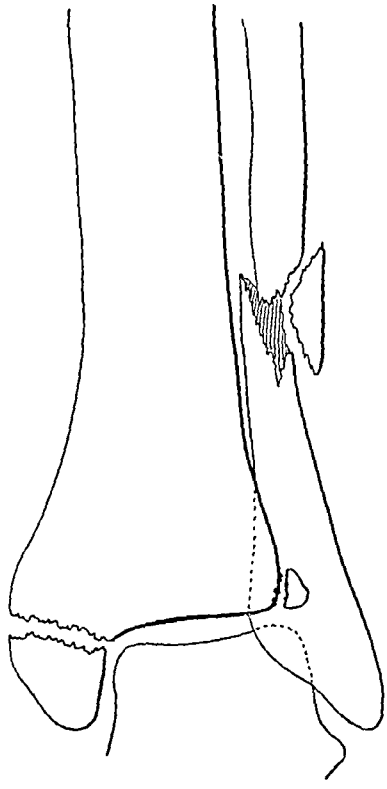

Fig. 26.—Fracture by abduction, second degree (B, II, b) (Pott's fracture, Dupuytren type): diastasis evidenced by detachment of fragment from anterior tubercle of tibia (intermediate fragment); fracture by bending clearly shown by detachment of wedge from concave side of fibula.

Rose and Carless[35] (1920) distinguish between Pott's fracture and Dupuytren's fracture thus:

"In Pott's fracture, sudden abduction, usually combined with eversion of the foot, results in severe strain on the internal lateral ligament, which gives way, or the base of the internal malleolus is torn off. The astragalus is at the same time driven outward against the external malleolus, and the force is thence transferred up the fibula, which bends and breaks at some weak spot. Generally, eversion is a large element in the force that produces the fracture which then runs obliquely from above downward and forward through the malleolus;

35. Rose and Carless: Manual of Surgery, Ed. 10, London, 1920, p. 632.

less frequently it is due to a pure abduction and may then be situated in the position originally described by Pott, viz., about three inches above the tip of the malleolus, and is transverse, the upper end of the lower fragment being displaced inward toward the tibia. The inferior interosseous ligament remains intact. . . .

"In Dupuytren's fracture a much more serious lesion is produced. The interosseous tibiofibular ligament yields more or less completely, or the flake of the tibia to which it is attached is torn off."

Speed[36] (1916) thus describes the mechanism of fractures about the ankle (p. 772): "When abduction and eversion of the foot are the cause of the fracture, the astragalus is pushed outward, and the fibula tends to break at a

Fig. 27.—Diastasis of inferior tibiofibular joint, following rupture of internal lateral ligament, but not succeeded by fracture of fibula (B, II, b, 1, Variant).

point above the termination [presumably he means the *upper* termination] of the tibiofibular ligament in a transverse or oblique line from compressive force. Coincidently the internal lateral ligament either ruptures, or holding its insertion into the tibia, pulls off the internal malleolus squarely near its lower end (Fig. 566). [This figure represents a "low Dupuytren" fracture.] If this eversion continues strongly, the lower fibular fragment may be separated a little from the tibia by tearing of the tibiofibular ligament, and the internal malleolus is correspondingly dragged outward by the internal lateral ligament,

36. Speed: Textbook on Fracture and Dislocations, Philadelphia, 1916, p. 772.

and comes to lie under the joint surface (Fig. 567). [This figure shows a Pott's fracture, with wide diastasis; and the latter certainly preceded the fracture of the fibula and did not, as Speed contends, follow it.] Some torsion is present in all these cases. . . . If the torsion is a more predominating feature in conjunction with the eversion, we obtain the spiral fractures of the external malleolus, as this point projects lower down than the internal malleolus and meets with most of the force in external torsion and eversion. [The reason alleged is insufficient explanation.] These spirals, in a quickly acting force, are above the lower end of the tibiofibular ligament which by a slight elasticity holds while the rigid bone gives; but in slower acting force with more eversion or compressive violence from the body weight, the extreme end

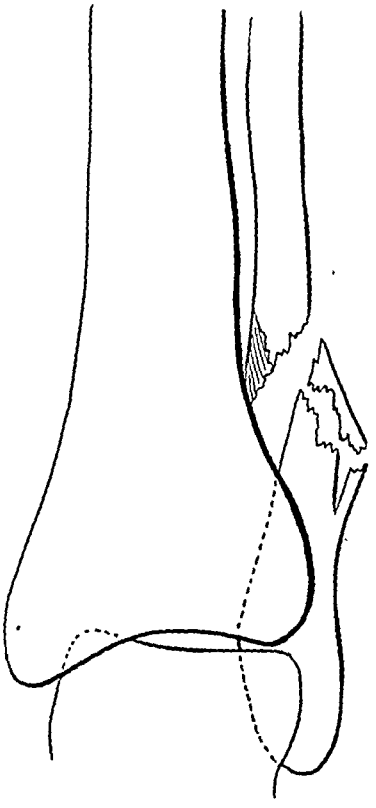

Fig. 28.—Fracture of lower fifth of fibula (surgical neck) by direct violence (kick of horse): there is no diastasis and under such circumstances the typical bending fracture (wedge detached from surface of flexion), which has been overcorrected by adduction of foot, could not have been produced by indirect violence (pressure of astragalus outward on external malleolus).

of the external malleolus is fractured and splintered up in a spiral manner. As a rule there is not much damage to the internal malleolus and the internal lateral ligament in this mechanism (see Fig. 568)."

This figure shows a low mixed oblique fracture of the fibula, unreduced, though the foot is in adduction and inward rotation. Speed says reduction has not been secured because of laceration of the external lateral ligament. But how could such a laceration occur in the mechanism he is discussing? Speed adds that "sometimes in eversion, in addition to fibular fracture, the tibiofibular ligament is torn, a condition permitting wide separation between the bone ends

and possibly accompanied by a shell of bone pulled out from the tibia." Writing (p. 785) of "malleolar fractures caused by inversion of the foot," he says, "The mechanism of isolated fractures of the internal malleolus is that of fall or compression from body weight against the talus, which is tipped inward by the inverted foot. . . . For this result the inversion must not be great, because the pull of the external lateral ligament would also pull off the external malleolus." (Thus he regards fracture of the external malleolus as a secondary and not the primary lesion in adduction fracture. But the illustration he gives as an instance of isolated fracture of the internal malleolus is not happily chosen [Fig. 592], as it shows the astragalus displaced from the external malleolus,

Fig. 29.—Fracture by abduction, third degree (B, III). The internal malleolus is represented by the whole lower end of the tibia; the fibula is broken by bending; there may or may not be an intermediate fragment. There were only two cases of this kind in our series of 300 cases.

an occurrence obviously permitted only by partial rupture of the anterior fibers of the external lateral ligament or sprain fracture of its tip.)

MECHANISM

Now, after the somewhat tedious historical review given above, it is worth while, before proceeding further in our inquiries, to pause a moment to refresh our knowledge concerning the structure and functions of the ankle. We have read of eversion, of abduction, of rotation,

of torsion, compression and bending, of malleolus and fibula, of ligaments and tubercles, of sprains, displacements and diastases; but it is clear that few authors use any of these terms in the same senses, and

Fig. 30.—Fracture by abduction (B, II, b, 1): rupture of internal lateral ligament, followed by diastasis (note the intermediate fragment), and this succeeded by a bending fracture of fibula, in this case at an unusually high level.

that some of them probably do not know what they mean themselves. But what Nélaton[37] (1844) said of surgery in general may well be

37. Nélaton: Eléments de path. chir., Paris, 1844, vol. 1, Preface.

applied to this particular part of surgical knowledge: "*Rien en chirurgie n' est assez abstrait pour que l'obscurité s'excuse par le sujet même, et sur un grand nombre de points la science est assez avancée pour que la verité apparaisse au milieu des controverses à celui qui la cherche sans préoccupation.*" And if what I succeed in explaining in the following pages appears to you to be nothing new, you will admit its truth; and I shall be satisfied. If on the other hand, you do not agree with my

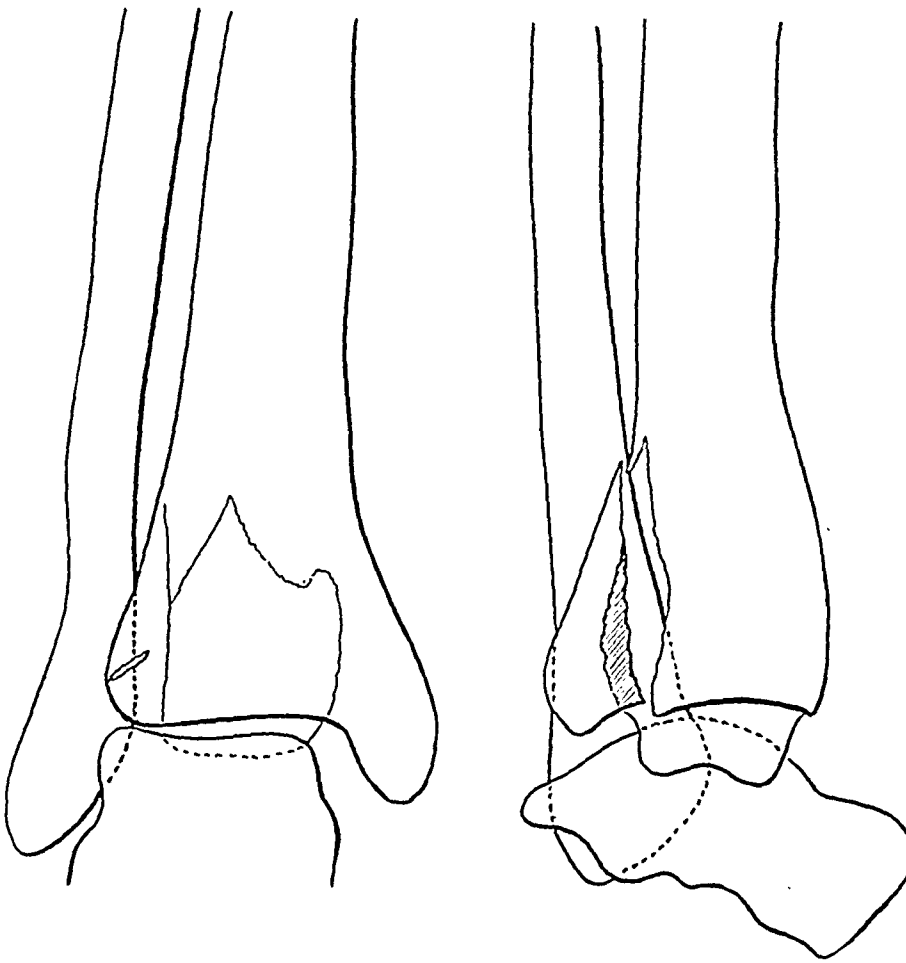

Fig. 31.—Fracture of posterior margin of tibia, associated with a tibiofibular diastasis, as evidenced by sprain fracture at this joint. The posterior marginal fragment which is unusually large is visible also in the antero-posterior view.

conclusions, that will not in the least disconcert me, for it will not impair their truth.

The ankle joint is formed above by the tibiofibular mortise, and below by the trochlea of the astragalus, which fits into the mortise as a tenon. This trochlear surface is one fourth wider in front than behind, conforming to the divergent direction of the internal surfaces of the

malleoli. The inferior articular surface of the tibia may be described as the roof or ceiling (*plafond*) of the joint; and the articular surfaces of the malleoli have long been known as the "cheeks" of the mortise.[38] That portion of the fibula *which projects beyond the tibial plafond* is properly called the external malleolus; and the corresponding projection of the tibia is called the internal malleolus. The posterior lip of the tibial plafond projects so low as to have been called by Destot the posterior malleolus. This serves to reinforce the mortise posteriorly. It is further deepened by the transverse tibiofibular ligament which

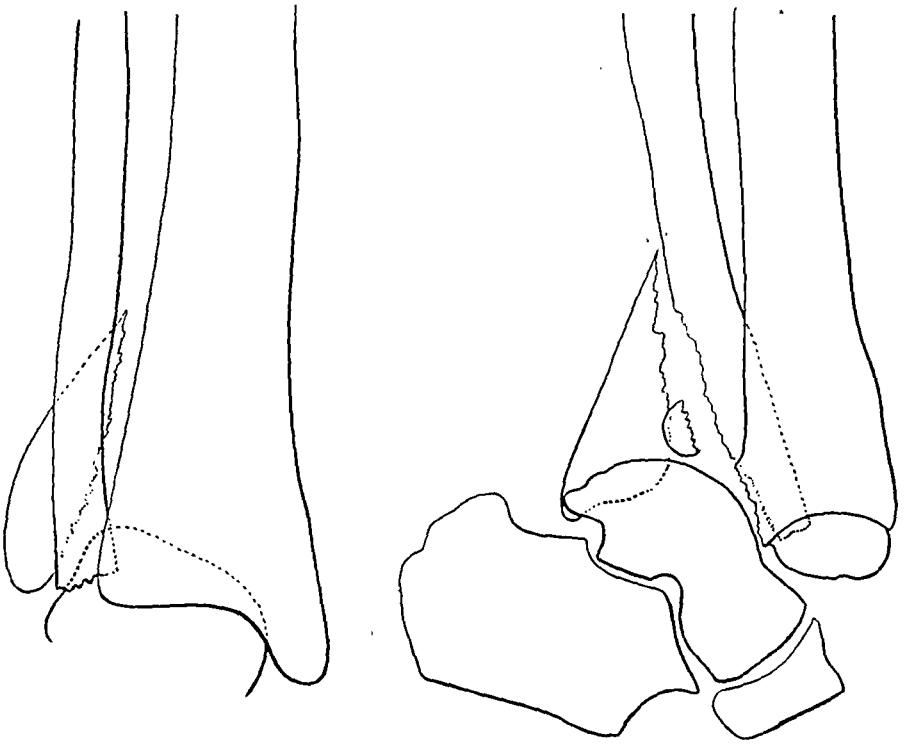

Fig. 32.—Small posterior marginal fragment in a case of fracture by external rotation. Notice the mixed oblique fracture of fibula; the intact internal malleolus (rupture of internal lateral ligament), and the complete posterior dislocation of the foot, the astragalus and the posterior marginal fragment accompanying the external malleolus.

extends from the external malleolus to the posterior lip of the tibia. Thus in walking, as the foot meets the ground in plantar flexion, the leg bones are checked in their tendency to slide forward on the astragalus by the wedge shape of the trochlea of the latter bone (broad anteriorly

38. From the Greek word for cheek, Quénu derives the adjective *génienne,* which he constantly employs in his classification and nomenclature of ankle fractures, inventing such terms as *bi-malleolaire géni-sus-genienne, géni-peronière* and *géni-supramalleolaires.*

and narrow posteriorly), by the corresponding divergence of the anteroposterior planes of the malleoli, and by the long posterior lip of the tibial plafond. In walking backward (always digitigrade, not plantigrade) the same mechanism is effective.

The fibula is attached firmly to the tibia, but a slight range of motion is permitted. The interosseous membrane extends throughout the length of the tibial and fibular shafts, the fibers running downward and laterally from tibia to fibula (as in the forearm from radius to ulna); and in addition, there are strong ligaments whose fibers run in the same direction, binding both ends of the fibula to the tibia, at which

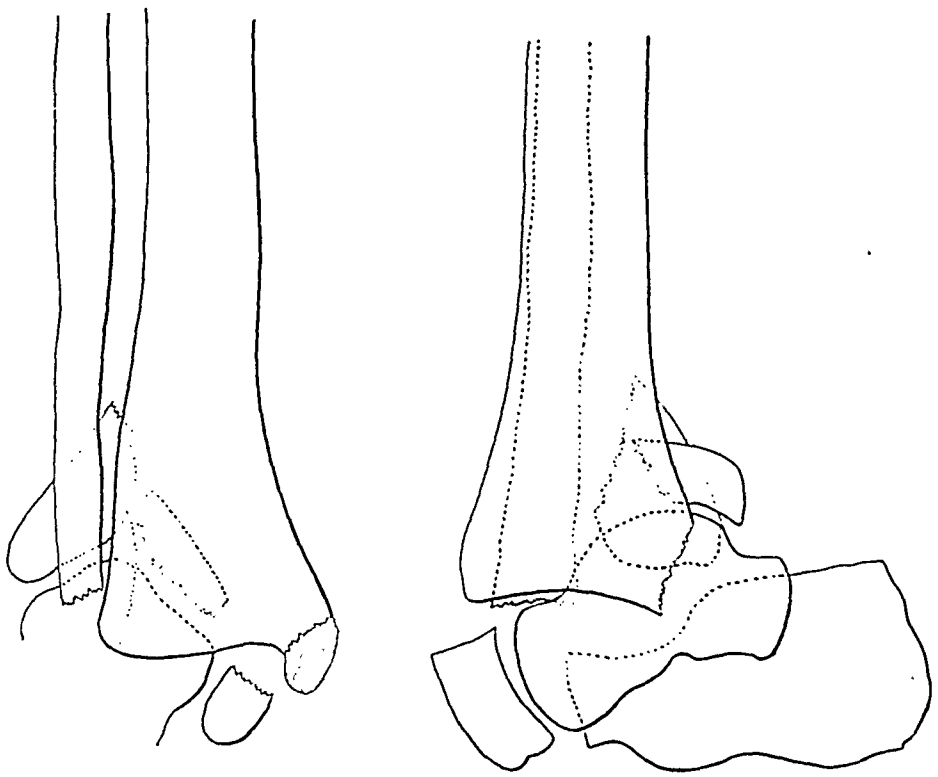

Fig. 33.—Medium-sized posterior marginal fragment in association with mixed oblique fracture of fibula and fracture of internal malleolus. The posterior marginal fragment, which is visible also in the anteroposterior view, accompanies the external malleolus and the astragalus in the very marked lateral displacement and in the incomplete posterior dislocation.

points only are the two bones in contact. At the upper end, where the head of the fibula butts against the overhanging external condyle of the tibia, there is a synovial cavity to the tibiofibular joint; but at the lower end, where the fibula is received into a longitudinal groove between the anterior and posterior tubercles on the lateral surface of the tibia (Fig. 4), no such joint cavity exists, union being effected by a dense feltlike interosseous ligament, reinforced anteriorly by the anterior

inferior tibiofibular ligament, and posteriorly by the posterior ligament of the same name. The malleoli, of which the external is the longer and is situated more posteriorly, serve to keep the foot (which is appended to the astragalus) under the leg bones. The astragalus itself has no muscles attached to it, and serves only as a ball in a ball-bearing joint to facilitate movements of the leg bones above it and of the tarsal bones below and in front. The foot is attached to the leg bones by

Fig. 34.—Large posterior marginal fragment in association with mixed oblique fracture of fibula and fracture of internal malleolus; only moderate displacement, chiefly due to the outward rotation.

ligaments, of which the lateral portions are best developed, constituting for the ankle, as in other hinge joints, lateral ligaments which hinder motion except in the anteroposterior plane. The internal lateral ligament passes from the internal malleolus in radiating direction (1) anteriorly to the scaphoid and median surface of the calcaneum (sus-

tentaculum tali) and (2) posteriorly to the median tubercle on the posterior surface of the astragalus. The external lateral ligament has three distinct bands, passing from the external malleolus: one goes forward to the lateral border of the neck of the astragalus, just above the sinus of the tarsus; the middle band passes downward and slightly backward to the calcaneum; while the posterior, whose deep portion is extremely strong (Fig. 5), is attached to the lateral tubercle on the posterior surface of the astragalus (os trigonum), which, being from 5 to 7 mm. posterior to the median tubercle, is the portion of the

Fig. 35.—Small posterior marginal fragment in association with abduction fracture of fibula and fracture of internal malleolus. Note the diastasis, the typical wedge detached from the flexion surface of fibula and the posterior marginal fragment accompanying the external malleolus and astragalus in their marked lateral and posterior displacement.

astragalus which casts the farthest posterior shadow in lateral roentgenograms of the foot. This posterior band of the external lateral ligament is so exceedingly strong that it is very seldom ruptured; it holds the astragalus almost indissolubly attached to the external malleolus,[39] and

39. Chaput (Bull. et mém. Soc. de chir. de Paris **38**:1192, 1912.) says they are like Siamese twins.

in injuries of the ankle either one or other bone to which the ligament is attached is more easily broken than is the ligament ruptured. As will be shown subsequently, usually the fibula gives way when the strain comes; occasionally, however, the posterior tubercle of the astragalus is detached; and I have seen at least one case in which fracture occurred at both points simultaneously.[40]

The next question that arises is, what is the function of the fibula?

Fig. 36.—Posterior marginal fragment associated with diastasis and fracture of internal malleolus, and with fracture of fibula by bending backward (flexion surface posterior, extension surface anterior) as evidenced by wedge detached from posterior surface of fibula.

40. The posterior tubercle of the astragalus may sometimes be fractured by direct violence as it is crushed against the posterior lip of the tibia in forced plantar flexion of the foot.

Humphry[41] (1858) notes that the fibula is an inconstant bone in animals: in carnivora and pachydermata it extends from the upper end of the tibia to the ankle as in man. In most rodents it is united with the tibia at the lower part. In ruminants it altogether disappears. In birds its upper extremity enters into the knee joint and articulates with the external condyle of the femur; it lies close against the tibia and dwindles and disappears about the middle of the leg. In reptiles, it is large, in many extending to the knee joint above and

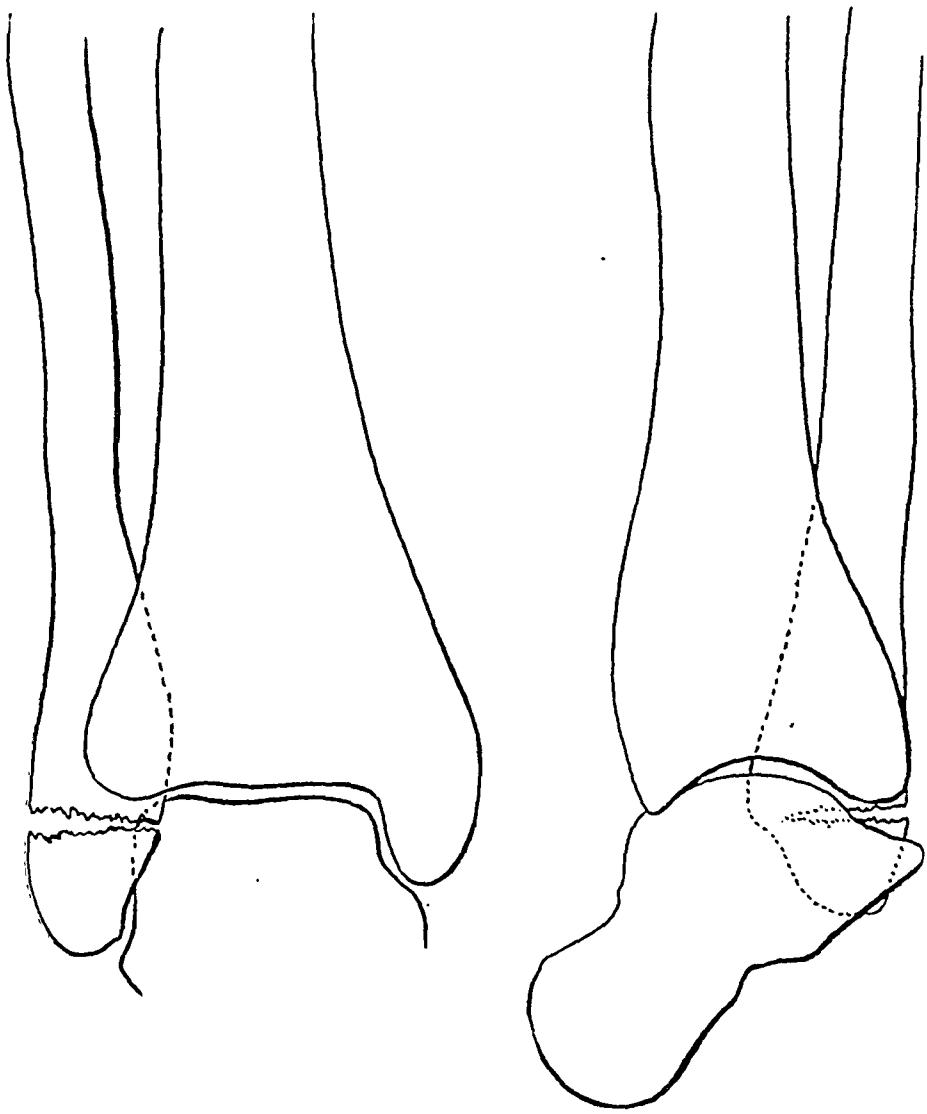

Fig. 37.—Fracture by adduction, first degree (C, I); avulsion of external malleolus. See page 118.

to the tarsus below. In the bat, the lower half of the fibula and the upper half of the ulna are retained.

It has seemed to me, from study of the skeletons in the Museum of the Academy of Natural Sciences of Philadelphia, that the fibula was best developed and extended farthest beyond the tibia at the ankle in those animals which

41. Humphry: Treatise on the Human Skeleton, Cambridge, 1858, p. 490.

were most nearly plantigrade, and in which, as in man, stability rather than agility was demanded. In digitigrades, such as the horse and camel, there is no fibula; in partial or less complete digitigrades (rhinoceros) it extends beyond the tibial plafond, but not below the level of the internal malleolus. In a still less complete digitigrade (almost a plantigrade), such as the elephant, it extends below the level of the internal malleolus, and there is outward rotation of the lower end of the tibia, as in man. In the gorilla, chimpanzee, orang-utan, etc., on the other hand, which are more plantigrade than digitigrade (but in which, as already noted, agility is retained at the expense of stability),

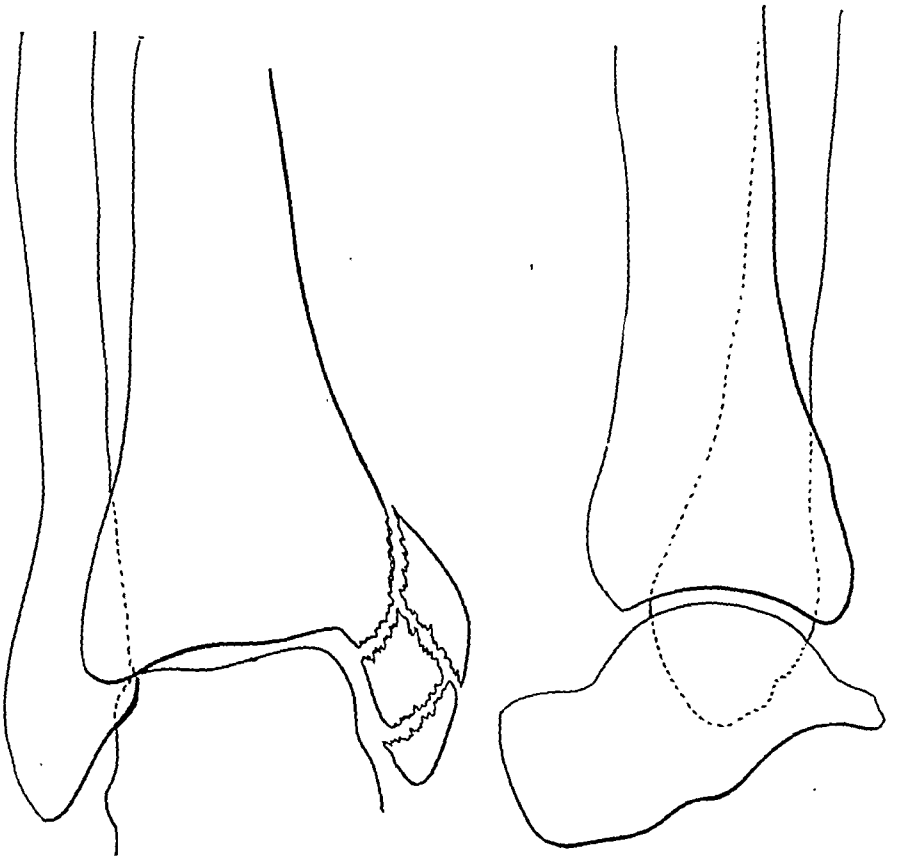

Fig. 38.—Adduction fracture, second degree (C, II, a); avulsion of external malleolus, represented by partial rupture of anterior fibers of external lateral ligament (rare) followed by compression fracture (note the comminution) of internal malleolus.

the lower end of the tibia has not rotated out as far as in man (in fact, not so far out as a transverse plane through the tibial condyles), and the fibula descends no lower than the internal malleolus. This lack of development of the fibula in these more or less anthropoid animals was noted by Bland-Sutton[42] (1888); and he further calls attention to the fact that in babies born with congenital clubfeet this deformity is merely a lack of normal development, the outward rotation of the lower end of the tibia not having occurred, and the external malleolus not having descended below the level of the internal.

42. Bland-Sutton: Am. J. M. Sc. **95**:376, 1888.

Evidently, he concluded, the external malleolus was developed only to aid members of the human race to walk in the erect posture; it was required to keep the foot steady and prevent it from turning outward into a position of extreme valgus. As Destot says, the external malleolus acts merely as a splint to maintain the direction of the foot.

But if this is so, why is the fibula a separate bone in man? Why is not the external malleolus merely a part of the tibia? To this I know of no better answer than that given by Bromfeild[11] (1773) that if it were a part of the tibia,

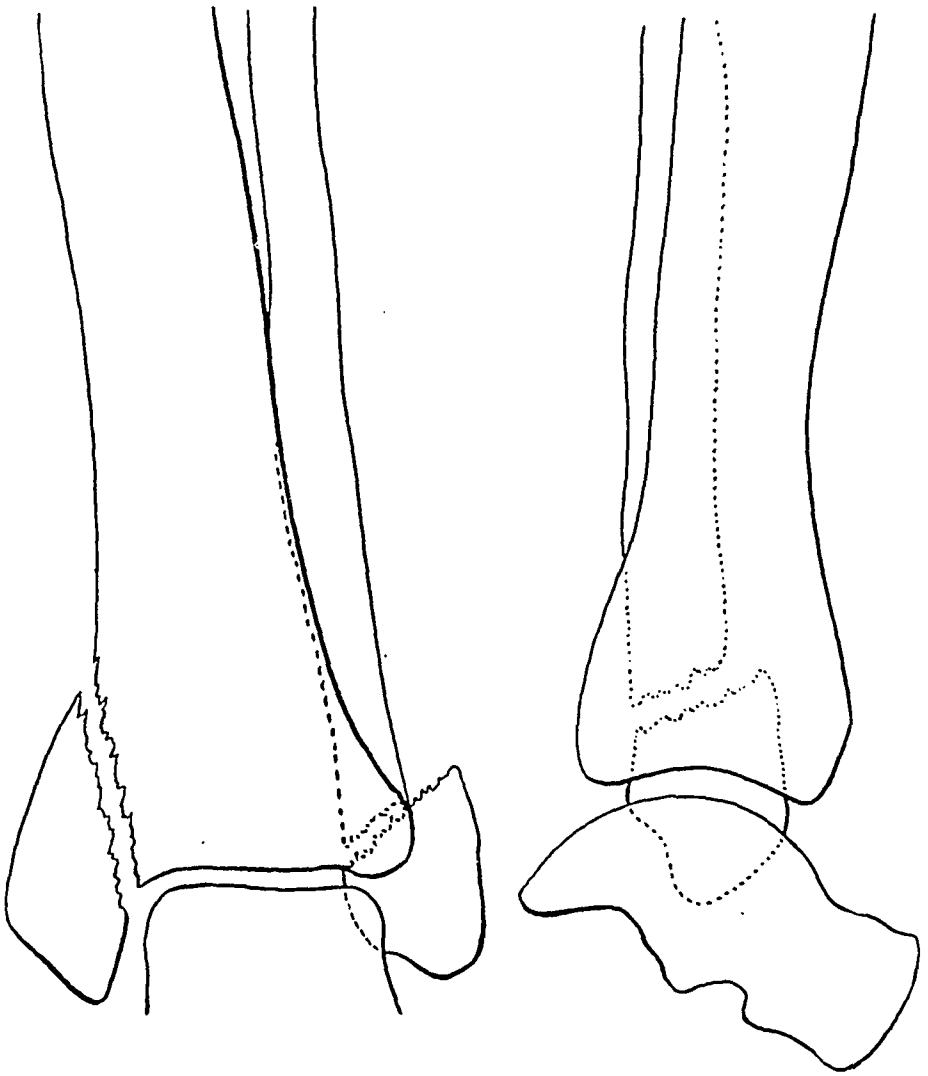

Fig. 39.—Adduction fracture, second degree (C, II, a); avulsion of external malleolus followed by compression fracture of internal malleolus.

and no give or play whatever occurred between the malleoli, no one could take more than a very few steps without fracturing one or other malleolus.

If a leg is studied from which all soft parts have been removed except the ligaments and the interosseous membrane, these phenomena may be observed:

In full plantar flexion (extension) of the foot, the anterior and middle bands of the external lateral ligament become tense and pull the external malleolus medially (and slightly downward and backward) against the tibia, keeping

the external malleolus in close contact with the astragalus as this glides forward and presents to the intermalleolar space a slightly less diameter than in full dorsiflexion of the foot. In the latter movement, dorsiflexion, the anterior band of the external lateral ligament becomes lax, and as the external malleolus is forced away from the tibia and slightly upward, the anterior and posterior tibiofibular ligaments become tense, especially the anterior ligament; also, as flexion beyond a right angle occurs, much tension develops on the middle band of the external lateral ligament, and this pulls the malleolus backward: the posterior band of the external lateral ligament is always tense; it makes the astragalus and external malleolus practically one bone.

Fig. 40.—Adduction fracture, second degree (C, II, b); large tibial fragment extending into shaft replaces compression fracture of internal malleolus.

The expansion of the intermalleolar space which occurs during dorsiflexion of the foot may amount to several millimeters. I have measured it by affixing a wire in each malleolus and bending the ends of these wires forward over the ankle joint until they crossed each other in parallel lines: by scratching a mark on each wire at the same point when the foot is in full plantar flexion, it is easy to measure the excursion as the foot is brought up into full dorsiflexion. This excursion, which exceeds two mm. and may approach three mm., allows the wider anterior diameter of the articular surface of the astragalus to pass back between the malleoli in dorsiflexion, while the downward drag of the

anterior and middle bands of the external lateral ligament keeps the malleoli in contact with the small posterior diameter of the astragalus which presents between them in full plantar flexion. Destot[8] (1911) pointed out that inasmuch as the intermalleolar axis and the axis of rotation of the astragalus, in flexion and extension, do not coincide (they form an angle of about 30 degrees, open laterally, Figure 41), it is not a directly transverse diameter of the astragalus that presents between the malleoli at any point of flexion or extension, but a

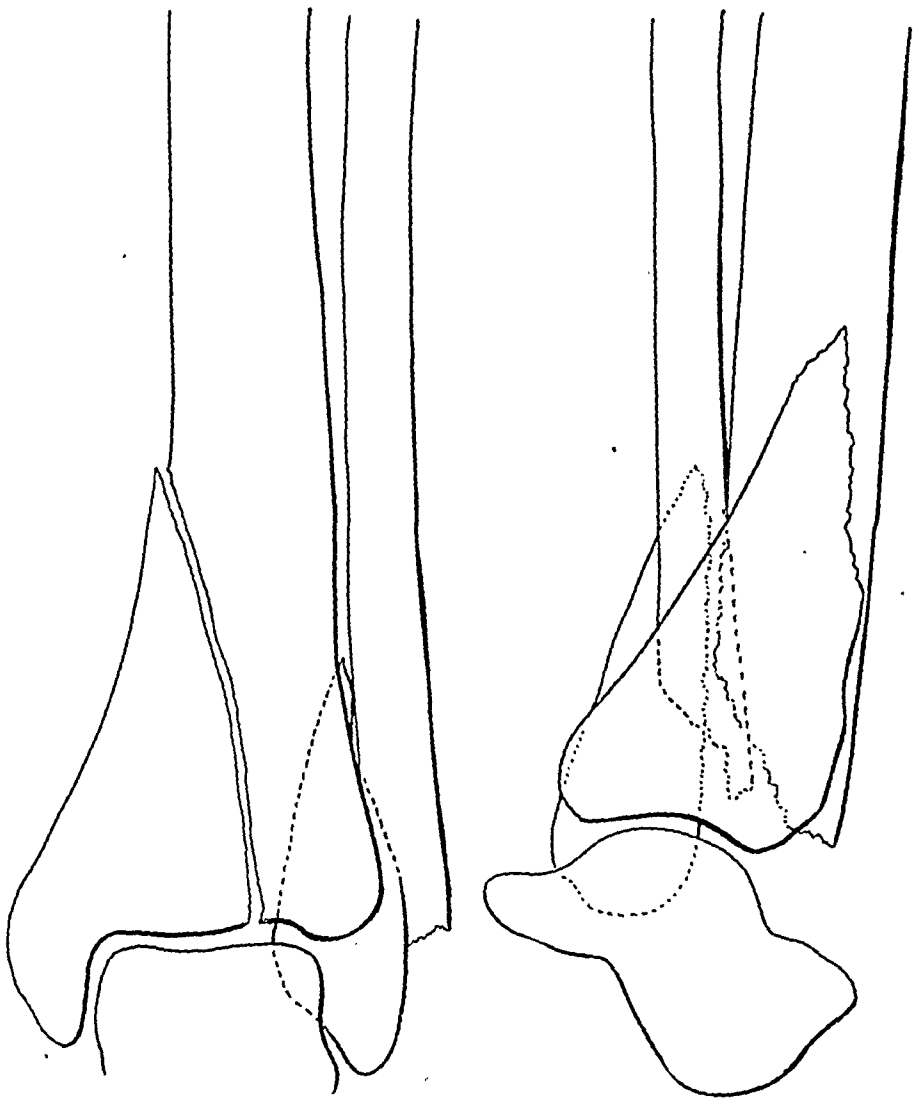

Fig. 41.—Adduction fracture second degree (C, II, b); splitting fracture of median articular surface of tibia replaces crush of internal malleolus. See page 118.

diameter of varying obliquity which is, however, always nearly the same in length; and he is inclined to ignore the existence of the movements of the external malleolus. And I have dwelt at some length on these movements because I have found them nowhere described and because there has been some dispute about them. Humphry[41] (loc. cit., p. 557) asserted that the increase of the distance between the malleoli was secured solely by the elasticity of the fibula, which bent inward toward the tibia in its lower fourth, when the

external malleolus was forced outward. Nancrede[43] (1880), however, pointed out that an upward and downward movement of the fibula occurred, and asserted that Humphry's theory was "preposterous and untrue."[44] This is my own opinion also.

The upper end of the fibula can also be seen to move in flexion and extension of the foot at the ankle; in full plantar flexion (with median and downward movement of the external malleolus), the superior end of the fibula moves

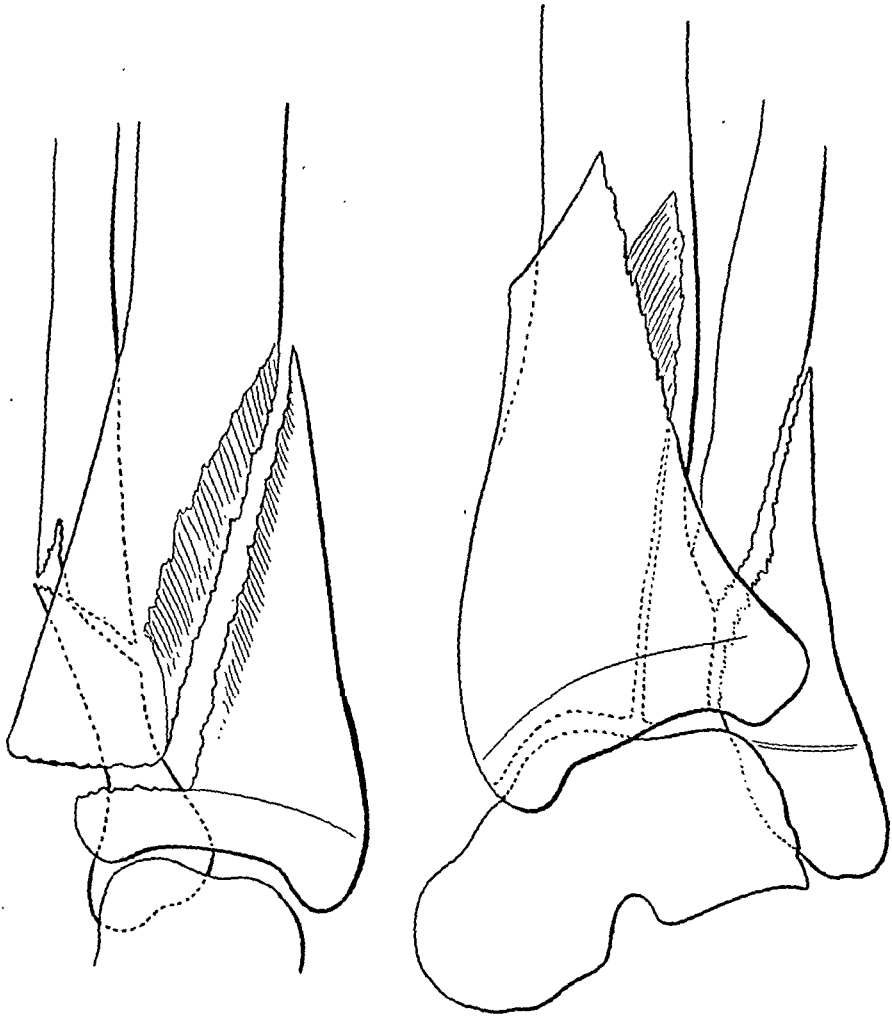

Fig. 42.—Adduction fracture, third degree (C, III); detachment of lower epiphysis with splitting of median surface of tibia.

slightly forward and rotates slightly outward, its anterior surface turning away from the tibia. This movement is due largely to the median and backward pull exerted on the external malleolus by the middle and posterior bands of the external lateral ligament. The head of the fibula slides backward and very slightly upward again in full dorsiflexion. Thus the chief movement of the

43. Nancrede: Phila. M. Times **10**:316, 1880.
44. Nancrede: Maryland M. J. **7**:76, 1880.

superior tibiofibular joint is an anteroposterior one (downward and forward, or upward and backward) around the inferior tibiofibular joint as a pivot; but these movements are so slight as to be scarcely appreciable.

Very little change occurs in the interosseous membrane during these movements, except in its lower fourth, where it spreads and becomes tense (the aperture for the anterior peroneal artery tends to become round from oval) as the external malleolus ascends and moves backward; and it again becomes relaxed when the external malleolus descends and moves mesially toward the

Fig. 43.—Adduction fracture, third degree (C, III); the supramalleolar fracture by adduction (type produced experimentally by Tillaux). See pages 71 and 119.

tibia. The strength of the interosseous membrane is much greater than usually supposed. Even when the lower end of the fibula is freed from its tibial attachments, very great force is required to rupture the interosseous membrane, and fracture of the fibula in its lower third is the nearly invariable sequel.

The normal movements of the ankle joint are those of flexion and extension—20 degrees of dorsiflexion and 60 degrees extension or

plantar flexion, a total of 80 degrees approximately. This motion occurs around an axis which passes in the frontal plane somewhat below and in front of the tip of the external malleolus. This axis makes an angle of 30 degrees (thereabouts) with the bimalleolar axis. This arrangement accounts for the greater excursion forward of the lateral astragalar surface in relation to the external malleolus as compared with the motion which occurs between the median surface of the astragalus and the internal malleolus; as well as for the apparent deviation of the point of the foot medially in full plantar flexion, and laterally in full dorsiflexion.

If movements were possible in the ankle joint around an antero-posterior axis, they should be named adduction (tibial flexion) and abduction (fibular flexion), or movements in the frontal plane toward and away from the median line. These movements are quickly resisted by the tension on the lateral ligaments (Figs. 6 and 7), and if forced, the malleolus *away from which motion occurs* is torn off by its ligament, or the ligament itself ruptures (see the experiments of Hönigschmied, related on page 72). Motions of adduction and abduction in the foot normally occur in the subastragalar joint and permit the calcaneum without difficulty to accommodate itself to slight irregularities of the soil. But the calcaneum is attached to the astragalus by the extremely strong astragalocalcanean interosseous ligament; and when such movements are too extensive, they are transmitted directly to the astragalus and from it to the tibiofibular mortise where fracture of one or the other malleolus is the usual consequence. Not until that malleolus on which the pull comes has given way, or the corresponding ligament has ruptured, is the astragalus able to act on the other malleolus by a push so as to produce a compression fracture. Rare exceptions to this general rule occur, however, as when the calcaneum is itself first broken, and becomes so displaced as to press directly on the end of the fibula, producing a compression fracture of the external malleolus (Fig. 23).

Movements of rotation around the long axis of the leg may be attempted in the ankle joint by twisting the point of the foot toward or away from the median line. As pointed out by Maisonneuve[4] (1840), movements of inward rotation are almost inseparable from a movement of adduction, as the numerous joints in the anterior tarsus render the foot very mobile in this direction. Any movement toward outward rotation, however, converts the foot into a rigid lever, and motion is easily and with much force transmitted to the ankle joint, the astragalus attempting to turn so as to bring its long axis crosswise between the malleoli. Owing to physical laws, it is on the external malleolus that the greatest strain comes. Maisonneuve illustrated this by placing a ruler (which represents the foot) between two parallel

volumes (which represent the malleoli): the volume which is moved is always that toward which the long end of the lever moves (Fig. 8); even if this volume be much heavier than the other it is easily moved by the greater leverage exerted. In movements of outward rotation, the foot, relatively to the tibia, is a lever of the first order, with its fulcrum on the anterior border of the fibula: the arm of the resistance will have, say, a length of 3 cm., that of the power 12 cm. (the length of the foot being taken as 15 cm. from the toes to the posterior border of the ankle joint). Relatively to the fibula, it is a

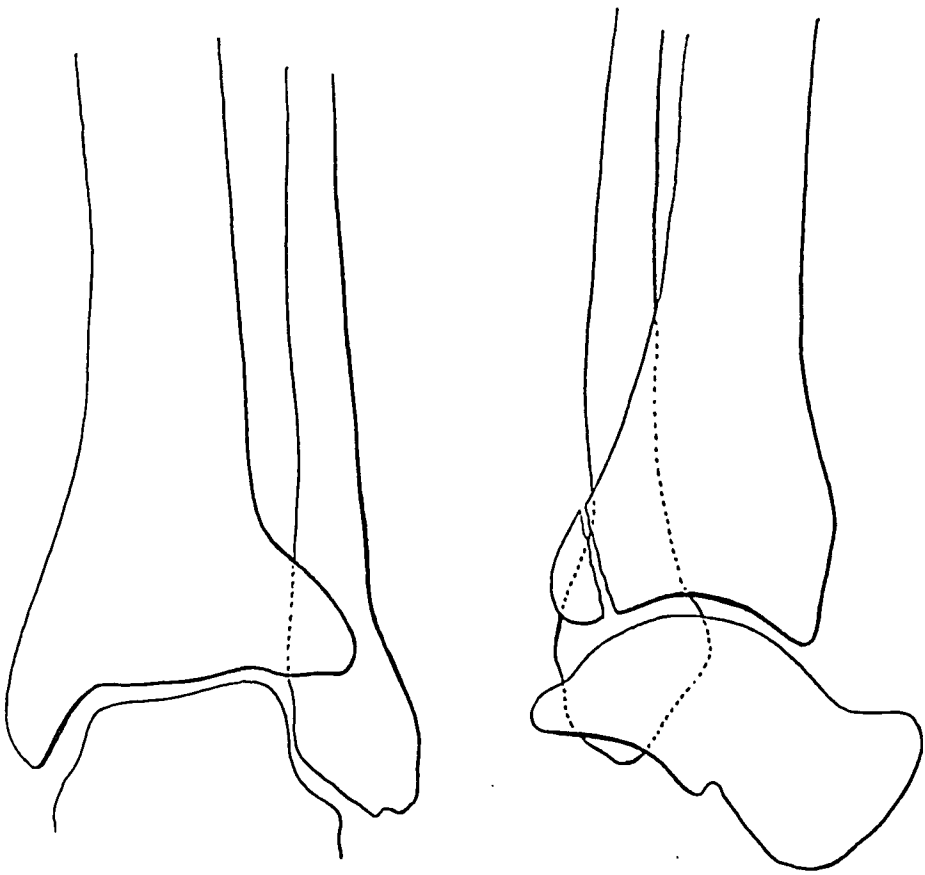

Fig. 44.—Isolated fracture of posterior tibial margin; no displacement; from compression upward and backward.

lever of the second order, with its fulcrum at the posterior border of the internal malleolus: the resistance, therefore, has an arm of 3 cm. (as in the other case) but the power has an arm of 15 cm. (the whole length from the point of the foot to the fulcrum). Thus the force which tends to fracture the fibula is as 12 is to 9, or as 4 is to 3. Such a mechanism as this (outward rotation of the foot) usually causes an oblique fracture of the lower end of the fibula (see Hönigschmied's [6] experiments, page 72); and if such a fracture be made

by an osteotome it will be found that *external rotation is the only movement that will cause separation of the fragments* (Fig. 9). It is evident that the mechanism of this fracture, which is the most frequent of all fractures of the ankle (more than 25 per cent. of all cases), involves not only a push outward on the anterior border of the external malleolus, as noted by Maisonneuve, but also, as Hönigschmied pointed out, a pull inward on its posterior border by means of the posterior band of the external lateral ligament. The line of this fracture is oblique from above and behind, downward and forward. It is, properly speaking, a spiral fracture produced by torsion. Its obliquity varies greatly; but it is always higher on the posterior surface of the fibula than on its anterior, and the line of fracture passes through and involves the inferior tibiofibular joint. Almost invariably, its lower and anterior end extends to the external malleolus (in 90 per cent. of our cases): often just below the tibial plafond, sometimes as far down as the very tip of the malleolus. Thus in practically every instance the anterior inferior tibiofibular ligament remains intact, or even if partially ruptured, there results no true diastasis between fibula and tibia. At most, the lower fragment, comprising that part of the fibula posterior to the attachment of the anterior tibiofibular ligament, rolls outward and slightly backward around the unruptured posterior tibiofibular ligament as a hinge.

If this "mixed oblique"[45] fracture of the fibula, as Destot names it, is the sole lesion resulting from outward rotation of the foot, there is little or no displacement (Figs. 10 and 11). This was the case in all of the seventy-nine cases studied by Dr. Bromer and myself. If the force continues to act, the next lesion which is added is rupture of the internal lateral ligament (in twelve cases only, in our series), or, far more frequently, fracture of the internal malleolus, usually only of its anterior tip, seldom of its whole extent (Fig. 12). This combined lesion (oblique fracture of the fibula with fracture of the internal malleolus) occurred in thirty-two cases in our series, or in 10 per cent. of the entire number.[46] The displacement may be slight or marked. And in very many cases (fifty-one additional cases in our series), besides these two lesions, there is added the complication of fracture of the posterior margin of the tibia. Counting in all complications and variations, this type of fracture occurred in 100 cases or in 33 per cent. of the total 300 cases we have studied.

---

45. "Mixed" because involving the fibula both above and below the tibiofibular joint.

46. Chaput (Bull. et mém. Soc. de chir. de Paris **32**:1047, 1906) noted that among 130 cases of fracture at the ankle, of which he had studied the roentgenograms, 113 conformed to this oblique type of fracture of the fibula, against only seventeen cases in which the fracture was clearly above the malleolus.

Seldom does the obliquity of the fibular fracture pass so high as to be above the level of the anterior inferior tubercle of the tibia (Figs. 13 and 14): in three cases this tubercle was detached (in two of these there was no appreciable lesion at the internal malleolus, but in one, the internal malleolus was fractured), and in two others it is probable that a disjunction of the joint had occurred, as indicated by suggestive roent-

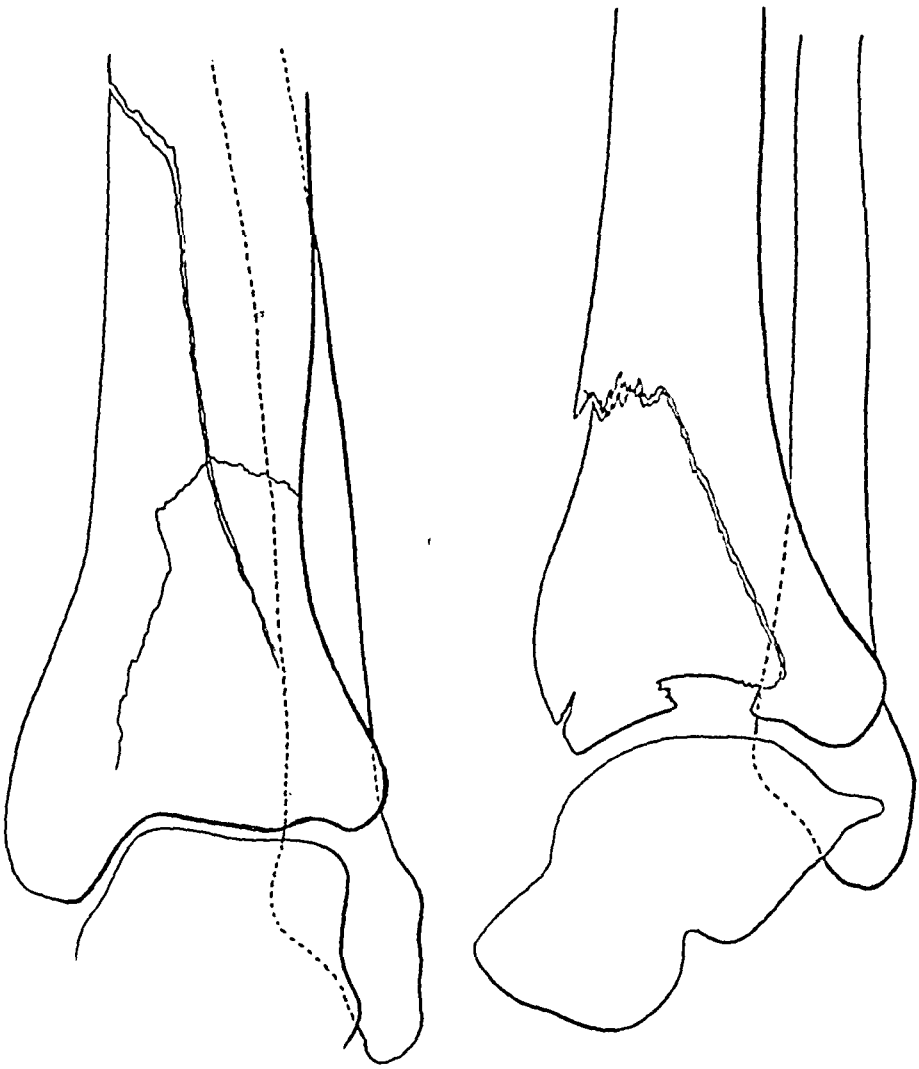

Fig. 45.—Comminuted fracture of tibial plafond; from compression upward.

gen-ray findings. This lesion (fracture of the anterior tibial tubercle, or diastasis of the tibiofibular joint) must occur previous to, even if nearly simultaneously with, the oblique fracture of the fibula;[47] because

47. Lapointe (Souligoux: Bull. et mém. Soc. de chir. de Paris **44**:1042, 1914) quite justly contends that if fracture of the anterior tubercle can occur as an isolated lesion (as in the case he reported), it must be admitted it may also occur as the first lesion of a more complicated fracture.

after the fibula is fractured its lower fragment (on which alone the force is acting) is already detached from the anterior tubercle of the tibia, and a continuance of the force would merely increase the separation. Moreover, there is lack of displacement in these isolated oblique fractures of the fibula merely because to permit displacement it is necessary that the internal malleolus (or its ligament) previously give way. If a tibiofibular diastasis (with or without separation of the tubercle) occurs (and if it occurs it must always occur previous to a fracture of the fibula, as already remarked), then the fracture of the fibula (by torsion still) occurs not through the inferior tibiofibular joint but above it, sometimes through its surgical neck, often through its true neck in the upper third of the fibula, as originally pointed out by Maisonneuve. That such a lesion in the upper third of the fibula can occur without appreciable bony lesion at the ankle cannot be denied. We have two such cases; and Quénu [48] went so far as to say that many more such fractures occur without diastasis than with it; and that they may occur even without any lesion at all at the ankle joint (Fig. 15).[49] It must also be recognized that diastasis is not necessarily followed by fracture of the fibula at any level, as shown in the lesion represented in Figures 16 and 17 in which the fibula detached the anterior inferior tubercle of the tibia, and in which, after rupture of the internal lateral ligament had occurred, the fibula was forced by the astragalus around back of the tibia by continuance of external rotation of the foot, as in the mechanism described by Huguier [50] (1848), though in his cadaveric experiments, as well as in the case illustrated by Destot (Fig. 67, p. 142 of his monograph), this displacement was accompanied by (and I believe succeeded by) a fracture of the upper end of the fibula.

In rare instances, the avulsing force on the internal malleolus may be so great as to cause fracture of the entire lower end of the tibia (or in children a separation of the epiphysis [51]): this appears to have been the mechanism in four of our cases, which on a purely anatomic classification should perhaps be grouped with the supramalleolar fractures (Figs. 18 and 19).

The significance of the posterior marginal fragment, and the mechanism by which it probably is produced, will be discussed in another place (p. 112).

---

48. Quénu: Rev. de chir. **35**:897, 1907.

49. Long recognized as possibly due to pull of the biceps muscle. See a study by Lonhard (*Deutsche mil.-ärztl. Ztschr.* **43**:219, 1914).

50. Huguier: Union méd., Paris **2**:120, 1848.

51. In addition to the 300 cases of fracture of the ankle listed on page 122, we have records of at least nine cases diagnosed as epiphyseal separations; but as in these the roentgenograms available showed no gross separation at the epiphyseal line of the tibia, we have not included them in our statistics.

I desire to return now to the movement of *forced abduction,* a discussion of which has been intentionally postponed until disposition had been made of the much more frequent mechanism (outward rotation). We find in any large series of fractures at the ankle a certain number in which fracture of the internal malleolus is the only lesion (in our series this lesion occurred in more than 6.5 per cent. of the whole number). Now it is not rational to suppose that the same mechanism which at one time causes an isolated oblique fracture of the lower end of the fibula will at another cause an isolated fracture of the internal malleolus: they must be produced by different mechanisms. Experi-

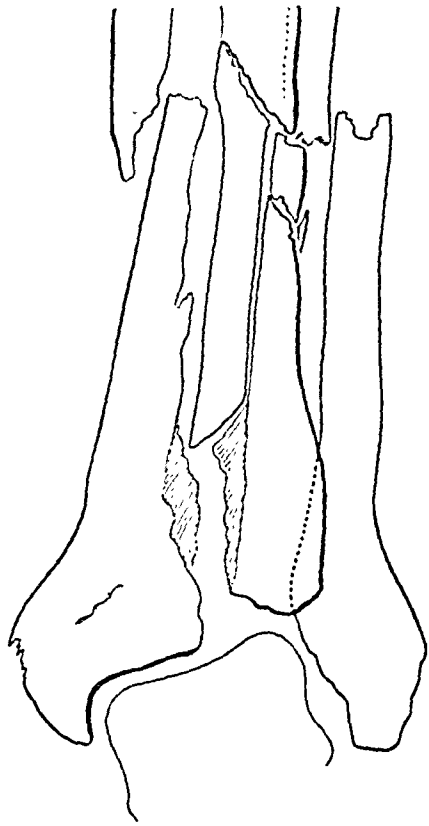

Fig. 46.—T or Y fracture involving ankle joint; from compression upward.

mentally, it is very clearly seen (note the experiments of Hönigschmied, detailed on page 72, that straight abduction (fibular flexion) of the foot has as its primary and most constant lesion fracture of the internal malleolus, or its equivalent, rupture of the internal lateral ligament. This is a prerequisite in order to free the astragalus sufficiently so that it may press directly on the external malleolus, which it does by rotation around an anteroposterior axis. The experiments of Bonnet [52] (1845), have been overlooked by most students. He showed, long

52. Bonnet: Traité des maladies des articulations, Lyon **2**:428, 1845.

before Tillaux or Hönigschmied, that abduction (fibular flexion) of the leg, while the foot was held in a vise, caused: first, fracture of the internal malleolus or rupture of the internal lateral ligament (Fig. 20), and, if the abduction was increased, a crushing or fracture of the external malleolus (Fig. 21), never of the fibula above the inferior tibiofibular joint. But sometimes no lesion of the external malleolus was caused even when the internal malleolus was widely separated. If, on the other hand, abduction of the foot was produced with the leg lying on its fibular side, but with the foot projecting free of the table, the same lesions occurred at the internal malleolus; but the fibula broke above the inferior tibiofibular ligaments at the point where it rested on the table.

In the mechanism of these fractures by abduction the influence of the tibiofibular ligaments is paramount:

1. If the tibiofibular ligaments hold, the fibula breaks across through the external malleolus proper (i.e., below the tibiofibular ligaments) and not above these ligaments by that "preposterous and untrue" mechanism to which Nancrede objected, namely, the inward bending of the fibula toward the tibia. It is not proper, perhaps, to deny that the latter mechanism might sometimes occur (all things are possible) in a patient with exceedingly relaxed ligaments; but I feel strongly inclined to state in the words of Souligoux (applied by him to the existence of an isolated fracture of the posterior tibial margin) that I do not believe such a mechanism exists, and will not believe it exists until somebody shows me its method of production. Of the 300 fractures which we have studied, we find only thirteen cases which seem to belong to this type (bimalleolar fracture by abduction): evidently the more nearly the movement of the foot conforms to the type of straight abduction, the more apt is diastasis, and as a consequence, fracture above the tibiofibular ligaments to occur (see below); while the more nearly it corresponds to external rotation (deviation of the point of the foot outward), the more certain is the fracture to be oblique in type, involving the inferior tibiofibular joint, but, as already explained, causing no true diastasis; hence the extreme rarity of true bimalleolar fractures by abduction (Fig. 22).[53]

2. If the tibiofibular ligaments rupture, then the fibula is freed from the tibia, and if the force continues (in life it is now the weight of the body borne chiefly, or at least abnormally, on the fibula), the fibula breaks "by flexion" and the break usually occurs where the fibula is weakest, through the surgical neck above the inferior tibiofibular ligaments. Study of roentgenograms or museum specimens of fractures

53. Mention has already been made (p. 99) of isolated fracture of the external malleolus associated with fracture of the calcaneum (Fig. 23).

of this type shows clearly two things: an evident tibiofibular diastasis, and a flexion fracture (Biegungsbruch) of the fibula. The typical mechanism of the flexion fracture is illustrated in Figure 24 (p. 79), copied from Messerer; and though at first glance some roentgenograms of fractures of the fibula at this height may not seem to indicate this mechanism clearly, more careful study (in nearly every case, at least, with which I am familiar) shows that the fracture conforms to the Biegungsbruch type: thus the line of fracture is either nearly transverse (rare), slightly oblique (frequent, Fig. 25), or (very frequent) is comminuted in the typical manner, with detachment of a wedge-

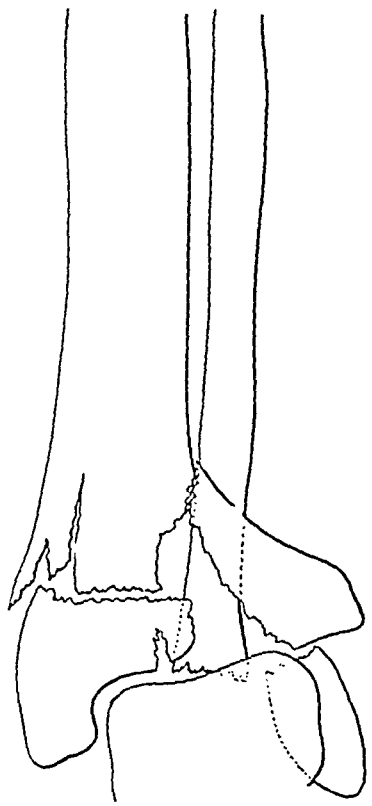

Fig. 47.—T or Y fracture involving ankle joint; from compression upward.

shaped fragment from the concavity of the bent bone (Figs. 26 and 35); that is to say, the wedge is on the lateral border of the fibula (apex toward the tibia) if the fibula was broken by straight abduction of its lower end, or on the posterior border (apex anteriorly) if it broke by posterior displacement of its lower end (Figs. 34 and 36).

Now it is a prerequisite for a bone (or any other similarly shaped structure) to be broken by indirect force through bending that one of its ends must be fixed and the other end movable. The upper end of the fibula is fixed by its attachments at the superior tibiofibular joint

and by the interosseous membrane; and to permit fracture by bending of its shaft, under such circumstances, by means of indirect force applied to the external malleolus, it is first of all necessary that the lower end of the fibula be freed from its attachments to the tibia. If these attachments are not freed, it is extremely unlikely that a fracture by bending can occur; though it is possible to conceive of an exceptional instance in which such an event might occur, as, for instance, if the surgical neck of the fibula (as in the second mechanism described by Bonnet) were pressed against the edge of a table or similar object by abduction of the foot; but in such a case the action of direct violence in causing the fracture could not be excluded. In life it would be less unlikely for a fracture by compression to occur (the force being transmitted in the long axis of the fibula which was still rigidly attached to the unbroken tibial shaft); whereupon the fracture would present a very different appearance (Fig. 15); or even less unlikely for a fracture by torsion to occur, though for this mechanism also it is necessary for the two ends of a bone to be movable in opposite directions or for one to be fixed and the other movable. Torsion was held by Maisonneuve (and no doubt correctly) to be the mechanism by which was produced the fracture in the upper third of the fibula described by him as "fracture par diastasis;" and it is this mechanism (torsion) which causes it to be situated so close to the fixed end of the bone,[54] and which makes me class it as a variant of the fracture "by outward rotation of the foot" already discussed; and which convinces me that it does not belong in the same class with fractures produced by straight abduction of the foot, in which cases, I repeat, the fracture of the fibula occurs in its lower third and is caused by a bending mechanism.

It is true, of course, that the force may cease to act before the fibula breaks; in which case merely a diastasis results (Fig. 27).

Careful study of thirty cases of fracture of the fibula through its surgical neck in our series has shown the characteristics of a fracture by bending in all except two cases, in which it was clearly by torsion. When this lesion (by whatever mechanism) was unaccompanied by a diastasis of the inferior tibiofibular joint (or its equivalent, detachment of the anterior tubercle of the tibia), then the history has shown (in all but one case in which the history is unknown) either that the fracture was due to direct violence (Fig. 28) or that the clinical signs of a tibiofibular sprain were present though no diastasis was shown by the roentgen ray. Quénu[55] (1912), however, for whose opinion every student of fractures has great respect, held that diastasis was not a neces-

54. Once the lower end of the fibula is freed from the tibia, the interosseous membrane presents no obstacle to torsion.

55. Quénu: Rev. de chir. **45**:242, 1912.

sary accompaniment of this type of fracture, though he acknowledged its extreme frequency, a fact to which he had called attention in 1909; and as early as 1907, he had pointed out that this type of fracture was that which was most frequently accompanied by diastasis. But he was at that time (1907) inclined to the view that the fracture of the fibula occurred simultaneously with or even before the diastasis. But Destot [56]

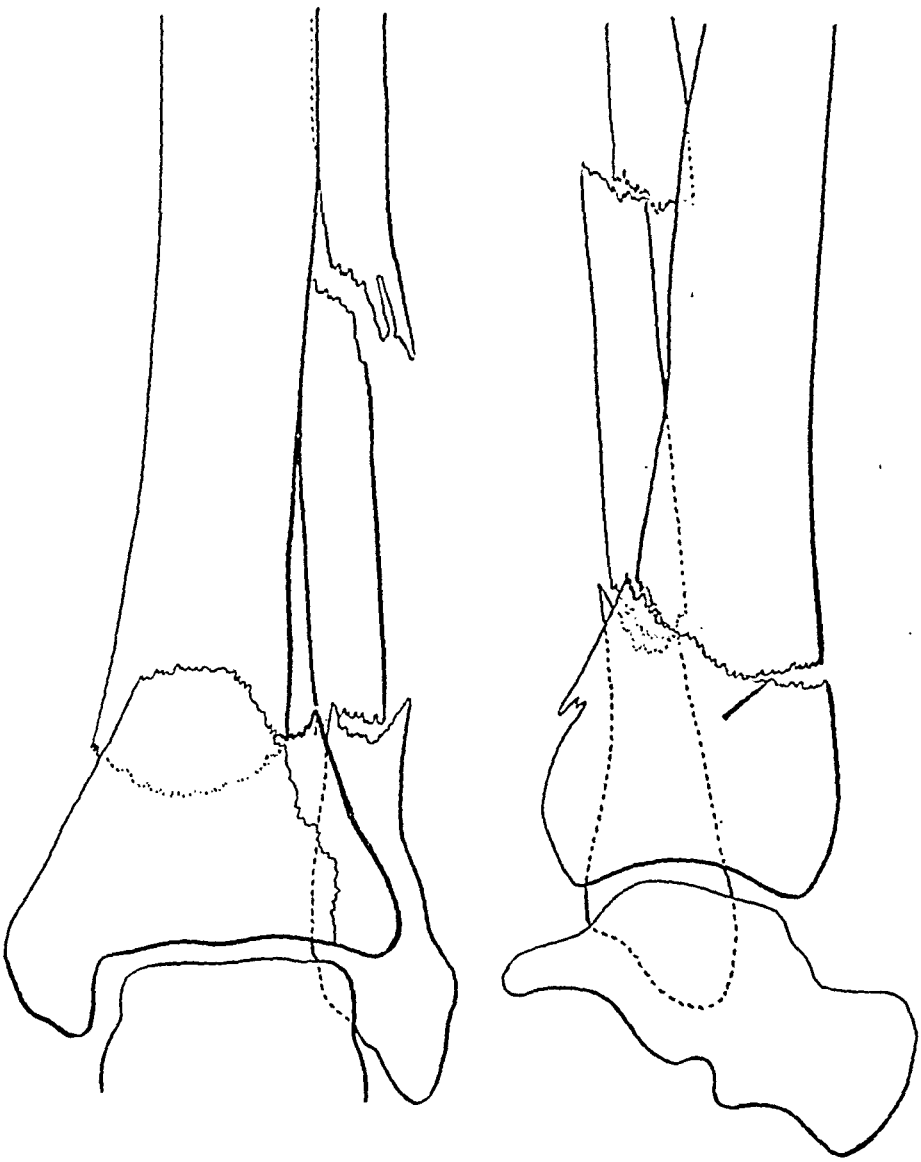

Fig. 48.—Comminuted supramalleolar fracture; probably by direct violence.

(1912) is firm in his belief that fracture of the fibula above the inferior tibiofibular joint demands as a preliminary a sprain or a diastasis of that joint. Is not then the legend to Figure 67, p. 142, in his monograph

56. Destot: Lyon chir. **8**:245, 1912.

(1911) inaccurate when it states that the diastasis shown was possible only because of the existence of a fracture near the head of the fibula?

Finally, as in fractures by outward rotation, the most advanced stage of abduction fractures may be regarded as one in which the entire lower end of the tibia is torn off as the representative of the internal malleolus; but in these also the fibula breaks characteristically by flexion through its surgical neck (Fig. 29)—it is not a mixed oblique fracture as in the third degree of fracture by external rotation already described (Figs. 18 and 19).



Fig. 49.—Anteroposterior view of ankle joint. See page 124.

Diastasis and Lateral Displacements of the Foot.—It is well to analyze more carefully what is meant by diastasis of the inferior tibiofibular joint.[57] It is easily seen in the prepared specimen that in all movements of the foot there is greater strain on the anterior than on the posterior inferior tibiofibular ligament; and that if the anterior

57. The criteria of diastasis from a roentgenographic study will be discussed by Dr. Bromer in his appendix to this paper.

ligament alone is divided, a separation of the fibula from the tibia to the extent of about 1 cm. becomes possible anteriorly, the fibula still being attached by the interosseous ligament and the posterior tibiofibular ligament. This degree of separation is sufficient to constitute a diastasis; lesser degrees, with incomplete rupture of the anterior tibiofibular ligament, and therefore without separation, constitute a sprain. But in many cases in which a temporary diastasis (disjunction) may have been present at the moment of the accident, it is no longer present when the

Fig. 50.—Lateral view, plantar flexion.

patient comes under the surgeon's care or is sent for roentgenologic study; and at the latter time can only be presumed to have existed by certain signs, especially evidences of a sprain fracture or detachment of the anterior tubercle of the tibia (Fig. 30).

If, in addition to division of the anterior tibiofibular ligament, one divides also the feltlike interosseous ligament, then a separation of the fibula from the tibia almost to the distance of 3 cm. may be possible; but even with this amount of diastasis of the anterior border of the fibula from the tibia, these bones are still united by the posterior tibio-

fibular ligament, so that the fibula is not entirely freed from the tibia though its lower end has become so movable as easily to permit a fracture by flexion.

Section of the posterior inferior tibiofibular ligament, as, indeed, noted by Quénu [58] (1907) permits only an insignificant separation of the fibula and tibia; and Quénu thinks that in life rupture of this ligament never occurs—at any rate it seems certain that this ligament is never ruptured alone, but only in conjunction with rupture of the anterior and interosseous ligaments. It is to be noted furthermore that it is next to an unheard of thing for the astragalus to be separated from the external malleolus, owing to the almost indestructible posterior band of the external lateral ligament; so that diastasis is not produced by a wedgelike action of the astragalus described by so many writers. I know of no case of true ascent of the astragalus between the tibia and fibula unaccompanied by the external malleolus: even in the beautiful case of diastasis recorded by Millikin,[59] though it is truly said that "the astragalus was jammed up between the outer surface of the tibia and the unfractured fibula" yet the astragalus had not been detached from the fibula and, therefore, cannot have acted as a wedge in driving the bones apart, though it certainly acted as a prop to keep them asunder. I have been at pains to reproduce this lesion on the cadaver, demonstrating that it is quite possible for the astragalus to become lodged against the outer surface of the tibia, between the latter bone and the fibula, without rupture of the posterior band of the external lateral ligament; though, of course, it is necessary to divide the internal lateral ligament and the inferior (anterior and posterior) tibiofibular ligaments, as well as the interosseous ligament and the interosseous membrane (the latter as far up as the upper third of the leg). And unless, in addition to the above, the anterior and middle bands of the external lateral ligament were divided, the astragalus maintained itself only in very unstable equilibrium between tibia and fibula; though no doubt in life, the stability would be greater owing to muscular tension. Moreover, in the type of fracture with diastasis in which the fibular fragment is accompanied by a fragment detached from the external surface of the tibia (as in Cooper's illustration copied by Vidal de Cassis), and which is usually described as exhibiting ascent of the astragalus between the bones of the leg, or along the outer side of the tibia, the astragalus carries with it the external malleolus (the lower fibular fragment), so that in no true sense has the astragalus ascended between the bones. Of course, it is true that dislocation of the astragalus may occur, forward or backward, detaching it from the fibula; and there is no

58. Quénu: Rev. de chir. **35**:897. 1907.
59. Millikin: Ann. Surg. **69**:650, 1919.

denying the possibility of its being dislocated upward between the intact tibia and fibula. All that I contend is that for it to become detached from the external malleolus in fractures of the leg bones at the ankle must be extremely rare, as there does not appear to be any such case on record.[60]

The Posterior Marginal Fragment of the Tibia, and Posterior Displacement of the Foot.—The existence of this fragment as the sole osseous lesion in a certain number of cases now on record,[61] including one of our own, proves that it may be the earliest stage of a lesion involving the ankle joint. But as there never has been any displace-

Fig. 51.—Lateral view, dorsiflexion.

ment of the fragment in these isolated lesions, it cannot be considered of much importance unless associated with a fracture of the fibula. As already noted, the existence of this fragment as a complicating lesion was well known to Cooper; it was noted by Earle[62] (1828) and by

60. Gross (System of Surgery, Ed. 5, Philadelphia **2**:85, 1872) says Druitt refers to such a case, but I have been unable to find the original report to ascertain the exact lesions. Wendel (Beitr. z. klin. Chir. **21**:146, 1898) collected five cases of upward dislocation without fracture; but the exact lesions do not appear to have been determined definitely in any case.

61. Tanton (Footnote 29, p. 165) refers to twenty cases recorded prior to 1916. As an isolated lesion it was first observed by Meissner (Beitr. z. klin. chir. **61**:136, 1909).

62. Earle: Lancet **2**:346, 1828-1829.

Adams [63] (1835); it was observed at necropsy by Dupuytren "with surprise" according to Malgaigne [64] (1832); Thaon [65] presented a necropsy specimen and said he had often seen this fragment in experiments made by Tillaux; it was clearly and accurately if succinctly described by Nélaton [66], (1847), and the fragment was recognized as a serious complication by Edmund Andrews [67] (1883, 1897). Since the introduction of the roentgen ray, it has been studied by Chaput [68] (1899, 1907), Bondet [27] (1899), Grashey [69] (1907), Meissner [61] (1907), Plagemann [70] (1911), Destot [8] (1911), Quénu (1912-1915), and by Stimson (in every edition of his book since 1899). Hence it was with surprise that surgeons who were tolerably familiar with the literature of their profession, as well as with fractures of the ankle, saw Cotton [71] (1915) describe it as "a new type of ankle fracture" which "has never been adequately described in print and has apparently escaped the notice even of those who deal with fractures habitually;" and noticed his complacent comment that in certain circles it was called "Cotton's fracture;" as well as his statement that he believed there were no necropsy specimens.[72] Cotton, however, did well to call attention to its frequency; as did Speed in a paper which was not published until after Cotton's paper was read, though it appeared in print before the latter.

The mechanism by which this fracture is produced is almost certainly, as contended by Lucas-Championnière,[73] a crushing force from below upward;[74] it is possible that traction by the posterior inferior

63. Adams, in Todd: Cyclopedia of Anatomy and Physiology, London **1**:161, 1835-1836.

64. Malgaigne: Gaz. méd. de Paris **3**:647, 1832.

65. Thaon: Bull. Soc. anat. de Paris **45**:212, 1870.

66. Nélaton: Eleménts de path. chir., Ed. 2, Paris, **3**:296, 1874.

67. Andrews in Ashhurst: International Encyclopedia of Surgery, New York **3**:707, 1883; also in Internat. Clinics, Philadelphia, 1897.

68. Chaput: Bull. et mém. Soc. de chir. de Paris **25**:776, 1899; Les fractures malleolaires, Paris, 1907.

69. Grashey: Fortschr. a. d. Geb. d. Röntgenstrahlen. **11**:152, 1907.

70. Plagemann: Beitr. z. klin. Chir. **73**:688, 1911.

71. Cotton, F. J.: A New Type of Ankle Fracture, J. A. M. A. **64**:318 (Jan. 23) 1915.

72. In addition to the necropsy specimen which figures in Cooper's Plate XVII (reproduced here as Fig. 3), those described by Stimson and that of Thaon, already alluded to, there are in the Mütter Museum of the College of Physicians of Philadelphia three necropsy specimens showing this posterior marginal fragment. The most recent of these specimens has been in the museum for a period at least of forty years. (A description of these specimens will be published elsewhere by Dr. Bromer and myself.)

73. Lucas-Championnière: Bull. Soc. anat. de Paris **45**:212, 1870.

74. Rochet (Rev. d'orthop. **1**:269, 1890) produced it experimentally by dropping a weight of 60 kilograms, from a height, on the upper end of the tibia while the foot was in plantar flexion.

tibiofibular ligament, through the medium of the fractured lower end of the fibula, may aid in displacing the fragment, even if it cannot be the sole cause of its detachment. The size of the fragment varies from a small portion of the lip to a large fragment, extending 10 cm. up the posterior surface of the shaft. McKnight, at the meeting of the Philadelphia Academy of Surgery, May 2, 1921, showed a roentgenogram (anteroposterior view only) of a fracture which I believe conformed to this type, though the fragment was the largest with which I am acquainted: the fragment (an isolated lesion, without displacement) included nearly all the posterior lip of the tibia, as well as its entire lateral (fibular) border; and the apex of the large wedge extended to a point about 10 cm. above the articular surface, on the posterolateral border of the tibia.

TABLE 1.—INCIDENCE OF POSTERIOR MARGINAL FRACTURES

	Total Ankle Fractures	Posterior Marginal Fractures Associated	Isolated	Total	Per Cent.
Ashhurst and Bromer	300	57	1	58	19
Chaput (Les fractures malléolaires, Paris, 1907)	136	42	0	42	30
Destot (Quénu: Bull. et mém. Soc. de chir. de Paris, **39**: 165, 1913)	1700	139	6	145	8.5
Quénu (Rev. de chir. **45**:260, 1912)	129	11	1	12	9.3
Sear (M. J. Australia, **1**:526, 1917)	156	26	3	29	18.6
Speed (Surg., Gynec. & Obst. **19**:73, 1914)	161	16	0	16	10

INCIDENCE OF ASSOCIATED POSTERIOR MARGINAL FRACTURES

Type	Ashhurst and Bromer No.	Ashhurst and Bromer Per Cent.	Destot No.	Destot Per Cent.
Fibula, oblique mixed	0	....	0	....
Low Dupuytren	51	88	89	64
Bimalleolar	0	....	17	12
Pott's	5	8.6	29	20
Adduction	1	1.7	0	....
Maisonneuve	0	....	4	3
	57		139	

The lesion corresponds, as Tanton[29] (loc. cit., p. 171) has noted, to Rhea Barton's fracture of the posterior margin of the radius.

It is a much more frequent complication than commonly supposed. Among our 300 cases it was present no less than fifty-eight times, or in 19 per cent. of all the cases; and in 51, or 50 per cent., of those conforming to the "low Dupuytren" type.

There is sometimes confusion between this posterior marginal fragment and the intermediate fragment ("third fragment of Tillaux"),

as remarked before.[23] The posterior tubercle of the tibia, which limits posteriorly the gutter for the reception of the fibula (Fig. 4), and to which is attached the posterior tibiofibular ligament, may be fractured by the pull of this ligament. It appears then in lateral roentgenograms as an infraction or sprain fracture, but does not involve the ankle joint. In the true marginal fractures, on the other hand, the line of fracture always extends into the tibial plafond; the fragment (contrary to what is said by Tanton) usually remains attached to the external malleolus



Fig. 52.—Rotation outward, obliterating outline of the posterior tubercle. (Same happens in mesial deviation of the tube.) The anterior tubercle overlaps the lateral margin of the fibula.

by the posterior tibiofibular ligament, and is often displaced backward with the external malleolus; sometimes (more frequently than thought) it may be detected in anteroposterior roentgenograms as a deltoid fragment; and, if large, its shadow sometimes overlaps that of the median border of the tibia, giving a double contour.

The posterior marginal fragment, as already remarked, may occur as an isolated lesion; only once in our series (Fig. 44). It may be

associated with (*a*) merely a diastasis, with sprain fracture of the anterior tubercle of the tibia (Fig. 31); (*b*) it may accompany the mixed oblique fracture of the fibula in the various stages of the fracture by outward rotation, being small (Fig. 32), medium sized (Fig. 33), or large (Fig. 34); and (*c*) it occurs also with fractures by abduction (Figs. 35 and 36), though very much less frequently than with external rotation fractures. Quénu has had one case in which fracture of the internal malleolus was the only other lesion, and another fracture of precisely the same type has come under our notice since our series of 300 cases was completed.

Its presence is not necessary to permit the occurrence of posterior displacement of the foot (Figs. 16 and 25), but certainly favors it. This posterior displacement is very rare without the posterior marginal fragment. Either a posterior marginal fragment must exist, or there must be rupture of the posterior inferior tibiofibular ligament. It is only a continuance of the force (now the weight of the body) after the fracture has been produced, that causes the displacement, since there are in our series no less than fourteen instances (out of a total of fifty-eight posterior marginal fractures) with slight if any displacement.

The factors which permit posterior displacement of the foot deserve a few words. Quénu was the first, I believe, to point out that the essential lesion is freeing the lower end of the fibula from the tibia; and I may remark that this necessity is merely a corollary of what has been insisted on so often in these pages, namely the indissolubility of the union between the astragalus and the fibula. I cut everything else at the ankle (tendons and ligaments as well as all other soft parts) leaving only the middle and posterior bands of the external lateral ligament attaching the external malleolus to the foot. Under these circumstances even an incomplete posterior dislocation of the foot cannot occur (except by rotation of the foot inward around the long axis of the leg, a mechanism which does not occur in life). I then cut the middle band of the external lateral ligament; but still no posterior displacement could be produced. Next I fractured the fibula 7.5 cm. (3 inches) above its tip; but this did not permit posterior displacement. Finally, I divided the anterior inferior tibiofibular ligament, and even the interosseous ligament; but so long as the fibula remained attached to the tibia, and the atragalus to the fibula, no posterior dislocation could be produced. On another foot, I divided all structures uniting the foot to the fibula except the middle band of the external lateral ligament; but no dislocation of the foot was possible; then I divided also the posterior inferior tibiofibular ligament and the interosseous ligament (which allowed less diastasis than when the anterior tibiofibular ligament was divided), but still no posterior dislocation of the foot was possible except by rotating it inward around the one remaining ligament as a pivot.

As a result of these investigations, it may be concluded that either the middle or the posterior band of the external lateral ligament is sufficient to hold the astragalus against the external malleolus, and that (even after fracture of the internal malleolus or rupture of the internal lateral ligament) *no backward dislocation of the foot can occur* (1) unless the astragalus is freed from the external malleolus by rupture of both the middle and posterior bands of the external lateral ligament (a lesion which apparently has not been recorded in association with

Fig. 53.—Rotation inward; very little change from the normal. (Same happens in lateral deviation of the tube.)

fractures at the ankle); (2) or unless the external malleolus is freed from the tibia (*a*) by diastasis of the inferior tibiofibular joint, with or without detachment from the tibia of an intermediate fragment; (*b*) by fracture of the fibula in such a way as to detach with the lower fragment of the fibula the fibular insertions of both the middle and posterior bands of the external lateral ligament (in other words, unless a virtual diastasis occurs, but one in which the intermediate

fragment belongs to the fibula instead of to the tibia). One very frequent fracture of the fibula (the mixed oblique of Destot) fulfils these requirements; as does another less usual, namely a transverse fracture of the external malleolus proper below the level of the tibia. But as the latter fracture usually is subperiosteal or incomplete, and without displacement, it follows that posterior displacement of the foot with this lesion is unknown.

Therefore, the fractures which may be accompanied by posterior displacements of the foot are those of the Pott or Dupuytren type, in which diastasis is the rule; and those of the low Dupuytren variety, in which the fracture of the fibula is of the mixed oblique type. Quénu [75] is wrong, I am sure, in claiming (1912) that the existence of a posterior marginal fragment is a necessary condition for the occurrence of a posterior subluxation (Figs. 16 and 25); but it is well to remember that the distorted shadows of a roentgenogram in a case of fracture of the low Dupuytren variety, in any of its stages, may mislead the observer into the belief that a posterior displacement is present, when the appearances are due entirely to an outward rotation of the astragalus around the long axis of the leg.

Forced Movements of Adduction (Tibial Flexion).—Since the time of Cooper and that of Maisonneuve and Bonnet, there has been little dispute about the mechanism of these fractures: it has been generally recognized that a tearing off of the external malleolus is the first lesion (Fig. 37), followed by a compression fracture of the internal malleolus (Figs. 38 and 39); or, when the weight of the body forces the tibia heavily on the displaced astragalus, a splitting upward of the tibial shaft occurs, the line of fracture commencing at some point of the articular surface, splitting this in the sagittal plane and terminating on the median border of the tibia at a variable distance above the internal malleolus (Figs. 40, 41 and 42). The more nearly longitudinal the line of fracture, the less necessary will it be for the external malleolus to be fractured as a preliminary step: such fractures verge into those due to comminution upward in the long axis of the limb. Stimson [76] (1912) gives an admirable illustration of such a longitudinal fracture of the tibia without any lesion of the fibula. But if the displacement in these longitudinal fractures is marked enough, the fibula may break secondarily (by flexion or torsion) above the inferior tibiofibular joint, as the lower end of the fibula is carried inward with the astragalus (Fig. 41). A variant of this type is the lesion recorded by Silhol [77] in which the fibular fracture is replaced by an intermediate

75. Quénu: Rev. de chir. **46**:1912.
76. Stimson: Fractures and Dislocations, Ed. 7, Philadelphia, 1912, Plate 27.
77. Silhol: Bull. et mém. Soc. de chir. de Paris **42**:819, 1916.

fragment detached from the tibia. Even in one of our own cases (Fig. 40), there is an intermediate fragment, in addition to the fracture of the fibula.

The supramalleolar fracture by adduction, produced experimentally by Tillaux, and already mentioned on page 71, may be considered the most advanced degree of this type (Figs. 42 and 43.)

SUMMARY

These then are the abnormal movements—external rotation, abduction, adduction—which are responsible for the great majority (95 per cent.) of fractures about the ankle: external rotation causes about 61 per cent., abduction about 21 per cent., and adduction about 13 per cent. of the lesions. The remaining small proportion (5 per cent.) consists chiefly of those fractures which may be recognized either as caused by compression in the long axis of the limb, or by direct crushes; or even by very rare forced movements such as straight flexion or extension, internal rotation, etc. The fractures by compression in the long axis of the limb include (*a*) the isolated fractures of the tibial margins (anterior, posterior [Fig. 44], median or even lateral), which Sear [78] speaks of as "vertical plane fractures;" (*b*) comminuted fractures of the tibial plafond (Fig. 45), and (*c*) T or Y-fractures involving the ankle joint (Figs. 46 and 47), which may be regarded as an advanced degree of the supramalleolar V-fractures described by Gosselin,[79] the latter usually being complicated by a fissure extending into the ankle joint, the mechanism being the same as in those of the radius with comminution of the wrist fragment.[80] The supramalleolar fractures of Malgaigne [81] (1847) are thus distributed according to their mechanism, some into those by adduction, others as due to compression in the long axis of the limb, and a few probably due to direct violence (Fig. 48). We count no supramalleolar fracture as one involving the ankle unless it falls within 4 cm. of the joint level (Richet, 1875). Fractures as close to the ankle joint as 4 cm. compromise its functions as surely as do supracondylar fractures of the humerus compromise those of the elbow.

Now, it is because of the impossibility of classifying together anatomically lesions which, as Stimson says, are merely alternative, or whose differences are due to the early cessation of the force before the typical form has been reached; or, I may add, to its continuance after the typical stage has been passed—it is because of this impossibility, I

78. Sear: M. J. Australia **1**:526, 1917.
79. Gosselin: Gaz. d. hôp. **28**:218, 1855.
80. Gosselin: Bull. et mém. Soc. de chir. de Paris **5**:147, 1863.
81. Malgaigne: Fractures, Paris, 1847, p. 818.

repeat, that I believe a classification based on mechanism, imperfect though it be, is, nevertheless, more easily understood and remembered. And it is for this purpose that Dr. Bromer and I have ventured to

TABLE 2.—CLASSIFICATION OF THREE HUNDRED ANKLE FRACTURES

A. Fractures by External Rotation		
1. First Degree: Lower end of fibula only ("mixed oblique")	79	(26 %)
2. Second Degree: Same, *plus* rupture of internal lateral ligament or fracture of internal malleolus ("low Dupuytren")	100	(33 %)
Viz.,		
(*a*) Internal lateral ligament, uncomplicated	13	
Internal lateral ligament complicated by posterior marginal fragment of tibia	13	
(*b*) Internal malleolus, uncomplicated	32	
Internal malleolus complicated by posterior marginal fragment of tibia	42	
3. Third Degree: Same, *plus* fracture of whole lower end of tibia, representing the internal malleolus	5	(1.7 %)
Total Fractures by External Rotation	184	(61 %)
B. Fractures by Abduction (Fibular Flexion)		
1. First Degree: Internal malleolus only	20	(6.6 %)
2. Second Degree: Same *plus* fracture of fibula (transverse, above or below tibiofibular joint)	41	(13.7 %)
(*a*) Below inferior tibiofibular joint (no diastasis) ("bimalleolar fracture")	13	
(*b*) Above inferior tibiofibular joint (with diastasis) ("Pott's fracture," "Dupuytren type")	28	
3. Third Degree: Internal malleolus represented by whole lower end of tibia	2	(0.66%)
Total Fractures by Abduction	63	(21 %)
C. Fractures by Adduction (Tibial Flexion)		
1. First Degree: External malleolus only, transverse, at or below level of tibial plafond	27	(9 %)
2. Second Degree: Same, *plus*		
(*a*) Internal malleolus below level of tibial plafond ("bimalleolar fracture")	3	
(*b*) Median surface of tibia up and in from joint surface	8	11 (3.6 %)
3. Third Degree: Same, *plus* whole lower end of tibia ("supramalleolar fracture by adduction")	2	(0.66%)
Total Fractures by Adduction	40	(13.3 %)
D. Fractures by Compression in Long Axis of Leg		
1. Isolated Marginal Fractures	1	
2. Comminution of tibial plafond	3	
3. T or Y-fractures ("V-fractures of Gosselin")	4	
Total Fractures by Compression in Long Axis of Leg	8	(2.7 %)
E. Fractures by Direct Violence (Supramalleolar types)	5	(1.7 %)

arrange our series of fractures as shown in Table 2. Our aim has been to place under each mechanism, first, the simplest resulting form of fracture, and to advance thence to more complicated lesions,

noting at the same time in their appropriate places the variants and the complications of the simple or the more complex lesions which were encountered. It is true that it is not always easy to determine the mechanism, even with all the aid derived from the clinical history, the roentgen ray and a knowledge of the lesions which can be produced on the cadaver; but the more one studies the subject, the fewer exceptions he will find to the general laws of mechanics; and the more his

TABLE 3.—ANATOMOPATHOLOGIC CLASSIFICATION OF THREE HUNDRED ANKLE FRACTURES

A. Fibula, Below Inferior Tibiofibular Joint				
1. Alone (slight or no displacement, often subperiosteal)	27	(9 %)		
2. Same, *plus* internal malleolus below tibial plafond (includes bimalleolar fractures by adduction and by abduction)	16	(5.0 %)		
3. Same, plus split of tibia up and in	8	(2.6 %)	51	(17 %)
B. Fibula, Obliquely Through Inferior Tibiofibular Joint				
1. Alone (slight or no displacement, often subperiosteal)	79	(26 %)		
2. Same, plus rupture of internal lateral ligament	26	(9 %)		
3. Same, *plus* fracture of internal malleolus	74	(25 %)	179	(60 %)
C. Fibula, Above Inferior Tibiofibular Joint				
1. Alone (slight or no displacement, often subperiosteal)	0	(.....)		
2. Same, *plus* rupture of internal lateral ligament and diastasis	8	(2.7 %)		
3. Same, *plus* fracture of internal malleolus and diastasis	20	(6.6 %)	28	(9.3 %)
D. Tibia, Involving Ankle Joint				
1. Internal malleolus alone (slight or no displacement, often subperiosteal)	20	(6.6 %)		
2. Isolated marginal fractures	1	(0.33%)		
3. Comminuted, T and Y-fractures	7	(2.3 %)	28	(9.3 %)
E. Supramalleolar Fractures, Not Involving Ankle Joint Directly	14	(4.3 %)	14	(4.3 %)

experience increases, the easier will it become to recognize the variants from the typical lesions. Those fractures which have given us most concern are the true bimalleolar fractures with little or no displacement. since these may be caused possibly by external rotation, certainly both by abduction and adduction. But as the total number of these fractures observed is small (sixteen cases or only 5 per cent. of the entire series), and as even among this number the mechanism was reasonably certain in all but ten cases (3 per cent. of the entire series), the margin of error is small.

TABLE 4.—CATALOG OF THREE HUNDRED FRACTURES INVOLVING THE ANKLE

	No. Cases	
A. By Rotation of the Astragalus Outward Around the Long Axis of the Leg		
I. First Degree: Lower end of fibula only. Oblique or spiral fracture from above and behind, down and front, the line of fracture passing through the inferior tibiofibular joint. Line varies from nearly transverse to nearly longitudinal, but is always higher on posterior than on anterior surface of fibula. In 84 per cent. of cases the lower anterior end of line of fracture was on anterior surface of external malleolus between its tip and the anterior inferior tubercle of the tibia; in 8 per cent. of cases it was above the anterior tubercle (when there was diastasis or the tubercle was detached); and in 8 per cent. it passed through the fibula at the level of the anterior tubercle on the tibia. Slight or no displacement	76	
Variant: fracture of fibula in *upper third* from lesion at ankle (Maisonneuve, 1840)	1	
(In this case there was incomplete fracture of fibula below its head (Fig. 17) but without bony lesion at ankle)		
Complication: intermediate fragment	2	
	—	79
II. Second Degree: Fibula as in first degree, *plus* rupture of internal lateral ligament or fracture of internal malleolus. There may be slight or considerable lateral displacement; but in uncomplicated cases there is rarely a real posterior displacement, the apparent posterior displacement seen in lateral roentgenographic views being due usually to outward rotation which distorts the shadows.		
(*a*) Internal Lateral Ligament (in roentgenograms this lesion is differentiated from first degree only by presence of lateral displacement of astragalus from internal malleolus with slight displacement of lower fibular fragment)	12	
Variant: Diastasis without fracture of fibula (Fig. 16)	1	
First Complication: Fracture of posterior tibial margin. Line of fracture usually extends about 2 cm. up along posterior surface of tibia, and running down thence nearly vertically, detaches a mere chip or more often one fourth to one third of the articular surface; rarely as much as one half	10	
Variant: Diastasis without fracture of fibula, but with posterior marginal fragment (Fig. 31)	1	
Second Complication: Intermediate fragment	0	
Third Complication: Second fracture of fibula in upper third (Maisonneuve's fracture; these two cases occurred in opposite legs of same patient)	2	
(*b*) Internal Malleolus	32	
(with slight or no displacement, twenty cases)		
First Complication: Fracture of posterior tibial margin (Figs. 32, 33, 34)	40	
(slight or no displacement, fourteen cases)		
(lateral and posterior displacement twenty-six cases)		
Second Complication: Intermediate fragment	2	
	—	100
III. Third Degree: Internal malleolus represented by whole lower end of tibia		5
(This will include most cases of separation of lower epiphysis of tibia)		
Total Fractures by Mechanism of Outward Rotation		184

TABLE 4.—CATALOG OF THREE HUNDRED FRACTURES INVOLVING THE ANKLE—(*Continued*)

		No. Cases
B. By Abduction (Fibular Flexion) of Foot		
I. First Degree: Fracture of internal malleolus only, transverse, at or below level of tibial plafond. No displacement		19
II. Second Degree: Rupture of internal lateral ligament or fracture of internal malleolus, as in first degree, followed by fracture of fibula more or less transverse either below or above inferior tibiofibular joint		
(*a*) Fracture of fibula below inferior tibiofibular joint (i.e., of external malleolus proper) with fracture of internal malleolus or rupture of internal lateral ligament (with no displacement, three cases; internal malleolus displaced more than external, four cases; both malleoli equally displaced, six cases)	13	
Variant: Crush of calcaneum (replacing fracture of internal malleolus) followed by compression fracture of external malleolus	1	
(*b*) Fracture of fibula above inferior tibiofibular joint (in lower third), the line of fracture indicating a fracture by flexion (Biegungsbruch), with slight or no torsion; slightly oblique, often comminuted with detachment of a wedge-shaped fragment from the surface of flexion, and its apex toward the surface of extension	28	
	—	42
1. Fracture of fibula alone, or with rupture of internal lateral ligament	6	
Variant: Diastasis without fracture of fibula	2	
2. Fracture of fibula with fracture of internal malleolus at or below level of tibial plafond	12	
First Complication: Posterior marginal fragment of tibia (Figs. 35 and 36)	5	
Second Complication: Intermediate fragment	3	
III. Third Degree: Internal malleolus represented by whole lower end of tibia (This will include some cases of separation of lower epiphysis of tibia)		2
Total Fractures by Mechanism of Abduction		63
C. By Adduction (Tibial Flexion) of Foot		
I. First Degree: Fracture of external malleolus, transverse, at or below level of tibial plafond. Slight or no displacement, often subperiosteal	26	
Complication: Posterior marginal fragment of tibia (infraction)	1	
	—	27
II. Second Degree: Fracture of external malleolus as in first degree, *plus:*		
(*a*) Fracture of internal malleolus below level of tibial plafond	2	
Variant: Fracture of external malleolus represented by rupture of external lateral ligament	1	
(*b*) Fracture of median surface of tibia up from tibial plafond	8	
	—	11
III. Third Degree: Fracture of fibula usually above inferior tibiofibular joint, *plus* fracture across tibia above ankle joint (Tillaux, 1872)		2
Total Fractures by Mechanism of Adduction		40
D. By Compression in Long Axis of Leg		
I. Isolated marginal fractures of tibia: anterior margin, none; posterior margin, 1; median margin, none; lateral margin, none	1	
II. Comminution of tibial plafond	3	
III. T or Y-fractures of Tibia into Ankle-Joint	4	
	—	8
E. Fractures by Direct Violence (Supramalleolar Types)		5
Grand Total		300

It will be noted that in our classification the fibular lesion dominates the clinical picture in the first two classes (those of outward rotation and abduction), and that these correspond to the first grand division of Destot's classification—those fractures in which the equilibrium of the foot is involved; while the third, fourth and fifth classes correspond to Destot's second division—those fractures which involve the tibial pestle and compromise the function of support. For the sake of completeness we also give an anatomopathologic classification, constructed on the same principles (Table 3).

Following the classifications is a catalog of the lesions encountered in this series of cases, which, with the aid of the classifications as a guide, we hope may prove of interest to students of fractures (Table 4).

ROENTGEN-RAY STUDY OF THE ANKLE JOINT

By Dr. Bromer

I. THE NORMAL ANKLE JOINT—ANATOMY

By means of the roentgen ray, the structure of the ankle joint can be most satisfactorily demonstrated. The tibiofibular mortise is shown (Fig. 49), and below it the trochlea of the astragalus fitting into it as a tenon. The "plafond" and the "cheeks" of the mortise are easily recognized, likewise the longer external malleolus and the anterior and posterior tubercles of the fibular groove. In the lateral view (Fig. 50), the low projection of the posterior lip, called by Destot the posterior malleolus, reinforcing the mortise posteriorly, can easily be visualized; and the point where it meets the trochlear surface of the astragalus, acting as a check on the latter when the foot is in plantar flexion as in walking, is most noticeable. (The degree of plantar flexion in the roentgenogram is much greater than is assumed in walking, but is used more fully to demonstrate the check). In this view, the longer external malleolus is shown overlapping the shadow of the internal malleolus. With stereoscopic plates they usually can be fairly well distinguished. The lateral tubercle on the posterior surface of the astragalus (os trigonum) is the farthest posterior shadow of the astragalus. In the interpretation of roentgenograms of the ankle joint, due care must be exercised not to diagnose a sprain-fracture of the posterior tubercle, where an accessory bone, the os trigonum, often is found. In general, no fracture exists, and it is this bone that is present if the surfaces of the fragment are smooth and rounded.

II. FUNCTION AND MOVEMENTS OF THE ANKLE JOINT

The roentgen ray can be used to demonstrate the movements of the ankle joint. Thus the rotation of the astragalus about the axis previously described by Dr. Ashhurst in full dorsiflexion and plantar flexion

is shown in Figures 50 and 51. The movements of the fibula were shown in the following way: A normal ankle was examined; the ankle and leg of the subject being securely bound to the table, a Bowen stereoscopic plate holder was placed beneath the ankle joint. Lateral views were made first with the foot in full dorsiflexion, then later with the foot in full plantar flexion. Great care was exercised that the position of the leg—i.e., tibia and fibula—was not altered. The stereoscopic plate holder gave an exact duplicate position for the second exposure. The tube was in no way shifted. Anteroposterior views were taken in the same way. In this plane, the heel was allowed to project as far as possible over the edge of the plate holder in order to obviate any change in height of the tibia above the plate due to change of position of the os calcis. The superior tibiofibular articulation was examined in the same way.

It was found that these views could be superimposed over diffused strong light. As an additional check the distances between the same relative points were accurately measured. The fact that the images of the tibia could be accurately superimposed would tend to rule out any possibility of error due to change in height of tibia. It was found that in full plantar flexion in the anteroposterior view the fibula moved inward and downward 1 mm. or, vice versa, so much expansion and movement upward occurred in full dorsiflexion. No change of the fibula in relation to the tibia could be found in the lateral views.

With regard to the upper extremity of the fibula, the forward movement of the fibula in plantar flexion was shown in the lateral view by an increase of 1 mm. in the distance between the posterior lip of the upper extremity of the fibula and the posterior border of the tibia. In the same way in the anteroposterior view the head of the fibula was found lying farther in toward the midline with the foot in plantar flexion than it was with the foot in dorsiflexion. All of these measurements were made by means of calipers, and the same level was obtained by means of superposition of the films over diffused strong light.

III. SOME DIFFICULTIES ENCOUNTERED IN INTERPRETATION OF THE ROENTGENOGRAMS OF THREE HUNDRED CASES

During the intensive study of the roentgenograms, from the point of view of roentgen interpretation, most interesting questions arose, necessitating definite solutions before any classifications or any theories of mechanism could be determined. These questions came almost entirely from a lack of standardized technic. The 300 cases had been examined by four different roentgenologists. The technic of only one of them was known. Immediately, the question arose: Does not this, or that, represent some variation from the real normal, produced by variations

in the procedures of these different roentgenologists, rather than a pathologic condition?

Textbooks on roentgenology describe certain more or less standardized positions for examination of the ankle joint. They point out anatomic landmarks above which to center the target of the tube. But none of them describe the variations in shadow which may occur: for instance, from increased or decreased target plate distance, or from variations produced by lateral shifting of the target, or by variations in posture of the joint. It would seem that opportunities for error are numerous. The very nature of hospital dressings—so different in the various institutions—constitutes one of the most prolific sources of error. The difficulty of exact centering through a plaster-of-Paris dressing or of an ankle encased in a fracture box is obvious.

The discussion which follows may seem to be far-fetched to some and futile to others. I am well aware of the conditions under which many busy roentgenologists work. I realize that a plate or film placed under an ankle with the target at any given distance above it, and the perpendicular assumed or guessed at, with a proper exposure technic will result in a so-called excellent negative. We admit that in a busy hospital service most of our patients were so examined. We admit that to the best of our knowledge no patients in any way afterward suffered, clinically, from such unstandardized examination at our hands. It is entirely probable that many clinicians can and will say, Why more? But I contend that in our study of these cases we were greatly hampered by such methods in arriving at definite conclusions. Gross lesions are usually apparent and easily diagnosed. The fine points in diagnosis are the difficult ones. It is only by exact methods that the science of diagnosis is advanced and the sum total of our knowledge of the subject increased.

The first difficulty that arose, the solution of which was of utmost importance, was the exact determination of just what on the roentgenogram determines diastasis of the lower tibiofibular junction. The normal ankle joint was roentgenographed under all possible conditions, in an effort to study the possible variations in shadows of the normal due to changes in technic. It was first examined at various target plate distances with the foot and target in the perpendicular plane; then the same ankle was roentgenographed with the leg in different angles of rotation and also with the foot in full dorsiflexion and plantar flexion, and again with the target deviated to either side from the perpendicular plane. A study of these results shows the necessity for the roentgenologist's deciding on one target plate distance for all examinations, also for him to formulate or design some scheme for quickly securing in each case the same perpendicular plane of the ankle and target,

especially in the anteroposterior view. A long upright rod with another at right angles, attached to its lower end, can readily be made and used for this purpose (goniometer).

From the results obtained on the roentgenograms showing the variations in target plate distance, it can be assumed that shadows on roentgenograms follow certain rules. Thus, as this distance decreases, all shadows proportionately increase provided there is no shift of the target in any direction, or any change in the position of the ankle, as, for instance, rotation of the limb. Thus the distance between the shadow of the line of the posterior tubercle on the fibular groove and that of the mesial margin of the fibula is increased if the target is moved nearer the plate, but likewise the width of the fibula and tibia seems to be proportionately increased. However, by no possible manipulation of the tube to either side up to 75 degrees from the perpendicular, or by inward or outward rotation of the leg to 80 degrees can the shadow of the most lateral point of the anterior tubercle be made to pass to the median side of the shadow of the median border of the fibula. (It seemed that the above-mentioned angles were the limits of the possible errors that could have been made in the roentgenograms of our series). Hence it was felt that we could safely say that whenever this did happen, tibiofibular diastasis was established. In fact, if the space between the lateral margin of the fibula and the lateral border of the anterior tubercle exceeds more than two thirds of the width of the fibula, it is most probable that the first degree of diastasis (Fig. 36) exists. This would seem to be certainly the case if the roentgenogram was made with the foot and ankle and tube in the absolute perpendicular plane (Figs. 49, 52 and 53).

Chaput [39] (1912) gave figures in millimeters showing variations of the "clear space" as he called it between the line of the posterior tubercle and the mesial border of the fibula, and claimed that if this space exceeded more than 3 mm., or if the area of the overlapping shadows of fibula and anterior tibial tubercle was less than 10 mm., diastasis was present. The objection to this as compared with the above method is obvious. Measurements on the roentgenogram vary greatly with changes in technic, target plate distance, etc., with age periods and in the different sexes. So a method establishing a means of estimation proportionate for each individual case is manifestly the best.

The larger the clear space between these bones, the greater the degree of diastasis. If there is additional roentgen evidence of a sprain fracture or detachment of the anterior tubercle, there is double assurance (Figs. 30 and 31). But here again one must make due allowance for the fact that when the patient reaches the roentgenologist reduction often has been established. The clear space will then not be abnormally

wide, and diastasis can only be presumed to have existed by the evidence of a sprain fracture or a fracture of the anterior tubercle. If these are not present, then no diagnosis of diastasis can be made by the roentgen ray. It seems possible that by a very complete study of normal ankles in both sexes, and in all age periods under identical conditions of technic, more absolute criteria can be established whereby this diagnosis can be made.

The clear space between the internal malleolus and the astragalus in the anteroposterior view is also a most interesting study. What determines the earliest or first degree of lateral displacement of the astragalus? This certainly is of the utmost importance in the determination of such displacement, particularly the so-called outward displacement. It was found that a 10 degree inward rotation of the leg increased this clear space, that the same amount of external rotation correspondingly decreased it; that variations in target plate distance proportionately increased or decreased it as the case might be, that tibial and fibular flexion of the foot both decreased it. So if a minute, careful diagnosis is to be made, the absolute perpendicular must be maintained. Had we had all roentgenograms of the 300 cases studied, made under identical technic, such diagnoses could have been made. We feel that quite a considerable degree of displacement had to be present, in fact so much that it would be apparent under any condition, any position of tube or ankle, before we could say definitely in the foregoing cases that a lateral dislocation existed. Probably also a better idea of rupture of the internal lateral ligament can be obtained by means of this clear space. Thus, when the internal malleolus is intact in the pure abduction fractures, this space may afford an idea of whether or not the internal lateral ligament has ruptured. Here again faulty methods prevented exact conclusions, and this again emphasizes the possibility of study under standardized conditions.

Study of the fibular groove led to the definite conclusion that the anterior tubercle always casts the more lateral shadow, the posterior tubercle the more mesial. This was confirmed by placing pieces of lead of different sizes on the lips of the groove in a living subject and then roentgenographing the ankle. It was noted, in the negatives made with deviations of the tube and change in position of the ankle, above described, that in the perpendicular plane the line of the posterior tubercle was always clearly defined, that this clear definition persisted when the leg was rotated in or with lateral deviation of the target; but with the leg rotated out or with mesial deviation of the target, this line had a tendency to disappear, becoming merged with the dense shadow of the thicker middle portions of the tibia. It is apparent that such variations may materially interfere with the exact determination of

just what constitutes the so-called posterior fragment. It may also interfere in the same way with recognition of the intermediate fragment. If this line remains intact, the posterior tubercle is not injured and the posterior inferior tibiofibular ligament is also probably not affected. It is possible that a deltoid shaped posterior marginal fragment broken from the tibia at a point mesial to and behind the posterior tubercle may be so displaced that its shadow overlaps the line of the posterior tubercle. The exact portion fractured can then only be determined by means of stereoscopic plates, and even then this is sometimes impossible. A fracture with such displacement was produced on a dried specimen, likewise another involving the posterior tubercle so as to interfere with the line of the latter on the roentgen-ray negative. In the anteroposterior view, they were indistinguishable, both appearing to be fractures of the posterior tubercle. However, stereoscopic films showed quite plainly the character of the first, i. e., a fragment displaced behind the tubercle and really not involving it.

In conclusion, this study has shown that while the roentgen diagnosis of the gross lesions of the ankle joint is a comparatively easy matter for the trained roentgenologist, the finer points of diagnosis so necessary to a thorough understanding of the mechanism are entirely dependent on more exact methods of technic than are often now employed.[82]

---

82. In addition to the footnotes already given, the following, selected from more than 250 articles studied in the preparation of this paper, will be found of interest:

Bruns: Die Lehre von den Knochenbrüchen, Stuttgart, 1887, p. 57.

Farabeuf: Précis de manuel operatoire, Paris, 1909, p. 835.

Hamilton: Practical Treatise on Fractures and Dislocations, Philadelphia, 1860, pp. 443 and 685.

Messerer: Ueber Elasticität und Festigkeit der Menschlichen Knochen, Stuttgart, 1880, Plate 14, Figures 7, 11 and 3.

Quénu: Bull. et mém. Soc. de chir. de Paris **32**:943, 1906; Rev. de chir. **36**:62, 1907; Bull. et mém. Soc. de chir. de Paris **38**:1070, 1912; ibid. **45**:1142, 1919.

Scudder: Treatment of Fractures, Ed. 8, Philadelphia, 1915, p. 545.

Tillaux: Traité d'anatomie topographique, Paris, Ed. 2, 1878, p. 1023; Gaz. d. hôp. **59**:89, 1886.

STUDIES IN EXHAUSTION: III. EMOTION

G. W. CRILE, M.D.

CLEVELAND

Intense emotion, especially fear, is one of the most injurious of human experiences. In fact, fear may be defined as the typical emotion, since practically every emotional state is allied to it, even anger, which must have originated in the impulse of self-protection against threatened danger. In the hope of discovering which organs participate in the production of fear, and the rôle assumed by each, I began a research to this end in 1908, the earlier results of which were reported in the Ether Day Address at the Massachusetts General Hospital, in 1910. In its various phases, this research has continued to the present time in the laboratory and the clinic, the emotive experiences of the war adding an overwhelming amount of human data to laboratory findings.

As stated in the preceding report,[1] it is practically impossible to formulate any experiment so that but one stimulus will act upon the animal; but as in the case of hunted foxes or of struggle in other animals, extreme exertion is the dominating activation, so in the case of a small animal subjected to threatened attacks, fear is the prevailing stimulus.

Most of our experiments were with rabbits which for varying periods of time were threatened by muzzled dogs. In some instances, the frightened rabbits were killed at once; in others, varying periods of time were allowed to elapse before death, that the later effects of the emotion might be studied; in still other cases, the animals were subjected to daily periods of fright on several successive days.

A. Histologic Studies

Rabbits.—Group 1: Experiments in which the rabbits were subjected to but one period of fright and then immediately killed.

Group 2: Experiments in which rabbits were subjected to but one period of fright, but were not killed until after two and one-half to six hours had elapsed.

Group 3: Experiments in which the rabbits were subjected to one period of fright on each of several successive days and killed shortly after the last period.

---

1. Crile, G. W.: Studies in Exhaustion: II. Exertion, Arch. Surg. **3**:116 (July) 1921.

Differential Purkinje cell counts, made by Dr. Austin and Dr. Hitchings, from the rabbits in each of these groups, are shown in Tables 1, 2, 3 and 4. These findings are graphically represented in Figure 1. Equally marked changes were observed in the cerebellum and the cerebrum; less marked changes were found in the medulla, and changes even less marked than the latter were present in the spinal cord.[2]

Woodchucks.—While these experiments with rabbits were in progress, we had an opportunity to secure two woodchucks, which were dug out of their hibernating holes without being awakened. One was killed immediately; the other was frightened by several dogs for fifteen minutes without being injured in any way, and was killed six hours later.

The result of the comparative examination of the brains of these two animals is given in Table 5. The contrast is of special significance since it not only shows the possible effects of fear on the central nervous system, but the Purkinje cell counts of the woodchuck which was killed without being awakened from his hibernating sleep as compared with the normal Purkinje cell counts in dogs, in foxes and in rabbits (Table 6), which demonstrate strikingly the restorative and protective value of sleep. The sections of the brain of this hibernating woodchuck contained the most perfect cells of any among the thousands of sections examined in these researches on exhaustion.

In the experiments thus far described, histologic studies were made only of the nervous system. Later, after we had extended our histologic studies to include all the organs and tissues of the body, another series of experiments on fright were performed which demonstrated brain cell changes of the same nature and degree as those in the earlier series, and less marked, but frequent, changes in the cortex of the suprarenals and of the liver (Figs. 2 to 10). These findings are shown in Tables 7 and 8. The other organs and tissues showed no demonstrable histologic lesions (Table 9).

The effects of insomnia and sleep on the histologic changes produced by fright are shown in Table 10; and the findings in preliminary observations of the effects of sodium bicarbonate and of magnesium sulphate on the changes produced by fright are shown in Table 11.

B. Physicochemical and Functional Studies

Effect of Fear on Suprarenal Output

Thirty-five tests of the effect of fright on the suprarenal output were made in our laboratory by Drs. Hitchings, Sloan and Austin

2. Crile, G. W.: Proc. Soc. Exper. Biol. & Med. 7:87-88, 1909-1910.

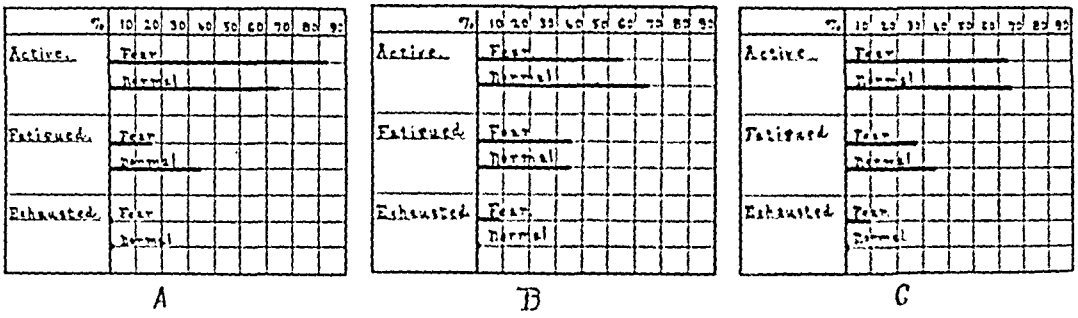

Fig. 1.—Average differential Purkinje cell counts in rabbits: *A*, rabbits killed immediately after a single period of fright; *B*, rabbits killed in from two and one-half to six hours after a single period of fright, and *C*, rabbits killed after daily periods of fright extending from two to three weeks.

TABLE 1.—Differential Counts of the Purkinje Cells of Rabbits Killed Immediately After One Seance of Fright

Duration of Fright	Stages: Active, per Cent.	Fatigued, per Cent.	Exhausted, per Cent.
60 minutes	73	25	2
60 minutes	84	16	0
25 minutes	69	28	3
25 minutes	94	5	1
10 minutes	77	21	2
60 minutes	86	14	0
30 minutes	87	12	1
25 minutes	83	17	0
35 minutes	92	8	0
40 minutes	89	11	0
Average	83.4	15.7	0.9
Normal average rabbit	64.8	34.5	0.7

Average duration of fright: 37 minutes

TABLE 2.—Differential Counts of the Purkinje Cells of Rabbits Killed at Varying Periods After One Seance of Fright

Duration of Fright	Interval of Time Until Killed, Hours	Stages: Active per Cent.	Fatigued, per Cent.	Exhausted, per Cent.
40 minutes	2¼	48	35	17
45 minutes	3½	70	26	4
90 minutes	3½	47	45	8
90 minutes	6	63	31	6
45 minutes	6	50	40	10
Average, 63 minutes	...	55.6	35.4	9.0
Normal rabbit average	...	64.8	34.5	0.7

TABLE 3.—DIFFERENTIAL COUNTS OF THE PURKINJE CELLS OF RABBITS KILLED AFTER REPEATED PERIODS OF FRIGHT

Periods of Fright	Interval of Time Until Killed	Stages: Active, per Cent.	Fatigued, per Cent.	Exhausted, per Cent.
16 times in 3 weeks	Found dead*	59	27	14
14 times in 2 weeks	24 hours after last period	68	26	6
Average	.....	63.5	26.5	10.0
Normal rabbit averages	.....	64.8	34.5	0.7

* This animal could not have been dead more than twelve hours, and the brain was therefore examined in a shorter time after the last period of fright than in the case of the second rabbit in this group, hence the greater percentage of exhausted cells could not be attributed to postmortem changes.

TABLE 4.—COMPARISON OF AVERAGES IN TABLES 1 TO 3

	Active, per Cent.	Fatigued, per Cent.	Exhausted, per Cent.
Group I. Rabbits killed immediately after one seance of fright	83.4	15.7	0.9
Group II. Rabbits killed in from 2½ to 6 hours after one seance of fright	55.6	35.4	9.0
Group III. Rabbits killed after repeated seances of fright	63.5	26.5	10.0
Normal average	64.8	34.5	0.7

TABLE 5.—COMPARATIVE STUDY OF THE BRAIN OF A HIBERNATING AND OF A FRIGHTENED WOODCHUCK

A. *Cerebrum*

Hibernating Woodchuck	Frightened Woodchuck
Cells moderately hyperchromatic with very even distribution of the granules	Marked chromatolysis, cells more irregular in outline than in hibernating woodchuck Many cells with large vacuoles. No hyperchromatic cells, some active, nearly all fatigued, or exhausted

B. Cerebellum

	Differential Purkinje Cell Count: Active, per Cent.	Fatigued, per Cent.	Exhausted, per Cent.
Hibernating woodchuck	90	10	0
Frightened woodchuck	4	58	38

TABLE 6.—COMPARISON OF THE AVERAGE NORMAL PURKINJE CELL COUNTS IN DOGS, IN FOXES AND IN RABBITS WITH THE PURKINJE CELL COUNT IN A HIBERNATING WOODCHUCK

	Differential Purkinje Cell Counts: Active, per Cent.	Fatigued, per Cent.	Exhausted, per Cent.
Normal dog	71.2	28.1	0.7
Normal fox	71.0	28.5	0.5
Normal rabbit	64.8	34.5	0.7
Hibernating woodchuck	90	10	0

TABLE 7.—HISTOLOGIC STUDIES OF FEAR

Animal	Duration of Fright	Brain	Suprarenals	Liver
Rabbit	30 minutes	Cerebellum: occasionally hyperchromatic and active cell; many fatigued; few exhausted Cerebrum: occasional hyperchromatic and active; almost all fatigued	About normal; only few cells in outer portion of cortex show loss of cytoplasm or vacuolation; medulla pale	Marked loss of cytoplasm and vacuolation in all cells
Rabbit	30 minutes	Cerebellum: no hyperchromatic cells; some active; almost all fatigued; few exhausted Cerebrum: occasional hyperchromatic cells; some active; almost all fatigued; few exhausted	Almost normal; very few cells of cortex show loss of cytoplasm; medulla deeply stained; no loss of cytoplasm in cells	Total loss of cytoplasm and complete vacuolation of all cells
Rabbit	30 min. per day for 45 out of 48 consecutive days	Cerebellum: active, 75%; fatigued, 22%; exhausted, 3% Cerebrum: some hyperchromatic, many exhausted	Cortex: only a few slightly affected cells Medulla: normal	Almost all cells show great loss of cytoplasma, only a few around central vein being in fair condition
Rabbit	20 min. per day for 45 out of 48 consecutive days	Cerebellum: active, 74%; fatigued, 24%; exhausted, 2% Cerebrum: more hyperchromatic than in the foregoing; some fatigued	Cortex: great loss of cytoplasm and vacuolation Medulla: lightly stained; otherwise normal	Every cell had lost almost all its stainable material

TABLE 8.—HISTOLOGIC STUDIES OF FEAR

Animal	Duration of Fright	Brain	Suprarenals	Liver
Woodchuck	Frightened for 60 min. immediately after hibernation sleep; killed 5½ hours after termination of fear	Cerebellum: mostly fatigued; occasional exhausted; no hyperchromatic	Cortex: normal Medulla: normal	Almost entirely normal; only slight loss of cytoplasm and vacuolation around periphery of some lobules
Woodchuck	Had been in laboratory for some time; frightened for 15 min.; killed immediately	Cerebellum: many fatigued; occasional hyperchromatic Cerebrum: hyperchromatic and active	Cortex: only a narrow strip of outer cortical cells show slight loss of chromatin and vacuolation Medulla: normal	Slight uniform loss of cytoplasm

TABLE 9.—EFFECT OF FRIGHT ON VARIOUS ORGANS AND TISSUES OF THE BODY

	Belgian Hare, Male, Wt., 3,780 Gm.	Rabbit, White Female, Wt., 3,562 Gm.	Woodchuck, Male, 3 Years Old	Woodchuck, Male
Duration and manner of fright	Frightened twice a day for 20 minute periods for 47 days	Frightened twice a day for 20 minute periods for 47 days	Dug from hibernating hole; worried by dog for 1 hour; killed 4 hours later	Had been in laboratory some time; frightened for 15 minutes; killed immediately
Cerebrum	Some hyperchromatic cells, many fatigued	Some hyperchromatic cells, some fatigued; more hyperchromatic cells than in foregoing experiment	Most all cells active; occasional fatigued cell	Hyperchromatic and active
Cerebellum	75% active cells 22% fatigued 3% exhausted	74% active cells 24% fatigued 2% exhausted	No hyperchromatic cells; a few active; occasional exhausted cell	Occasional hyperchromatic cell, many fatigued
Liver	Nearly all cells show great loss of chromatin; only a few cells around central vein are in fair shape	Stainable material almost entirely lost; in worse condition than in preceding experiment	Almost entirely normal; slight loss of cytoplasm and vacuolation around periphery of some lobules	Almost normal; very slight loss of cytoplasm, uniformly distributed
Suprarenal	Cortex: a few slightly abnormal cells Medulla: deeply stained and normal	Cortex: many cells greatly affected, only a little stainable material left Medulla: less well-stained than in foregoing experiment	Cortex and medulla: entirely normal and well-stained; no cells show loss of cytoplasm	Nearly all cells normal; a narrow strip of outer cortical cells shows slight loss of chromatin and vacuolation
Kidney	.....	Bowman's capsule, tubules and glomeruli normal	.....	Bowman's capsule, tubules and glomeruli normal, well-stained
Thyroid	.....	Acini large; epithelium flat; no increase in interstitial tissue	Acini irregular; very large amount of interstitial tissue between acini	
Thymus	Faintly stained; medulla large; corpuscles numerous and small	Normal, well-stained; Hassell's corpuscles few		
Spleen	Normal	Normal	Normal and well-stained; few corpuscles and small; lymph spaces congested with red blood cells; fewer lymphocytes than normal	Normal, many well-stained lymphocytes
Lung	.....	Normal, epithelium intact	Greatly congested; alveoli not distended	Normal
Heart	Normal, faint striations	Normal, faint striations	Normal	Nuclei well stained; striations not present in section
Aorta	Normal	.....	Normal	Normal
Voluntary muscle	.....	Normal, striations marked	Well stained and normal, beautiful striations	Normal, crowded with lymphocytes
Lymph nodes	.....	.....	Normal; but lymph spaces extremely distended	

TABLE 9.—Effect of Fright on Various Organs and Tissues of the Body.—(Continued)

	Belgian Hare, Male, Wt., 3,780 Gm.	Rabbit, White Female, Wt., 3,562 Gm.	Woodchuck, Male, 3 Years Old	Woodchuck, Male
Stomach	.....	.....	Both acid and peptic cells well stained, muscle normal	Mucosa pink; acid, peptic, and parietal cells poorly defined
Intestines	Normal	Normal	Epithelium and muscle normal	Epithelium and muscle normal
Testicle	Much distorted and shrunken; well-stained cells in all stages of activity and fatigue	.....	Very few dividing cells or spermatozoa in tubules; very great number of large interstitial cells	Normal, active spermatogenesis; large number of interstitial cells crowded between tubules
Uterus	.....	Epithelium and cilia normal; muscle normal; not deeply stained		

TABLE 10.—Histologic Studies of Fear

Animal	Description of Experiment	Brain	Suprarenals	Liver
Rabbit	½ hour fright followed by insomnia 10 hours; killed immediately after insomnia period	Cerebellum: no hyperchromatic; few active; very marked fatigue in almost all cells Cerebrum: many fatigued; some hyperchromatic and active cells	Cortex: normal; no loss of cytoplasm	Stain not deep; cells all normal
Rabbit	½ hour fright followed by insomnia 10 hours; killed immediately after insomnia period	Cerebellum: few active cells; no hyperchromatic, almost all badly fatigued Cerebrum: some hyperchromatic and active cells; many fatigued cells	Slight loss of cytoplasm and vacuolation in some cells of cortex Medulla: deeply stained	Stain faint with uniform but not marked loss of cytoplasm; no vacuolation
Rabbit	30 minutes fright; insomnia 5 hours; sleep 5 hours; killed immediately	Cerebellum: mostly fatigued; no hyperchromatic Cerebrum: all fatigued; no hyperchromatic	Cortex: normal Medulla: normal	Normal
Rabbit	30 minutes fright; insomnia 5 hours; sleep 5 hours; killed immediately	Cerebellum: mostly fatigued; some hyperchromatic in stage II Cerebrum: mostly hyperchromatic	Cortex: normal Medulla: normal	Uniform loss of cytoplasm; some vacuolated cells; a few cells with eccentric nuclei; cell outlines regular

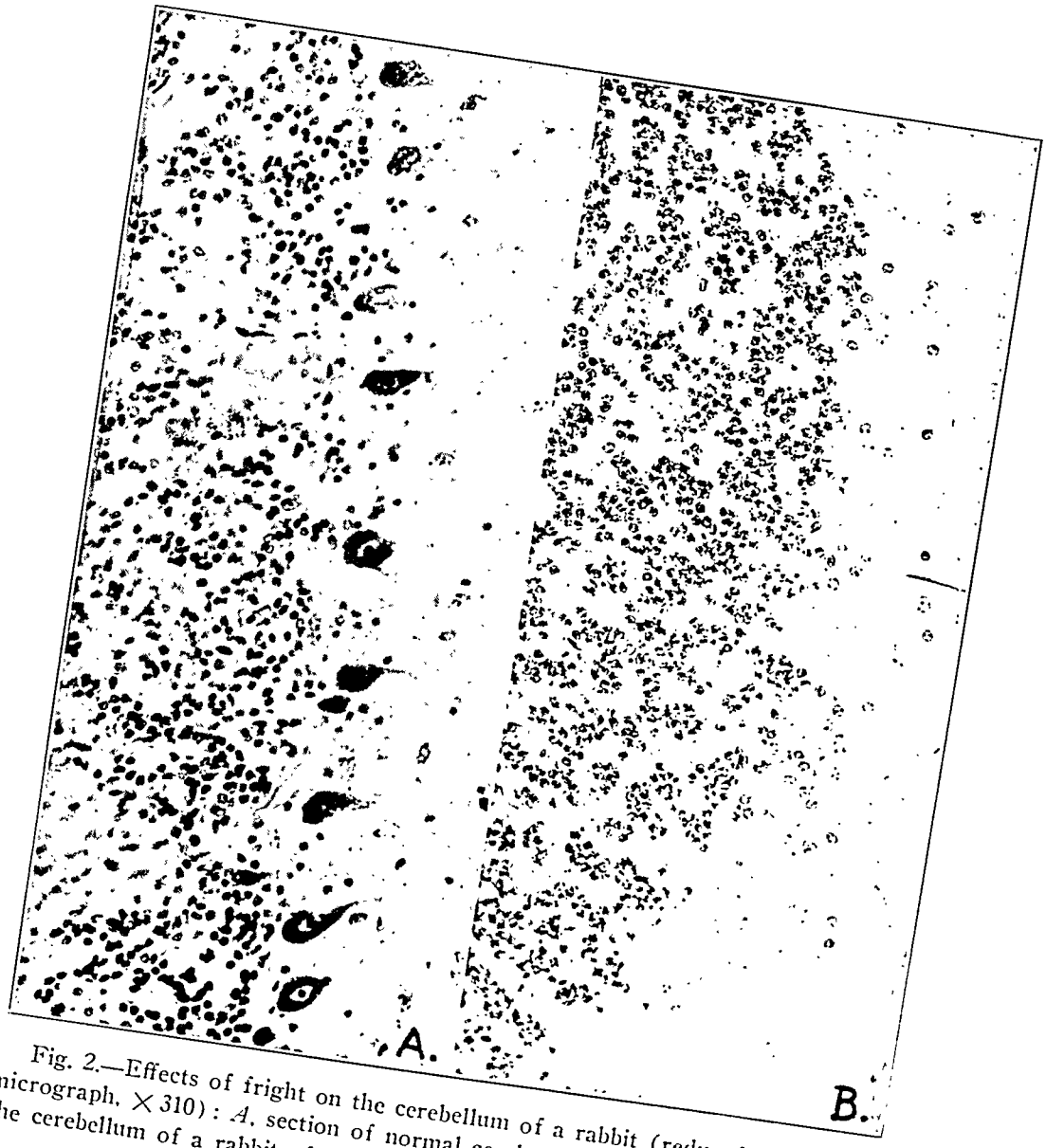

Fig. 2.—Effects of fright on the cerebellum of a rabbit (reduced from photomicrograph, × 310): *A*, section of normal cerebellum of a rabbit; *B*, section of the cerebellum of a rabbit after repeated periods of fright.



Fig. 3.—Immediate and late effect of fright on the cerebellum of woodchuck (reduced from photomicrographs, ×310): *A*, section of cerebellum of a hibernating woodchuck; *B*, section of cerebellum of a woodchuck killed immediately after a single period of fright; *C*, section of cerebellum of a woodchuck killed four hours after a single period of fright.

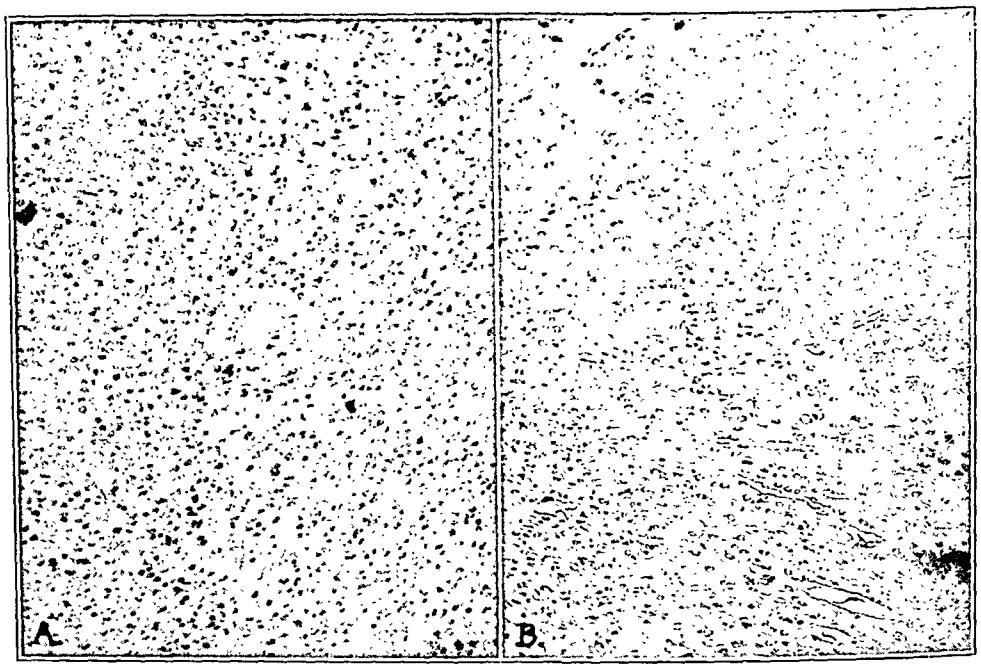

Fig. 4.—Effect of fright on the cerebrum of a rabbit (reduced from photomicrographs, ×85): *A*, section of normal cerebrum of a rabbit; *B*, section of cerebrum of a rabbit after repeated periods of fright.

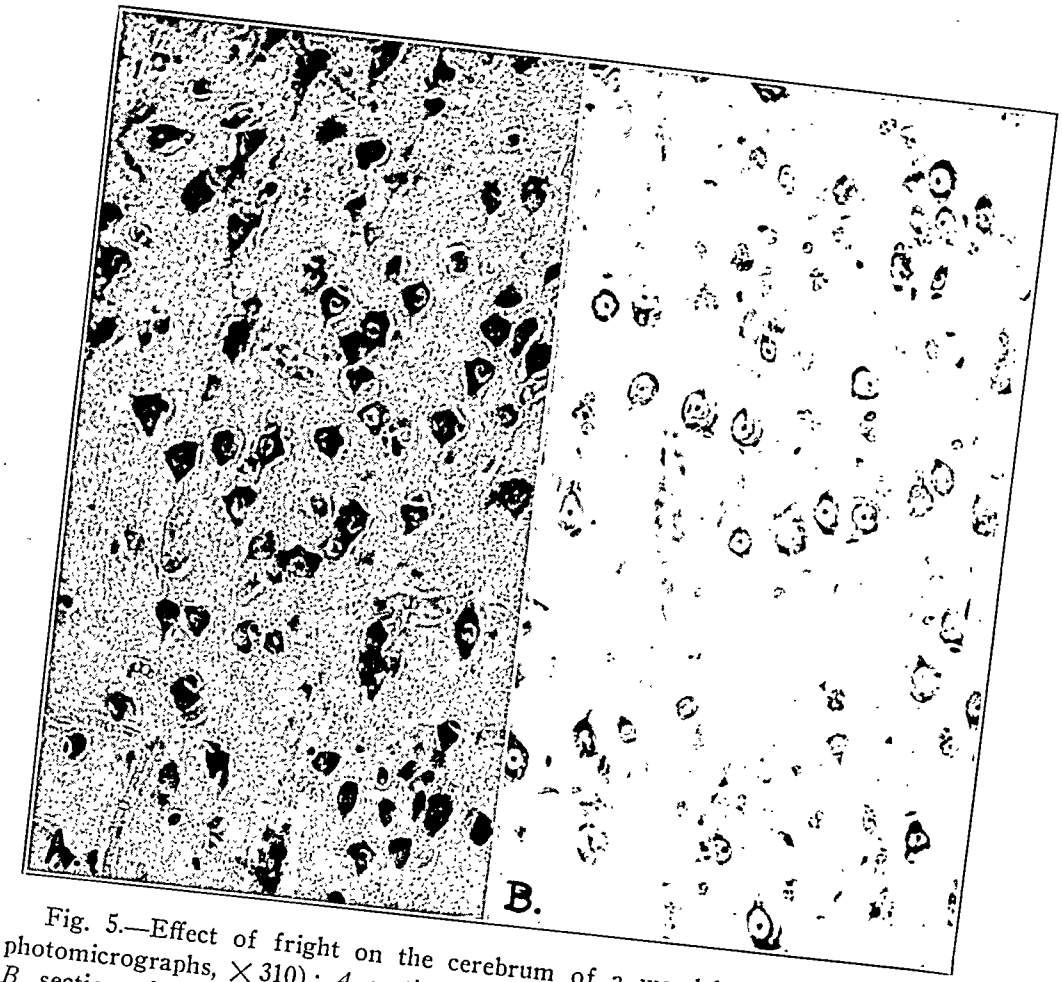

Fig. 5.—Effect of fright on the cerebrum of a woodchuck (reduced from photomicrographs, × 310): *A*, section of cerebrum of a hibernating woodchuck; *B*, section of cerebrum of a woodchuck killed four hours after a single period of fright.



Fig. 6.—Effect of fright on the medulla of a woodchuck (from camera lucida drawings): *A*, section of medulla of a hibernating woodchuck; *B*, section of medulla of a woodchuck after a single period of fright.

Fig. 7.—Effects of fright on the liver of a rabbit (reduced from photomicrographs, × 1,640): *A*, section of normal suprarenal of a rabbit; *B*, section of suprarenal of a rabbit after repeated periods of fright.

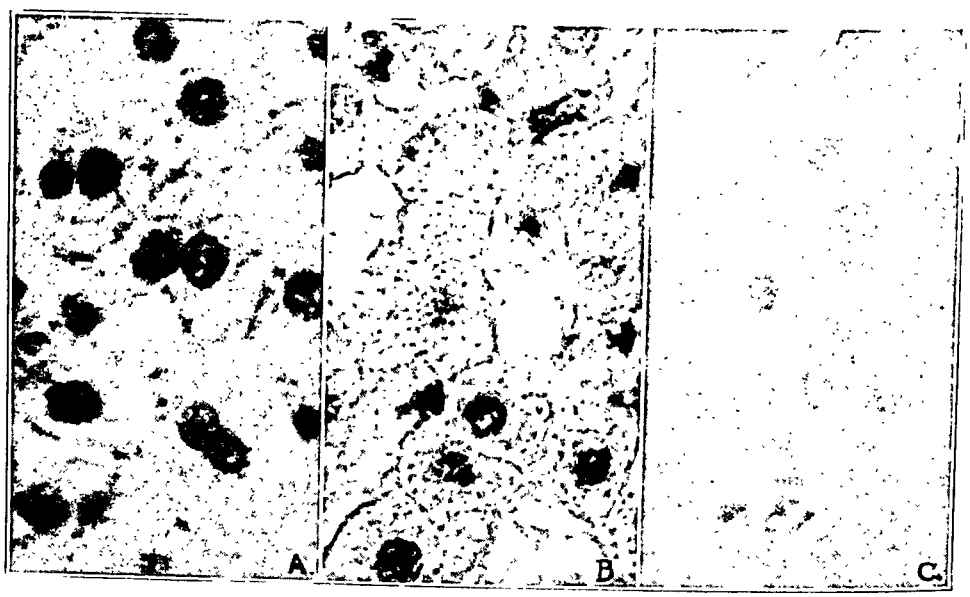

Fig. 8.—Immediate and late effects of fright on the livers of woodchucks (reduced from photomicrographs, × 1,640): *A*, section of normal liver of woodchuck; *B*, section of liver of woodchuck killed immediately after one period of fright, and, *C*, section of liver of woodchuck killed four hours after one period of fright.

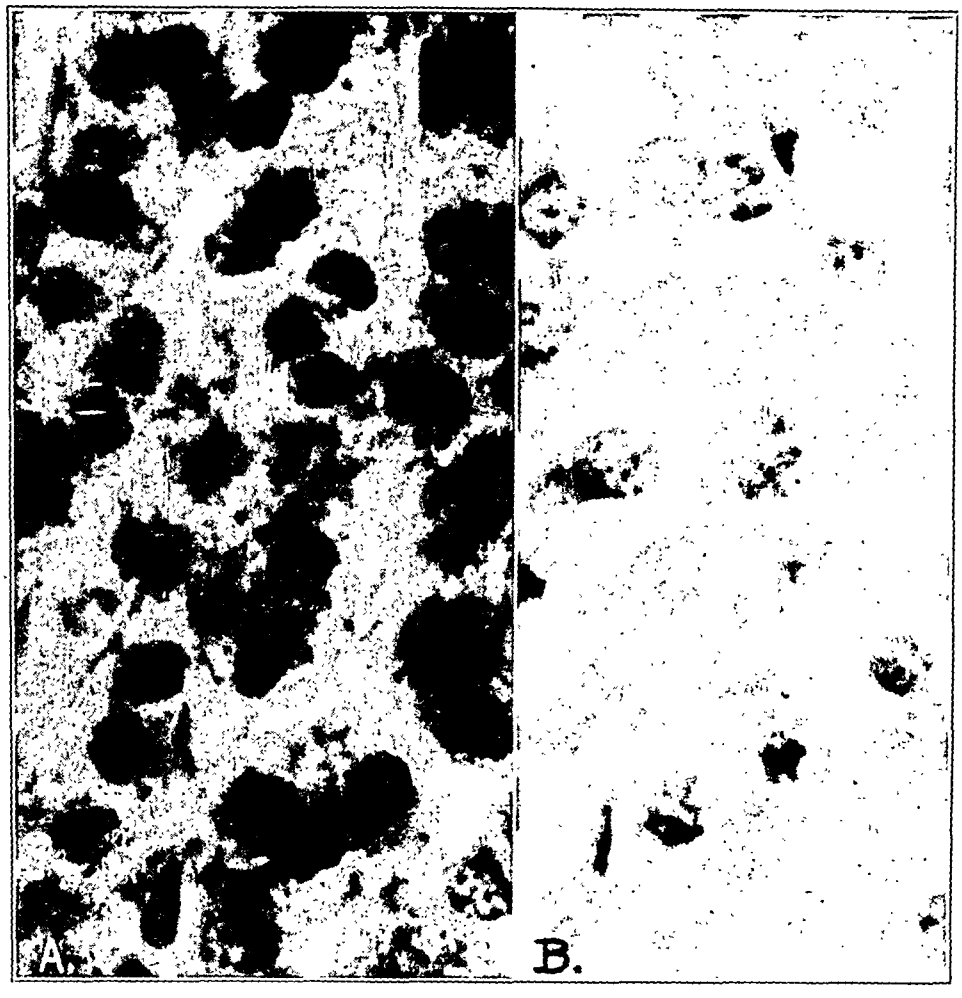

Fig. 9.—Effect of fright on the suprarenal of a rabbit (reduced from photomicrographs, × 1,640): *A*, section of normal suprarenal of a rabbit; *B*, section of suprarenal of a rabbit after repeated periods of fright.



Fig. 10.—Immediate and late effects of fright on the suprarenals of woodchucks (reduced from photomicrographs, × 1,640): *A*, section of normal suprarenal of a woodchuck; *B*, section of suprarenal of a woodchuck killed immediately after a single period of fright, and *C*, section of suprarenal of a woodchuck killed four hours after a single period of fright.

TABLE 11.—Histologic Studies of Fear

Animal	Description of Experiment	Brain	Suprarenals	Liver
Rabbit	½ hour fright followed by subcutaneous injection of 4 c.c. per kg. 25% solution magnesium sulphate; killed in 6 hours	Cerebellum: only an occasional hyperchromatic and active cell; almost all fatigued; few exhausted Cerebrum: no hyperchromatic cells; many active and fatigued cells	Cortex: slight loss of cytoplasm and vacuolation in outer cells Medulla: pale with loss of cytoplasm in some cells	No loss of cytoplasm or vacuolation; stain not sharp
Rabbit	½ hour fright followed by subcutaneous injection of 4 c.c. per kg. 25% solution magnesium sulphate; killed 6 hours later	Cerebellum: occasional hyperchromatic and active cell; almost all fatigued; few exhausted Cerebrum: some hyperchromatic cells; some active; many fatigued; few exhausted	Cortex: loss of cytoplasm and vacuolation in outer cells Medulla: pale with loss of cytoplasm in some cells	Moderate uniform loss of cytoplasm in all cells
Cat	½ hour fright followed by 2 intravenous injections of 10 c.c. saturated solution Na_2HCO_3 ten minutes apart; killed 4 hours after second injection	Cerebellum: some hyperchromatic cells; most all active; some fatigued cells; stain intense	Cortex: marked loss of cytoplasm and vacuolation	Slight uniform loss of cytoplasm

TABLE 12.—Effect of Fright on the Suprarenal Output
(Cannon test)

Animal	Duration and Manner of Fright	Epinephrin Test 1	Epinephrin Test 2	Epinephrin Test 3
Female cat	Frightened 15 min. by bulldog	Before fright negative	Immediately after fright positive	10 min. after fright negative
Large male cat	Frightened 15 min. by bulldog	Before fright slightly positive reaction	Immediately after fright positive	15 min. after fright positive
Female cat	Frightened 15 min. by bulldog	.....	2 min. after fright slight reaction	
Male cat	Frightened 13 min. by bulldog; intense fright	Before fright negative	Immediately after fright positive	10 min. after fright slight reaction

by either Cannon's or Elliott's method[3] (Figs. 11 and 12). The protocols given in Table 12 give positive evidence that increased activity of the suprarenals is produced by fright, while the findings shown in Table 13 indicate that the stimulus which induces this increased activity is transmitted to the suprarenals from the brain (Fig. 13).

3. Elliott, T. R.: J. Physiol. **32**:401-406, 1905; ibid. **44**:374-409, 1912; ibid. **46**:285-290, 1913; ibid. **49**:38-53, 1914. Cannon, W. B.: Am. J. Physiol **33**:356-372, 1914. Cannon, W. B., and de la Paz, D.: Am. J. Physiol. **28**:64-70, 1911. Cannon, W. B., and Cattell, McK.: Am. J. Physiol. **41**:39-57, 58-72, 74-78, 1916. Hitchings, F. W., Sloan, H. G., and Austin, J. B.: Cleveland M. J. **12**:684-691, 1913. Stewart, G. N., and Rogoff, J. M.: J. Exper. Med. **24**:709 (Dec.) 1916; J. Pharm. and Exper. Therap. **8**:479-524, 1916.



A B C

Fig. 11.—Tracing showing effect of fear on the suprarenal output of a cat (Cannon test). The first tracing *A*, was made by the contractions of intestinal muscle in blood from a normal cat. The contractions of the intestinal muscles were inhibited when the normal blood was replaced by blood from the same animal after it had been frightened. This inhibition is evidence of increased epinephrin in the blood stream, more epinephrin apparently is produced in the early stages of fright (*B*) than in the later stages (*C*).



Fig. 12.—(Exp. 756, Jan. 16, 1914).—Tracing showing effect of fear on the epinephrin content (Elliott test). After the removal of the left gland, the animal (a cat) was frightened, after which the right gland was removed and the epinephrin content tested by the Elliott method.

TABLE 13.—EFFECT OF FRIGHT ON THE SUPRARENAL OUTPUT AFTER DIVISION OF SPLANCHNICS

(Cannon test)

Animal	Anesthetic and Operation	Duration and Manner of Fright	Epinephrin Test 1	Epinephrin Test 2	Epinephrin Test 3
Large male cat	N_2O plus local block abdominal wall; major splanchnics cut	Frightened 7 min. by bulldog	7 min. after fright negative	20 min. after fright negative	Epinephrin added to blood positive
Immature female cat	N_2O tracheotomy; 4 splanchnics cut above diaphragm	Frightened 5 min. by bulldog	Immediately after fright negative		
Female cat	N_2O tracheotomy; 4 splanchnics cut	Frightened 5 min. by bulldog	Negative		
Male cat	N_2O tracheotomy; splanchnics cut	Frightened 5 min. by bulldog	Negative		

TABLE 14.—EFFECT OF FEAR ON THE H-ION CONCENTRATION OF THE BLOOD

	P_H
Experiment 1.	
Normal blood from rabbit	7.58
Immediately after rabbit had been frightened by a fox terrier for 5 minutes	6.99, 6.91, 6.98
Ten minutes after termination of period of fright	7.19
Experiment 2.	
Normal blood from rabbit	7.65, 7.67
Immediately after rabbit, confined in box,* had been frightened by dog for 10 minutes	7.17, 7.17
After rabbit had been kept quiet in box for 45 minutes and then again frightened for 5 minutes	7.24, 7.41
After rabbit had rested 30 minutes	7.58, 7.60
Experiment 3.	
Blood from femoral vein of cat. Cat tied down and vein exposed under cocain	7.43
After cat had been frightened for 10 minutes by a dog	7.20
One hour later; animal struggling, respiration very rapid	7.37
Experiment 4.	
Normal blood from rabbit	7.62, 7.62
After rabbit had been frightened for 3 minutes by a fox terrier	7.54, 7.54
Fifteen minutes after the intravenous injection of 1.5 c.c. 2 per cent. morphin	7.52
Sixty minutes later	7.57
Immediately after administration of ether for 5 minutes	7.32, 7.32
Experiment 5.	
Blood from cat which had been tied down and was struggling	7.09, 7.14
Immediately after cat had been frightened for 15 minutes by a dog	7.16
One hour later, after intravenous injection of 1½ grains (0.1 gm.) morphin sulphate in divided doses	6.99
Three hours after fright, cat dying	6.98
Experiment 6.	
Blood from the vena cava of a cat, taken through a catheter passed to the vena cava through the femoral	7.21, 7.24
Immediately after cat had been frightened by a dog for 15 minutes	7.02, 6.97
Immediately after the subcutaneous injection of 15 m. 1:1000 epinephrin chlorid	6.95, 6.95
Forty-five minutes later	6.89, 6.89

* By keeping rabbit in a box during the seances of fright the element of exertion was in part eliminated.

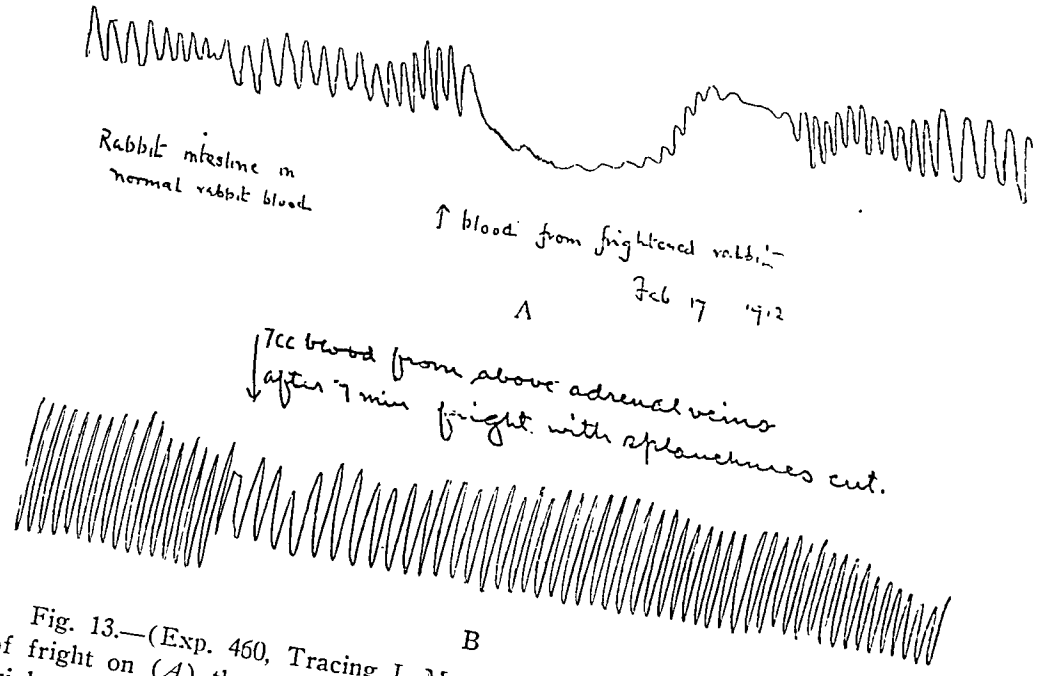

Fig. 13.—(Exp. 460, Tracing I, March 6, 1913).—Comparison of the effect of fright on (*A*) the suprarenal output of a normal rabbit with the effect of fright on, (*B*) the suprarenal output of a rabbit after division of the splanchnics. (Note the apparent lack of suprarenal response in *B*.)

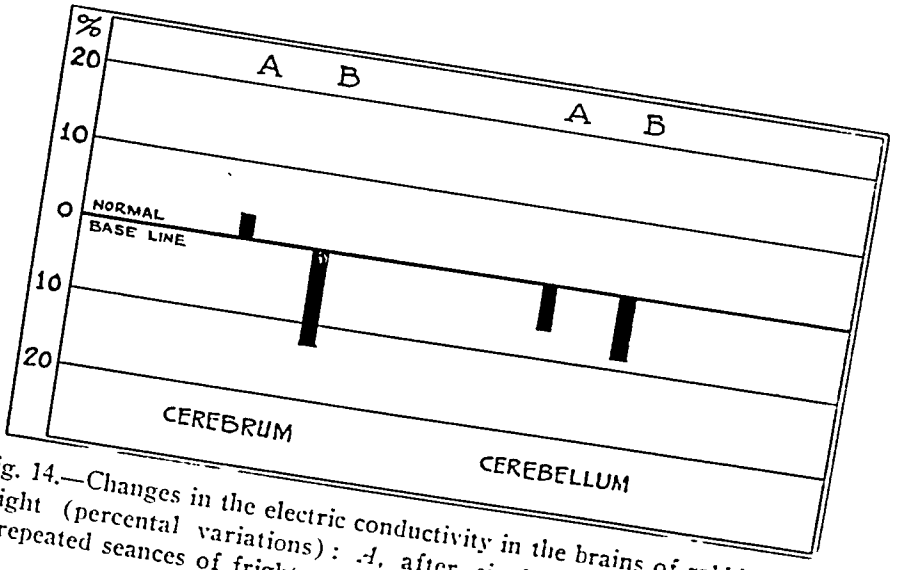

Fig. 14.—Changes in the electric conductivity in the brains of rabbits produced by fright (percental variations): *A*, after single seance of fright, and, *B*, after repeated seances of fright.

EFFECT OF FEAR ON THE H-ION CONCENTRATION OF THE BLOOD

Six studies of the effect of fright on the H-ion concentration of the blood, made by Dr. Menten,[4] showed that in every instance the H-ion concentration was markedly increased. This increased acidity was evidenced clinically by a greatly increased respiratory rate. The neutralization of the increased acidity was retarded in the two cases in which morphin was administered after the period of fright, and in one instance in which epinephrin was given.

In this series of experiments, no measurements of the H-ion concentration of the urine or of other body fluids were made (Table 14).

PHYSICOCHEMICAL STUDIES OF THE EFFECTS OF FEAR[5]

In order to determine the effect of fear on the chemical content of the thyroid, suprarenals, liver and muscle, ten rabbits were frightened

TABLE 15.—PHYSICOCHEMICAL STUDIES OF THE EFFECT OF FEAR ON CERTAIN ORGANS AND TISSUES

	Series	Thyroid; Iodin Content	Suprarenals: Epinephrin Content, per Cent.	Suprarenals: Epinephrin Activity, per Cent.	Glycogen Content, per Cent.	Muscles; Glycogen Content
A.	12 normal rabbits	0.25 mg.	0.01	2	1.66	
	12 rabbits after fright 1 hour	0.47 mg.	0.033	1.67	1.42, 0.745 (duplicate assay)	
B.	10 normal rabbits	1.11 mg. 0.01%	0.025	1.25	1.01	Trace
	10 rabbits after fright ½ hour	2.48 mg. 0.19%	0.030	1.5	1.25	Trace

by dogs as in the experiments described above. The glands and tissues from these rabbits and also from an equal number of normal rabbits were sent to Parke, Davis and Company, where assays were made through the courtesy of Dr. Houghton, and Messrs. Biggs, Hamilton and Rome by the methods described in the preceding section of these studies in exhaustion.[1]

The results are given in Table 15. In each of these tests, the iodin content of the thyroid gland is increased; but the variation in the findings in the liver, suprarenals, and muscle indicates the need for many additional experiments.

In our own laboratory, we confirmed Cannon's findings of glycosuria in cats, but not in rabbits.

In five experiments in which the urine was tested prior to and after the seance of fright, albumin and casts appeared.

4. Menten, M. L., and Crile, G. W.: Am. J. Physiol. **38**:225-232, 1915.
5. Cannon, W. B., and Lamson, P. D.: J. Pharm. & Exper. Therap. **7**:167-171, 1916.

In four experiments, performed by Prof. R. D. Milner and Dr. C. A. Bowers, measurements of the basal metabolism were made after seances of fright, and compared with the basal metabolism of a series of normal rabbits. The results are shown in Table 16.

TABLE 16.—CHANGES IN THE METABOLISM OF RABBITS CAUSED BY FEAR

	Weight of Animal, Gm.	Time, Minutes	Corrected Measurements, C.c. CO_2	Corrected Measurements, C.c. O_2	R. Q.	Remarks
A. Normal Rabbits	2,304	60	1.003	1,247	0.80	Without food for two days; rabbit restless
	2,334	60	0.9571	1.126	0.85	Fed after 4 p. m. preceding day; food allowed to remain in cage all night
		40	0.7229	0.894	0.81	
		51	0.7993	1.005	0.80	
	2,340	64	0.9571	1.171	0.82	
		31	0.5397	0.636	9.85	
		60	1.059	1.168	0.90	Generous feeding after 4:30 preceding day; stomach full this morning
	2,346	60	1.018	1.134	0.90	
		30	0.5804	0.690	0.84	
		30	0.5855	0.709	0.83	
	2,346	30	0.6618	0.768	0.86	Fed on morning of preceding day
		45	0.7025	0.942	0.74	
		45	0.7535	0.924	0.82	
		45	0.7891	0.928	0.85	
B. Frightened Rabbits	.....	45	0.8095	1.048	0.772	Fed previous afternoon
		45	0.6873	0.863	0.796	
	1,372	45	0.6516	0.839	0.776	Rabbit frightened by dog until exhausted
		45	0.4378	0.594	0.74	
		45	0.4684	0.618	0.76	
	2,229	60	0.6516	0.794	0.82	Frightened by dog for 20 min.; very little apparent disturbance
		45	0.6415	0.997	0.64	
		45	0.7178	0.938	0.765	
	2,219	45	0.6211	0.787	0.789	Frightened by dog for one half hour
		45	0.8604	0.927	0.93	
		45	0.6771	0.963	0.70	Frightened and chased by dog for 25 min. until completely exhausted
			0.6669	1.010	0.66	

TABLE 17.—AVERAGE SPECIFIC CONDUCTIVITY OF THE BRAINS OF NORMAL RABBITS (expressed in reciprocal ohms)

	Number of Animals	Average Deviation	Percental Variation	Average Conductivity
Cerebrum.....	6	2.7	1.4	0.00189
Cerebellum.....	6	1.4	0.8	0.00164

CHANGES IN THE SPECIFIC ELECTRIC CONDUCTIVITY OF THE BRAIN PRODUCED BY FEAR

Electric conductivity measurements of various tissues of Belgian hares were made by Miss H. R. Hosmer and Miss A. F. Rowland after single and after repeated seances of fright, conducted as nearly as possible in an identical manner with the experiments in the previous phases of this research. Both the normal and the frightened animals in this group were purchased from the same dealer, and had been kept for some time under identical conditions in our laboratory. The measurements from these normals and from the frightened animals are given in Tables 17 and 18, and the results on the conductivity of the brain are shown graphically in Figure 14.

CLINICAL EFFECTS OF FEAR

Temperature.—In most of our experiments the temperature rose, sometimes as much as 3 degrees Centigrade, the maximum usually being reached in from fifteen to twenty minutes. Marinesco has shown that a much higher temperature than this is required to cause brain cell changes from heat alone. In two rabbits in which complete thyroidectomy had been performed two weeks before the experiments, the temperature *fell* instead of rising; in one case 2 degrees and in the other 5 degrees Centigrade.

TABLE 18.—SPECIFIC CONDUCTIVITY OF THE BRAINS OF RABBITS AFTER SINGLE AND AFTER REPEATED SEANCES OF FRIGHT
(expressed in reciprocal ohms)

		Cerebrum	Cerebellum
After single seance of fright	Rabbit 1	00199	00144
	Rabbit 2	00191	00156
	Rabbit 3	00195	00163
Average		00195	00154
After repeated seances of fright	Rabbit 1	00157	00153
	Rabbit 2	00161	00147
	Rabbit 3	00178	00149
Average		00165	00150
Normal average		00189	00164

TABLE 19.—EFFECT OF FEAR—REPEATED TEN MINUTE PERIODS—ON THE TEMPERATURE OF RABBITS

	Group I						Group II			
	Rabbit 1		Rabbit 2		Rabbit 3		Rabbit 1		Rabbit 2	
Day	Before Fright	After Fright	Before Fright	After Fright	Before Fright	After Fright	Before Fright	After Fright	Before Fright	After Fright
1	39	39.5	37	39	37	40	39.25	39.5	39.25	39.75
2	39	40	37.5	40	37	40	39	39.5	39.25	39.25
3	37	39	37.5	39.5	39	39	37.5	39.75	38.75	
4	37	39	.....	.....	38.25	39.5	39	39.5	38.5	38.75
5	37	38.5	.....	.....	37	38	39.75	41	40	40.75
6	37	38.5	.....	.....	37	38.5	39.5	39.25	39	40.5
7	37	38.75	.....	.....	37.5	40	39.25	39.5	39.5	39.5
8	36	36.25	.....	....	37	37.5	39	40	39	39.5
9	37.5	.....	.....	.....	37	.....	39.25	40	39	39.75
10	38.5	39.25	.....	.....	38.5	39.25	39.5	39.75	39.5	39.75
11	38.5	39.75	.....	.....	39	39.25	38	39	38	38
12	38.25	39.25	.....	.....	39	39				
13	39	41	.....	.....	38	41				
	Average elevation of temperature				1.3 C. Rabbit 1 2.2 C. Rabbit 2 1.48 C. Rabbit 3		Average elevation of temperature		0.7 C. Rabbit 1 0.45 C. Rabbit 2	

In two experiments in each of which rabbits were frightened for ten minutes twice daily for several successive days, the temperature changed during each seance of fright as shown in Table 19 (temperature given in degrees Centigrade).

Respiration.—The respiratory rate was always increased—in one instance to 140 per minute.

Pulse.—The heart beat was accelerated.

Blood Pressure.—The average blood pressure of seven normal rabbits was 76 mm. of mercury; that of two frightened rabbits was 93 mm. of mercury.

In all the experiments, half an hour of continued fright exhausted the rabbit completely, as was evidenced by the gross clinical phenomena and the position—flat on the floor with head and legs extended—assumed as soon as the cause of fear was removed.

HUMAN PHENOMENA

In persons under emotional stress the increased activation is manifested by the facial expression and by muscular and mental phenomena. The increased suprarenal activity is evidenced by the inhibition of the intestines; the participation of the liver, by glycosuria; the muscular factor, by the trembling inhibition of movement, muscular fatigue, and increased temperature; the increased H-ion concentration preeminently by the increased respiratory rate. If the emotional stress continues over a prolonged period, the thyroid gives evidence of its participation by enlargement and by the phenomena, which if they become established are characteristic of the condition designated as exophthalmic goiter.

The phenomena of this disease present striking evidence of the participation of each organ in the kinetic chain in emotional response.

During the World War, the human phenomena of intense activation, in which activation due to the emotions played a predominant rôle, were manifested on a vast scale—in the noncombatants at home, in the refugees, in the soldiers in the field and in hospitals, and in the prisoners of war. As the tide of war approached and engulfed each individual, his resultant activation was expressed in intensified consciousness—in insomnia, in exertion and in emotion, to the results of which, according to the fortunes of the individual, the stimuli of physical injury and infection may have been added.

At the American Ambulance in January, 1915, we were able to secure specimens of the brains, livers and suprarenals of soldiers who had participated in the great retreat of the allied armies from Mons to the Marne. During this retreat, goaded by shot and shell and the ever advancing enemy, they had marched for nine days and nights without adequate sleep and food, and in constant fear of capture. Each had been wounded, the wounds of each had been infected to some degree; but in no instance was either wound or infection sufficient to cause death. In the fatal exhaustion of these men, it is obviously impossible to assign the predominant rôle to insomnia, to exertion or to emotion—each unquestionably contributed its share to the fatal result. The results of the histologic examination of the brains, livers and

TABLE 20.—RESULTS OF HISTOLOGIC EXAMINATIONS IN SOLDIERS

	Cerebellum	Cerebrum	Medulla	Suprarenal	Liver
Soldier 1	No hyperchromatic cells; very few active, many exhausted, nearly all fatigued	All fatigued and exhausted	No hyperchromatic cells; few active; nearly all cells fatigued with marked loss of cytoplasm and eccentric nuclei; cytoplasm very finely granular	Outer two thirds of cortex shows loss of cytoplasm and moderate vacuolation; glomerular layer not so much affected as the central part of the cortex	Slight loss of chromatin and small vacuoles in most cells except in periphery of lobules where there is large vacuolated appearance
Soldier 2	No hyperchromatic cells; few active; nearly all badly fatigued; remaining cytoplasm in cells very finely divided; many exhausted cells	No hyperchromatic or active cells; all fatigued or exhausted, cytoplasm very diffuse	Olive cells all fatigued with marked loss of cytoplasm	Slight loss of chromatin and vacuolation of outer cells of cortex	No loss of cytoplasm but granules not distinct; no vacuolation
Soldier 3	No hyperchromatic or active cells, all badly fatigued or exhausted; loss of cytoplasm almost complete with exception of nucleoli	No hyperchromatic cells but many active cells with diffuse chromatin; no distinct granules; not many exhausted cells	Olivary cells slightly fatigued; motor cells fatigued with many eccentric nuclei	Very slight loss of cytoplasm of an occasional cell; nearly all normal	No loss of cytoplasm or vacuolation; granular degeneration of cytoplasm
Soldier 4	No hyperchromatic or active cells; all cells fatigued or exhausted	No hyperchromatic or active cells; nearly all fatigued; some exhausted	Cells in various stages of fatigue; many active olivary cells; some fatigued	Slight loss of cytoplasm of cortical cells	No loss of cytoplasm or vacuolation; stain weak and diffuse
Soldier 5	Occasional active cell; nearly all fatigued	Some hyperchromatic cells; many active; occasional cell fatigued	Occasional active cell; nearly all fatigued	No loss of cytoplasm or vacuolation	No loss of cytoplasm or vacuolation

suprarenals of these soldiers are therefore included here, since they illustrate the effects of the acme of intensified consciousness due to the utmost exaggeration of normal activations (Table 20 and Figs. 15 and 16).

CONCLUSIONS

1. Extreme emotion causes demonstrable histologic lesions in the central nervous system, the liver and the suprarenals. The first effect of fear, as evidenced by the histologic changes in the brain cells, is increased activity, manifested by hyperchromatism followed by a progressive chromatolysis if the activation is continued. After a single seance of intense fear, the initial hyperchromatism is apparently followed by a period of hypochromatism with a gradual return to the normal.



Fig. 15.—Effect of exhaustion from insomnia, exertion and emotion on the brains of soldiers (reduced from photomicrographs, ×310): *A*, section of normal human cerebellum; *B* and *C*, sections of cerebellum of exhausted soldiers. Note the disappearance of Purkinje cells.

2. Fear causes glycosuria (in cats), albumin and casts in the urine, diminished metabolism, and changes in the iodin content of the thyroid.

3. The hydrogen-ion concentration of the blood is increased by fear.

4. Preliminary observations of the changes in the specific conductivity of the cerebrum produced by fear indicate that they parallel the histologic changes; i.e., there is first an increased conductivity followed by a decrease to below the normal.

5. Clinically, extreme emotion raises the body temperature, increases the respiratory and pulse rate; and, if sufficiently intense and prolonged, produces a complete prostration, which may prove fatal.

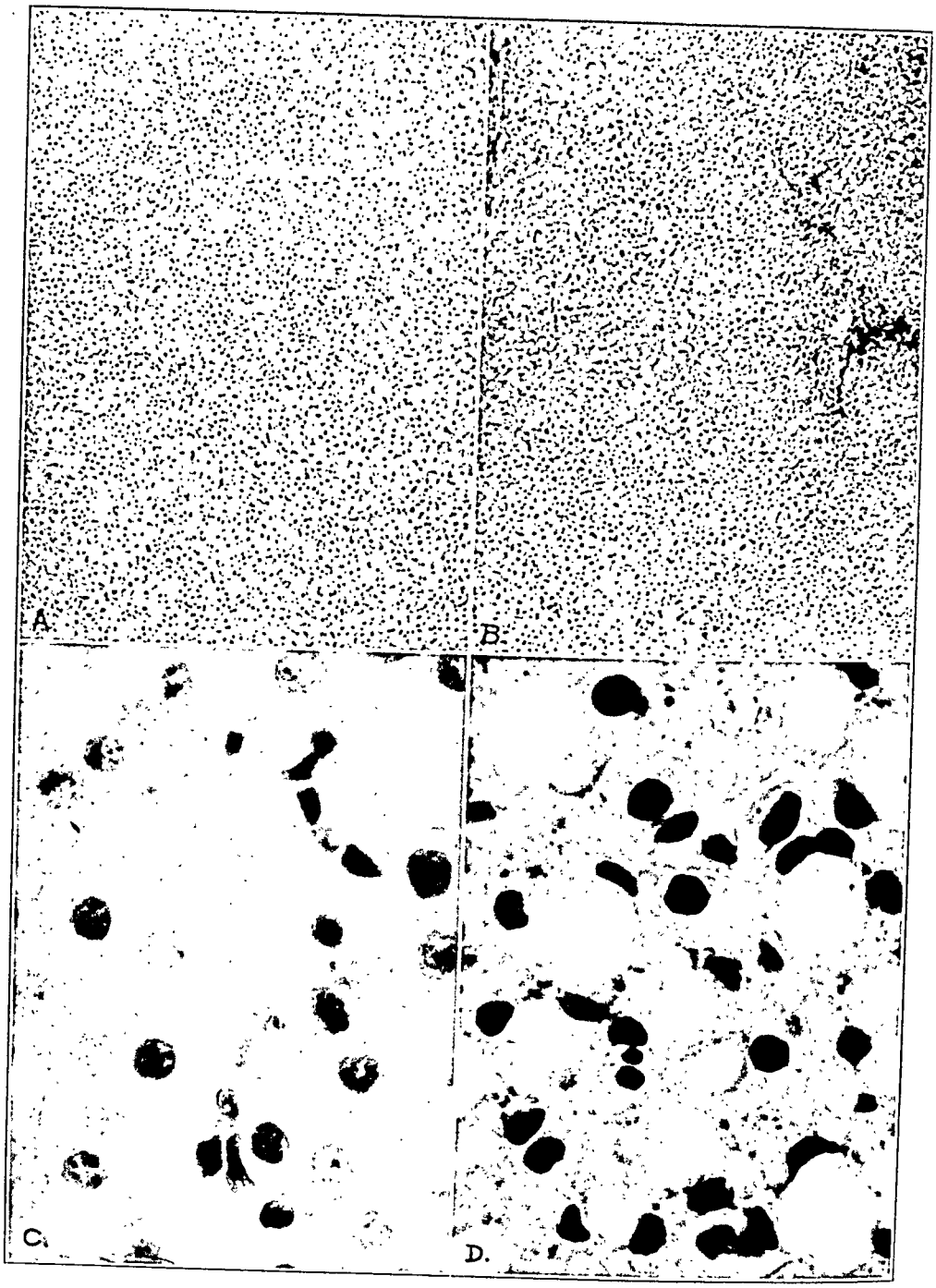

Fig. 16.—Effect of exhaustion from insomnia, exertion and emotion on the livers of soldiers: *A* and *C*, sections of normal human liver; *B* and *D*, sections from the livers of exhausted soldiers. In *B* and *D* the disappearance of cytoplasm and vacuolated spaces as compared with the evenly distributed cytoplasm in *A* and C may be noted. (*A* and *B* from photomicrographs, × 120; *C* and *D* from photomicrographs, × 1,640.)

The emotive response of timorous animals is a commonplace. As a human experience, it is universal. That it may be graded in intensity up to a critical point is acknowledged; that it may be overwhelming and suspend function is commonly observed. In our researches, we used many animals, and found, as Colonel Mott [7] has concluded, that the emotive response is one of the most powerful of which the organism is capable. Emotion causes a more rapid exhaustion than is caused by exertion, or by trauma, excepting extensive mangling of tissue, or by any toxic stimulus except the perforation of viscera. Apparently, in birds, in particular, the emotion of fear may instantly overwhelm the organism, as when a bird is unexpectedly confronted by a snake.

In our experiments, fear caused profound changes in the cells of the brain, the liver, and the suprarenals; in some cases an acidosis developed acutely; in some cases albumin and sugar appeared in the urine; the epinephrin output, as has been demonstrated by Cannon, was increased; the electric conductivity of the brain, the liver and of other organs was altered.

In short, our researches have shown that the emotions drive the organism with extreme intensity; that, like trauma or exertion, emotion may drive the organism within the limits of normal response, or so overwhelmingly as to suspend the normal functions and reduce the individual to a state of complete, cold prostration. In other words, emotion may cause exhaustion; it may cause shock.

---

7. Mott, F. W.: War Neuroses and Shell Shock, New York, Oxford University Press, 1919.

STRUCTURAL RESULTS OF PROSTATECTOMY WITH REFERENCE TO METHODS OF ENUCLEATION

BASED ON A STUDY OF ONE HUNDRED AND THIRTY-SIX CASES *

FRANK HINMAN, A.B., M.D.

SAN FRANCISCO

A recent analysis of my own cases of prostatectomy [1] shows a close relationship between functional and structural results and emphasizes the fact that good anatomic restoration is essential to a complete cure of the prostatism. The failure of good posterior urethral restoration and of preservation of sphincters and ejaculatory ducts may be the result of anatomic changes produced by the disease or by the surgical procedure. It is seldom that uncomplicated prostatism can so alter anatomic structures as to be incurable. Unsuccessful and incomplete enucleation of the hyperplastic mass is, however, one of the chief surgical errors that lead to immediate functional failure, or later, to recurrence of prostatism. A knowledge of the pathology of prostatic enlargement, with the anatomic changes that accompany it, and a careful consideration of these facts in relation to either the suprapubic or perineal method of enucleation are essential to an understanding of the structural defects peculiar, as well as common, to both. Such an understanding, if well founded, should reduce the frequency and gravity of structural defects surgically produced and lead in consequence to marked improvement in functional results.

PATHOLOGY AND ANATOMIC CHANGES

The facts regarding the anatomy and pathology may be briefly stated. Hyperplasia begins in the central group of glands in separate foci and probably never as a diffuse process. Numerous spheroidal tumors result, which tend to agglomerate, and in their growth condense the peripheral gland tissue by compression to form a pseudocapsule. It is inside this false capsule that surgical enucleation is performed.[2] The posterior lobe is separated from the other lobes by

---

*Read before the Section on Urology at the Seventy-Second Annual Session of the American Medical Association, Boston, June, 1921.

1. Hinman, Frank: "Suprapubic versus Perineal Prostatectomy, a Comparative Study of Ninety Perineal and Thirty-Eight Suprapubic Cases," read before the American Urological Association, Montreal, June 2, 1921.

2. Freyer ("Clinical Lectures on Enlargement of the Prostate with a Description of the Author's Method of Total Enucleation of the Organ," William Ward Company, 1920) contends that he performs a complete pros-

the connective tissue sheath carrying the ejaculatory ducts and apparently does not undergo hyperplastic changes, so that for all practical purposes all enlargements are prespermatic. Any peri-urethral group of glandular tissue of the middle, lateral or anterior lobes may be the initial focus of hyperplasia.[3] These changes may also occur in the subcervical and subtrigonal groups and cause obstruction; but it is, indeed, rarely, if ever, that one sees enlargement of these groups without an associated enlargement of some of the chief lobes of the prostate. The type of enlargement will necessarily conform to the number and location of initial foci and their relative growth. All sorts of combinations have been observed; but the commonest is bilateral and middle lobe enlargement which is peri-urethral and more or less fused into one mass. The histopathology of this mass varies from an almost pure adenoma to myoma or fibroma; but most frequently it is a mixed fibromyo-adenoma with the glandular element predominating. The more fibrous or muscular types are smaller, the former commonly complicated by or secondary to prostatitis, and both likely to be unassociated with a false capsule. An enlargement which has no false capsule or line of cleavage is recognized as difficult of enucleation. Growth

---

tatectomy. He bases his conclusion on the following evidence (p. 156): "(1) The general conformation of the specimens removed by me indicated that they were entire prostates. (2) The absence of any palpable substance in the cavity that remained at the time of operation, as felt between a finger in this cavity and a finger in the rectum, a very thin membrane consisting merely of the bowel and sheath of rectovesical fascia lying between the points of the fingers. (3) The absence of any mass resembling prostatic tissue in the cases operated on, at any period after the operation, on examination by the finger in the rectum. (4) When the enlarged prostate projects prominently in the bladder the true capsule is at once reached on scraping through the mucous membrane covering it by the finger nail. (5) The absolute and complete relief of symptoms after operation. (6) But Mr. Thompson Walker has adduced the most cogent evidence of all by demonstrating that no prostatic tissue is found in specimens removed from the bodies of persons on whom the operation had been performed during life." It is rather hazardous to disagree with two such eminent authorities, nevertheless, I do not hesitate to do so. For all practical purposes, complete enucleation of the prespermatic portion in cases of large glands is effected by the Fuller-Freyer as well as by the radical *en masse* perineal method. The false capsule of compressed nonhyperplastic gland tissue is insignificant in these cases. In smaller enlargements, however, there is a very visible and evident false capsule composed of more or less normal gland tissue. This can be clearly demonstrated in postmortem examinations of unoperated cases of prostatism. A complete enucleation would remove the vermontanum and terminal portions of the ejaculatory ducts. This, I believe, is often done suprapubically, as has been demonstrated by a number of our perineal specimens before we appreciated the importance of incision of the supramontane urethra.

3. Freyer conceives the prostate as formed of two lateral lobes.

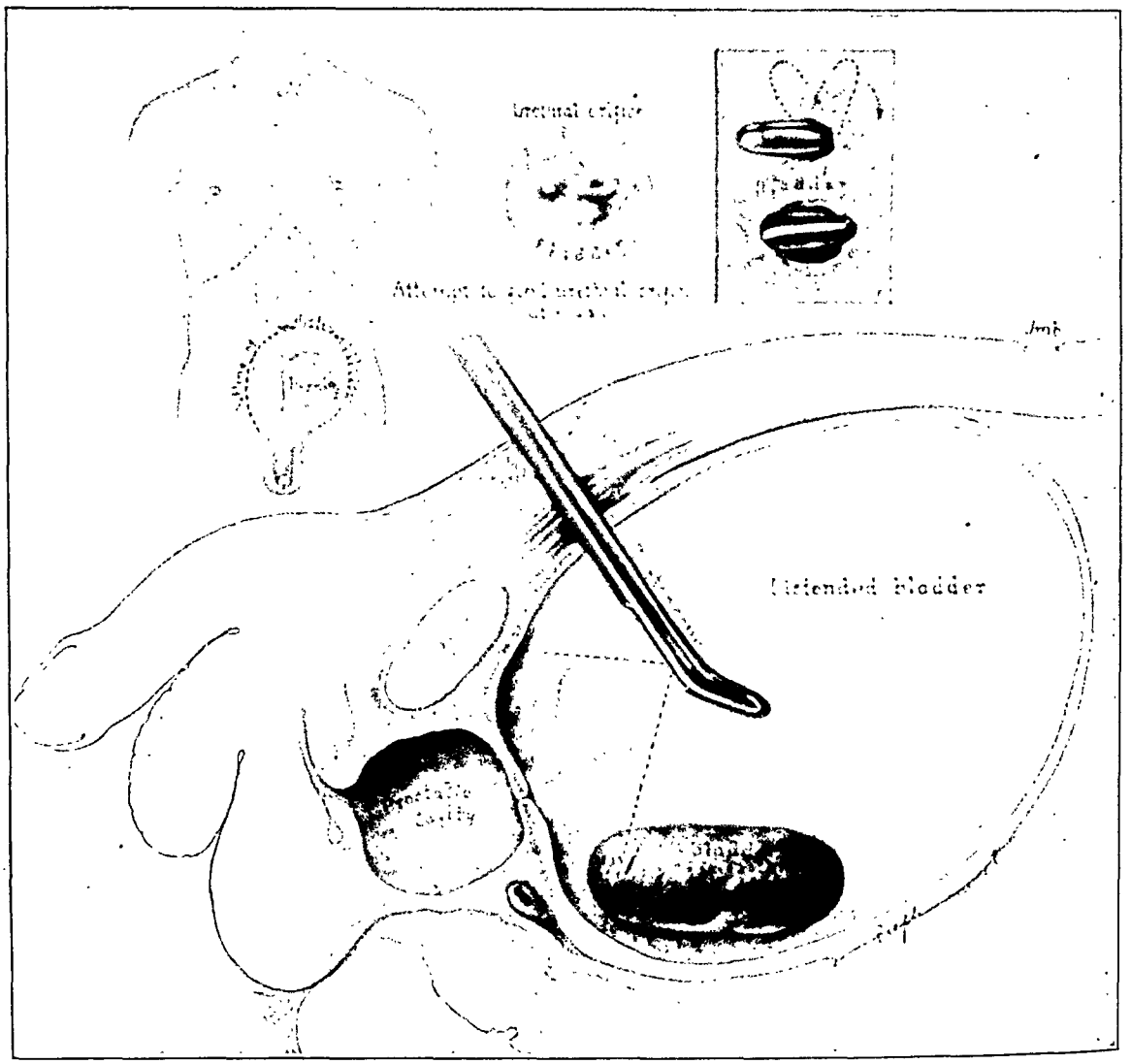

Fig. 1.—Diagrammatic representation of conditions as found in a man, aged 74, five years after suprapubic prostatectomy. He had never voided through the urethra since operation and had worn a suprapubic tube for five years. Repeated previous attempts to catheterize or dilate the urethra were unsuccessful. There were marked pyuria and renal insufficiency; a very large abdominal hernia through the scar of the suprapubic incision. There was no suspicion or evidence of cancer. Cystogram revealed double cavity, and it was at first thought that we were dealing with a diverticulum. Cystoscopically a very large prostatic cavity with an orifice that closely simulated the mouth of a diverticulum was found, through which the shaft of the instrument could be passed with difficulty. The bladder was markedly dilated and contained a large stone. Passing the cystoscope through the suprapubic sinus, a lithotrite could be made to engage at the contracted vesical orifice through the urethra (as shown in inset) and the stone was crushed under cystoscopic control. Young's punch instrument was inserted in the same way and the vesical neck contracture enlarged (inset *a* and *b*).

follows the line of least resistance intravesically inside the internal sphincter, and with large glands, the internal sphincter may be much dilated. The supramontane portion of the urethra is elongated and distorted in accordance with the type of enlargement. The verumontanum and ejaculatory ducts are pressed posteriorly, and the inframontane portion of the prostatic urethra with the external sphincter is undisturbed. What problems with reference to the enucleation of this hyperplastic mass from its prostatic bed do these facts present to the surgeon?

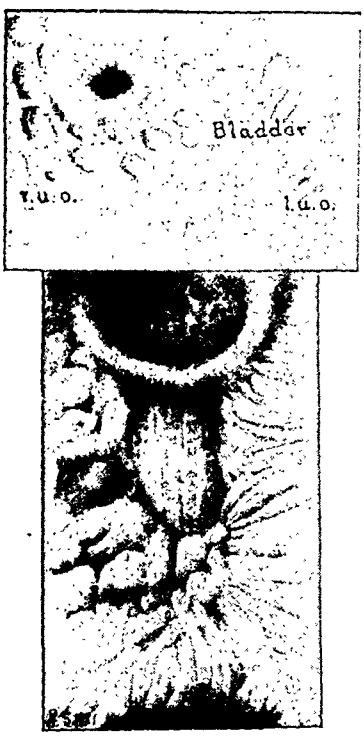

Fig. 2.—Urethroscopic appearance of prostatic urethra four years after suprapubic prostatectomy; large granular and nodular cavity with dilated vesical orifice.

METHODS OF ENUCLEATION

Suprapubic enucleation is commonly a one-piece removal performed in one of two ways: Intra-urethrally or extra-urethrally; but the hyperplastic mass is sometimes removed in separate pieces either way. Intra-urethral *en masse* enucleation has been performed by us by forcing a finger back into the urethra and tearing it anteriorly. By blunt dissection on this line of cleavage, the hyperplastic mass is freed from within outward. In a few cases, we have made an annular or linear incision of the mucosa over the intravesical mass as an entering wedge for extra-urethral enucleation, from without inward, outside the urethra.

The extra-urethral would seem to be a method better suited to surgery, although more difficult, and probably more often secures a complete removal. Whenever the gland is not brought away in one piece, it is sometimes difficult to determine whether spheroids remain, even with bimanual palpation with the finger in the rectum, which few surgeons practice because of danger of sepsis. Any of these procedures must be performed through the internal sphincter, which is thereby dilated and sometimes destroyed. The supramontane portion of the prostatic urethra is torn or more commonly completely removed. Tags and flaps

Fig. 3.—Urethroscopic appearance of prostatic urethra two years after perineal prostatectomy; persistent nodule at right side of vesical orifice; tags in prostatic urethra and small sinus persisting at site of perineal fistula which has been permanently closed. The only functional disturbance is nycturia.

of mucosa are generally left at the prostatic margin or cavity. The prostatic cavity is packed for hemostasis, thus tending to perpetuate posterior urethral elongation and cavity formation.

Perineal enucleation, if Young's technic is followed, preserves the prostatic urethra throughout, and rarely is either the internal sphincter or vesical mucosa disturbed. The bilateral posterior lobe incisions render possible good preservation of the ejaculatory ducts and verumontanum. When properly performed, the external sphincter remains untouched. The gland is enucleated in separate portions, first the right,

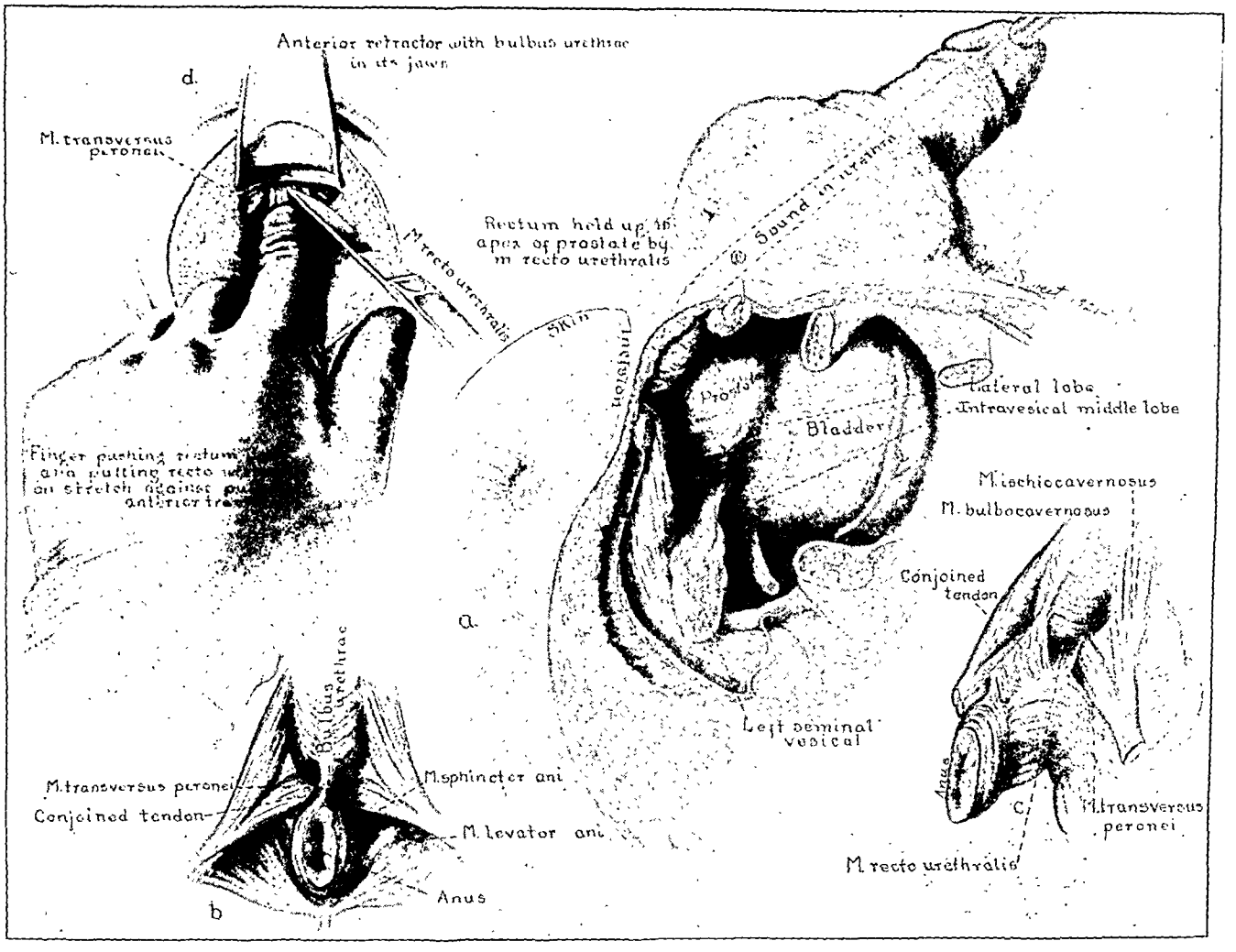

Fig. 4.—The all important recto-urethroprostatic juncture; *a*, close apposition of bulbus urethrae, triangular ligaments carrying the external sphincter, rectum and apex of the prostate; *b*, exposure of the membranous urethra keeping close to the rectum in order to preserve the perineal union and not injure the bulb, transversus perinei or triangular ligaments with the external sphincter; *c*, correct division of the conjoined tendon and recto-urethralis muscle; careless dissection may injure rectum or perineal union; *d*, separation of rectum from apex of prostate is best effected by knife and blunt dissection putting the recto-urethralis muscle on stretch by pressing rectum down with finger and pulling the bulb with the external sphincter and triangular ligaments up with anterior retractor.

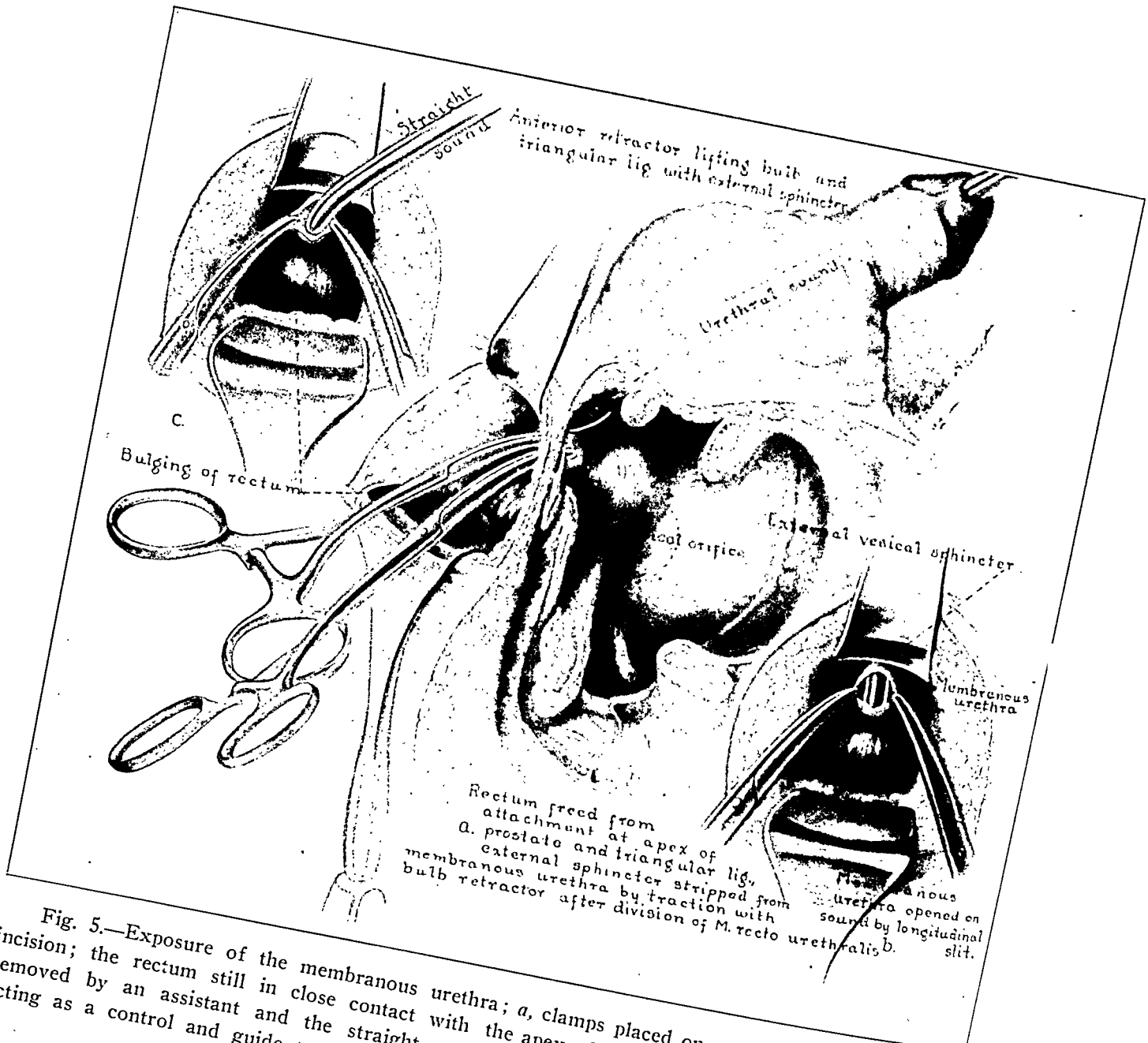

Fig. 5.—Exposure of the membranous urethra; *a*, clamps placed on each lip of the longitudinal incision; the rectum still in close contact with the apex of the prostate (*b*); *c*, the urethral sound removed by an assistant and the straight sound inserted into the bladder through the incision, acting as a control and guide to the insertion of Young's prostatic tractor.

then the left lobe, or vice versa, and an anterior or middle enlargement is finally delivered through one or the other of the lateral incisions. Successfully executed, the method is surgically ideal. Technical difficulties are increased with the ring type, and very large hyperplasias and these difficulties, probably more than the anatomic difficulties of approach, appeal to me as the important factors leading to the general disrepute of a perfect surgical procedure.

STRUCTURAL DEFECTS OF SUPRAPUBIC AND PERINEAL PROSTATECTOMY

The common defect in structure following suprapubic enucleation is a failure of restoration of the prostatic urethra, which is replaced by a larger or smaller cavity, either infundibular or spindle shaped, according to its association with a widely dilated or contracted vesical neck (Figs. 1 and 2). Incomplete enucleation may leave nodules or large lobes at various parts of the cavity or neck, which may be so placed as to impair sphincteric action, resulting in dribbling, or, to prevent complete evacuation, resulting in continued frequency and urinary infection. Tags of mucous membrane or other tissue left in the prostatic ensemble or about the neck may repair in such a way as to act as an irritant or even a ball valve polyp, producing marked disturbances of urination.

Cavity formation rarely follows the perineal operation; but structural defects at the neck from the presence of nodules or tags are common, and unless the operator is familiar with the perineal method, nodular remnants, due to incomplete removal of all the hyperplastic mass, are more likely to remain than after the suprapubic operation (Fig. 3). These cause functional disturbances and may lead to recurrence of prostatism. Deep fissure or sulcus formation is also not uncommon, particularly in cases after removal of very large glands, and, in such cases also, mucosal plication may lead to obstruction to instrumentation as well as urination.

MODIFIED METHOD OF PERINEAL ENUCLEATION

The radical *en masse* enucleation as usually done suprapubically insures more certain and complete removal of the hyperplastic tissue than does the lobular removal by the perineal method. This fact raises the question as to whether block enucleation through the perineum might not secure cleaner and more complete removal and at the same time give better structural restoration, or whether a one-piece perineal enucleation with divulsion of the prostatic urethra might leave, as is common suprapubically, a large prostatic cavity, or finally whether such radical removal would be more likely to injure the ejaculatory



Fig. 6.—Method of enucleation: *a*, the rectum has been dissected from the posterior surface of the prostate along line of fascia of Dénonvillier and is held out of the way by the deep posterior retractor; the prostatic mass is drawn down into the wound by the prostatic tractor, and ready for incision for enucleation; *b*, a wide inverted V incision is made in the posterior lobe well into the hyperplastic mass; *c*, the pointed flap of posterior lobe when thrown back exposes the verumontanum and ejaculatory duct orifices. A diamond shaped block of prostatic urethra is preserved by a second inverted V incision of the mucosa with its apex just above the superior crista of the verumontanum; *d*, depression of the prostatic tractor exposes the roof of the membranous urethra which is divided with scissors so as to free completely the urethral end of the prostatic urethra. The hyperplastic mass is freed *en masse* by blunt dissection, or adhesions can be accurately divided with knife or scissors.

ducts. In order to arrive at an answer, we have now performed twenty-five perineal operations by a modification of Young's method of enucleation, whereby the hyperplastic gland may be removed in one piece just as is done suprapubically. The one purpose is to secure complete and clean removal and at the same time preserve the ejaculatory ducts, the verumontanum and both sphincters as effectively as by the old method. No attempt is made to preserve the supramontane portion of the urethra.

The technic of conservative perineal prostatectomy as practiced and taught by Hugh H. Young is followed up to the incision of the posterior lobe for the purpose of enucleation. The anatomic difficulties of approach of this operation are mastered with a thorough knowledge of the recto-urethro-prostatic juncture (Fig. 4). Injuries of the rectum or external sphincter never follow a properly performed perineal exposure.[4] The urethra at its membranous portion is opened by a longitudinal incision (Fig. 5), and after the insertion of the prostatic tractor, the rectum can easily be separated from the prostate along the line of Dénonvillier's fascia (Fig. 6*a*). After the prostate is well exposed, instead of making two lateral incisions into it, after Young's technic and as was done in our first sixty-five cases, an inverted V incision having a wide obtuse angle, the apex of which is at the opening into the membranous urethra, is used (Fig. 6*b*). This incision is deepened well into the lateral spheroids, or, if no lateral hyperplasia exists, is continued down through the urethral mucosa to the prostatic tractor (Fig. 6*c*). When so extended, it allows one to drop back the verumontanum and ejaculatory ducts in a triangular flap of the posterior lobe, thus giving wide exposure of the prostatic urethra (Fig. 6*c*). It is important now that the prostatic urethra above the verumontanum near the bladder be incised by another inverted V or elliptic cut so as to free the supramontane urethra completely from this flap portion (Fig. 6*c*), as otherwise the colliculus might be torn or mutilated by the manipulation to follow. Division of the roof of the membranous urethra with scissors (Fig. 6*d*) now frees the whole prespermatic portion. The hyperplastic mass can be easily and accurately dissected loose with perfect preservation of the internal sphincter (Fig. 7), and when the prostatic urethra has been divided at its vesical end with scissors or knife (Fig. 7*b*), this mass can be removed *en masse* on the shaft of the prostatic tractor (Fig. 7c). Tactile and visual inspection of the vesical neck is now easy, and tags or defects may be remedied by the proper procedure (Fig. 7*d*). Small

4. In ninety cases we have had but one rectal injury, caused by an inexperienced assistant holding the retractor so that its edge dug into the rectal wall. This fistula closed promptly and spontaneously. We have not one case of incontinence from injury to the external sphincter.

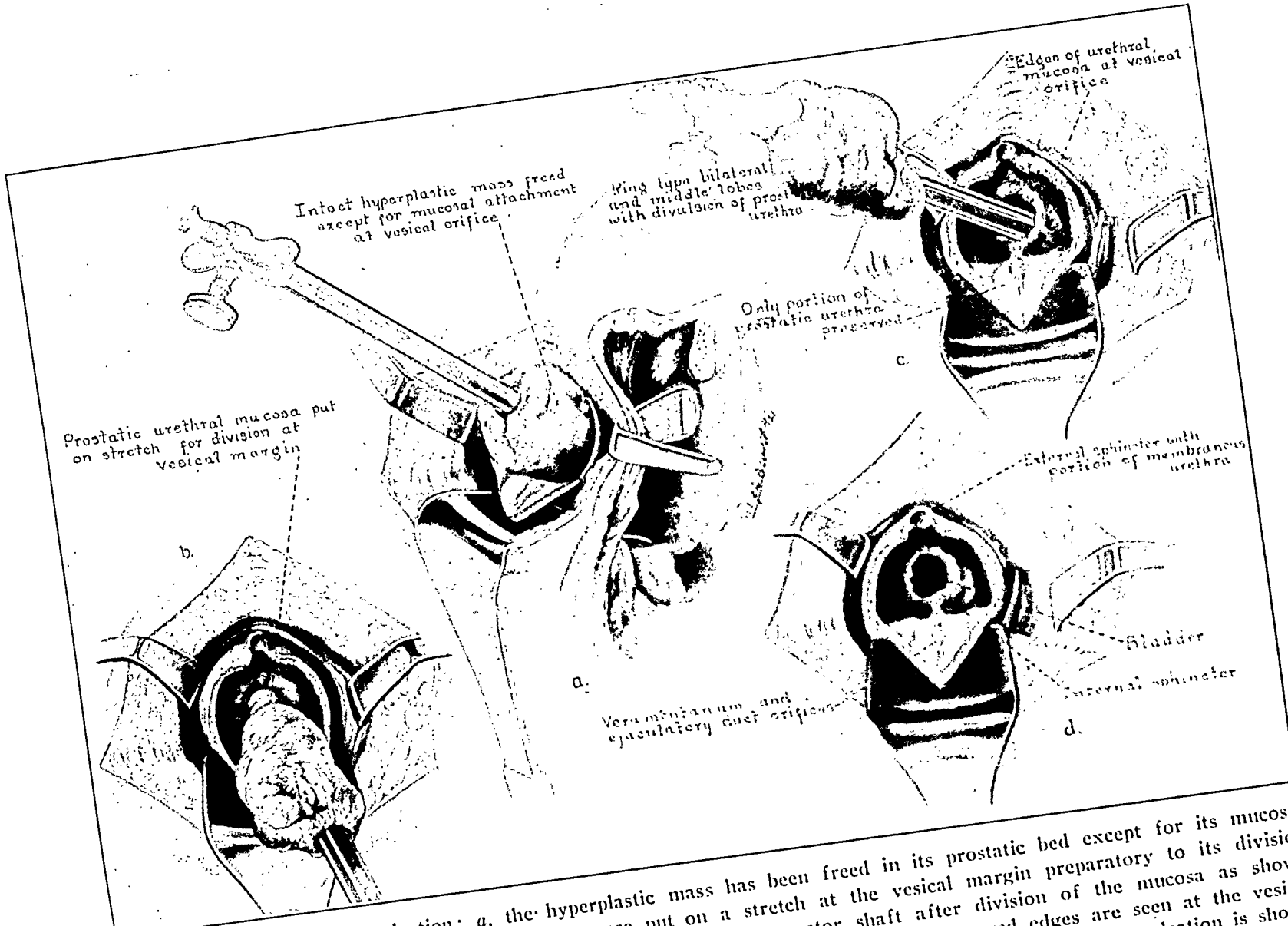

Fig. 7.—Method of enucleation: *a*, the hyperplastic mass has been freed in its prostatic bed except for its mucosal attachment at the vesical end; *b*, the urethral mucosa put on a stretch at the vesical margin preparatory to its division with knife or scissors; *c*, ring type hyperplastic mass slid out on tractor shaft after division of the mucosa as shown in *b*. The greater portion of the prostatic urethra has been removed with it. The ragged edges are seen at the vesical margin. Internal sphincter has been surgically preserved; the structural result of perineal *en masse* enucleation is shown at *d*. Prostatic urethra divulsed; internal and external sphincters preserved; ejaculatory ducts and verumontanum preserved; healing is possible with almost complete, or complete, obliteration of the prostatic cavity and for this healing the methods of drainage and of packing for hemostasis are important.

subcervical or intravesical lobes which failed to come away with the main mass can now be accurately and cleanly removed.

The enucleation having been completed, a catheter on a stilet is passed through the urethra by an assistant, and its end is inserted into the bladder alongside the tractor, which is then removed (Fig. 8). The catheter is thus placed for reestablishment of the urethra as is done in external urethrotomy. A second catheter is placed through the perineum into the bladder for the purpose of through-and-through irrigation. The prostatic cavity is lightly packed about the two catheters passing through it, with one strip of gauze (Fig. 8*b*), which is brought out with the perineal catheter at one side. The triangular flap of the posterior lobe, carrying the ejaculatory ducts and verumontanum, is replaced in position by a mattress suture of chromic gut on the side opposite the gauze and catheter (Fig. 8*c*). An infraprostatic gauze pack is placed for the purpose of cavity obliteration and hemostasis (Fig. 8*d*). Closure now follows the usual technic (Fig. 9.) The gauze and perineal catheter are removed after twenty-four hours. It is our custom to remove the prostatic pack first, and, if no bleeding follows, in one-half hour the infraprostatic pack with the perineal catheter is removed. If there is bleeding, it is readily controlled by pressure with hemostat against the infraprostatic pack, and repacking is not required. The urethral catheter is often left in from four to twelve days, and suction applied to it by a Connell apparatus or Davis bottle. In ten of the twenty-five cases the perineum remained dry after the second day and healed, to all practical purposes, by first intention.

COMMENT

This type of inverted V incision of the posterior lobe is not new as it was used by Young in his earliest cases but has been replaced by two lateral incisions because it was thought that better anatomic preservation was thus possible. Any systematic effort for clean, complete removal of the enlarged prostatic mass in one piece through the perineum, however, has not been previously made. With medium-sized enlargements of glandular type, removal through lateral incisions is satisfactory, and remarkable preservation of the mucosal layer of the prostatic urethra, leaving the verumontanum and ejaculatory ducts intact, is possible. But in enucleating large glands, tears and extension of the lateral incisions to the membranous urethra almost invariably result, and this leaves a very narrow strip of tissue as the ejaculatory bridge. The ejaculatory ducts and verumontanum can be satisfactorily preserved with the V type of posterior lobe incision irrespective of the size and pathology of the hyperplasia. A good view of the vermontanum can always be had, and the necessary amount of mucosa for its preservation can be trimmed off with knife or scissors from the supra-

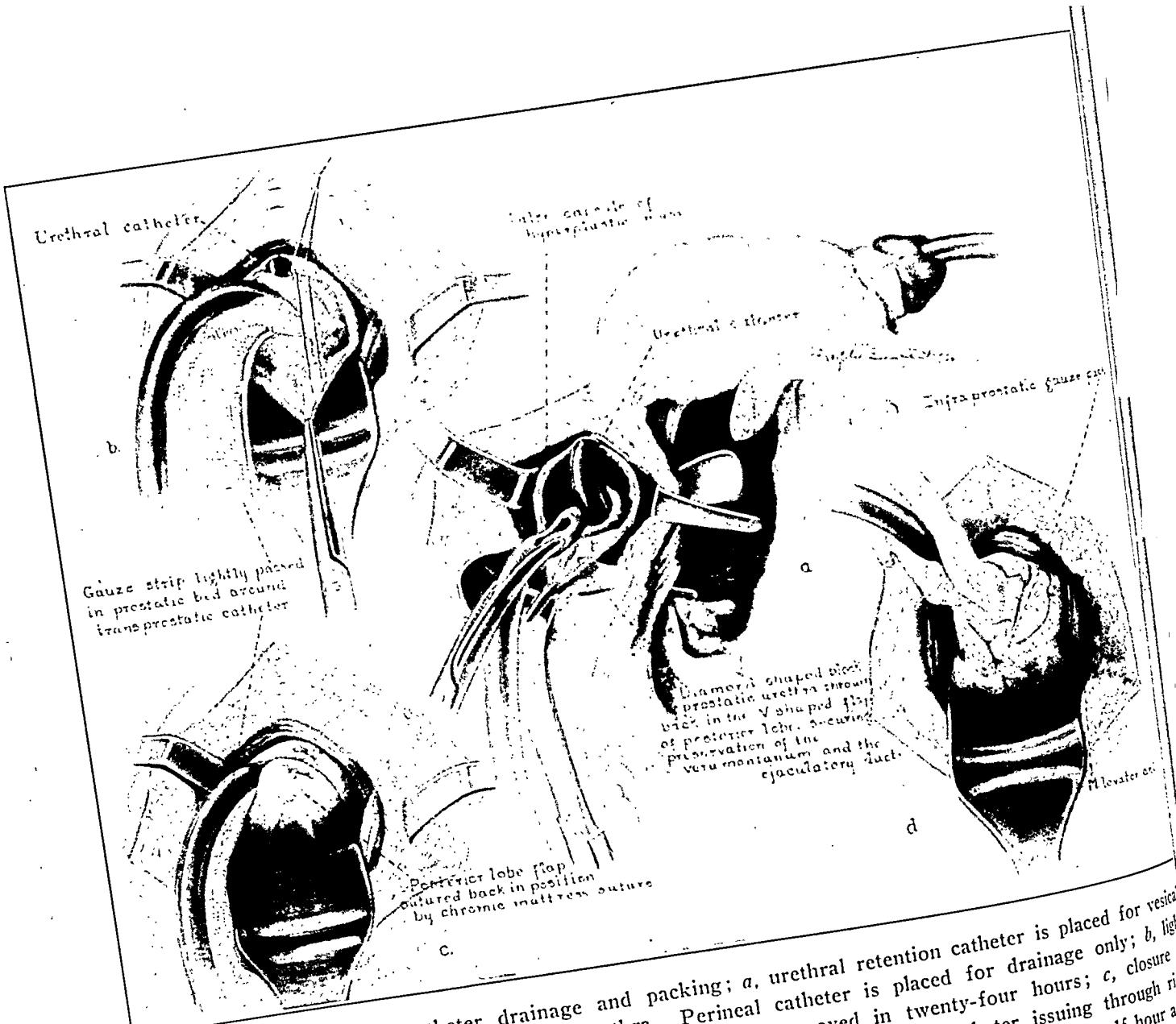

Fig. 8.—Method of catheter drainage and packing; *a*, urethral retention catheter is placed for vesical drainage and reestablishment of prostatic urethra. Perineal catheter is placed for drainage only; *b*, light prostatic gauze pack in the prostatic bed for hemostasis; removed in twenty-four hours; *c*, closure of the prostatic flap by a mattress suture on the left with gauze and perineal catheter issuing through right sided slit; *d*, placement of a large or small infraprostatic gauze pack which is removed one-half hour after the prostatic gauze is removed provided there is no hemorrhage.

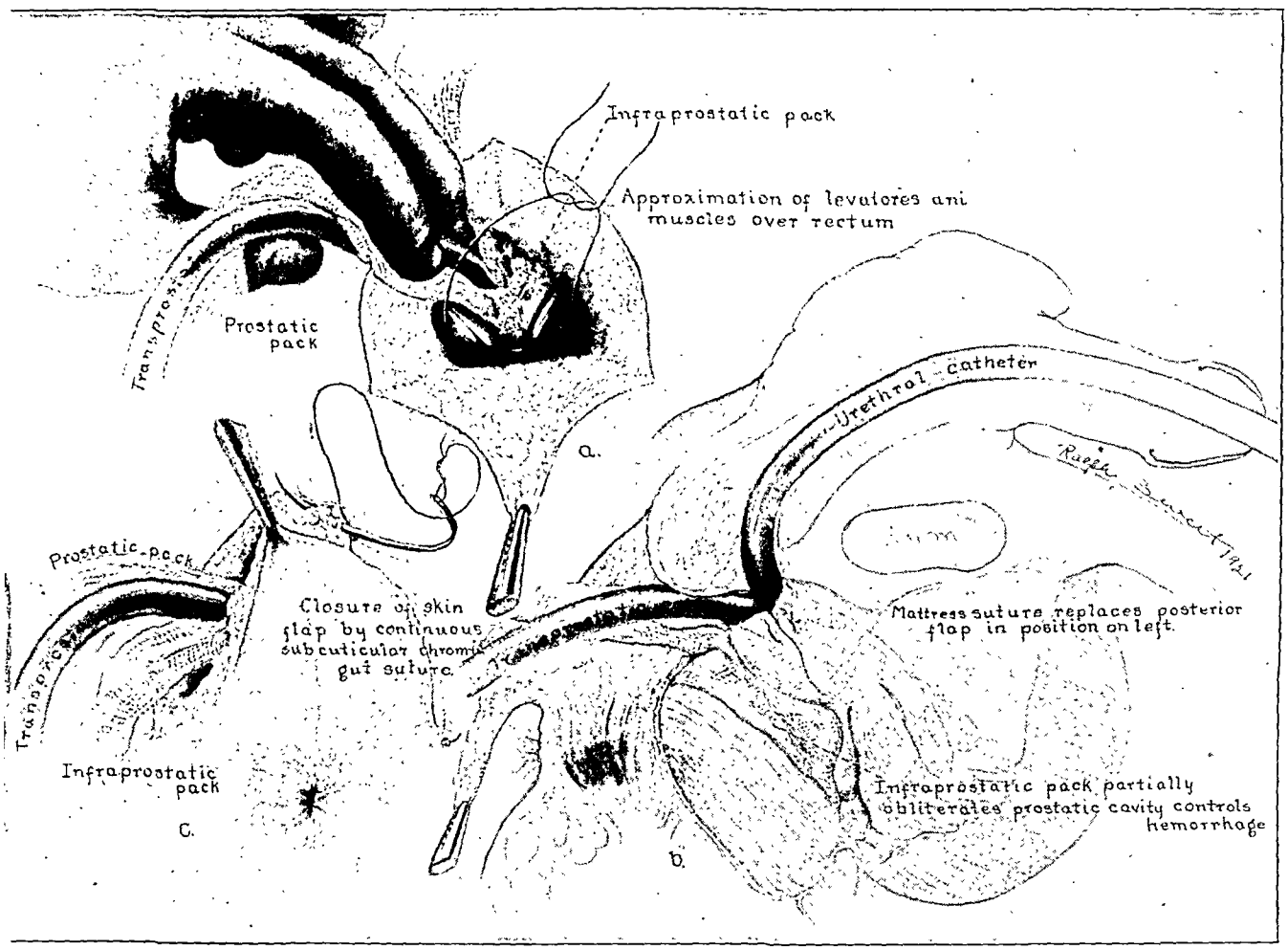

Fig. 9.—Method of drainage and packing: *a*, protection of the rectum by approximation of levatores ani between it and infraprostatic gauze pack; *b*, urethral catheter establishes the prostatic urethra and the infraprostatic pack obliterates the prostatic cavity; *c*, method of closing skin with subcuticular chromic gut. The catheter and gauze strips have an exit at one side. The former anchored with silk suture, the latter marked so that the prostatic pack can be first removed.

Fig. 10.—Ring type of bilateral and middle lobe enlargement removed in recent case through the perineum. Small fibromyo-adenoma enucleated *en masse* with complete preservation of colliculus and internal sphincter, but with removal of the supramontane portion of the prostatic urethra.

Fig. 11.—Side view, showing long mass of hyperplasia extending intravesically posteriorly to form the middle lobe.

Fig. 12.—Large bilateral and middle lobe removed by way of the perineum in Case 13 (reported in accompanying table). Glandular type hyperplasia with clean-cut separation, anteriorly, of lateral lobes which fuse with middle lobe posteriorly.

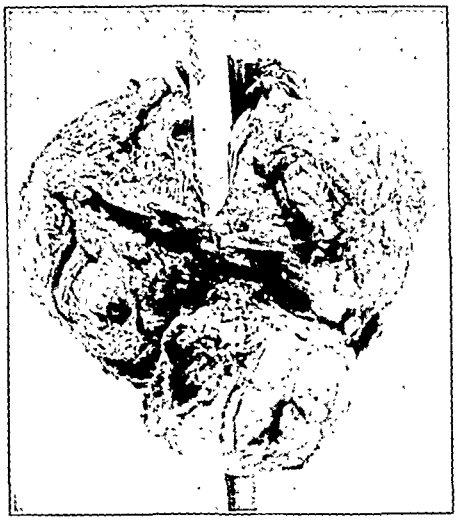

Fig. 13.—Large glandular ring type hyperplasia, enucleated intact by way of the perineum before the importance of incision of the supramontane portion of the prostatic urethra was appreciated. The colliculus and terminal portions of the ejaculatory ducts have been removed with the prostatic urethra.

Fig. 14.—Posterior urethra spread apart to show verumontanum; same case as shown in Figure 13.

Fig. 15.—Posterior view showing distal ends of torn ejaculatory ducts; same case as shown in Figure 13.

l number	1	2	3	4	5	6
I Urination:						
e the average number of voidings during the day	6	4 to 6	Every two to four hours	3 times	4-5 times	About every 2 hours
Do you get up at night to void?	Yes	Never more than once, sometimes none	Yes	Yes	No	Yes
Give the average number of times	2	.....	Twice	Once or twice	0	Three times
Give the approximate time of night that these voidings occur	2 a. m.	2 to 4 a. m. or not at all	2:30 a. m.-6 a. m.	Towards morning	.....	.....
Do you have burning on urination?	No	No	No	No	0	No
Do you have hesitancy of urination?	No	No	Yes with little dribbling	No	0	No
Do you have difficulty of urination?	No	No	None	No	0	No
Do you have dribbling of urine?	Yes	No	Yes	No	0	No
1. Is this at end of urination?	Yes	.....	Yes, before and after	.....	.....	.....
2. Is this between urination?	Yes	.....	Occasionally on *exertion*	.....	.....	.....
Do you have good control of urination?	Fairly good	Yes	Except as above stated	Yes	Very good	Yes
What is the character of your urine:						
Clear?	Clear	Clear	.....	Clear	Yes	Clear
Or cloudy?	.....	.....	Slightly	.....	.....	.....
II. Regarding Your Sexual Life Since Operation:						
1. Have you sexual desire?	Yes	Yes	Yes	No, not often	Occasionally	Yes
2. Do you have erections?	No	Yes	No, my operation completely emasculated me	No	No	.....
A. Are they satisfactory?	.....	Yes	.....	.....	.....	Not very
B Or unsatisfactory?	.....	.....	.....	.....	.....	Unsatisfactory
3. Have you had sexual intercourse?	No	Yes	If penetration is essential, no	Seldom	No	Yes
A. If not, has it been attempted?	Yes	.....	Attempted twice since leaving hos. Decidedly *unsatisfactory. There* was seminal discharge but incomplete and unsatisfactory	Seldom	No	.....
B. Or not attempted?	.....	.....	.....	.....	.....	.....
C. Give average frequency and character	.....	Once in two weeks	.....	.....	.....	.....
4. Is ejaculation complete?	.....	Yes	.....	.....	.....	.....
5. Do you have seminal discharge?	No	Yes	As stated above	No	No	.....
III. General Condition:						
1. Do you consider yourself cured of your prostatic trouble?	Yes, with exception of the dripping	Yes	Yes, as far as ability to void urine	Yes	Yes	Yes
A. If you do not, please describe the character of present disability	.....	Loss of sexual power	.....	.....	.....	.....
2. How does your general health compare with what it was previous to operation?	Good, only I am suffering from neuritis which I had before operation and I get pretty bad at times which you can see by my writing as I can hardly hold my pen	Very good	It is somewhat improved. I have good physical endurance, can walk and drive my auto long distances, 200 miles at one sitting without fatigue	Much better	Fully as good	Good
Remarks	Catheter life for 1 year before operation. Has been seen since above answers were *received* and "dripping" is insignificant	Periodic catheter life for 3 years	Coudé catheter broke off in prostatic urethra after operation and fragment had to be removed on 5th day per perineum followed by pronounced urinary infection with bilateral epididymitis; had intermittent catheter life for 6 months before operation	Man of 88 had a huge prostate and left hospital wearing a urinal on account of dribbling. Final result is a complete cure. Had led catheter life for 5 months	Very large prostate in man of 76. Catheter life for 6 months	Complete retention and marked vesical distention on admission, 5 weeks preparatory treatment. Had led catheter life for 3 months

7	8	9	10	11	12	13	14	Summary
5 to 6	4	4-5	3 to 4 hrs.	4 to 5	3 to 4 times	About every 4 hours	4 times	4 to 5
Yes	No	Yes	Yes	No	Yes	Yes	Yes	No, 3 Yes, 11
Always once sometimes twice	No	2-3, get up for bowel movement void at same time	3 to 4 times	.....	6 to 7	Two	2	2
6 a. m.	.. ..	.....	.....	.....	....	12 and 4	2-5 a. m.	
No	No	No	I do	No	No	No	No	No, 13 Yes, 1
No	No	No	No	No	No	No	Occasionally	No, 12 Yes, 2
No	No	No	No	No	No	No	No	No, 14
Slight in morning	Slight	No	Yes	No	No	No	No	No, 9 Yes, 5
Yes	Yes	.....	No	.....	.....	.....	.....	4
No	No	.....	Yes	.....	.....	.....	.....	3
Yes, very good	Yes	Yes	Fairly good	Yes	Yes	Yes, very good	Yes	Yes, 14
Yes	Yes	.....	.....	Yes	Yes	.....	Yes	10
.. ..	.....	Occasionally	Cloudy, strong odor	.....	.....	Yes	.....	4
Sometimes	Yes	.....	No	No	.....	Practically none	Yes	9
Partial	Few	.....	Very little	No	No	No	Yes	6
No	No	.....	No	.....	.....	.....	Yes	No, 4 Yes, 3
Yes	.....	.....	Yes	.....	.....	.....	.....	4
No	Yes	.....	No	No	No	No	Yes	5
No	....	.....	No	No	No	No	.....	2
.....	.....	.....	.....	Not attempted	.....	Yes	.....	6
... .	Once or twice a week	.....	.....	.....	.....	.....	Once every two weeks	
None	No	.....	.....	.....	.....	.....	Yes	2
Not attempted. No intercourse 2 yrs. before operation	No	.....	Yes	No	No	No	Yes (watery nature)	3
Yes	Yes, but in voiding the urine comes freely for a while but sometimes shuts it off before I get through and there is a dribbling for a time	Yes	Yes	Yes	Yes	Yes	Yes	14
Excellent much better than before operation	Decidedly better	Improved	Much better	Greatly improved	My health is as good as before operation, my only trouble is that my legs are very weak from thigh to knee	Much improved	Very much improved	Improved in 12 As good in 2
Preliminary cystotomy and removal of large vesical calculus. Periodic catheterization for 3 months	This man has since been cystoscoped and a small tag of mucous membrane at the vesical margin removed by fulguration with complete relief of dribbling and hesitancy. Had complete retention before operation and used catheter 3 months	This patient has senile dementia which was present before operation	Had pronounced pyuria and bilateral pyelonephritis with cystitis before operation	Catheter life for 1 year before operation	This patient has a chronic nephritis and cardiac decompensation. Under preparation for 6 weeks. Had periodical incontinence on admission	Catheter life for 4 months before operation	Intermittent catheter life for 6 months	All were advanced cases of prostatism and had been compelled to use a catheter intermittently or regularly

montane portion, so that when this is removed later, with the hyperplastic mass, tearing of the vermontanum and consequent disturbance of the ejaculatory ducts do not occur. Before we appreciated the importance of the deep incision in this supramontane portion of the prostatic urethra, in two or three instances the verumontanum with the ends of the ejaculatory ducts was torn away with the hyperplastic mass (Figs. 10 and 11). These experiences lead us to believe that the colliculus and the terminal portions of the ejaculatory ducts are often similarly removed in suprapubic *en masse* enucleation.

Attempts to preserve the membranous coat of the prostatic urethra when one follows Young's technic in patients with big prostates are usually unsuccessful. In view of the deep sulci and the distortion and elongation of the prostatic urethra in these cases, preservation seems undesirable. So much loose unattached mucous membrane may be so folded or plicated that it forms obstruction to instrumentation as well as urination and prevents good structural healing. The ability of urethral mucosa to repair is familiar to every urologist who can readily recall extensive resections of the urethra in performing external urethrotomies and the rapidity with which these gaps fill in. Complete divulsion of the prostatic urethra is universally practiced in suprapubic enucleation, and it ought not to be more mutilating when done perineally under direct control of the eye. However, is such complete divulsion of the prostatic urethra responsible for the large cavity formation so much more frequently encountered after suprapubic prostatectomy? This is doubtful. Cavity formation is more readily accounted for by the difference in methods of packing for the control of hemorrhage and the anatomic difference of enucleation. Suprapubically, the whole enlargement must be shelled out through the internal vesical sphincter, and often the vesical mucosa is stripped back from the bladder wall. Perineally, only the intravesical portion of the gland is drawn back through the sphincter, which is undisturbed surgically. The suprapubic operator packs the cavity full from above, elongating and exaggerating the prostatic space and often adding to the separation of the vesical margin from the prostatic cavity. The perineal operator packs lightly and partially from below and relies largely on infraprostatic compression for hemostasis, which tends to foreshorten the prostatic space and obliterate the cavity. Repacking suprapubically only exaggerates and prolongs the existence of the cavity. Repacking through the perineum is almost invariably an infraprostatic compression with further obliteration of the cavity. In none of our twenty-five cases of *en masse* enucleation by prostatic urethral divulsion through the perineum has cavity formation ever occurred.

The great advantage of this modification is that it secures a more complete removal of the hyperplasia. Ring type enlargements are quite frequent, and even if they are not typical, there

is some fusion of tissue between the separate lobes (Fig. 13), and it is an easy and no uncommon matter to leave behind small or large spheroids at the region of separation of these lobes when they are removed separately or in portions. The smaller fibrous enlargements, particularly, tend to be ring type, and resection of such enlargements is extremely difficult and incomplete when performed by segments, but much simpler and more certain when removed *en bloc* (Fig. 12). The absence of a pseudocapsule makes such removal very unsatisfactory suprapubically, but is an insignificant factor perineally because of the good exposure obtained by laying the posterior urethra wide open, with the inverted V type incision. There is no comparison between the accuracy and ease of *en masse* enucleation by the two methods. Perineally, with blunt dissector, scissors or knife, one can perform an accurate surgical resection under direct control of the eye.

The cases that have been treated by this modification have been reported elsewhere.[5] The importance and perfection of certain details of operative technic and of methods of drainage and packing were not fully realized in the first ten or twelve cases. In the accompanying table, however, the actual answers to a questionnaire are given by these earlier patients in whom one year or more has elapsed since operation and in all of whom radical *en masse* enucleation was performed. All fourteen state that they are cured of prostatism; two have complete preservation of sexual function, and in five others, it is diminished and partial, untried in seven.[6]

The immediate results of the more recent twelve cases, in which the perfected details of the procedure were applied, have all been completely satisfactory. The average stay in the hospital after operation has been twenty-three days, and the average time for closure of the perineal fistula has been five days. Seven cases have closed to all practical purposes by first intention, there being no urinary leakage after a few hours from the time of removal of the perineal drain. In two cases, however, owing to urethral and urinary infection, the urethral catheter had to be removed early and closure was delayed, and by granulation being complete on the fourteenth and nineteenth day, respectively. One patient whose perineum healed by first intention had quite a profuse secondary hemorrhage on the ninth day, which acted and was treated similarly to the hemorrhage following a punch operation. The convalescence was uneventful in six cases; two patients

5. Cases 30 to 50, inclusive, and Case 11 of Group A; Cases 38, 39 and 40 of Group B, "Suprapubic Versus Perineal Prostatectomy" read at the Montreal meeting of the American Urological Association, June 2, 1921.

6. Before operation, sexual life was stated as normal in only four of the fourteen cases; the other ten having markedly diminished, lost or unknown, because untried, sexual ability.

had troublesome cardiac insufficiency, one renal insufficiency, two a mild phlebitis and six rather marked pyuria, with evidence of urinary infection. Only two patients had epididymitis after operation. The general and functional result indicates a complete cure in all these recent cases. Five patients have stated that their sexual life was normal before operation. It was lost or absent in two, diminished in three and not stated in two. It is already known that in three, normal sexual life has been resumed.

CONCLUSIONS

Failure of complete restoration of function after prostatectomy is commonly associated with structural defects. Suprapubically, the common defect is the persistence of a large prostatic cavity. Perineally, the defect is commonly due to nodules or lobular remnants from incomplete or irregular enucleation. It is possible to perform a one-piece perineal prostatectomy, remove the hyperplasia with the associated prostatic urethra completely and cleanly, and at the same time surgically preserve both vesical sphincters and the colliculus and ejaculatory ducts. The structural result in such a radical procedure is surprisingly good, and less apt to be defective than when done suprapubically. A large prostatic cavity has never resulted, and the prostatic urethra becomes quickly reestablished. The functional results have been entirely satisfactory in twenty-five cases.

RELAXED PELVIC FLOOR: END-RESULT IN SIXTY CASES *

ELLIOTT C. CUTLER, M.D., AND C. HAROLD JAMESON, M.D
Resident Surgeon and Assistant Resident Surgeon, Respectively,
Peter Bent Brigham Hospital
BOSTON

INTRODUCTION

The purpose in undertaking this study was to determine what operative procedures, in cases of relaxed pelvic floor, have given the best results in this clinic. Between the years 1913 and 1920, 130 patients were operated on for some form of relaxed pelvic floor. The nomenclature used was varied: cystocele, rectocele, prolapse, procidentia and relaxed pelvic floor. Of these, sixty patients reported in person for subsequent examination, twenty-nine reported by letter and forty-one could not be located. The cases of the sixty patients that were examined are reported in full, and certain deductions are drawn from the results in these patients. The results in the twenty-nine cases as given by letter or by talking with patients who refused examination are reported separately; but no deductions are made, as such observations appear unreliable. It is our opinion that only careful physical examination, after a suitable period of time has elapsed, should be used to judge the results achieved. In fact, several women returned for observation stating that they had been fully relieved, examination of whom showed that the cervix was protruding several inches from the labia. No attempt was made to select cases, and we believe that the patients returning for examination illustrate well the various types of this disability.

The extensive literature which pertains to this subject is evidence that the present methods of treatment are not entirely satisfactory. Articles appear frequently describing an improved operation or the variation of some older technic. The discussion of the principles and mechanism involved in prolapse is equally prolific. At the same time, it can be said that end-result studies are much less common, although it seems that careful studies of such results might eliminate at least a portion of the methods of cure variously advocated. The recent contribution of J. G. Clark [1] is an excellent example of the value of such a study.

---

* From the Surgical Clinic, Peter Bent Brigham Hospital.

1. Clark, J. G.: Surg. Clinics N. America **1**:77-100 (Feb.) 1921.

Relaxation of the pelvic floor appears to be the mechanism by which all these conditions are produced. The further titles of cystocele, rectocele, prolapse and procidentia merely represent the extent of the lesion. The result of relaxation of the pelvic floor is a hernia so lucidly described by Moschcowitz[2] in his study of prolapse of the rectum. This conception of his, admirably described and illustrated with charts, he in turn derived from the anatomic study of Waldeyer[3] and the clinical work of Ludloff,[4] Zuckerkandl,[5] and others. He discovered later that the operation he perfected had been previously performed by Duval and Quénu.[6] Jones,[7] Frank[8] and Clark[1] have applied this theory of herniation to prolapse of the vagina and uterus, giving all credit to Moschcowitz for the clinical application of the idea. The condition thus simulates hernia elsewhere.

The etiologic factors may be and are many, just as with other types of hernia; but congenital defects and trauma stand out as the principal causes, and one or both are usually present. Congenital conditions undoubtedly constitute a considerable factor, and in the literature cases of nulliparas with complete procidentia are reported. Jones[7] states that the acquired form of deep culdesac is more common than the congenital type. This congenital type he thinks is due to absence or weakness of the transversalis fascia. Trauma is probably of greater importance, although there are patients even in this small group who have had between six and ten children and who present marked laceration of the perineum without any real herniation. The factor of increased intra-abdominal pressure, whether due to tumor, ascites or straining at stool with constipation seems to be of only contributary importance. According to the type and extent of the herniation, the bladder, uterus, rectum or bowel may rest within the prolapsed part.

In order to obviate descriptions of the types of operation performed, we are submitting here a short description of the various procedures used in this clinic. The fact that the staff of this hospital is small permits of such a standardization.[9] However, all experienced in gynecologic surgery will appreciate that with each case there may be some variation from standard types of operation. The number of such

2. Moschcowitz, A. V.: Surg., Gynec. & Obst. **15**:7-21, 1912.
3. Waldeyer, W.: Das Becken, Bonn **23**:148, 1899.
4. Ludloff, K.: Arch. f. klin. Chir. **59**:447-457, 1899; Ibid. **60**:717-811, 1899.
5. Zuckerkandl, O.: Deutsch. Ztschr. f. Chir. **31**:590-608, 1891.
6. Duval and Quénu: Cited by Moschcowitz, Footnote 2.
7. Jones, D. F.: Boston M. & S. J. **175**:623-627 (Nov. 2) 1916.
8. Frank, R. T.: Surg., Gynec. & Obst. **24**:42-60 (Jan.) 1917.
9. Operations in this series were performed by the visiting surgeons, Drs. Cheever and Homans or by the successive resident surgeons, Drs. Goetsch, Jacobson and Cutler.

procedures used in such a small clinic as this is the best evidence of the necessity for such variations. There are certain principles, however, which are constantly followed.

The operations for cystocele and rectocele are performed after accepted procedures and resemble the operations so well described by Frank.[8] In the cystocele operation, after dissecting back the mucosal flaps, the bladder is freed from the cervix, pushed up and held in position by approximation of the paravesical fascia, including the pubocervical ligaments, after which the excess of mucosa is excised and the mucosa reapproximated. In the rectocele operation, after dissecting back the mucosal flaps, the levator muscles are exposed and approximated by interrupted mattress sutures, placed, to begin with, as high inward on the rectum as possible. The excision of excess mucosa and reapproximation of mucosa and skin over the perineum varies with each case. These simple plastic repair procedures have on the whole proved satisfactory.

The abdominal operations have varied more widely. The simplest types are ventral suspension and ventral fixation of the uterus. The procedures most commonly followed are the Gilliam and Olshausen methods, well described by Graves [10] in his textbook of gynecology. In performing the Gilliam suspension, our method of securing the round ligament is to pass a curved clamp from above downward through the internal inguinal ring, grasp the ligament beneath its peritoneal coat and drag it up on the anterior surface of the recti muscles, where it is sutured to the anterior rectus sheath and sometimes to the other ligament. This is essentially the Mayo [11] modification. Ventral fixation in this clinic is performed by passing either silk or chromic catgut sutures into the fundus and then above the anterior rectus sheath, tying the knot, sometimes intraperitoneally and sometimes on the rectus sheath.

Supravaginal hysterectomy, with suture of the round ligaments to the cervical stump for support or fixation of the stump to the anterior abdominal wall, is the most frequent procedure for prolapse of the uterus. Graves finds this a most satisfactory operation, with which opinion our statistics concur. In some cases, one ovary has been tucked into the broad ligament.

Bisection of the uterus with removal of the endometrium and suture of the two halves of the uterus to the rectus sheath on each side has been attempted in several of the most pronounced cases of procidentia.

The Mayo operation of vaginopexy is also recorded a few times, performed both by the vaginal and abdominal routes.

---

10. Graves, W. P.: Gynecology, Philadelphia, W. B. Saunders Company, 1917.

11. Mayo, W. J.: Surgical Treatment of Prolapse of the Uterus and Walls of the Vagina, J. A. M. A. **59**:1421-1424 (Oct. 19) 1912.

An operation in which we are greatly interested and which we have called here the Moschcowitz procedure is an adaptation of Moschcowitz's operation for prolapse of the rectum, first used for this purpose, we believe, by Dr. D. F. Jones,[7] of Boston. Clark [1] also reports much success with, and interest in, this operation. In performing this operation, the uterus is drawn up and the pouch of Douglas obliterated by spiral stitches commencing on the lateral and posterior walls of the pelvis and running over to the cervix, final sutures being taken to approximate the uterosacral ligaments. When these sutures are completed, the cervix is held at a high level, and enough space is left posteriorly, at the entrance to the pelvis, for passage of the rectosigmoid. The posterior culdesac should thus be obliterated. The fundus is then held upward and forward by some form of ventral fixation or suspension. If future pregnancies are desired, the suspension may be of the Gilliam type. We have had such patients return after childbirth (Case 10, Chart 2). This principle of posterior fixation of the cervix and obliteration of the culdesac may, indeed, be applied following supravaginal hysterectomy. On the whole the logic of, and results achieved by, this operation are extremely creditable.

The interposition principle has not been used in operations in this clinic.

PRESENTATION OF MATERIAL

Some classification seemed necessary in order to present the results more clearly. A classification has been selected based on the age and child-bearing possibilities of the patient rather than on the type and extent of the lesion. Of necessity the treatment must vary both according to the desire for more children and because of the severity of the lesion, for one cannot invariably consider such lesions from the ideal point of view of what method will give a more nearly permanent cure.

The following arbitrary grouping appeared most convenient: Group 1, women in the child-bearing age; Group 2, women past the child-bearing age. The dividing line cannot correspond to the biologic limit, since it seems reasonable to include in Group 2 women near the menopause who do not desire more children and those with serious organic diseases, such as cardiac or renal disease, in whom future pregnancies would be a serious menace to life. Each group is further subdivided into Class A, vaginal prolapse (cystocele and rectocele), in which the uterus is in its normal relation; Class B, vaginal and uterine prolapse in which there is some degree of uterine descensus and Class C, procidentia, in which there is uterine prolapse with the uterus outside. There is nothing new in this method of grouping and classification, and there is little to commend it, except the fact that the question of future child-bearing warrants a definite limit and that the extent of

the lesion gives a fairly definite syndrome, the variations of which may demand varying types of operation. It is understood, however, that in the final consideration as to the wisest operative procedure each case demands its own analysis. Nevertheless, this scheme provides a convenient skeleton for purposes of discussion.

Of the total 130 patients operated on and used as the basis of this study, forty-seven are to be considered as falling in Group 1 and eighty-three in Group 2. Their ages varied from 23 to 80 years. All but four were married, and the number of pregnancies in each case varied from none to thirteen. The number of pregnancies, however, has not appeared to exert much influence on the type or degree of lesion. The four unmarried women suffered from marked prolapse and procidentia, and prolapse was equally common among those with few or many children. Equally striking is the fact that age seems to be of no significance. There are among these cases older women with ten, twelve and thirteen children who showed simple cystocele or rectocele with

TABLE 1.—NUMERICAL DIVISIONS OF CASES

Class	Group 1	Group 2
A. Vaginal prolapse only	6	7
B. Vaginal and uterine prolapse	12	26
C. Procidentia	0	9
	18	42

some laceration of the perineum, while women in the second and third decades with one or two children showed complete procidentia. These facts seem to indicate that there is frequently some congenital predisposition to this lesion and that child-bearing and age are in certain cases only secondary factors similar to increase in intra-abdominal pressure and differing only in degree.

A. PATIENTS RETURNING FOR EXAMINATION

The chief interest is centered on the sixty patients who returned for examination. This includes only patients seen after an interval of at least six months following operation. The average interval was thirty-five months, the interval varying from six to ninety-one months. In only six cases was the interval from operation to final observation under one year, namely, six, eight, nine, ten, eleven and ten months. Of the sixty patients, eighteen are in Group 1. All of these eighteen patients were under 40 years of age and desired more children or were so young that it was thought that sterilization or further abdominal operation was unjustifiable. This leaves forty-two patients in Group 2.

The numerical divisions of cases into groups and classes is given in Table 1.

The excess of patients in Group 2 over Group 1 will doubtless be taken by some to contradict any statements regarding the small part age and trauma play. We believe, however, there is a better explanation in the following facts: First, relaxation of the pelvic floor, like inguinal hernia, is a progressive lesion, and many patients seek relief only when time has proved the futility of hoping for improvement and has shown the increase in their disability. Second, women with milder degrees of this trouble, when still in the child-bearing age, are often advised to wait until this period of life is over before entering the hospital. This means that many women with milder degrees of herniation who would enter the hospital in Group 1 are turned away temporarily and on return subsequently will fall within Group 2.

All but one patient in Group 2 were married. The average age in Group 1 was 33 and in Group 2, 48. The average number of children in Group 1 was 2.5, in Group 2 was 4.6.

The following tables summarize the material in full by groups and classes. Table 2 deals with the cases of vaginal prolapse in Group 1. These patients all suffered from mild degrees of vaginal prolapse, two patients with rectocele alone and four patients with rectocele and cystocele. Two patients had a badly torn perineum. All these women were married and had had children at the time of operation, and none are reported as having had subsequent pregnancies. With one exception, they were in good general physical condition. Symptoms had been present for from nine months to eight years, and in the great majority of cases they dated back either to the last childbirth or the one preceding the last. The chief complaint varied from simple backache, which was present in most cases, to moderate bladder or bowel incontinence and frequently to an actual protrusion from the vagina.

All patients but one were subjected to relatively simple operative procedure. All had local plastic operations, and only one of the six had an abdominal operation in addition. The results on the whole are fair, and no patient showed a complete recurrence though the interval from operation to final observations averaged forty-six months, more than three and one-half years.

The most radical operation, Case 1, and one of local repair, Case 3, gave excellent results. The radical operation, hysterectomy, was performed because of complicating fibroids rather than on account of the greater degree of the local lesion. If it is true that herniation with a congenital weakness is behind many cases, one would expect that cases of this class in Group 1, with simple vaginal prolapse for which vaginal plastic operations were performed, would progress and in time recur, even as a simple inguinal hernia, with muscle and fascia repair but

TABLE 2.—GROUP 1, CLASS A, VAGINAL PROLAPSE, SIX CASES

Case; Surgical No.	Married or Single; Age; No. of Children	Preoperative Condition	Previous Operation	Local Condition	Complicating Condition	Chief Complaint; Duration	Operative Procedure	Months to Final Observation	Result at Final Observation
1 11025	Married 35 4	Good	None	Small cystocele; large rectocele	Fibromyomas of uterus	Backache; 2 years	Anterior and posterior colporrhaphy; perineorrhaphy; supravaginal hysterectomy*	20	Firm perineum; some right sided pain; good result
2 1993	Married 38 1	Good	None	Large rectocele; small cystocele	None	"Falling of womb and backache"; 6 years	Anterior and posterior colporrhaphy	69	Slight cystocele; functional incontinence; cervix well supported
3 2396	Married 26 3	Good	None	Large rectocele; small cystocele	None	Weakness, 4 years	Dilatation and curettage; anterior and posterior colporrhaphy	16	Good perineal body; small movable uterus; well supported
4 5432	Married 38 3	Good	None	Small rectocele	Cervical polyp	Lump in vagina; 4 years	Posterior colporrhaphy; amputation of cervical polyp	51	Firm perineum; small outlet; uterus 1 degree retroverted
5 573	Married 38 2	Good	None	Small rectocele; complete tear of perineum	Dysentery	Bowel incontinence, relaxed vagina; 4 years	Posterior colporrhaphy, repair of complete tear	81	Some descensus; slight retrocele; uterus well supported
6 4982	Married 33 13	Poorly nourished	None	Large rectocele; small cystocele; lacerated perineum	Fibroid of uterus (?)	Menorrhagia, pain right side; 9 months	Dilatation and curettage; anterior and posterior colporrhaphy	40	Perineum fair; menorrhagia; fibroid uterus diagnosed; operation advised

* Unless otherwise stated "supravaginal hysterectomy" implies "with ventral suspension of cervical stump by round and broad ligaments."

TABLE 3.—GROUP 1, CLASS B, VAGINAL AND UTERINE PROLAPSE, TWELVE CASES

Case; Surgical No.	Married or Single; Age; No. of Children	Preoperative Condition	Previous Operation	Local Condition	Complicating Condition	Chief Complaint; Duration	Operative Procedure	Months to Final Observation	Result at Final Observation
1 8243	Married 36 5	Good	None	Large cystocele; small rectocele; lacerated cervix; retroversion	None	Pain in back, falling of womb; 12 years	Anterior and posterior colporrhaphy, supravaginal hysterectomy, bilateral salpingectomy, incidental appendicectomy	21	Cervix high, good perineum, good result
2 8680	Married 39 2	Obese	None	Large rectocele; small cystocele; retroversion	None	Falling of womb; 6 years	Amputation of cervix, posterior colporrhaphy, ventral suspension by Gilliam method, incidental appendicectomy	24	Feels fine; no rectocele or cystocele, cervix high; good result
3 6990	Married 37 13	Good	None	Large cystocele; small rectocele; retroversion	None	Pain in lower abdomen; 3 years	Anterior colporrhaphy; ventral fixation of uterus	26	No cystocele or rectocele; uterus well suspended; dysmenorrhea; good result
4 941	Married 31 2	Poorly nourished	Dilatation and curettage	Small rectocele; moderate descensus	None	Womb trouble, pain lower abdomen; 7 years	Dilatation and curettage, posterior colporrhaphy, ventral suspension (Gilliam)	17	Slight bulging of vagina; cervix well suspended; complains of piles; good result
5 130	Married 33 2	Good	None	Small rectocele; retroversion	None	Falling of womb; 3½ years	Anterior and posterior colporrhaphy, ventral suspension (Gilliam)	91	Perineum strong; no complaints; good result
6 3173	Married 39 2	Good	Dilatation and curettage 12 years ago	Large cystocele; small rectocele; descensus	None	Falling of womb, backache; 6 years	Amputation of cervix, anterior and posterior colporrhaphy	26	Complains of recurrence, 3 mos.; much frequency of urination and dysuria; feels miserable; moderate descensus and recurrence of rectocele and cystocele

7 10420	Married 27 2	Good	None	Moderate cystocele and rectocele with descensus	None	Bulging from vagina, descensus, functional incontinence of urine; 9 years	Dilatation and curettage, anterior and posterior, colporrhaphy, ventral suspension (Gilliam)	8	Cervix protrudes from vagina; return of symptoms
8 6744	Married 32 2	Good	None	Small cystocele and rectocele with retroversion	None	Lower abdominal pain; 2 months	Amputation of cervix, posterior colporrhaphy, ventral suspension (Gilliam)	11	Dysuria, lumbar backache; uterus in good position with slight tenderness in vaults
9 6215	Married. 37 3	Good	None	Lacerated perineum and cervix, retroversion	None	Backache; 8 years	Trachelorrhaphy, posterior colporrhaphy, ventral fixation, incidental appendicectomy	41	Slight cystocele and rectocele, good perineal body, cervix well supported, only fair result
10 8007	Married 22 2	Good	None	Lacerated cervix and perineum, prolapse	None	Dragging sensation in pelvis, backache, 1½ years	Trachelorrhaphy, posterior colporrhaphy, Moschcowitz with Gilliam suspension	40	Child born one year following operation, with backache since; examination shows weak perineum, no cystocele or rectocele, cervix low and anterior, fundus in normal position
11 10048	Married 32 2	Good	None	Cystocele with prolapse	Cholelithiasis	Debility, backache, indigestion, abdominal pain; 3 years	Dilatation and curettage, anterior colporrhaphy, ventral suspension (Gilliam), appendicectomy, cholecystectomy	22	Uterus in good anterior position, normal adnexa, no cystocele, return of indigestion for six months
12 8273	Married 37 2	Good	None	Prolapse of uterus	None	Debility, menorrhagia, leukorrhea, backache; 15 years	Dilatation and curettage, ventral suspension (Gilliam), bilateral salpingectomy	23	Uterus in good anterior position, slight leukorrhea

without operation on the peritoneal sac, would recur. The evidence in this small group is that local operation in early cases of vaginal prolapse effects permanent relief. The explanation may lie in the fact that if the lesion is taken early enough, and further trauma, as childbirth, does not occur, the further progression of the incipient lesion is prohibited. Another explanation is the accepted theory that trauma produces a local weakness which may result in simple local prolapse in which the tear is insufficient to initiate herniation of the pouch of Douglas. In this class of cases, the latter explanation is probably the more justifiable.

Table 3 shows the cases of vaginal and uterine prolapse in Group 1. Into this class fall patients in whom there is some degree of descensus of the uterus in conjunction with vaginal prolapse. Uterine prolapse without some degree of vaginal prolapse is uncommon. All patients were married and had children at the time of operation. Only one patient, Case 10, has reported a subsequent pregnancy. The chief complaint was either "falling of the womb" directly, or such symptoms as bulging from the vagina, and backache. The condition had been present symptomatically from two months to twelve years. At the time of operation, all patients were considered good surgical risks.

All patients but one (Case 12) were submitted to some type of local vaginal repair, associated in three cases with amputation of the cervix and in one case with trachelorrhaphy. In addition, all but one had laparotomy, the abdominal procedure being: ventral suspension by modified Gilliam operation, 8 cases; ventral fixation with silk, 1 case; Olshausen suspension, 1 case; supravaginal hysterectomy with round ligament support to the cervix, 1 case, and Moschcowitz procedure, 1 case. Case 6, in which no abdominal procedure was carried out, recurred completely after three months. Of the eleven other patients, all but one, Case 7, have done well and showed a good anatomic result at the time of the last examination. The explanation for the failure in Case 7 probably lies in some mechanical failure at, or shortly after, operation. It should be remarked that at operation in this case a large retroverted uterus was found. It is possible in a Gilliam suspension when the round ligaments are very lax that they should stretch farther and allow descensus to recur, though temporarily holding the uterus in good anterior position. The excellent results of the Gilliam operation in general would seem to show its efficacy. It may be said, however, that in this case there was more descensus than in the others, and the cervix actually came to the labia. In such cases, in degree almost procidentia, with great slackening of all supports and herniation of the pouch of Douglas, a more radical operation should be performed than any type of round ligament suspension which leaves the pelvic floor

still unprotected from the thrust from above. In Case 10 the Moschcowitz procedure was carried out; the cervix was held posteriorly; the culdesac obliterated and the fundus suspended by a Gilliam operation. Within five months, this patient was pregnant. There was a normal delivery. The final examination seemed to indicate that the posterior fixation of the cervix had broken away. The symptomatic and anatomic result, however, was good.

A study of this class demonstrates that with descensus a combined operation is necessary, and that although simple suspension may suffice, if the degree of relaxation is considerable, some radical attempt at obliteration of, or support to, the posterior culdesac is necessary. The failure in Case 6 should have been foreseen, while the failure in Case 7 suggests the need of a more careful study of the actual relaxation and herniation at the time of operation and a better adaptation of procedure to conditions found within the pelvis. The youth of this patient, 27, probably was the reason why nothing more radical was done. Furthermore, she desired more children.

There were no cases of procidentia in Group 1.

Group 1 as a whole shows satisfactory results, two cases in Class B, Cases 6 and 7 being the only failures in the eighteen cases, 89 per cent. successes. Case 7 should not be judged too severely, however, since in a patient of 27 no surgeon would undertake an operation entailing sterility unless the condition absolutely demanded it. Moreover, the Gilliam operation plus vaginal plastics is usually sufficient. The general deductions to be drawn are that before the menopause in women desiring more children, vaginal prolapse can usually be permanently relieved by plastic operations on the vagina, and that when the vaginal prolapse is accompanied by moderate uterine descensus, the condition can be relieved by vaginal plastic operations plus some simple abdominal procedure, preferably the Gilliam suspension or the Moschcowitz procedure.

As shown in Table 4, Class A, Group 2, is relatively small. All seven patients show simple vaginal prolapse; all had children. The chief complaint consisted of a bulging from the vagina or frequency of micturition. These symptoms had existed for from four months to twenty years, with an average of more than twelve years. No patients had had previous pelvic operations.

In all cases simple vaginal plastic operations were performed, combined with amputation of the cervix in one case only. The average duration of time from operation to final examination was thirty-five and one-half months, almost three years. The anatomic results at this time were good in all except one instance, Case 7. With this exception there was no real recurrence in any case, though in two cases a small

TABLE 4.—GROUP 2, CLASS A, VAGINAL PROLAPSE, SEVEN CASES

Case; Surgical No.	Married or Single; Age; No. of Children	Preoperative Condition	Previous Operation	Local Condition	Complicating Condition	Chief Complaint; Duration	Operative Procedure	Months to Final Observation	Result at Final Observation
1 11125	Widow 45 5	Good	None	Large cystocele and rectocele	Hemorrhoids	Bulging from vagina; 8 years	Anterior and posterior colporrhaphy, perineorrhaphy; clamp and cautery for hemorrhoids	19	Firm perineum, no cystocele or rectocele, good plastic result; general nervousness, rapid pulse, palpable thyroid, metabolism +31, hyperthyroidism
2 11495	Married 54 3	Obese	None	Large cystocele; small rectocele	None	Bulging from vagina; 20 years	Anterior and posterior colporrhaphy	16	Excellent perineum; no cystocele or rectocele; no descensus; good result
3 5759	Widow 53 13	Good	None	Moderate cystocele and rectocele	None	Pain in the right lower quadrant; 20 years	Dilatation and curettage, posterior colporrhaphy	31	No cystocele or rectocele; occasional sharp pain in left lower quadrant; no descensus; good result
4 4798	Married 47 7	Good	Dilatation and curettage	Large cystocele	Inguinal hernia	Lump in vagina; 4 months	Anterior colporrhaphy	50	Small cystocele, no rectocele, descensus, backache
5 6797	Married 41 4	Poor	None	Moderate cystocele and rectocele, lacerated perineum	Chronic nephritis, Hypertension	Torn perineum; 5 years	Posterior colporrhaphy, repair of complete tear	37	Incontinence and dysuria; obese; diastasis recti; no cystocele or rectocele; no prolapse; good result for plastics
6 5297	Married 40 4	Good	None	Lacerated and hypertrophied cervix, slight rectocele	None	Leukorrhea	Dilatation and curettage, amputation of cervix, posterior colporrhaphy	51	Obese; backache and frequency; small cystocele; uterus well supported; fair result
7 10360	Married 40 4	Obese	None	Large cystocele, small rectocele, lacerated cervix	None	Frequent micturition; 18 years	Anterior and posterior colporrhaphy	9	Recurrence; reoperated on 10 mos. later here; anterior and posterior colporrhaphy, perineorrhaphy, posterior fixation of cervix, anterior fixation of cervix, (prolapse)

cystocele was present with some frequency of urination. One patient (Case 7) suffered a recurrence with descensus and was reoperated on ten months later in this hospital, the vaginal plastics being done again and a Moschcowitz operation performed with posterior fixation of the cervix and anterior fixation of the fundus. This case showed no recurrence eight months later.

The long duration of symptoms in this group is further evidence of why Group 1 patients are relatively few and the disproportion between Classes A and B can be taken as evidence of the progressive nature of the lesion. That some patients, however, have simple vaginal prolapse for a period of twenty years, as shown in two cases in the present group, is probably best explained by the fact that in these cases, so few as to be exceptional, the lesion is chiefly traumatic, with little congenital tendency to herniation.

The results in this class are good, possibly because of the above explanation, and this would seem to agree with the findings in the similar class in Group 1. There may be certain types of vaginal prolapse in which relaxation of the pelvic floor plays almost no part. One is certainly left with the impression that vaginal plastics will cure vaginal prolapse if there is no associated uterine prolapse.

The twenty-six cases summarized in Table 5 emphasize the relative size and importance of this group. The combined number of cases in Class B in both groups is 63.5 per cent. of the total sixty cases. It appears from a study of the previous classes that complete prolapse should be infrequent if operative relief is given early. Simple vaginal prolapse on the other hand often causes insufficient subjective symptoms to demand operative relief, or when patients with vaginal prolapse with sufficient symptoms do seek relief, we find that there is already a concomitant uterine prolapse. It is, therefore, in this class of patients, containing the majority of cases with relaxed pelvic floor, that most interest centers.

Of the twenty-six patients in this class, all but three were considered good surgical risks. One patient was unmarried, and three had had no pregnancies. The average age was 46 years. Symptoms dated back from one month to twenty-five years; but in only six cases had there been symptoms for less than one year. Six patients had been subjected to previous operations for the same complaint, and in two instances the operation had been repeated previous to coming to this clinic. In all these cases some form of perineal repair had been performed, and in four cases there had been, in addition, some form of abdominal operation. The chief complaints were "falling of the womb," backache, bearing down pains, incontinence of urine and in three cases actual appearance of the womb at the labia. It appears from these data that combined vaginal and uterine prolapse is more common in multiparous

TABLE 5.—GROUP 2, CLASS B, VAGINAL AND UTERINE PROLAPSE, TWENTY-SIX CASES

Case; Surgical No.	Married or Single; Age; No. of Children	Preoperative Condition	Previous Operation	Local Condition	Complicating Condition	Chief Complaint; Duration	Operative Procedure	Months to Final Observation	Result at Final Observation
1 10831	Married 41 2	Good	None	Large cystocele and rectocele, prolapse, fibroids	Myomas	Falling of womb and menorrhagia; 3 years	Anterior and posterior colporrhaphy, perineorrhaphy, supravaginal hysterectomy, incidental appendicectomy	20	Slight leukorrhea; slight cystocele and rectocele, firm perineum, slight descensus; occasional frequency and functional incontinence; coitus unsatisfactory; no life
2 11450	Widow 68 4	Good	Dilatation and curettage, perineal repair, 1914	Large cystocele, small rectocele, Slight prolapse	Urethral caruncle	Bulging from vagina, dysuria; 25 years	Anterior and posterior colporrhaphy, excision of caruncle	10	No relief of symptoms; subsequent operation for prolapse in September, 1920, within 1 year
3 5284	Married 47 5	Good	None	Moderate cystocele and rectocele, retroversion, slight prolapse	None	"Falling of womb"; 6 years	Anterior and posterior colporrhaphy, suspension, Moschcowitz	12	Dysuria; firm perineum; slight cystocele, no rectocele; uterus high, in good position
4 5280	Married 42 4	Good	Perineal repair 9 years ago, removal of left ovarian cyst 1 year ago	Moderate cystocele and rectocele, descensus	None	Backache; 1 year	Anterior and posterior colporrhaphy, ventral fixation, Moschcowitz; lysis of intestinal adhesions	52	Subsequent operation, hysterectomy because of abdominal pain (April 1, 1920, outside) stated there was no anatomic recurrence; excellent perineum, no cystocele or rectocele
5 9165	Married 48 5	Good	None	Large cystocele and small rectocele, descensus	None	Protrusion from vagina; 8 years	Anterior and posterior colporrhaphy, ventral fixation, incidental appendicectomy	24	No subjective symptoms; no cystocele or rectocele; uterus high and fixed; excellent result
6 4707	Married 58 None	Good	None	Large cystocele, retroversion, prolapse	None	Falling of womb, incontinence of urine; 3 months	Anterior colporrhaphy, ventral suspension	30	Frequency of micturition, uterus 1½ inches outside; complete recurrence
7 4528	Married 58 None	Good	None	Moderate cystocele and rectocele, retroversion, slight prolapse	None	Backache, falling of womb; 1 month	Anterior and posterior colporrhaphy	49	No cystocele or rectocele; cervix high, no symptoms
8 567	Married 55 3	Poorly nourished, senile	None	Large cystocele and rectocele, prolapse and retroversion	None	Falling of womb; 1 year	Anterior and posterior colporrhaphy, ventral suspension and fixation	84	Complete procidentia; backache
9 571	Married 43 9	Good	None	Small cystocele and rectocele, prolapse, retroversion	None	Falling of womb; 7 years	Anterior and posterior colporrhaphy, ventral suspension and fixation, dilatation and curettage, trachelorrhaphy	71	Cervix outside; backache; fair perineum

10 462	Married 42 5	Good	None	Large cystocele, small rectocele, prolapse, lacerated cervix	None	Falling of womb; 7 years	Anterior and posterior colporrhaphy, trachelorrhaphy, ventral suspension and fixation	84	Relieved; satisfied with result; anterior abdominal wall solid; cervix high and fixed; fundus anterior
11 2509	Married 38 5	Good	None	Small cystocele and rectocele, retroversion, prolapse, lacerated perineum	None	Abdominal pain; 18 months	Posterior colporrhaphy, ventral suspension	28	Recurrence of prolapse; pain and dragging sensation
12 2590	Married 40 3	Good	None	Moderate cystocele and rectocele, lacerated cervix. prolapse	None	Backache and dragging sensation; 8 years	Dilatation and curettage, trachelorrhaphy, ventral suspension (Gilliam), posterior colporrhaphy	27	No recurrence; good result
13 1236	Married 38 8	Good	None	Large cystocele and rectocele, lacerated cervix, prolapse	None	Falling of womb, lower abdominal pain; 8 months	Dilatation and curettage, trachelorrhaphy, posterior colporrhaphy, ventral suspension (Gilliam)	6	Plastics satisfactory; fundus good anterior position; letter two years later, recurrence
14 2099	Married 53 2	Good	Two plastics, 2 and 5 years ago; abdominal operation 2 years ago	Moderate cystocele and rectocele, prolapse	None	Bearing down pain; 19 years	Bisection operation with implantation in rectus sheath	30	Prolapse; symptomatic recurrence; marked cystocele; failure
15 5118	Widow 53 1	Good	None	Lacerated perineum, prolapse	None	Falling of womb; 20 years	Bisection operation with implantation in rectus sheath	51	Uterus well supported; no prolapse, no cystocele or rectocele; examination shows carcinoma of anus
16 3350	Single 58 None	Good	None	Prolapse	None	Dragging sensation, functional incontinence of urine; 9 months	Myomectomy, bisection of uterus with implantation in rectus sheath	56	Symptoms recurred; examination shows large cystocele, prolapse; fixation broken away
17 135	Married 68 8	Poorly nourished	Trachelorrhaphy and vaginal plastic 12 years ago	Large cystocele and rectocele, prolapse	None	Falling of womb; 22 years	Anterior and posterior colporrhaphy	85	No symptoms; large rectocele, some descensus
18 9978	Married 45 1	Good	None	Large rectocele, small cystocele, fibroids, retroversion	None	Uterus falls out; 21 years	Posterior colporrhaphy, supravaginal hysterectomy with suspension	18	Total relief; very slight bulging anteriorly and posteriorly; cervix fairly well supported
19 10140	Married 45 2	Fair	19 and 3 years ago abdominal operations for relief of prolapse, appendicitis and fibroid of uterus	Large cystocele and retrocele, retroversion, prolapse	Cholelithiasis	Falling of womb; 18 years	Dilatation and curettage, amputation of cervix, anterior and posterior colporrhaphy, bilateral salpingectomy, right oophorectomy, supravaginal hysterectomy with fixation; cholecystectomy	16	No cystocele or rectocele; cervix high, complete relief; (lipoma back); excellent result

TABLE 5.—GROUP 2, CLASS B, VAGINAL AND UTERINE PROLAPSE, TWENTY-SIX CASES—(*Continued*)

Case; Surgical No.	Married or Single; Age; No. of Children	Preoperative Condition	Previous Operation	Local Condition	Complicating Condition	Chief Complaint; Duration	Operative Procedure	Months to Final Observation	Result at Final Observation
20 9607	Married 37 1	Poor	None	Large cystocele, small rectocele, lacerated cervix, retroversion, prolapse	Diabetes, heart disease (auricular fibrillation)	Backache; 3 years	Ventral suspension (Gilliam)	19	Uterus in good position, no cystocele or rectocele; abdominal wound satisfactory; dyspnea and fibrillation
21 10490	Married 48 7	Good	None	Large cystocele, small rectocele, prolapse	None	Falling of womb; 1 year	Trachelorrhaphy, anterior and posterior colporrhaphy, right salpingectomy, supravaginal hysterectomy, suspension of cervix, incidental appendicectomy	14	Dysuria, slight cystocele, firm perineum, fair support
22 4115	Married 38 8	Good	None	Moderate cystocele and rectocele, retroversion	None	Falling of womb; 2 years	Posterior colporrhaphy, ventral suspension	47	No symptoms; firm perineum
23 8879	Married 50 3	Good	None	Retroversion, some prolapse	None	Bearing down sensation; 6 years	Anterior and posterior colporrhaphy, ventral suspension (Gilliam), incidental appendicectomy	24	No cystocele or rectocele, no prolapse; dyspareunia; no other symptoms
24 6795	Married 66 9	Good	None	Retroversion, rectocele, moderate descensus	None	Frequent micturition, bulging from vagina; 1 year	Trachelorrhaphy, posterior colporrhaphy, supravaginal hysterectomy, bilateral salpingectomy, fixation of cervix and rectosigmoid	44	Excellent result, good perineum; no prolapse
25 11018	Widow 89 7	Good	Perineal and abdominal operation 14 years previously	Large cystocele, moderate rectocele, retroversion, moderate prolapse	None	Backache, protrusion cervix from vagina;	Dilatation and curettage, supravaginal hysterectomy	20	No symptomatic relief; frequency and dysuria; examination shows large cystocele with cervix coming to labia, lax perineum
26 6464	Married 36 4	Good	None	Cystocele and rectocele, moderate prolapse, lacerated cervix	None	Backache for 15 years, protrusion cervix	Anterior and posterior colporrhaphy, supravaginal hysterectomy, incidental appendicectomy	48	Complete symptomatic relief; examination shows small cystocele, thin perineum, cervix slight descensus

than nulliparous women, that its onset is insidious and that patients usually seek operative relief only when the lesion has progressed for years. It would appear that simple plastic operations, as evidenced by the number of cases with recurrence after such operations, do not always cure.

The operative procedures may be divided thus: (1) simple vaginal plastics; (2) abdominal operations, and (3) abdominal operation combined with vaginal plastics.

Vaginal plastics alone were done in Cases 2, 7 and 17 in which anterior and posterior colporrhaphies were performed. Of these, in Case 2 there was a complete recurrence, and the patient was reoperated on within a year. As this patient had already had one unsuccessful plastic operation a few years previously, it is obvious that an abdominal operation should have been performed. In Cases 7 and 17 there was no recurrence of symptoms, but when one patient (Case 17) was examined after a seven year interval, a large cystocele and some descensus were present. This patient, however, with her advanced age and hypertension, was not considered a good surgical risk at the time of operation. The good result after four years in Case 7 stands alone and may be more a symptomatic than an anatomic cure.

Abdominal operation alone was performed in Cases 14, 15, 16, 20 and 25. Bisection of the uterus and implantation above the rectus muscle was performed in Cases 14, 15 and 16, and in Case 20 a modified Gilliam suspension. Two patients, Cases 15 and 20, did well and at fifty-one months and nineteen months, respectively, after operation showed no recurrence anatomically or symptomatically. Cases 14, 15 and 25 recurred almost completely. A 60 per cent. failure is hardly satisfactory. The most marked feature of the recurrence was the great degree of vaginal prolapse, which suggests that had the abdominal operation been combined with vaginal plastics or by such a procedure as that of Moschcowitz to obliterate the posterior culdesac, the result would have been more satisfactory.

Combined abdominal and vaginal plastic operations were performed in seventeen instances, Cases 1, 3, 4, 5, 6, 8, 9, 10, 11, 12, 13, 18, 19, 21, 22, 23 and 26. In eleven cases both anterior and posterior colporrhaphy were performed while in the remainder, anterior or posterior colporrhaphy as indicated by the local condition.

There are seven patients in whom the simplest abdominal procedure, ventral suspension (Gilliam), was performed; Cases 6, 10, 11, 12, 13, 22 and 23. Of these seven patients, four, Cases 10, 12, 22 and 23, showed a good result at the final examination, with no prolapse. Three patients, Cases 6, 11 and 13, showed recurrence to the same or even greater degree than at the original observation. This is distinctly unsatisfactory and appears to condemn this type of operation

in women past the menopause. The mechanism by which recurrence occurs seems to be not only the failure of the round ligaments to maintain alone the position of the uterus but the fact that such a suspension does not protect the pouch of Douglas from the thrust from above. In fact, it appears to guide the intestines into the culdesac, thus tending to increase the amount of pressure brought to bear at this point and giving added strain on the ligaments, with the result that they stretch and thin out.

Ventral fixation of the uterus is the next procedure in simplicity. There were three cases in this group, Cases 5, 8 and 9. Examination showed one patient, Case 5, relieved, and two failures, with complete recurrence, Cases 8 and 9. There was no essential difference in these cases previous to operation, although one patient (Case 8) was generally senile and poorly nourished. The operation consisted of passing silk sutures into the fundus and over the rectus sheath, tying the knot intraperitoneally. The explanation of the failures in this small group seems to be much the same as when the modified Gilliam operation was performed, the weight of the intestine being guided into the posterior culdesac and exerting excessive strain, thus favoring herniation of the pouch of Douglas and pulling the uterus gradually away from the anterior abdominal wall. A retrospect of this group of combined operations in which some form of suspension or fixation was added to vaginal plastic operations shows poor results. Of the ten cases, five recurred completely. The explanations given above seem to explain the reasons for these recurrences and to lead to the conclusion that this type of operation should not be performed in women beyond the menopause or in whom for other reasons subsequent pregnancies need not be considered.

Two more procedures, the Moschcowitz and supravaginal hysterectomy with ventral fixation of the cervical stump, remain to be discussed. Only two patients returned for examination in whom the Moschcowitz operation, with ventral fixation of the fundus and posterior fixation of the cervix with obliteration of the pouch of Douglas, had been performed (Cases 3 and 4). Both of these patients showed entirely satisfactory results, twelve and fifty-two months after operation. There was slight dysuria in Case 3, and one patient (Case 4) had had a subsequent hysterectomy elsewhere for abdominal pain four years after operation. This patient (Case 4) was seen eighteen months after operation and showed an excellent anatomic result. Also she stated at the final examination that there had been no anatomic recurrence and that the subsequent operation was for pain only, very possibly from postoperative adhesions, which had not been entirely relieved by her operation in this hospital. This type of operation appears to be the most rational, as it creates a new and higher pelvic floor and can be used in young women contemplating subsequent pregnancies.

TABLE 6.—GROUP 2, CLASS C, PROCIDENTIA, NINE CASES

Case; Surgical No.	Married or Single; Age; No. of Children	Preoperative Condition	Previous Operation	Local Condition	Complicating Condition	Chief Complaint; Duration	Operative Procedure	Months to Final Observation	Result at Final Observation
1 5044	Married 55 4	Poorly nourished	Perineal repair 2 years ago	Complete procidentia	Myomas of uterus	Falling of womb; 20 years	Vaginal hysterectomy with fixation; anterior and posterior colporrhaphy	48	Slight cystocele, slight descensus vaginal vault; fair result
2 5580	Married 52 7	Good	Plastics six years ago	Complete procidentia	None	Falling of womb; 6 years	Bisection of uterus with implantation in rectus sheath	45	Marked rectocele; uterus well suspended; no prolapse
3 1721	Married 64 8	Good	None	Procidentia	None	Womb outside; 9 months	Vaginopexy and fixation of uterus	10	Complete recurrence
4 8916	Widow 45 3	Good	None	Complete procidentia	None	Falling of womb; 6 years	Dilatation and curettage, posterior colporrhaphy, ventral fixation	19	Slight cystocele, prolapse, postoperative hernia
5 8956	Married 45 6	Good	Right nephrectomy 2 years ago	Large cystocele and rectocele, procidentia	None	Falling of womb; 6 months	Anterior and posterior colporrhaphy, supravaginal hysterectomy, bilateral salpingectomy, left oophorectomy, incidental appendicectomy	24	Ventral hernia in scar; no cystocele or rectocele; cervix high
6 4495	Married 52 2	Good	None	Procidentia	None	Falling of womb, frequency of micturition; 8-10 years	Bisection of uterus with implantation in rectus sheath	47	Large cystocele; no prolapse; feels well
7 10075	Married 37 10	Poorly nourished	None	Small cystocele and rectocele, procidentia	None	Falling of womb for years, outside 6 months	Amputation of cervix, anterior and posterior colporrhaphy, supravaginal hysterectomy, bilateral salpingectomy, left oophorectomy, incidental appendicectomy	16	Complete relief; small cystocele, cervix attached to anterior abdominal wall but descends somewhat
8 9545	Married 46 7	Good	None	Procidentia	None	Falling of womb, outside; 13 years	Supravaginal hysterectomy, ventral suspension of stump, posterior colporrhaphy, incidental appendicectomy	19	Large cystocele; good perineum; no prolapse
9 7535	Married 47 2	Good	None	Procidentia	None	Weakness, protrusion from the vagina; 6½ years	Posterior colporrhaphy, supravaginal hysterectomy, bilateral salpingectomy, suspension of cervix	34	Rectocele; ventral hernia; cervix supported fairly high

In six cases (Cases 1, 18, 19, 21, 24 and 26), supravaginal hysterectomy was performed, with, in two cases (Cases 19 and 24,) ventral fixation of the cervical stump and in the others suspension of the stump by the round and broad ligaments. The supporting value of round ligament suspension of the cervical stump seems great in spite of the recent contention of Bissell.[12] On the whole, the results in these cases are good, with complete relief and anatomic cure in Cases 18, 19 and 24, only slight descensus and frequency in Cases 1 and 26 and a very slight bulging of the anterior vaginal wall in Case 21. This type of operation appears to have given better results than any other and to be a logical procedure if accompanied by vaginal plastics. To be sure, it does not create, as in the Moschcowitz operation, a new pelvic floor and protect the pouch of Douglas, but it elevates the culdesac and should securely fix that portion attached to the cervix.

A retrospect of the last eight cases shows satisfactory results. Both types of operation must be adapted to individual cases. It is suggested that the Moschcowitz procedure, obliterating the culdesac by posterior fixation of the cervix, might be applied after supravaginal hysterectomy. It is probable that when a marked herniation of the culdesac is demonstrable at operation, as described by Jones,[7] the Moschcowitz procedure is more suitable than hysterectomy.

The absolute influence that childbearing may have is not evident. The unmarried woman in this class presented an advanced lesion and it partially recurred after a radical operation, Case 16. Two patients (Cases 22 and 17), with eight children, did well after relatively simple procedures.

Table 6 summarizes the cases of procidentia or complete uterine prolapse. There are nine patients, varying in age from 27 to 64, all had children and the chief complaints were either "falling of the womb" or a description of the womb being outside. The symptoms had been present from six months to twenty years. All were good surgical risks.

The operative procedure varied widely. In Cases 1 and 2 previous vaginal plastics had been performed. In three cases, Cases 2, 3 and 6, no vaginal repair was performed as a part of the procedure in this clinic. In Cases 2 and 6, bisection of the uterus with implantation under the anterior rectus sheath was performed. In Case 3 the intra-abdominal procedure consisted of antiversion of the uterus, with vaginopexy and fixation of the uterus to the anterior abdominal wall. This resulted in complete recurrence in ten months. Presumably the sutures gave way. The reason for omitting a vaginal repair is not clear. In these three cases the vaginal prolapse recurred completely and is evidence that a combined operation is preferable. The cervix

12. Bissell, D.: Surg., Gynec. & Obst. **31**:578-583 (Dec.) 1920.

in both cases of bisection of the uterus remained well fixed to the abdominal wall; but as Frank [8] has shown, this does not prevent herniation of the pelvic floor.

In six of the nine cases a vaginal repair was performed at the same time as the abdominal operation. The most common abdominal procedure in this class was supravaginal hysterectomy with round ligament suspension of the cervical stump, Cases 5, 7, 8 and 9. As a group, these patients did well; two patients (Cases 5 and 7) were completely relieved. In Cases 8 and 9, respectively, a small cystocele and rectocele recurred; but in both cases the cervical stump remained high and the symptomatic relief was complete. It is unfortunate that no patients on whom supravaginal hysterectomy with ventral fixation of the stump was performed returned for observation, since this maneuver offers a little better chance for permanent relief. Graves [10] states that it is the operation of choice. It appears, however, that better vaginal repair might have given complete anatomic cure in Cases 8 and 9. In Case 8, in which a cystocele recurred, no anterior colporrhaphy had been performed. In Case 4, in addition to posterior colporrhaphy, ventral fixation alone was performed, resulting in recurrence of the uterine prolapse with cystocele. This is evidence again that simple suspension and fixation operations, rather than obviating the pressure in the pelvis, tend to increase it by guiding the bowels into the posterior culdesac. In Case 1 a vaginal hysterectomy, with suspension of the vaginal vaults by broad and round ligaments, was performed after the Mayo method. This gave a very fair result, with but slight cystocele, four years later.

The results in Class C bear a striking relation to the performance of a combined operation. In all cases in which there was a single procedure, that is, either an abdominal or a vaginal operation alone, there has been a recurrence. On the whole, supravaginal hysterectomy with round ligament suspension of the stump in conjunction with vaginal plastic operation appears to insure a good final result.

A summary of Group 2 patients shows that of the forty-two patients, those in Class A with simple vaginal prolapse (seven cases) were relieved by simple plastic operations on the vagina with one exception. The twenty-six patients in Class B upon whom several distinct types of intra-abdominal procedure were performed show a much less commendable end-result. The cases submitted to simple vaginal operations (three cases) showed complete recurrence in two cases; those submitted to abdominal operation alone (five cases) showed complete recurrence in three instances; those submitted to a combined vaginal and abdominal operation showed five recurrences in eighteen cases. The recurrences occurred in those patients in whom some form of simple ventral suspension or fixation of the uterus had been per-

formed. The results in the nine cases in Class C are no more encouraging since only five cases are satisfactory. All the uncombined operations (three cases) failed, and one ventral fixation with vaginal repair failed. In the whole group there are fifteen failures (35 per cent.) in forty-two cases.

A comparison of Groups 1 and 2 shows a great difference in end-results. The results in Group 1 are satisfactory whereas those in Group 2 are less good. The reason for this seems to depend on the more advanced lesions in Group 2, due to the progressive nature of this disability. The fact that patients do not seek operative relief until the anatomic lesion is very extensive explains the relative predominance of Group 2 patients.

TABLE 7.—DATA CONCERNING CASES IN WHICH REPORT WAS MADE BY LETTER

No. of Cases	Type of Operation	Result
Group 1:	Class A—Vaginal prolapse	
3	Vaginal plastic	1 relieved, 2 not relieved
	Class B—Vaginal and uterine prolapse	
3	Vaginal plastic	2 relieved, 1 not relieved
3	Vaginal plastic plus ventral suspension of uterus	2 relieved, 1 not relieved
1	Vaginal plastic plus supravaginal hysterectomy with round ligament suspension of cervix	1 relieved
	Class C—Procidentia	
1	Vaginal plastic plus supravaginal hysterectomy with round ligament suspension of cervix	1 relieved
11		
Group 2:	Class A—Vaginal prolapse	
6	Vaginal plastic	2 relieved, 4 not relieved
	Class B—Vaginal and uterine prolapse	
3	Vaginal plastic	2 relieved, 1 not relieved
5	Vaginal plastic plus ventral suspension or fixation of uterus	3 relieved, 2 not relieved
	Class C—Procidentia	
2	Vaginopexy	2 relieved
1	Bisection of uterus and implantation in rectus sheath	1 complete recurrence
1	Vaginal plastic plus ventral fixation of uterus	1 not relieved
18		
Total, 29 cases		

It appears that simple vaginal prolapse in either group is relieved by repair of the local lesion, that a combination of uterine and vaginal prolapse is more permanently relieved when treated early (Group 1), and by a combined operation, in which the abdominal procedure must be more than simple suspension or fixation of the uterus, and that procidentia requires a radical operation, preferably of some type that obliterates or elevates the pouch of Douglas.

B. THE PATIENTS WHO REPORTED BY LETTER

Table 7 demonstrates the character of cases in which report was made by letter, the operation performed and the end-results obtained. This table includes eleven cases in Group 1 and eighteen cases in Group 2. Seven patients in each group report symptomatic relief. This demon-

strates the greater difficulties in relieving Group 2 patients, either symptomatically or anatomically. A study of the operative procedures used indicates that patients on whom only local repair operations were performed in both Groups 1 and 2 did badly. This is contrary to the results observed in the examined cases. The five cases of procidentia, however, show results proportionate to the data obtained on patients actually examined and on whom hysterectomy was performed the results are good. Compared with the more accurate data collected in the cases of patients that returned for examination, the relative group percentages are as follows: Group 1, examined cases, 89 per cent. successes, letter cases 63.6 per cent.; Group 2, examined cases, 65 per cent. successes, letter cases 50 per cent. The unsatisfactory outcome in Class B patients in both groups seems to result from an inadequate operative procedure.

COMMENT

The material studied is representative in that it contains the varying degrees and types of relaxed pelvic floor. It consists of unselected cases from the local community. The patients' ages vary from the second to the seventh decade. The duration of the interval from operation to observation was sufficiently long to justify acceptance of the results as final.

The class of patients with uncomplicated vaginal prolapse treated by local plastic procedures shows surprisingly good results; better in the group of patients examined than in those reporting by letter. This interpretation of results was possibly influenced by rigid insistence on anatomic cures at the final observation. The reason why cases of this type do not go on to uterine prolapse is not clear; but it appears that there may be cases in which local trauma permits of a local herniation without actually destroying the supporting power of the pelvic floor. It is well recognized that cases with complete perineal tears frequently do not progress to uterine prolapse. Possibly the good results in this group will be partially vitiated with time. The results seem, however, to indicate that when uterine prolapse is to accompany vaginal prolapse it commences simultaneously with the vaginal lesion, and that if, therefore, patients at examination show no uterine prolapse, they can be permanently relieved by local vaginal operations. Retroversion may be considered as the initial stage of uterine prolapse.

The class of patients with uterine and vaginal prolapse (Class B) show less satisfactory results. Of the patients reporting for examination, those in Group 1 showed satisfactory results, those in Group 2 unsatisfactory results (ten recurrences in twenty-four cases). Among the patients reporting by letter in Group 1, two patients in seven were unrelieved and in Group 2, three patients in eight were unrelieved.

Certain of the failures can be explained by unwise choice of operative procedure. Thus, in patients in this class in whom a simple repair or an abdominal operation alone was performed, there was frequently recurrence. And when a combined operation was performed, but the abdominal procedure was a simple Gilliam or other suspension or fixation operation, there were several recurrences. A combined operation in which the abdominal procedure was either some form of hysterectomy or a Moschcowitz procedure proved satisfactory. It appears, therefore, that a combined local repair and abdominal operation should be performed when uterine and vaginal prolapse are present.

The type of abdominal procedure to be employed may depend on whether the patient desires more children It is recognized that the Gilliam operation and even ventral fixation of the fundus do not endanger subsequent pregnancies. It is also accepted, and these results seem to coincide with this view, that such operations do not give a high percentage of successes in uterine prolapse. The Moschcowitz procedure also permits of subsequent pregnancies, and these results as well as those of Clark [2] demonstrate its efficacy in this class of patients. In Group 2 when future childbearing is of no importance, a wider range of operations is available and the findings in this clinic agree with the opinion of Graves,[10] Tittel [13] and others that supravaginal hysterectomy, with either ligamentous suspension or ventral fixation of the stump, is most efficacious.

In procidentia cases, Class C, the results have been equally discouraging. Four of the nine patients who returned for examination had recurrences and two of the four patients replying by letter were unrelieved; six failures in thirteen cases (almost 50 per cent.). Here again uncombined operations resulted badly, patients on whom even such a radical abdominal procedure as bisection of the uterus returning for examination with most distressing vaginal prolapse. Patients on whom a hysterectomy, or the Moschcowitz procedure was performed, in combination with a vaginal repair, usually did well, and removal of the uterus either from above or by vagina after the Mayo procedure has proved satisfactory. The necessity of combined operations and radical abdominal interference is again demonstrated.

The type of operation is now and then further influenced by the condition of the patient. It must be remembered, however, that the combined operation need not be performed at the same sitting. They have frequently been performed separately, usually with an interval of from a week to ten days, but sometimes after some weeks, the patient returning for the second stage when thoroughly rested. The

13. Tittel, K.: Zentralbl. f. Gynäk. **44**:517 (May 15) 1920.

vaginal procedure is necessarily performed first. The task set is never a simple one and the patient must be made to understand this from the beginning.

CONCLUSIONS

Vaginal and uterine prolapse are the result of weakness in supporting structures, either congenital, traumatic or combined, in origin. The condition is essentially a herniation.

Vaginal prolapse when unaccompanied by any uterine prolapse can usually be cured by local vaginal repair procedures.

A combination of vaginal and uterine prolapse always requires a combined local repair and an abdominal operation. The type of abdominal procedure must depend somewhat on the desire for more children and on the condition of the patient. Uterine suspension and fixation operations are usually insufficient. Supravaginal hysterectomy with suspension or fixation of the cervical stump or the Moschowitz procedure has proved to be an efficient operation with lasting benefit

Procidentia must be treated by radical combined operations. Hysterectomy, either vaginal, or by the abdominal route, with some form of intra-abdominal vaginal support, and the Moschcowitz procedure have proved, in the cases studied, to give the best results.

SIXTEENTH REPORT OF PROGRESS IN ORTHOPEDIC SURGERY *

ROBERT B. OSGOOD, M.D.; ROBERT SOUTTER, M.D.; HARRY C. LOW, M.D.; MURRAY S. DANFORTH, M.D.; C. HERMANN BUCHOLZ, M.D.; LLOYD T. BROWN, M.D., AND PHILIP D. WILSON, M.D.

BOSTON

CONGENITAL CONDITIONS

Steindler [1] describes twenty-five cases of congenital malformations and deformities of the extremities, and discusses their treatment by means of both original and classical methods. He finds in many cases an hereditary tendency and coexisting deformities. He believes that in the majority predevelopmental errors are the etiologic factors.

Torticollis.—Meyerding [2] has observed only twenty-six cases of congenital torticollis in nine years at the Mayo Clinic, and considers the deformity rather rare. In their treatment he has employed the generally accepted surgical method of dividing by open operation all tight structures and retaining the corrected position by plaster-of-Paris casts.

Fragilitas Ossium (Osteogenesis Imperfecta).—Frontali [3] reports a typical case of fragilitas ossium in which the thymus gland showed both atrophy and sclerosis. The other glands of internal secretion were normal. He maintains that examination of the thymus ought to be made in all cases of this type.

Congenital Dislocation of the Hip.—Calot [4] considers that recent progress in the treatment of congenital dislocation of the hip is due, first, to the discovery (?) that the true acetabulum in 90 per cent. of young children is formed by the ischial and not the iliac portion of the os innominatum; second, that the head and neck of the femur must be retained in the horizontal and transverse position throughout the whole treatment, the amount of rotation being exactly equal to the amount of torsion of the upper end of the femur, and the amount of abduction exactly equal to the angle of slope of the neck; and third, that the criterion of cure is the roentgen-ray evidence of a large and solid

---

* This report is based on a review of 654 articles selected from about 875 titles having to do with surgery of the extremities and spinal column, appearing in medical publications, chiefly from July 1, 1920, to May 1, 1921. Only those papers seeming to represent progress in this branch of surgery have been selected for abstract and editorial comment.

1. Steindler: J. Orthop. Surg. **2**:639 (Dec.) 1920.
2. Meyerding: J. Orthop. Surg. **3**:91 (March) 1921.
3. Frontali: Riv. di clin. pediat., May, 1920.
4. Calot: Presse méd. **28**:666 (Sept. 22) 1920.

horizontal vault of bone, forming the roof of the original acetabulum. He states that this roof of bone can be observed to form during the time of fixation in the cast.

Galloway,[5] impressed by the bad results of his own attempts and those of others to cure congenital dislocation of the hip by bloodless methods of reduction, has been performing open operations in nearly all the cases which have come under his observation. He states that his operative findings have convinced him of the futility of obtaining a satisfactory replacement by manipulative methods in the great majority of cases. His conclusions are: 1. All cases should be treated by open operation and never by manipulation alone. 2. Open operation should be performed without first attempting to replace the head by manipulation. 3. The best age for open operation is between 2 and 3. 4. For children under 6, the anterior incision gives adequate exposure; in older or especially difficult cases the posterior incision should be employed. 5. In unilateral dislocations there is no upper age limit; although limited motion may result, the greater stability is more to be desired. 6. Never attempt to operate on both hips at one sitting. Galloway has performed fifty operations on thirty-six patients. He considers twelve cured. He records fourteen other "good" results, and six failures. Six are too recent for final report. He has had one fatality.

[Ed. Note.—The recent findings of the commission appointed by the American Orthopedic Association, which will be given more fully in a future report, have shown that the cases of congenital dislocation of the hip which have resulted in apparently anatomically complete cures by the bloodless manipulative methods are very rare. They have not shown that the functional results are as discouraging as the roentgenologic findings might lead us to fear. Several clinics have demonstrated extensive series of cases in which the functional results were satisfactory in a majority of the cases. We are not prepared to accept Galloway's dicta on the basis of the present evidence, but in fairness to our own patients we must explain to them that the successful reduction of the dislocation may not mean a perfect anatomic cure, and that subsequent growth changes may occur. How serious an impairment of function these changes may represent later in life we cannot yet fully predict. Whether Galloway's open methods will give a larger proportion of good functional results and avoid the frequent deformations of the head, which we now know so often follow reduction by manipulative procedures, we do not yet know; but at the present moment we are by no means prepared to abandon the manipulative procedures and accept the open operation as a routine, as Galloway suggests.]

5. Galloway: J. Orthop. Surg. 2:390 (July) 1920.

Dubreuil-Chambardel[6] reports five cases of congenital dislocation of the hip occurring in children whose mothers had suffered from the same condition. The dislocations in the mothers had been corrected in early childhood.

Feutelais[7] reports a rare condition of congenital permanent contraction in flexion of both hip joints. There was no demonstrable central or peripheral nerve lesion. A firm fibrous band between the anterior superior spine and the thigh represented the tensor vaginae femoris muscle, and at operation both this muscle and the sartorius were found to contain no muscle tissue. These firm fibrous bands cast a heavy shadow in the roentgenogram. Resection of the restraining bands and retention in a plaster spica restored normal function.

Congenital Equinovarus.—Elmslie,[8] after describing very exactly the antomy of clubfoot and emphasizing the importance of a knowledge of its morbid anatomy as a prerequisite to treatment, expresses the opinion that tenotomies have been too freely performed, and that they often very definitely affect the ultimate function of the foot. Repeated manipulations and plaster casts are his methods of choice. Relapse, he states, is due to incomplete correction at first. The obstructions to be overcome are the astragaloscaphoid capsule, the displacement of the cuboid inward upon the os calcis, and the obliquity of the neck of the astragalus and anterior portion of the os calcis. He describes his operation, in which through an incision along the inner side of the foot the anterior two thirds of the internal lateral ligament, together with the astragaloscaphoid capsule, is completely cut away, thereby exposing the head of the astragalus, the tuberosity of the scaphoid, and the sustentaculum tali. From the outer side, the os calcis is cut through with an osteotome, one-half inch (1.3 cm.) behind its anterior border. The whole anterior part of the foot can now be abducted and elevated. If the obliquity of the neck of the astragalus is an obstacle, it can be similarly osteotomized.

Ober[9] previously has described a somewhat similar operation for resistant cases in which the patient is not less than 2 years of age. The skin incision is made from the posterior tibial groove three fourths of an inch (1.9 cm.) above the internal malleolus, extending forward across the mesial surface of the tibia, curving downward and ending at the inferior border of the scaphoid. This cuts the deep fascia, periosteum, annular ligament, and anterior portion of the deltoid ligament. The next step is removal of the astragalonavicular ligament from the scaphoid and clearing of the superior surface of the astragalus

6. Dubreuil-Chambardel: Bull. de l'Acad. de méd. **84**:281 (Nov. 30) 1920.
7. Feutelais: Rev. d'orthop., September, 1920.
8. Elmslie: J. Orthop. Surg. **2**:669 (Dec.) 1920.
9. Ober: J. Orthop. Surg. **2**:558 (Dec.) 1920.

of the anterior tarsal ligament, if it is adherent. The plantar fascia is divided subcutaneously. The adduction is corrected over a wedge, and forcible manipulation corrects the inversion and plantar flexion. The Achilles tendon is divided subcutaneously. Overcorrection must be possible with one finger. The first plaster is applied in only slight overcorrection because of the circulation, chiefly of the skin. Fourteen days later overcorrection can be greatly increased. Subsequent plasters are applied until full overcorrection is obtained, and are continued for four or five months. Then some form of clubfoot brace is worn for from six to eight months longer.

Summary.—1. The operation lengthens the foot. 2. Any desirable amount of overcorrection may be obtained. 3. No important vessels or nerves are injured. 4. The removal of the contractures allows one to obtain anatomic reposition of displaced bones.

Zadek [10] is insistent that the treatment of congenital clubfoot should be begun at the earliest possible moment. In all resistant cases, plaster-of-Paris casts should be used, and the treatment should be continued until the dorsum of the foot rests easily against the lower end of the leg. This postion, he thinks, should be maintained for about four months, in the average case. Rarely is a brace necessary. He believes that altogether too much reliance is being placed on braces, which are only retentive and not corrective. Frequent observation is necessary, and most of the relapses are due to insufficient treatment after the gross deformity has been corrected.

[ED. NOTE.—We have been more and more impressed, not only with the feasibility, but also with the completeness of functional cure, in quite extreme cases of congenital equinovarus by manipulative methods alone. The plaster technic must be meticulous and often prolonged, but we have yet to observe better end-results from any other method. Bone operations in children are surely to be discountenanced, except possibly the exact "skeletal adjustments" of Hoke. Small, awkward, and weak feet result. Neither the Ober nor the Elmslie operations should affect bone growth materially, and they may well prove entirely safe short cuts to function in resistant or neglected cases. We must, by this time, be familiar with the really disastrous results to future function for which the so-called Phelps operation is responsible.]

TUBERCULOSIS

Stigmas of Predisposition to Bone and Joint Tuberculosis.—Rivers,[11] reviews the extensive historical evidence of a tuberculous dyscrasia

10. Zadek, Isadore: Correction of Congenital Clubfoot in Infants, J. A. M. A. **75**:536 (Aug. 21) 1920.

11. Rivers: Brit. J. Child. Dis. **17**:59 (April-June) 1920; cont. **17**:140 (July-Sept.) 1920.

accumulated before the discovery of the bacillus. To this extensive and delightfully written review, Mr. Rivers, who is tuberculosis officer of the Barnsley District, West Ridings, Yorks, adds the data of his own experience. The three chief historical stigmas were red hair, icthyosis, and nasal abnormalities. From a study of over 350 cases of bone and joint tuberculosis and a series of normal controls, Rivers finds that red hair is about twice as common among tuberculous patients as among normal persons, icthyosis is also about twice as common, and nasal defects, chiefly catarrhal or atrophic rhinitis, are more than three times as common. Mental defects and hypertrichosis are also found much more frequently in tuberculous children.

General Treatment of Surgical Tuberculosis.—Sorrel,[12] the successor of Ménard as chief surgeon to the Municipal Hospital of Paris at Berck sur Mer, has become convinced that heliotherapy at the seashore is the most energetic treatment for bone, joint, and glandular tuberculosis. He places little value on drugs or auto-inoculation with fluid removed from tuberculous joints. The effects of serotherapy and tuberculin treatment he considers inconclusive. He is, however, convinced of the value of roentgen-ray treatment of glandular tuberculosis. In children, surgical intervention should rarely be undertaken, while in adults resection is the rule. After 50, he believes a cure from resection cannot be expected, and that amputation is generally indicated. His impression is that the actual duration of a tuberculous lesion is not shortened much by treatment, and that it completes a more or less definite cycle. We can, however, reduce the amount of bone destruction and allow healing to take place with the least disturbance of function.

Negri's[13] experience confirms the value of heliotherapy, even at comparatively low altitudes, and van Ree,[14] after observing the effects of roentgen-ray treatment in 470 cases of glandular tuberculosis, mostly in the neck, is enthusiastic over the brilliant results. Improvement occurred in every case, and 85 per cent. of the patients were clinically cured within a few months. The exposures are made at three-week intervals. Aspiration or occasionally the excision of a favorably located single gland may hasten the healing process. Abscesses should not be opened by incision. Deep bone processes do not seem to be so tractable, but superficial lesions of the smaller bones and joints often heal rapidly under roentgen-ray therapy, especially if the sequestrums are removed.

Steindler,[15] reviewing 350 cases of joint tuberculosis, of which 225 were treated conservatively, twenty-eight operatively, and ninety-seven

12. Sorrel: Presse méd. **29**:101 (Feb. 5) 1921.
13. Negri: Policlinico **27**:324 (Oct.) 1920.
14. Van Ree: Nederlandsch Tijdschr. v. Geneesk. **2**:1985 (Nov. 13) 1920.
15. Steindler: J. Iowa M. Soc. **11**:33 (Feb.) 1921.

not at all, feels that the strongest advocacy should be given to heliotherapy and outdoor life and, usually, to institutional care. All severe cases of spinal or hip joint disease should be treated in recumbency, and the general trend of his opinion is towards lengthening the period of recumbency.

Mixed Lung and Joint Tuberculosis.—Some rather interesting observations have been made by Jacquemin,[16] physician to a hospital to which these combined cases are sent. He thinks that he has discovered that the prognosis depends on which process is primary. He considers that the secondary process acts like a derivation or fixation abscess, and a lessening of the severity of the primary process may be expected. When the process in the lungs is secondary to the bone or joint process, the lungs soon become compromised; but when the bone or joint process has developed secondarily to a lung process, he has found it to do little harm, and he believes it should be looked on as a favorable sign. He believes that these secondary bone foci should not be operated on, citing disastrous examples among his cases. On the other hand, all primary bone or joint foci should be excised with the object of relieving what he considers a sort of sacrificial process in the lungs.

Tuberculosis of the Spine.—Calvé and Galland's [17] conception of the mechanics of Pott's disease is that of a fracture of the spine, the two segments balancing on the diseased articulation. In children, they believe the disease heals completely in from three to five years, with the minimum of deformity, by conservative methods employed in recumbency. In adults, after two years of recumbency, they believe a long, ankylosing bone graft makes safe a quicker return to function, relapses being very common without this added protection.

In adults, Calvé [18] prefers the Albee transplant in the lumbar region, but elsewhere the bone periosteal ankylosing operation. He believes that from two to three years of recumbency should precede the operative procedure, and six months of recumbency should follow the operation. A protective corset should be worn for two or three years after the patient is allowed to be up. Calvé and Galland consider that even in children it is possible that a short bone graft, limited to the diseased vertebrae, may immobilize the articulation more securely than Nature can alone. They insist, however, that the classic treatment of recumbency and an antituberculous regimen must be continued until repeated roentgenologic examinations demonstrate that a complete bony ankylosis has been secured. Calvé reports four cases in which he has attempted to relieve the paraplegia by inserting his special curved

16. Jacquemin: Bull. méd., Sept. 18, 1920.
17. Calvé and Galland: Rev. de chir. 58:340, 1920.
18. Calvé: Médécine 2:38 (Oct.) 1920.

trocar into the spinal canal through the intervertebral foramen, with the object of relieving the pressure from a suspected abscess within the canal. This method was reviewed and comment on it was made in the fifteenth report of progress. One of the four patients he now reports cured, two are improving, and in the fourth he considers the result a failure.

Stone [19] reviews sixty-five cases of caries of the vertebrae, in thirty-three of which operation was performed in one way or another to obtain ankylosis. The remaining cases received the classic nonoperative treatment. Nineteen per cent. of the patients treated without operation developed abscesses; 42 per cent. of the patients operated on developed abscesses. He states that operation did not control the progress of the deformity. The mortality of the operations was 15 per cent. He concludes on the basis of his review that operative procedures are not indicated in children and that after care must be continued for as long a time as in the cases in which operation was not performed.

[Ed. Note.—It is evident that more general employment of roentgen-ray therapy is demanded, surely in all the more or less superficial forms of surgical tuberculosis. The wide experience of Stromeyer [20] that roentgen-ray treatment is of great value in young individuals, and as a postoperative treatment, is one of the latest bits of testimony to this effect. It is evident that heliotherapy is being gradually accepted as perhaps the most important part of an antituberculous regimen, quite irrespective of whether heliotherapy of the Alpine height type is or is not available. It is evident also that in spinal caries more and more reliance is being placed on prolonged recumbency to effect a permanent cure, and that less and less reliance, especially in children, is being placed on bone grafting operations. The recent report of the commission of the American Orthopedic Association on ankylosing operations on the spine gives added strength to this view. The report will be discussed more fully in a future report of progress.]

Operative Treatment of Healed Hip Disease.—Rogers and Peabody [21] believe that the three groups of these cases which they differentiate demand different operative procedures. In the first group, in which the lesion has healed with firm bony ankylosis, a curved osteotomy just below the trochanter, or transtrochanteric, serves to correct the adduction and flexion deformity. In the second group of cases, in which there is some remaining motion, but a fixed deformity, they

19. Stone: J. Missouri M. A. **17**:367 (Sept.) 1920.

20. Stromeyer: Deutsch. med. Wchnschr. **46**:514 (May 6) 1920; cont. **46**: 542 (May 13) 1920.

21. Rogers and Peabody: J. Orth. Surg. **2**:589 (Nov.) 1920.

advocate an arthrodesis of the joint, no matter how slight the motion. In the third group, in which there has been extensive destruction of the head and neck, and in which the trochanter is elevated and rests on the ilium, a simple arthrodesis in position may be less sure to succeed than taking off the top of the trochanter, cleaning out the old acetabulum, and placing the trochanter in it. The authors maintain that firm ankylosis of the joint in from 20 to 30 degrees of flexion and 10 degrees of abduction is the best functional result of tuberculous hip disease.

[Ed. Note.—We are in accord with the operative procedures which the authors advocate in the types of old hip disease. We are also ready to express our conviction that, in perhaps the majority of cases of tuberculous disease of the hip joint, occurring even before growth has ceased, bony ankylosis in the position they suggest is the best result to be obtained from our present methods of treatment. We are not convinced, however, that if recumbency were more generally employed, even in the mild cases, and some method (perhaps allowing a certain amount of painless voluntary motion) could be instituted for increasing the blood supply and decreasing the atrophy, useful motion in this peculiarly shaped joint could not be retained after the disease is overcome. We have observed an occasional result of this sort in true tuberculous disease of the hip, and although the range of motion has not been complete, and temporary joint strains (not lighting-up of the old process) have occurred, we believe these patients to be happier, less conspicuous, and more efficient than those with firm, painless ankylosis of the hip in a favorable position. We are not ready to give up striving to devise methods of cure of tuberculosis of the hip with useful motion remaining. We shall always have the recourse to ankylosis by arthrodesis if we fail.]

Spina Ventosa.—Rocher and Lasserre [22] have obtained rapid cures in nine cases of spina ventosa by making a lateral incision, scraping out the spongy tuberculous bony tissue beneath the periosteum, and suturing immediately. Continuous traction on the finger is maintained until healing and sufficient bone regeneration have occurred.

Arthrodesis of the Wrist.—Ely [23] has employed with satisfaction in tuberculosis of the wrist a tibial graft implanted in the radius, laid in a channel made in the carpal bones and terminating in the third metatarsal, the hand being maintained in slight dorsal flexion.

[Ed. Note.—Considering the experiences of Lexer and others with the lack of permanence of grafts which bridge articular surfaces, we should doubt the constant success of this procedure, unless the carpal

22. Rocher and Lasserre: J. de méd de Bordeaux **91**:466 (Sept. 10) 1920.
23. Ely, L. W.: An Operation for Tuberculosis of Wrist, J. A. M. A. **75**: 1707 (Dec. 18) 1920.

joints were destroyed as well. The experience has been that after a considerable period, a solution of continuity in the graft is very prone to occur where it crosses the articulation. There are several articulations in the wrist which must be thus crossed.]

Tuberculosis of the Knee Joint in Children.—Henderson [24] is convinced that the chief reliance in the relief of this condition must be open air, sunshine, tonics, good food, and general hygiene. His keynote is conservatism, with rest in the acute stage, and a Thomas knee splint during convalescence. Rarely is resection advisable.

Tuberculosis of the Foot.—Revel [25] believes that a thorough removal of tuberculous disease of the foot may be expected to eradicate the disease and afford better weight bearing than amputation and an artificial foot. He illustrates his article by three cases, one of thirty years' standing. Access to the disease is obtained by Delbet's method of cutting straight across the dorsum of the foot at the mediotarsal joint or between the tarsus and metatarsus, dividing all the dorsal tendons, nerves and vessels. The forefoot is swung down, and lengthwise incisions are made if necessary. All disease is dissected away and the forefoot is then sutured back in place, somewhat shortened, but still useful for weight bearing.

[Ed. Note.—We have observed the result in one such case in an adult in whom for ten years no sign of the disease has recurred and the patient walks with a scarcely perceptible limp.]

RICKETS, OSTEOMALACIA, OSTEITIS FIBROSA AND OSTEITIS DEFORMANS

Rickets.—Nathan [26] summarizes some recent research which seems to substantiate the claims that rickets is a deficiency disease. Empiric observations had already demonstrated the efficiacy of cod liver oil in the treatment long before its high content of fat soluble vitamin was known. In any event, we should use it as a preventive and as a method of treatment, assuming for the present a deficiency factor which this supplies.

The work of McCollum, Simonds, and Parsons [27] in producing "rickets" and similar diseases in rats by deficient diet seems to bear out these conclusions. Rats were fed on diets made up from more than 300 formulas in which there was a deficiency of the fat soluble vitamin A or of calcium. The diets produce in young rats disturbances in the growth and formation of the skeleton. When the diets were supplemented by purified food additions to make good these deficiencies,

24. Henderson: Minnesota Med. **3**:463 (Oct.) 1920.
25. Revel: Rev. de chir. **58**:205 (March) 1920.
26. Nathan: Presse méd. **28**:577 (Aug. 21) 1920.
27. McCollum et al.: J. Biol. Chem. **45**:343 (Jan.) 1921.

normal nutrition and skeletal growth were induced. They conclude that it is only possible at present to state that the etiologic factor in this condition is to be found in an improper dietetic regimen.

Working with Shipley,[28] the same observers administered cod liver oil in carefully regulated amounts to rats in which experimental rickets had been produced by feeding on a diet deficient in calcium, sodium, and chlorin ions, as well as in fat soluble vitamin A. The animals were in such a condition that life could have lasted only a few days longer. The results showed ocular and seemingly conclusive evidence that there was some substance in the oil which caused calcium to be deposited in the same fashion as in the spontaneous healing of rachitis in man.

Phemister, Miller, and Bonar[29] have been studying the effect of phosphorus in rickets. After careful microscopic and roentgenologic observations they conclude that its method of action is little understood. In the case of cod liver oil, the result might be attributed to the presence of fat soluble A, but this could not be the explanation for the action of phosphorus. There is a trace of phosphorus in cod liver oil in organic combination, but it is improbable that it is present in sufficient quantity to exert any influence. Evidently phosphorus and also cod liver oil in some way restore the power of normal ossification, which in rickets is temporarily lost. They consider that their experiments have refuted the contention of Wegner, who believed that phosphorus was incapable of assisting in ossification in rickets until some other factor restored the altered calcium metabolism to normal.

[Ed. Note.—Cod liver oil seems to be capable of bringing about normal bone formation in rickets. Phosphorus and actinotherapy seem capable also of so doing in certain instances. We may safely conclude that rickets is a disease of nutrition, but we apparently cannot yet positively say whether there is only one agent or whether there is more than one agent which can supply the deficiency in itself or make available substances necessary to normal bone formation and calcium deposition.]

Osteoclasis versus Osteotomy.—Blachard[30] considers the results from osteoclasis (Grattan), even in severe anterior bowlegs with the curvature near the joints, superior to the results from osteotomies. Nonunions following osteotomy are by no means rare, but he has never known one to occur after osteoclasis. In severe cases the Achilles tendon may be divided, and if, in an extreme bowing, the several osteoclases need to be performed at slightly different levels, three or four months

28. Shipley et al.: J. Biol. Chem. **45**:343 (Jan.) 1921.

29. Phemister, D. B.; Miller, E. M., and Bonar, B. E.: Effect of Phosphorus in Rickets, J. A. M. A. **76**:850 (March 26) 1921.

30. Blanchard: J. Orthop. Surg. **3**:1 (Jan.) 1921.

apart, there is no contraindication. Simple division of the Achilles tendon may be made at each operation. The other structures stretch sufficiently, and 10 cm. may be gained in length. Blanchard thinks that slow osteoclasis is dangerous. Not over eight seconds should be taken for the fracturing of the bone by the osteoclast.

Brüning,[31] on the other hand, advocates making several (up to six) osteotomies, with the Gigli saw, through small incisions. The traumatism is so slight that he does not hesitate to operate on both legs on the same day, even if the bones to be corrected are the femurs.

Actinotherapy in Rickets.—Riedel [32] reports from Ludloff's clinic excellent results in rickets from the use of the quartz lamp. We commented on the use of this form of actinotherapy in rickets in the fifteenth report of progress. He applies the light more vigorously than it is applied in Biesalski's clinic, using it daily, starting with three minutes and increasing three minutes a day up to thirty minutes. He states that delayed callous formation sometimes following osteotomy is greatly hastened by the light.

Rachitis Tarda.—Jean and E. Kollmayer [33] have observed 200 cases of rachitis tarda. They found these fell into three more or less distinct groups: (1) affecting chiefly the bones; (2) affecting the joints as well, especially the knees and feet; (3) affecting the alimentary canal with dyspepsia, diarrhea (often bloody), metrorrhagia, and bleeding from the bladder. Certain of the patients showed central nervous symptoms. They believe these changes to be best explained by external changes in the vascular system as a primary manifestation, and secondary changes in the endocrine glands. They think that the common cause of the osteomalacia and rachitis tarda is a decided lack of mineral salts in the food, owing to the insufficient fertilization of the soil during the war.

Osteomalacia.—Dieffenbach [34] contends that osteomalacia is a fairly common disease, though frequently unrecognized until spontaneous fractures call attention to the nature of the disease. The roentgenologic picture is fairly typical, but the clinical manifestations are typical also. There is a short, unsteady gait, with bent back and head, vague indefinite "rheumatic" pain referred to the different joints, and the presence of earthy phosphates in the urine. As the disease progresses, there is loss of height as the atrophic femurs or other long bones bend. In view of the almost epidemic character of the disease in central Europe, a nutritive disturbance would seem to be the probable etiologic factor, underfeeding, improper feeding, and deficiency in

31. Brüning: Deutsch. med. Wchnschr. **46**:1438 (Dec. 28) 1920.
32. Riedel: München. med. Wchnschr. **67**:838 (July 16) 1920.
33. Kollmayer, Jean, and Kollmayer, E.: Berl. klin. Wchnschr., Jan. 12, 1920.
34. Dieffenbach: Med. Rec. **97**:995 (June 12) 1920.

calcium, phosphorus, and the vitamins. There is also apparently a deficiency in suprarenal, parathyroid, and gonad secretion, perhaps primary, perhaps secondary. Treatment by rest, regulated diet, endocrine products, and actinotherapy, may be expected to bring about a cure in cases not too far advanced.

Cramer and Schiff [35] report the details of such a case of "famine osteomalacia" entirely relieved by nourishing food for a few weeks and the administration of calcium and phosphorus.

Chelmonski,[36] writing from Warsaw, describes a number of cases of what he calls alimentary osteoporosis encountered during the German occupation, when famine reigned. Recovery was prompt when the patient could have repose and proper food.

Freund and Lockwood,[37] in a case of osteomalacia, have studied the effects of certain endocrine extracts and oophorectomy on the metabolism of calcium and magnesium. During the administration of thyroid extract there was a marked increase in the loss of both calcium and magnesium. With pituitary extract there was a still greater loss of calcium, but little change in the magnesium content. During parathyroid administration there was retention of both calcium and magnesium. After removal of the ovaries there was a much greater loss of calcium and a slightly greater loss of magnesium than at any previous observation.

Ruggeri [38] reports a case of osteopsathyrosis in a child of 13, who had had twelve fractures. He found a deficit in the phosphorus, calcium, and magnesium balance. Under thymus extract administration this deficit was lessened and the condition improved, only to relapse later. There was associated a hypoplasia of the muscular and cardiovascular systems.

Hirsch [39] contends that rickets, osteomalacia, and osteoporosis belong to one great group of hunger osteopathies, and are differentiated only by the age and sex of the patients. Rickets is the disease of the child and the adolescent, osteomalacia that of the mature woman, and osteoporosis that of the age of involution. All these three affections showed a marked increase during and after the war. In all of them some influence of the endocrine system was noted.

Osteitis Fibrosa.—Langenskiöld [40] describes seven cases of osteitis fibrosa, giving the clinical and microscopic data. In localized lesions in which the bones become soft, resection of the abnormal bone is indicated. Diffuse lesions he considers hopeless.

---

35. Cramer and Schiff: Rev. méd. de la Suisse Rom. **40**:746 (Nov.) 1920.
36. Chelmonski: Presse méd. **29**:115 (Feb. 9) 1921.
37. Freund and Lockwood: Ann. Med. **1**:67 (April) 1920.
38. Ruggeri: Pediatria **28**:953 (Oct. 15) 1920.
39. Hirsch: München. med. Wchnschr. **67**:1087 (Sept. 17) 1920.
40. Langenskiöld: Acta chir. Scandinav. **53**:1 (Aug.) 1920.

Greig [41] reports two cases of osteitis fibrosa, in one of which there was a history of severe muscle strain. In the other there were successive fractures of the leg and thigh. Following these fractures there was marked bowing, and the roentgenograms taken for the first time after the fractures showed an osteitis fibrosa. One questions whether the process antedated or followed the fractures. An osteotomy was performed to correct the deformity, with a good result.

Beust [42] has observed a case of congenital fracture of the tibia in which the examination showed evidence of osteitis fibrosa, with the formation of a bone cyst at the seat of fracture. He states that Stierlin has reported a congenital fracture of the tibia due to osteitis fibrosa. He raises the question whether osteitis fibrosa may not be a more frequent cause of congenital fractures than has been supposed.

Osteitis Deformans.—Romer [43] reports three cases of an osteitis resembling true Paget's disease, confined to a single bone and following a definite injury. In one case five, and in another twenty, years had elapsed since injury, and no other bones were involved. Pain was a more marked factor than in typical Paget's disease. The bones were operated on and the pain relieved. Normal bone growth occurred in the areas in which the bone was removed.

[Ed. Note.—We have met one case of this sort in which no syphilitic taint existed.]

Sheath-Forming Osteitis.—Rénon and Géraudel [44] present roentgenograms of a patient having Marie's hypertrophic pulmonary osteoarthropathy. They think the term misleading, as only the shafts of the bones are involved. The photomicrographs show a double process in the bones, (1) the production of a sheath of spongy new bone, and (2) a calcification of the intercellular fibrillae and interfibrillar substances. The bones contain an excess of fat, while the calcium and magnesium content seems to be normal. Their own case was that of a man of 60, with cancer of the lung and a chronic pneumonia. In five similar cases on record the connection of the condition with disease of the lungs seemed certain.

SYPHILIS

Horwitz [45] has found the Wassermann reaction positive in only about 50 per cent. of the cases of bone and joint syphilis. Reliance must therefore be mainly placed on clinical findings. He recognizes three types: 1. Congenital, characterized by spontaneous fractures at or shortly after birth, epiphyseal involvement marked with joint symp-

41. Greig: Edinburgh M. J. **24**:324 (May) 1920.
42. Beust: Deutsch. Ztschr. f. Chir. **152**:60, 1920.
43. Romer: Lancet **1**:77 (Jan. 8) 1921.
44. Rénon and Géraudel: Presse méd. **28**:413 (June 23) 1920.
45. Horwitz: Am. J. Syphilis **4**:426 (July) 1920.

toms and symmetrical polyarthritis, though the joint motion is only slightly limited, and bone thickening, plus bone softening. 2. The late hereditary form. Here joint involvement is the exception and shaft involvement the rule, as shown by the saber shaped tibia, cortical thickening on the side of the convexity, and irregularity of outline. The tenderness is marked, but the disability is slight. Atrophy of the muscles in the lower extremity is common. 3. Acquired form. There is frequently synovitis, permanent or recurring. The degree of distention is out of proportion to the amount of pain and disability. The arthritis is usually secondary to shaft involvement and extension into the joint. The osteomyelitis begins as an osteitis extending into the medulla, and the symptoms are analogous to those of a pyogenic osteomyelitis, except that the new bone formation is more extensive. In the acquired form periosteitis is not as common as in the late hereditary type.

Gaenslen and Thalhimer [46] report a case of what they believe to be a syphilitic epiphysitis in an adolescent boy of 13. They suggest that the lesion is often mistaken for tuberculosis. They would differentiate it by (1) the predominance of cartilage, and the "riotous" appearance of the osteogenesis; (2) the lack of completion of the new bone formation; (3) the excess of calcium deposit in the cartilage in apposition to the areas of new bone formation; (4) the obliterating endarteritis in the thickened periosteum.

Cotton [47] has been impressed by the improvement which he has noted in five cases of Charcot joints from antispecific treatment. He thinks it stops further progress, and that actual bony repair has taken place in certain instances. The mechanical damage which may remain can be greatly helped by apparatus.

SCOLIOSIS

Schlesinger [48] has examined 12,860 schoolchildren and found that approximately 12.5 per cent. show curvature of the spine. The great majority of these are made up of what he terms constitutional curvatures and rachitic curvatures, the former being almost six times as common as the latter. The differential diagnosis between the two, he thinks, is easy, the constitutional being characterized by a long trunk, often graceful and quite flexible, while the rachitic shows a short, clumsy spine and a thorax markedly limited in mobility. The rachitic curves are much more common in the lower grade schools, and at the age of puberty. The etiology of the constitutional form is not clear to him, though he admits the probability of a constitutional anomaly of

46. Gaenslen and Thalhimer: J. Orthop. Surg 3:8 (Jan.) 1921.
47. Cotton: Ann. Surg. 7:488 (Oct.) 1920.
48. Schlesinger: Arch. f. Kinderh. 68:289, 1920.

muscles, ligaments, or bones. Faulty posture alone at school, or outside, he thinks does not explain it. These children as a class are neuropathic, with pallor of face, irritability, and frequent enlargement of the thyroid gland. There is a large percentage of short sightedness among them, which he thinks may well be a predisposing factor. Schlesinger has found that the rachitic curve tends to grow worse and needs radical orthopedic treatment. The constitutional curve often grows better under rest and careful postural education.

Kleinberg,[49] in a long article, gives the details of the treatment of scoliosis which he employs since his abandonment of the Abbott method, which failed to cure scoliosis in his hands. His conclusions are: (1) The most effective means of recognizing scoliosis is by the frequent routine examination of the naked backs of all schoolchildren. (2) Corrective treatment should be instituted as soon as the curvature is discovered. (3) Treatment should be continued uninterruptedly for years, until such improvement has been obtained as will reasonably assure the arrest of the deformity. (4) Extension of the spine is the best form of treatment, arresting the progress of the deformity and in many instances reducing the deformity. It is the least uncomfortable and does not cause malformation of the chest. (5) When the jackets are changed there must be no opportunity for relapse of the deformity.

Estes,[50] working at Lehigh University, concludes that "functional scoliosis" occurs in from 10 to 20 per cent. of college men, 70 per cent. of the curvatures being left-sided. He believes the commonest causes are "flatfoot," occupational or developmental peculiarities, and the shortening of one lower extremity.

[Ed. Note.—The problem of scoliosis is ever with us, and the satisfactory explanation of its etiology is still lacking in the majority of cases. We may call it "constitutional," idiopathic, functional, developmental, or whatever we choose, but these terms do not explain. It is clear, however, that posture alone does not cause it, nor short legs alone, nor vertebral anomalies alone. Rickets, we know, is associated in certain younger patients in an apparently causal relation. We believe that we must assume some condition of the bones of a similar nature to that in rickets, before a poor posture, or a short leg, or a vertebral abnormality can act as an exciting cause. We seem to be able to correct the condition in certain cases of mild, flexible curvature; we seem to be able to arrest, perhaps improve the condition in certain cases of considerable severity. It has not been yet proved beyond cavil that we can untwist and unbend, much less overcorrect, the curvature

49. Kleinberg: Surg., Gynec. & Obst. **32**:364 (April) 1921.

50. Estes, W. L.: Causes and Occurrence of Functional Scoliosis in College Men, J. A. M. A. **75**:1411 (Nov. 20) 1920.

in cases in which there is a fixed rotary curve, without danger to the general health and the possible production of other deformities out of all proportion to the advantage of the correction of the curvature.]

FOOT STRAIN AND FOOT DEFORMITIES

Objective Signs of Foot Strain.—Freiberg.[51] believes that pronation and abduction of the foot cause most strain at the tibiocalcaneal portion of the internal lateral ligament. Tenderness at the attachment of this ligament to the sustentaculum tali is a very characteristic sign. Freiberg suggests that an estimation of the amount of pressure at this point which causes pain may be a helpful sign in diagnosis of foot strain. In persons suffering from foot strain, pain is caused, as a rule, by pressure of less than 2½ pounds (1.13 kg.), most frequently by pressure of from ½ to 1½ pounds (227 to 681 gm.). If pain is caused by these light pressures, he interpretes it as a potential weakness in adductors and supinators.

Foot Strain in the Army.—Mebane[52] discusses foot abnormalities and their management in the light of his army experience in handling foot cases in base hospitals and development battalions, and on examining boards. The army considered that a normal foot must be unrestricted in its motion and must have its line of transmission of the body weight pass through the forefoot. The causes of foot trouble in the recruits were congenital, traumatic, and infectious. Success in treatment depended on accurate diagnosis, mechanical correction of abnormal positions, and the strengthening of weakened foot structures by means of carefully graduated exercises. Appropriate alterations in the tread of the Munson last army shoe and adhesive plaster strappings were employed. Felt pads and metal plates were found impractical in the army.

End-Results of Operations for the Relief of Hallux Valgus.—Spiers[53] has studied the end-results in ninety-six patients operated on in the orthopedic clinic of the Massachusetts General Hospital. The method generally employed until the last few years was excision of the head of the first metatarsal bone. There were a few cases each of cuneiform osteotomy of the first metatarsal, resection of the exostosis alone, and of the operation devised by Col. William Keller of the U. S. Army. This consists of the removal of the superior and mesial portion of the head, including the exostosis, and of the excision of a button of bone from the proximal end of the proximal phalanx. Spiers

51. Freiberg, A. H.: Objective Symptomatology of Footstrain, J. A. M. A. **75**:466 (Aug. 14) 1920.

52. Mebane: Mil. Surgeon **47**:428 (Oct.) 1920.

53. Spiers, H. W.: End-Result of Hallux Valgus Operations, J. A. M. A. **75**:306 (July 31) 1920.

found that (1) 66 per cent. of the excisions of the head were satisfactory to the patients; (2) by the excision method favorable results depended to no small extent on after-treatment; (3) the method was usually satisfactory in those patients whose occupations were sedentary; (4) after excision of the head, loss of normal range of motion is the rule; (5) in the unsatisfactory cases following excisions, the anterior arch was the trouble maker; (6) special and more or less permanent arch supports are essential after the head has been excised; (7) bony overgrowths frequently interfere with a satisfactory result after excision of the head; (8) the simple removal of the exostosis is rarely justified by the results; (9) the Keller method seems to offer a distinct advance in the operative treatment of hallux valgus.

Injuries to the Sesamoid Bones of the Great Toe.—Freiberg,[54] writing on this subject, recognizes the fact that divided sesamoids may be congenitally present in both feet and in both sesamoids, although the mesial sesamoid most often shows this abnormality. Injury to the sesamoids, including true fracture and subluxation, may occur. In none of his cases, except in a case of subluxation, was operation necessary to relieve the pain. The frequently renewed application of a thick felt pad, just behind the bone, until all tenderness had disappeared, and the wearing, for some time after this, of a transverse cleat, from one fourth to three eighths of an inch (0.6 to 0.9 cm.) in thickness, across the sole of the shoe, just behind the sesamoid bones, accomplished a permanent relief. Exercises for developing the power of the toe-flexing muscles completed the cure.

Hammond [55] reports two cases in which he found the mesial sesamoid adherent to the head of the first metatarsal bone. On removal, the sesamoids showed a tiny necrotic spot at this point.

Operations for Cure of Weak Feet.—Brodnitz [56] has modified Mueller's operation for the relief of severe flatfoot thus: Instead of reinserting the entire anterior tibial tendon into the scaphoid, he splits it and pulls one half through a hole in the scaphoid, and simply shortens the other half, thereby gaining a broader area of attachment, which he considers a great advantage.

Pingree [57] lengthens the tendons which are short and hold the foot everted, and shortens the adductors.

Human Prehallux.—Monahan [58] believes that the human prehallux, a structure growing from the inner border of the scaphoid downward and backward, is much more common than is generally recognized. He

54. Freiberg: J. Orthop. Surg. **2**:453 (Aug.) 1920.
55. Hammond: J. Orthop. Surg. **2**:506 (Sept.) 1920.
56. Brodnitz: München. med. Wchnschr. **40**:1158, 1920.
57. Pingree: J. Maine M. A. **10**:329 (June) 1920.
58. Monahan: Am. J. M. Sc. **160**:708 (Nov.) 1920.

has found it in 10 per cent. of cases of painful feet, many of them erroneously diagnosed as gout, rheumatism, and "flatfoot." It is not apparently a congenital structure in the human foot, but appears usually between the twentieth and fortieth years. Its origin is from some dormant ossification structure, often associated with syphilis or tuberculosis.

POSTURE

The Reaction of Bodily Mechanics to Cyclic Vomiting and Other Obscure Intestinal Conditions.—Talbot and Brown,[59] studying the effects of posture on the bodily functions of adults and children, have become convinced that vicious habitual postures inhibit normal intestinal function and induce constipation. Certain cases of cyclic vomiting, supposed generally to be due to some fault of innervation, have yielded rather strikingly to correction of the concomitant vicious posture by means of exercises and braces.

[Ed. Note.—We must not assume that all children with prominent abdomens, hyperlordosis, and feet which appear flat need a brace or even special exercises. Many apparently normal children go through this stage on the way to the erect posture of adult life. We may, however, recognize early the so-called congenital visceroptotic child, and associate causally obscure intestinal derangements, failure to gain weight normally, and general asthenia with this faulty position of the viscera and the accompanying faulty posture. The general improvement which takes place in their condition under postural treatment, when different methods of feeding, etc., have failed, is so extremely common as to be generally expected.]

Gastroptosis.—Beastrup[60] expects to find the stomach very low in women with long flat trunks, the upper abdomen curving in, and the lower abdomen prominent. The symptoms of dull headache, scanty frequent micturition, and constipation are usually present. He cites a case in which, after prolonged and unavailing medical treatment, a surprising gain in weight and a disappearance of symptoms occurred under massage and arsenic therapy, and through elevation of the foot of the bed, followed by the use of a supporting belt when the patient was allowed up.

Lee and Brown[61] are not prepared to say that many ailments of the nervous and gastro-intestinal system are caused by bad mechanical use of the body, but they recognize the frequent association of such symptoms. For example, their investigations have seemed to confirm

59. Talbot, F. B., and Brown, L. T.: Bodily Mechanics, Its Relation to Cyclic Vomiting and Other Obscure Intestinal Conditions, Am. J. Dis. Child. **20**:168 (Sept.) 1920.

60. Beastrup: Ugesk. f. Læger (Aug. 5) 1920.

61. Lee and Brown: Am. J. M. Sc. **160**:651 (Nov.) 1920.

the fact that certain cases of albuminuria in young men do not represent a true nephritis, but are associated almost exclusively with bad mechanical use of the body. In certain cases, such as poliomyelitis, one must be satisfied by bringing about a compensation in the same way as with an organic heart lesion. In other cases, a complete correction may be brought about by restoring proper bodily mechanics.

Reijs [62] has noted the effect which the attitude of the head and of the cervical spine has on the tonus of the fingers. This is a reflex action which can be demonstrated in decerebrated animals.

ARTHRITIS

The Nature of Arthritis.—In trying to construct a working hypothesis as to the cause of arthritis, Pemberton [63] considers it safe and certainly more reasonable to assume that a variety of factors may induce the substratum. These factors may be various types of infection, exposure to wet and cold, chronic intestinal conditions of which we have only imperfect knowledge, and the even more obscure internal glandular disturbances. The substratum is partly illustrated by a lowered sugar tolerance, which has been shown to accompany this disease almost invariably.

[Ed. Note.—We have in an earlier report of progress commented on Pemberton's work, which we believe is of exceptional merit. His method of attack seems most likely to succeed, and we find ourselves in heartiest accord with his belief that, considering the data now in hand, it is in the domain of physiology that the explanation of this disease is apparently to be found.]

Classification of Arthritis.—Pringle [64] considers that the differentiations and classifications of chronic arthritis suggested by Charcot, Goldthwait, and others, are unsound from a pathologic and etiologic, and even from a clinical aspect. Clinically, he recognizes two types of chronic arthritis: those which lead to ankylosis, both fibrous and osseous, and those which lead to ankylosis by deformity or locking. Pathologically, there are also two types, the inflammations and the degenerations. Between these, there are all gradations, and frequently both types are combined. He is, in general, in accord with Nathan's conclusions, and he quotes him as saying that, although a tooth or tonsil may be the portal of entry, when the micro-organism has once entered the blood stream, its connection with the portal of entry ceases. If a focus exists finally in the joint structures, it not only may cause local damage, but it also may sow general infection and metastases.

---

62. Reijs: Nederlandsh Tijdschr. v. Geneesk. **2**:2883 (Dec. 25) 1920.

63. Pemberton, Ralph: Nature of Arthritis and Rheumatoid Conditions, J. A. M. A. **75**:1759 (Dec. 25) 1920.

64. Pringle: Lancet **1**:1106 (May 22) 1920.

[ED. NOTE.—Pringle, as a matter of fact, recognizes the two great types as does Goldthwait, and he is in still closer accord with the classification of Nichols and Richardson. Nearly all observers recognize the type called by Goldthwait the infectious, and sometimes the atrophic, type, and designated by Nichols the proliferative or ankylosing type, which, unchecked, leads to fibrous or true osseous ankylosis. Pathologically, this is the inflammatory type; etiologically, the infectious or toxic type. There is also general recognition of the second great type, the hypertrophic of Goldthwait, and the degenerative or nonankylosing type of Nichols and Richardson. Pringle says that this type leads to ankylosis by deformity and locking. The joint surfaces become irregular and may intermesh to such an extent that they become somewhat locked. They may become more or less fixed in positions of deformity, but we believe that they almost never become ankylosed, except occasionally in the spine, and that they are always associated with a certain amount of bony overgrowth, which made Goldthwait speak of them as hypertrophic. We think Pringle is wrong when he says that these two great types are frequently combined. The clinical pictures are sometimes confusing, and occasionally, in a case in which the fires of an ankylosing or infectious arthritis have burnt out, the patient may, in later life, develop Heberden's nodes or a morbus coxae senilis. By the same token, a case of degenerative arthritis may, while this form is still slowly progressing, have some focal infection which will cause the other type to become active. We still believe, however, that the two types are, clinically, entities and separate diseases.]

Group Study of Three Hundred Cases of Arthritis.—Harding [65] has studied a group of 300 cases of arthritis in a U. S. Army hospital, at Camp Lewis, Washington. In 89 per cent. of the cases some infectious process other than that in the joints themselves was found and treated; but Harding is not at all convinced that the particular germ present in the tooth or tonsil is necessarily the sole causative factor. The blood cultures were all negative, and 90 per cent. of the men had had an attack earlier in life. Harding thinks this finding calls for a most thorough and painstaking removal of all sources of infection in the arthritides of childhood, in order to avoid the attacks of later life. The routine treatment was rest, free catharsis, and the splinting of painful joints. The results of the injections of nonspecific proteins were unfavorable in the seventeen cases in which they were tried.

The Colon and Other Foci of Infection in Chronic Arthritis.—Bassler [66] reports forty-five cases of polyarthritis. In thirty-five, focal infections were found and removed, and in ten no focal infections

65. Harding: California State J. M. **19**:26 (Jan.) 1921.
66. Bassler: Am. J. M. Sc. **160**:351 (Sept.) 1920.

could be discovered. None of the patients received any apparent benefit for their joint condition. Careful examinations of the blood and stools were made. The sedimentary bacterial growths were grown anaerobically and aerobically with animal inoculations. Forty-four of the cases showed instances of chronic intestinal toxemias, thirty-four saccharobutyric in type, two indolic, and eight mixed. The patients were then treated by diets suitable to their toxemias and by vaccines, for at least five months, with directions to continue the diet for a year longer. Bassler thinks that there is no possibility of a cure in the true sense, but there is a possibility of definite benefit. There is good reason to believe that if attention is given to the colon as well as to other foci of infection early in the disease, many patients will be saved the after effects of chronic joint deformity and invalidism.

Newcomet [67] suggests that chronic intestinal disease offers an explanation for many cases of arthritis of the spine, especially in middle aged persons. He cites Pemberton's work as also suggesting this causal relation.

Chapman [68] reports twenty-one personally observed cases of chronic arthritis in which distant foci of infection were removed; 76.2 per cent. of the patients showed improvement, 19 per cent. showed no change, 4.8 per cent. were worse after treatment. The most striking effects were obtained in the genito-urinary cases, though the treatment was long and continuous. Rapid recovery was the rule in the cases in which the teeth were the focus of infection.

Bacterial Studies in Arthritis.—McMeans [69] has isolated a single strain of *Streptococcus viridans* from the pus of a submaxillary abscess in a patient free from joint symptoms. In his studies of this organism, he discovered that it was of low pathogenicity and had a rather high invasive quality, possessing the ability to attack joints of rabbits and produce a chronic suppurative arthritis. This tendency to attack joints was not lost after a period of three months of artificial cultivation.

Richards [70] has taken blood cultures in 104 cases of chronic arthritis in which syphilitic and Neisser infections could be ruled out. *Streptococcus viridans* was found in fourteen cases. Joint and periarticular cultures were taken during an acute exacerbation of the disease in forty-four cases, and *Streptococcus viridans* was found in four cases. Streptococci were found in the feces, by the Gram stain, in forty-two cases and were isolated and identified as *S. viridans* in five cases. Complement fixation tests with *S. viridans* were positive in sixty-eight cases.

---

67. Newcomet, W. S.: Arthritic Changes in Spine: Their Relation to Roentgenologic Study of Gastro-Intestinal Tract, J. A. M. A. **75**:1418 (Nov. 20) 1920.
68. Chapman: Ann. Surg. **71**:648 (May) 1920.
69. McMeans: Am. J. M. Sc. **160**:417 (Sept.) 1920.
70. Richards: J. Bacteriol. **5**:511 (Sept.) 1920.

No foci of *S. viridans* could be detected in twenty cases, but of these negative cases, eleven showed a positive fixation test. In seven out of nine cases in which a streptococcus was found in the stool by the Gram stain, but could not be identified, a positive complement fixation test with *Streptococcus viridans* was obtained.

Nonspecific Protein Therapy in Arthritis.—Cowie [71] has been favorably impressed with the results of intravenous injections of foreign proteins in arthritis. He believes they should be used in those cases in which failure to secure benefit from the removal of foci of infection has occurred, or in conjunction with attempts to remove the focus. Unquestioned relief from pain often follows protein therapy, even though the focus is not removed; and, in addition to the improvement in the joint condition, the focus itself ceases to be active. As far as we know, foreign protein acts by combating infection. Acute and subacute processes that have not progressed beyond the first year, without structural change, are the ones which give the best results. Next to these are the cases which may show some structural change, but no ankylosis. Typhoid vaccine or a standard stock vaccine may be used. From one to ten injections, given at intervals of twenty-four or forty-eight hours, will demonstrate whether benefit is to be received. No anaphylactic phenomena accompany these injections, even though a second course of treatment may be instituted after an interval of several months.

Second Great Type of Arthritis.—Ely [72] includes under this term osteo-arthritis, arthritis deformans, hypertrophic arthritis, degenerative arthritis, and metabolic arthritis. He considers that this form has two distinguishing clinical features: (a) bone production (lipping or spurring) at the joint line, and (b) absence, except in spinal involvement, of union between the bone ends. Its main pathologic feature is the presence of an aseptic necrosis in the bone near the articular surface. This he thinks is the primary change, and the changes in the cartilage and the bony proliferation follow this. Ely thinks that the primary cause, in the great majority of cases, is infection in the alveolar processes of the jaw. Trauma is effective only as an added insult to a joint already diseased. This is called senile arthritis merely because elderly people are more prone to it, as they are to alveolar infections.

[Ed. Note.—We wish we could be as convinced as Ely seems to be that alveolar infections represent the usual important etiologic factor. His report of cases is impressive and his microscopic study very valuable, but we have not been so successful as he in finding foci in many of these cases.]

---

71. Cowie, D. M.: Nonspecific Protein Therapy in Arthritis, J. A. M. A. **76**:310 (Jan. 29) 1921.

72. Ely, L. W.: Second Great Type of Chronic Arthritis, Arch. Surg. **1**: 158 (July) 1920.

Tubby,[73] writing on senile painful hip, states that there is a focus of toxemia in the jaws in 75 per cent. of the cases. Intestinal, gall-bladder, tonsillar or middle ear foci are found in the remainder. He believes that a direct or indirect trauma to the joint results in the localization in the hip. His treatment, after the foci have been removed, is to relieve intra-articular pressure by recumbency for from four to six weeks, with traction on the limb. Every day the hip is moved passively five or six times. When the patient is allowed to be up, he applies a special caliper splint, with a pelvic girdle and a drop catch at the knee. For cases not thus relieved he advises excision of the head of the bone, with section of the adductors, to allow the limb to be immobilized in complete abduction.

Gentian Violet in the Treatment of Purulent Arthritis.—Churchman[74] believes that pyogenic arthritis due to *Staphylococcus aureus* or to the pneumococcus may be cured with the retention of joint mobility, by his method of joint lavage and staining with gentian violet. Whether the joint in this form of infection should ever be opened, unless the infection has become largely extra-articular, he doubts. Churchman is a little more guarded in his statements concerning gonorrheal arthritis, but he believes that the clinical course of the cases treated warrants the belief that lavage and staining offer a method of controlling the disease.

Acute Arthritis in Infants.—Johnson,[75] studying seventy-three cases of acute arthritis in infants, concludes that it is not a very rare condition, but serious in nature and usually secondary to an infection of the epiphysis. It may spread to the periarticular tissues without affecting the joint proper. Clinically, there is marked swelling, tenderness, redness and induration. Streptococcal and gonococcal infections are usually polyarticular; pneumococcal infections commonly affect only one or two joints. Fifty-three per cent. of his patients died, 9 per cent. were discharged improved, 38 per cent. were followed up and later reported well or greatly improved. The older the baby, the better the chance of recovery.

PARALYSIS, ANTERIOR POLIOMYELITIS, SPASTIC PARAPLEGIA, ETC.

Family Outbreaks of Epidemic Poliomyelitis.—Mulsow and Matousek[76] state that in all the widespread epidemics of poliomyelitis the occurrence of several cases in one family, has been recorded in a

73. Tubby: Practitioner **105**:325 (Nov.) 1920.

74. Churchman, J. W.: Gentian Violet in Treatment of Purulent Arthritis, J. A. M. A. **75**:583 (Aug. 28) 1920.

75. Johnson, F. E.: Acute Arthritis in Infants, Am. J. Dis. Child. **21**:170 (Feb.) 1921.

76. Mulsow, F. W., and Matousek, W. J.: Family Outbreaks of Poliomyelitis, J. A. M. A. **76**:159 (Jan. 15) 1921.

number of instances, although it is rare. Most often the disease has developed simultaneously in the different children. In one family of eleven children, there were four cases, two of the girls being affected at one time and two of the boys two weeks later. No source of infection was discovered.

[Ed. Note.—This evidence, as far as it goes, suggests that the infection is not usually from contact of one child with another, but simultaneous exposure from human or other contact. And if not from one child to another, is it not more probable that other than human carriers are the common sources of infection? In the exanthemas, human contact contagion is so often and so positively suggested that the burden of proof must be on those who suspect a nonhuman carrier. In poliomyelitis, the evidence of human contact contagion is so doubtful and rare that the burden of proof seems to be on those who maintain that the human carrier is the common source of infection.]

Treatment of Poliomyelitis.—Saethre [77] emphasizes the importance of preventing deformity from the very earliest stage of the disease. At first, perhaps with the help of simple apparatus, all the muscles must be maintained in a completely relaxed condition, a passive repose. Especially important is it to avoid the over-stretching of the paralyzed muscles. No exercise until all pain, hyperesthesia, and Kernig's sign have disappeared.

Mackay [78] maintains that every child surviving the acute stage of poliomyelitis can be assisted to regain muscle power. The cardinal points in treatment are: (1) anatomic rest; (2) muscle reeducation as soon as the inflammatory process has subsided, which may be at the end of the first week; (3) maintenance of warmth of the limbs, massage and avoidance of fatigue and strain.

[Ed. Note.—The author's principles of treatment are similar to those entertained by the closest observers of our recent epidemics, except that the consensus of qualified opinion seems to suggest a longer period of rest than he imposes. Rarely does it seem wise to begin any muscle training before the second month.]

Lovett [79] points out the importance of recognizing weakness of the gluteus medius and maximus as a controlling factor in many limps following poliomyelitis. Paralysis of the hip flexors and the abdominal muscles also causes limp. The gait should be most carefully analyzed before bone or tendon operations are performed below the hip, with the expectation of getting rid of the limp. Lovett deprecates the performance of serious structural operations on the foot when the chief

77. Saethre: Norsk Mag. f. Lægevidensk. **82**:122 (Feb.) 1921.
78. Mackay: Brit. M. J. **2**:513 (Oct. 2) 1920.
79. Lovett: Surg., Gynec. & Obst. **32**:20 (Jan.) 1921.

cause of the limp lies in the muscles of the hip and abdomen, without a clear statement to parents that, necessary as these operations may be, the limp will not be materially affected by them.

Astragalectomy.—Sever [80] has made an end-result study of 200 cases in which astragalectomy has been performed. The study leads to but one conclusion: that the operation is not a panacea for all cases of calcaneus and "flatfoot," and that it often fails to relieve the limp when the weakness of the hip or of the abdominal muscles coexists. As a result of this analysis, Sever feels that the operation is contraindicated in the case of any foot showing lateral instability as the result of the paralysis of one single muscle group. It is as successful an operation as any for feet which are flail, or in those which have only one muscle group left. If the long flexors are active, varus is liable to develop later, and a bad weight-bearing position results. It is not an operation to be lightly advised or invariably performed for various foot deformities, but should be reserved for older children and selected cases.

Whitman [81] comments on Sever's article, maintaining quite properly that the operation cannot be fairly criticized when judgment is based on a group of cases in which it has been performed to remedy several types of paralysis. He believes that the operation should be uniformly successful in cases of calcaneus, and that only lack of attention to the proper mechanics and insufficient attention to the details of position and after-treatment can account for bad results. If a varus deformity develops, owing to the pull of the tibialis posticus or the toe flexors, it may be overcome by a transplantation of these tendons.

Villard and Perrin [82] describe the results of twenty astragalectomies performed to correct a vicious attitude of the foot, chiefly equinovarus. They believe these results surpass those obtainable by tendon or joint operations.

[Ed. Note.—Both Sever's and Whitman's articles are valuable, the former as demonstrating that many poor results will follow astragalectomy unless the cases are carefully selected, and Whitman's as emphasizing the fact that astragalectomy was never devised to correct any but a special deformity, and that meticulous attention to mechanical details and after-treatment must be given. If these conditions are met, we believe, as Whitman does, that the results will be all that is desired. However, the very excellence of the results in properly selected cases, in which Whitman's details have been carried out, has led many good

80. Sever, J. W.: Removal of Astralagus in Paralytic Feet, J. A. M. A. **75**:1200 (Oct. 30) 1920.

81. Whitman: J. Orthop. Surg. **3**:19 (Jan.) 1921.

82. Villard and Perrin: Lyon chir. **17**:36 (Jan.-Feb.) 1920.

surgeons to extend the application of this procedure, and their bad results are tending to cast discredit on an operation which in these cases should never have been performed.]

Pes Cavus.—Mayer [83] has made a careful dissection of a specimen of pes cavus and believes that full correction of the deformity is only possible when the deep articular ligaments of the sole have been divided, especially the long plantar ligament. Simple fasciotomies are entirely insufficient.

Pes Equinus.—Gretsel [84] points out that simple tenotomy is often insufficient to correct severe cases of equinus and reports perfect results from the following operative procedure: An incision is made in the midcalf, starting at the level of the head of the fibula, and running distally to the point at which the Achillis tendon becomes distinct from the muscle. The gastrocnemius is divided at this point, retracted and reflected upward. The soleus is now separated from its origin on the fibula and tibia, with careful preservation of the nerves and vessels perforating the upper end of the muscle. The foot is now brought into dorsal flexion, and the gastrocnemius is turned downward again and retained by a few sutures.

Causes of Success and Failure in Tendon Transplantation.—Dunn,[85] in an extremely helpful article, emphasizes the fact that success in tendon transplantation depends on the possibility of reeducation of the transplanted muscle to perform its new function. When a single tendon has been taken to replace one of its own group, success has been the rule. Groups of muscles, not a single muscle of a group, may be used to replace muscles of a different action, but when a single tendon has been taken from a group to replace one not normally in action with it, failure has often resulted. Dunn finds that the most consistent failure has resulted from transplantation of a single peroneal tendon to replace the tibialis anticus. Both the longus and brevis should be taken when this type of transference is undertaken.

Spastic Paralysis; Stoffel's Operation (Neurectomy).—Gill [86] describes the purpose of the preliminary treatment and after-treatment, the indications, and the technic of the so-called Stoffel's operation or neurectomy for the relief of spastic paralysis. He has operated on thirty-two patients, some of whom have been observed for six years. The youngest was 3 years of age and the oldest 27. No ill results followed the operation in any case. The operations on the popliteal nerve for relief of contracture of the Achilles tendon have been most uniformly successful. The operations on the obturator nerve have,

83. Mayer: Ztschr. f. orth. Chir. **38**:80, 1919.
84. Gretsel: München. med. Wchnschr. **67**:1412 (Dec. 3) 1920.
85 Dunn: J. Orthop. Surg. **2**:554 (Oct.) 1920.
86. Gill: J. Orthop. Surg. **3**:52 (Feb.) 1921.

in all instances, corrected the adductor spasticity. The results in the hand, especially on the median nerve, have been more uncertain. Contractures may be overcome by this operation, but the amount of functional improvement depends on the nature and severity of the disease, on the mentality of the patient, and the careful, persistent after-treatment.

Tietze and Foerster [87] report that resection of the obturator nerve has given excellent results in four cases of adductor spasm. They believe it advisable to resect the nerve within the pelvis at the point at which it enters the obturator foramen, rather than in the adductor triangle, where bleeding from the venous plexus, deep in that region, may be hard to control. In the pelvis it is still undivided; in the abductor region there are two branches.

Léri and Gay [88] call attention to a form of spastic paraplegia prone to follow abortive epidemic encephalitis.

De Stefano [89] reports five cases of spastic paraplegia occurring in two families with syphilitic taint. He urges intraspinal, antisyphilitic treatment before degenerative changes have occurred.

Paralysis of the Iliopsoas.—Eberstadt [90] has found Ludloff's symptom of great value in diagnosing cases of isolated paralysis of the iliopsoas. When the patient is sitting upright on a table with the knees extended he is unable to raise his leg unless the iliopsoas is active. In that position the other flexors of the hip, the sartorius, the rectus, and the tensor fascia femoris, are thrown out of action.

Tendon Transplantation in Radial Paralysis.—Achard and Jarkowski [91] report excellent results from extensive transplantations after the manner of Jones [92] and Starr,[93] in cases in which irreparable damage and failure of repair of the radial nerve have occurred. They admit that these results are inferior to those in which radial continuity and subsequent repair have occurred, and council against the performance of these transplantations until every hope of this regeneration must be abandoned. They state that, when conditions are favorable, the central stump grows toward the periphery at the rate of 1 or 2 mm. a day. The integrity of the median and ulnar nerves must be complete before any transplantation operation is attempted. They advocate shortening the extensor tendons in the forearm, thereby avoiding an incision on the back of the hand, and lessening the danger of adhesions.

---

87. Tietze and Foerster: Zentralbl. f. Chir., 1920, p. 400.
88. Léri and Gay: Bull. et mém. Soc. méd. d. hôp. de Paris **44**:876 (June 18) 1920.
89. De Stefano: Pediatria, Oct. 1, 1920.
90. Eberstadt: München. med. Wchnschr., No. 30, 1920, p. 1020.
91. Achard and Jarkowski: Progrès. méd. **35**:387 (Sept. 4) 1920.
92. Jones: Brit. M. J., March 28, 1908.
93. Starr: To be published.

TENDON, BONE AND JOINT SURGERY

Heterogenous Tendon Grafts.—Durand [94] calls attention to the wide field for tendon implants which Nageote and Sencert (and he should have said Gallie) have opened up. The two former investigators believe that tendons taken from the embryo in utero of a cow are peculiarly adapted for grafting work, and that the fibrous portion of the tendon is all that is needed for the implant. The cells of the living organism into which the tendon is implanted grow into this fibrous framework with great ease. In preparing the implant, it is slightly stretched on a glass rod by means of threads passed through each end, and placed in 90 per cent. alcohol and sealed for ten days. The alcohol is now changed to 60 per cent. and the tube sealed anew, ready for use. They have used tendons thus preserved for seventeen months and have found them entirely satisfactory. Before the tendon is used, the alcohol is rinsed out with tepid artificial serum; the implant is sutured in place with fine catgut, and the limb is immobilized in plaster to relax the tendon. In Sencert's thirty-five grafts, the implanted tendon was never cast off.

Jaliper [95] also reports no failure in five cases in which implanted tendons from calves and dogs, removed from six to fifty days previously, had been employed for repair of hand tendons. The function is fairly good or very good in all.

Tenotomy.—Vulpius [96] believes that simple tenotomy is not such a harmless operation as the textbooks would lead one to believe. Examination of patients who have had section of the Achilles tendon performed frequently reveals improper length of the tendon, adhesions to surrounding tissue, etc. The Z-shaped, step-like tenotomy of Bayer injures also the gliding tissue, although overcoming some of the other dangers of simple tenotomy. Vulpius' method of procedure, which has given him great satisfaction in section of the Achilles tendon, is as follows: An incision is made along the border of the gastrocnemius, where it becomes tendinous, and the muscle and tendon are exposed. Incisions are made in the flat tendon with a V-shaped apex downward. A bit of the tendon running into the muscle belly is divided, the foot dorsally flexed to the desired angle, and the fascia and skin closed, without any sutures being taken in the muscle or tendon.

Dupuytren's Contracture.—Momburg [97] is in favor of conservative treatment of Dupuytren's contracture, in contrast to the more recent literature on the subject. In early cases, he has found persistent stretchings carried out by the patient to be efficient. In the more

94. Durand: Lyon méd. **129**:852 (Oct. 25) 1920.
95. Jaliper: Lyon chir., January and February, 1921.
96. Vulpius: München. med. Wchnschr., No. 15, 1919, p. 416.
97. Momburg: Deutsch. med. Wchnschr. **46**:602 (May 27) 1920.

advanced cases, he makes subcutaneous incisions of the prominent bands and has never been obliged to resort to the radical procedures which he considers dangerous to future function.

Repair of Lateral Ligaments of the Knee.—Edwards,[98] impressed by the success of two war cases of instability of the knee, describes the operation which he worked out on the cadaver. He believes that the function of the collateral ligaments is more important than that of the crucials, and that if these lateral ligaments are strong and tight, satisfactory function results. The operations are performed with the knee slightly flexed. In repairing the external lateral ligament, a lateral vertical incision is made and a rectangular flap from the fascia lata about 3 inches long is turned down. A similar flap of the deep structures, chiefly the tendon of the biceps left attached below, is defined, and pulling the fascial flap down and the tendon flap up, they are implanted into grooves in the condyle of the femur and the head of the fibula, fixing them with staples. For the internal or mesial ligament, a vertical incision is made over the mesial condyle, exposing the sartorius and the tendons of the gracilis and semitendinosus. These are separated from the condyles, pulled forward, and divided at the level of the condyle. The distal portions of the tendons are stitched together, and they are together implanted into a groove in the condyle of the femur and fixed under tension by a staple. The deep structures are sutured over them. The proximal portions of the tendons are stitched to the sartorius in order to preserve the function of the semitendinosus and gracilis. The sartorius is drawn well back to preserve the normal line of pull, and the wound is closed.

De Frenelle [99] reports similar procedures, using heterogenous tendon grafts in addition, if they are required in case of actual luxation.

Transplantation of Bone.—Leriche and Policard,[100] after extensive study of the fate of implanted bone, assert that the term "graft" cannot be applied to transplantation, because the implant inevitably loses its individual vitality. All bone transplants die. A fresh autotransplant provides the best material for regeneration when embedded in receptive tissue. Bone does not form well when there are great numbers of polymorphonuclear cells, in other words, in the presence of pus. They believe that the bone marrow of the implant plays no appreciable part in the regeneration. If the surrounding tissues are fibrous and avascular, there will be no reconstruction of bone. The reconstruction occurs by new intrahaversian formation, and, in the case of bone periosteum transplants, takes from twelve to fifteen months. Function of the limb, as soon as absorption has begun, is the best stimulus to

98. Edwards: Brit. J. Surg. **8**:226 (Jan.) 1921.
99. De Frenelle: J. de chir. **16**:399, 1920.
100. Leriche and Policard: Lyon chir. **17**:409 (July-Aug.) 1920.

regeneration. Their best results in treatment of pseudarthrosis of the tibia were in two cases in which weight bearing was allowed a month after the implantation. They consider it a biologic error to implant a hard solid bone in the hope of securing a stronger support. Slightly compact bone with the periosteum well contacted, is best fitted for the rôle it must play, the aim being to assure the absorption of the transplant in the shortest possible time. Implantation into spongy bone is much more likely to succeed than implantation into compact bone. Their conclusions are based on the ultimate outcome in nineteen cases. Bone periostum transplants can be successfully employed in gaps of from 12 to 15 cm., but in gaps of this length they believe it wiser to make use of a collection of bone-periosteum slices rather than a single block, except when the temporary support of a more solid graft is needed, as with the humerus or the femur. They look favorably on the implantation of previously prepared dead spongy bone, and believe the failures of the method have resulted from the employment of too hard and compact dead implants.

Cotte [101] also urges the bone-periosteum grafts as a routine, reserving the Albee transplant for very extensive defects. Like Leriche in the pervious article, he is impressed by the abhorrence which bone implants have for metal plates and wire.

Eloesser,[102] in an extremely judicial and careful article, discusses the employment of autotransplants of the ribs, basing his report on a series of twenty-two cases. He adopted the rib because it possessed certain theoretical advantages. It has a thin cortex and a large proportion of spongy tissue, lending itself to rapid absorption. Gallie and Robertson have shown that the process of absorption takes place more rapidly than the process of replacement. Therefore, the denser cortical tibial implant would be more suitable in cases in which stress and strain exist. No special instruments are required for removal of the rib. It can be readily cut and bent, and pierced with a needle. The supply is unlimited and the patient is not exposed to any risk of subsequent fracture. Eloesser's technic is to remove the rib with its periosteum, split it, and wrap it about the freshened bone ends, retaining it with kangaroo tendon passed through drill holes. His conclusions are: 1. Rib implantation is a feasible procedure. 2. The viability of the rib implants is great, even in the presence of suppuration, and they are more likely to survive in the presence of infection than more massive implants. 3. They are more rapidly absorbed. 4. They hypertrophy slowly. 5. They are prone to refracture (seven out of twenty-two cases). 6. They are not so useful as tibial implants

101. Cotte: J. Médécine **2**:15 (Oct.) 1920.

102. Eloesser, Leo: Rib Grafting Operations for Repair of Bone Defects and Their End-Results. Arch. Surg. **1**:428 (Nov.) 1920.

for the repair of large defects or when the implant is to be put under strain. 7. They are particularly useful when no great demand is to be made on the strength of the implant, as in repair of the bones of the skull and in facial plastics. 8. In twenty-two cases there were three failures, six partial successes, and thirteen successes.

Hamilton,[103] in cases of pseudarthrosis, implants his grafts under traction, cutting the proximal and distal ends on a bevel. The receptive channel is also prepared with overhanging edges and the implant sprung into place while traction is exerted on the limb. Greater firmness and better contact are the advantages of the method.

Magnuson [104] employs bone keys of ivory in fixing bone ends on account of the great strength of the ivory, and its slow but sure absorption and nonirritating qualities. After preparing with twin parallel saws a key way passing down into the medulla, a hole is drilled at each end. The ivory key is driven firmly into the key way and held in place by ivory screws passing at right angles to the key.

Shoulder Defects.—Albee [105] calls attention to the helpless condition in which patients who have suffered defects of the upper portion of the humerus are left, and the comparative frequency with which these cases are met. The surgeon must decide in the individual case whether an attempt should be made to preserve and perhaps increase motion between the scapula and the humerus, or whether an arthrodesis would result in more useful function. If motion is to be sought for, this motion must be controlled by muscles, else it is of less advantage than complete ankylosis between the scapula and the humerus, and the well controlled motion of the scapula is made available to move the humerus as well. In attempting to provide a movable scapulohumeral joint, Albee employs the head and a small portion of the shaft of the fibula, driving it for the length of an inch into a drill hole in the humerus, which may need to be split as well, if the circumference of the fibula is considerable. Albee emphasizes the importance of stitching the rotator and elevator muscles of the shoulder to the humerus and fibula implant in as nearly normal position as possible. If ankylosis is the end sought, he employs two fairly large and strong grafts in a sort of truss work, one from the humerus into the acromion and from the glenoid to the humeroacromial graft. These grafts are firmly and accurately fitted into their host bones, while the arm is held in the exact position the operator desires to maintain. The most favorable position is considered to be with the humerus elevated anteriorly and rotated so that the hand is brought in front of the face.

---

103. Hamilton: Texas State J. Med. **16**:210 (Sept.) 1920.
104. Magnuson: Northwest Med. **19**:299 (Dec.) 1920.
105. Albee: Surg., Gynec. & Obst. **32**:1 (Jan.) 1921.

Nonunion of the Humerus.—Henderson [106] reviews forty-one cases of pseudarthrosis of the humerus, finding the common cause to be imperfect immobilization in ambulatory splints. He advocates the use of the massive graft on the basis of his comparative results and because more endosteum to endosteum contact is thereby obtained. He thinks the medullary graft unsound in principle. His results show 85 per cent. of good results from the massive graft (fibula?), 70 per cent. from the inlay, and 50 per cent. from the intramedullary peg.

Ankylosing Operations on the Spine.—Polya [107] has been employing with satisfaction a modification of Albee's method of inserting a spinal graft. The erectores spinae on one side are dissected from the spinous processes which are divided as near their bases as possible. Still attached to the muscles on the other side, they are turned back, and the bony bed smoothed for the reception of the graft. The spinous process muscle flap is then adjusted over the graft, and the fascia and skin sutured. The technic is simple, and the graft, well contacted, is brought nearer the laminae thereby.

Forbes [108] describes his method of ankylosing portions of the spine, chiefly in selected cases of scoliosis, not claiming that it represents the perfection of Hibbs' operative technic, but maintaining that it thoroughly accomplishes its purpose. In the dorsal region, the spinous processes and laminae are exposed and so gouged by a concave chisel that their cortical layers are separated from the medulla beneath. A series of bone chips and fragments of periosteum are pried up along the superior and inferior borders of the laminae and made to interdigitate with one another. In the lumbar region, the spinous processes are split vertically into several thin slices, and bent upward and downward and to the sides, meeting each other and osteoperiosteal chips from the laminae. Forbes aims to create a veritable forest of bone chips. The plaster jacket applied in the best possible position obtainable is worn for six months.

New [109] reports fifteen operations in which he has employed boiled beef bone as the inlay for ankylosing a portion of the spine in cases of Pott's disease. He says the results are satisfactory as far as he knows them. The operative technic is that of Albee. The graft was retained in all but one case. This patient got out of bed the second day after the operation and the wound was split open, with subsequent infection.

[Ed. Note.—After a rather extensive experience with this method (thirty cases) and a careful study of end-results at the orthopedic clinic of the Massachusetts General Hospital, Brown considers the

106. Henderson: Southern M. J. **14**:148 (Feb.) 1921.
107. Polya: Zentralbl. f. Chir. **48**:884 (June 25) 1921.
108. Forbes: J. Orthop. Surg. **2**:509 (Sept.) 1920.
109. New: Nat. M. J. China, March, 1920.

value of this operation as still sub judice. The graft is always well tolerated; it splints the spine quite firmly at first, if it is accurately placed and retained, and it absorbs very slowly, but the living bone of the host seems to replace it slowly also, one may almost say rather reluctantly. It has been recovered a year and a half after insertion, almost unchanged, lying without irritation, but without fusion to its bed. Its use has many advantages, but our impression is that it cannot, in a certain proportion of cases, be counted on to fix, firmly and permanently, the vertebrae into which it is implanted, and that some form of fusion operation is necessary in addition. It may well prove a useful, nonirritating temporary splint favoring early fusion, and affording immediate fixation. Experiments on animals now in progress will confirm or refute this impression.]

Ankylosis of Sacroiliac Joint.—Hertz[110] describes a method of immobilizing the sacroiliac joint by driving a bone peg into it across its articular surfaces. He has employed the method in three cases of suppurating and in one case of nonsuppurating sacrocoxalgia. The implant healed without irritation.

[Ed. Note.—It is quite possible on the cadaver, as Hertz says, thus to immobilize the sacroiliac joint by driving a bone peg through it. We doubt the permanence of this immobilizing procedure, however, in the living subject, since the peg traverses an articular space. The procedure of Smith-Petersen seems to us to be better conceived. He gains access to the sacroiliac joint by removing a carefully preserved rectangular plug of bone from the ilium, running at right angles to the joint. He then denudes the joint of cartilage, continues his window into the sacrum, and drives the plug of bone into it, setting it like a nail beneath the surface of the ilium. He has performed this operation twelve times, with almost complete success. A fuller report will be made in a later report of progress.]

Transplantation of Fibula for Large Defects in Tibia.—Brandes[111] reports four cases of transplantation of the fibula into the tibia for large defects. If the defect reaches into the upper tibial epiphysis, he transplants the whole head of the fibula with the shaft, for purposes of growth. The upper end is transplanted first and then the lower, leaving the external malleolus, but bringing it in contact with the transplanted shaft. He counsels leaving the fibula longer than the apparent defect, as it sinks well into the spongy medulla of the tibia.

[Ed. Note.—It will be remembered that Stone, Codman, Campbell, MacAusland, and Wood have all reported similar successes, the fibula hypertrophying quite rapidly, finally attaining almost the size of a normal tibia.]

110. Hertz: Lyon chir. **17**:199 (March-April) 1920.
111. Brandes: Deutsch. Ztschr. f. Chir. **155**:312, 1920.

Arthroplasty.—Payr[112] reports a case of bony ankylosis of the hip, associated with partial fibrous ankylosis of the knee, ankle, and elbow. Arthroplastic operations were performed on all the joints with success.

Putti[113] epitomizes his experience with arthroplastic operations on the knee and thus emphasizes what he has grown to consider the essentials of the procedure. 1. Complete removal of all intra-articular structures is necessary. 2. Operation too soon after acute inflammation spells failure. 3. In joints ankylosed as a result of Neisser infection the postoperative treatment should be very gentle. A longer time is required in these cases for good results. 4. The knee on which the operation has been performed usually remains larger than the normal knee.

Osteochondritis Dissecans.—Rieger[114] agrees with Koenig and Axhausen in regard to the pathogenesis of osteochondritis dissecans, believing that an actual dissecting process takes place, and combating the contention that an actual single or even repeated trauma mechanically expels the bit of bone. The opinion which Rieger upholds is that of an actual fat embolism in the tiny end arteries of the lower end of the humerus and femur and the ends of other long bones. Fat embolism of these arteries has been observed at necropsy. In adults, these end arteries run in fat cells, in growing children, in connective tissue; and Rieger believes this conception of the pathogenesis of the condition explains the absence of the condition in children.

Kappis[115] believes, on the other hand, that the affection is always of traumatic origin, although he admits that apparently the blow is not always sufficient to cause immediate disruption of the fragment into the joint. He thinks that loose bodies in joints usually are derived from marginal proliferations or pieces of articular cartilage, and are of an arthritic nature. The bony tissue becomes necrotic, the marrow remains intact, and the hyaline cartilage is transformed into fibrous cartilage, continuing to grow without perichondrium in a way similar to that of experimental growth of tissue in nutritive fluid.

Axhausen[116] believes also that in the so-called osteochondritis dissecans, trauma is the important element; but he thinks the separation takes place slowly. The particular trauma which causes it is generally a blow on the condyles of the femur, with the knee flexed. In the cases in which operation had been performed soon after a trauma, and the separated bone found, the microscopic findings suggest a process antedating by a long time the last trauma. In his own case, the process was

112. Payr: Arch. f. klin. Chir. **114**:878, 1920.
113. Putti: J. Orthop. Surg. **2**:530 (Sept.) 1920.
114. Rieger: München. med. Wchnschr., June 15, 1919.
115. Kappis: Deutsch. Ztschr. f. Chir. **157**:214, 1920.
116. Axhausen: Deutsch. med. Wchnschr. **46**:825 (July 22) 1920.

almost entirely one of resorption with very active connective tissue and giant cells eroding the surface of the necrotic bone. In this case, the body was found free immediately after a trauma, and the casual observer would have considered it the immediate result of the last injury. Axhausen ventures the hypothesis that the dissecting process may be due to an embolus, perhaps a tuberculous one. A trauma only completes the separation.

Derangements of the Semilunar Cartilages.—Strahlmann and White,[117] reviewing the histories and operative findings in about sixty cases of derangement of the similunar cartilages of the knee, consider the most reliable diagnostic signs to be (1) a traumatic history, with recurring symptoms of disability; (2) definite localized pain or tenderness; (3) locking; (4) sense of derangement or feeling of insecurity; (5) swelling. They believe that the simple untorn hypermobile cartilage is an entity more common than fracture, and that it requires surgical intervention. Excision should be as complete as possible under perfect asepsis. The prognosis should be more or less guarded in cases of long standing, especially in those in which at operation the cartilage is found lacerated or comminuted. The reason for this is that secondary joint changes have occurred and are not always relieved by the removal of the original cause.

Jacobs and Worms[118] think that if a dislocated cartilage can be immediately reduced, and the limb immobilized and massaged while the patient practices voluntary exercises of the quadriceps, most patients fully recover. They have analyzed the results in 200 operative cases and believe the operation of meniscectomy entirely satisfactory in actual crushes or fractures of the cartilage or in the presence of recurring symptoms. Resection of small portions of the cartilage often fails to relieve.

Terracol and Colanéri[119] have injected air directly into the knee joint, following injuries from which damage to the semilunar cartilages was suspected. They feel that they are able to detect fractures and tearings by this method in the roentgenograms, confirming their clinical findings.

[Ed. Note.—We feel that lesions of the semilunar cartilages do not usually present great diagnostic difficulties. At least, the advisability or nonadvisability of operative exploration is usually easy to determine. We should doubt the wisdom of injecting air into a recently traumatized joint for the sake of possibly obtaining preoperative information, which exploration will more surely reveal.]

---

117. Strahlmann, L., and White, J. W.: Derangement of Semilunar Cartilage, J. A. M. A. **76**:561 (Feb. 26) 1921.

118. Jacob and Worms: Rev. de chir. **39**:898, 1920.

119. Terracol and Colanéri: Presse méd. **29**:113 (Feb. 9) 1921.

PERIPHERAL NERVE INJURIES

Reviews of Peripheral Nerve Injuries.—Stuckey [120] emphasizes the importance of reconstructing the original injury in an effort to evaluate the benefit likely to be derived from operations looking to the return of peripheral nerve function, and also for the purpose of diagnosing the existing type of injury to the nerve. In charting the sensory findings, it is not enough to use the terms epicritic and protopathic, but the type of stimulus used and the response thereto should be given. In examining for light touch, longitudinal, not transverse, strokings should be made, else confusion is probable. Stuckey states that the dorsal surface of the terminal phalanx of the thumb is the only area exclusively supplied by the radial nerve. In examination for return of voluntary motion, he pleads for estimation by sight and touch of individual muscle action as opposed to group action and motion of joints. The risk of being deceived by trick movements is thus materially lessened. The author recommends early and extensive nerve exploration in the majority of cases, but advocates great conservatism in suture, etc., until all facts as to late results are weighed.

In studying the true end-results of operations on the peripheral nerves, Thorburn [121] urges the recorder to group under headings what he means by restoration, that is, anatomic, physiologic, or economic restoration. The completeness of recovery of a divided nerve, Thorburn believes, is proportionate to the accuracy with which the individual fibers of the central or motor cable are approximated to these same fibers in the peripheral segment, and when there has been hopeless entanglement of motor, sensory and trophic filaments, there must be corresponding physiologic failure and confusion. When operative technic is accurate, good results may apparently be expected in about 50 per cent. of the cases (from one-third to two-thirds), but a perfect neurologic result is almost never attained. The chances of recovery are better when the small muscles do not have to be reenergized, and when the given nerve is of an almost purely motor or sensory type. The nearer the section is to the spinal cord, the better the prognosis. In the upper limb, the radial nerve is an easy first in its power of recovery, the median a bad second, and the ulnar a very poor third; but it is interesting to note that the absence of ulnar power sometimes cripples the hand very little. A surgeon who obtains 50 per cent. of really good economic recoveries after secondary nerve suture must be doing, according to our present standards, first-class work.

Sargent [122] points out the many factors which, in war wounds, militate against complete recovery from nerve suture. The most important

120. Stuckey: New York State J. M., September, 1920.
121. Thorburn: Brit. M. J. 2:462 (Sept. 25) 1920.
122. Sargent: Brit. M. J. 2:464 (Sept. 25) 1920.

of these are the concomitant vessel, muscle, tendon, and bone injuries, complicated by sepsis, which in many cases have resulted in an intraneural fibrosis, ascending and descending, and opposing the advance of the down-growing axons. End-results are of value only as they record the effect of end-to-end suture, carried out by skilful operators. Apparently the results are as good after secondary suture as after primary suture, other things being equal. Sargent, in conclusion, discusses the relief of causalgia by alcohol injections, section and resuture, and division of the sensory roots.

Forrester-Brown's [123] study of end-results of operations on peripheral nerves is based on 643 cases of nerve injuries observed at the Edinburgh War Hospital. The basis on which these were studied was (a) capacity for work, and (b) degree of recovery after neurolysis and suture. In 237 cases of suture, 12 per cent. of the patients are at ordinary work, 35 per cent. at light work, and 15 per cent. at heavy work. In 187 cases of neurolysis, 80 per cent. of the patients are at ordinary work. In eighty-one cases of tendon transplantations, 23 per cent. of the patients are at ordinary work, and 36 per cent. at light work. As to recovery after suture, of 158 patients, 28 per cent. showed complete motor return, 19 per cent. complete sensory return and 21 per cent. complete trophic return. Fifty per cent. showed incomplete return of all these functions. Total complete recovery of all functions was found in only five of the median cases, and in eight of the musculospiral. Three nerve grafts were explored because of lack of improvement. The graft could with difficulty be recognized, embedded in scar tissue, and of small caliber. There was no reaction to the faradic current. In 117 cases of neurolysis, 42 per cent. of the patients had full motor and functional return and 19 per cent. full sensory return. The early functional improvement after tendon transplantation was impressive and satisfactory. As a result of this study, the author believes that Tinel's sign should be discredited as an index of progressive recovery, and that the degree of recoverability is not dependent on the length of time which has elapsed between injury and suture.

Corbett [124] makes the interesting statement that in 100 cases of nerve injury from war wounds, 60 per cent. of the patients recovered without operation. He has accepted as the indication for exploratory operation three months of lack of improvement under proper conservative treatment, splinting, etc. In performing the operation of neurolysis, Corbett believes that it is very important to make fine longitudinal incisions into the nerve itself as well as to free it from surrounding

123. Forrester-Brown: Brit. M. J. **2**:467 (Sept. 25) 1920.
124. Corbett: Minnesota Med. **3**:422 (Sept.) 1920.

tissue. An internal keloid was demonstrated in several of the cases. Fat and muscle beds are considered to be most suitable as locations for the restored nerve.

Pollock [125] had an opportunity to make a bed to bed observation of cases of nerve injury in the hospitals of the American Expeditionary Forces. The striking feature was the very great percentage of improvement without operation. He estimates that there were 10,000 cases of nerve injury among our forces, and of that number only about 3,000 came to be classified as such in the reports of the Surgeon-General's office, indicating that approximately 66 per cent. of the patients had recovered sufficiently before they returned to America to be no longer classified as nerve cases. He estimates also that not more than 14 per cent. came to operation. These figures are not far from Corbett's estimate in the previous review. Like Forrester-Brown, he believes that Tinel's sign of tingling on distal tapping is not to be depended on in prognosis of recovery after suture. The duration of the paralysis without signs of beginning recovery is the best indicator by which to correlate the questions of physiologic and anatomic interruption.

Harris [126] reports the success of an operation to relieve a median anesthesia of the fingers. The lesion was distal to the muscular branches. The anesthesia was very troublesome, preventing the man from buttoning his coat, etc., and causing numerous burns. An anastomosis of the radial nerve into the distal portion of the median was performed. Sensation returned slowly, but the return was finally complete.

Barling [127] reports a case of a bad wound of the root of the neck with extensive injury to the brachial plexus. This was followed by almost intolerable pain in the arm for more than a year, apparently due to involvement of the plexus in the scar. For relief of the condition, complete intrathecal division of the fifth, sixth, seventh, and eighth cervical, and the first and second dorsal spinal roots was performed. The relief was immediate and permanent.

OSTEOMYELITIS

Bone Necrosis and Suppuration.—Ritter [128] takes issue with the textbooks of pathology and surgery, which nearly all teach that suppuration causes bone necrosis, by maintaining that it is the necrosis which causes the suppuration. To support his contention of this sequence, he calls attention to the fact that, even in the early cases of osteomyelitis, necrosis cannot be prevented by drainage operations. It is always present at operation and rarely increases. Suppuration of the

125. Pollock: Ohio State M. J. **16**:120 (Oct.) 1920.
126. Harris: J. Orthop. Surg. **2**:519 (Sept.) 1920.
127. Barling: Brit. J. Surg. **8**:142 (July) 1920.
128. Ritter: Arch. f. klin. Chir. **114**:1013, 1920.

bone marrow need not necessarily exist. There are certain spots of predilection for osteomyelitis, which suggest that the necrosis is determined by the arrangement of the arteries. In the growing child, as long as the epiphysis persists, the diaphyseal and epiphyseal arterial systems are almost entirely independent of one another, as the researches of Lexer and his pupils have shown. Although there is some collateral circulation, these arteries are to be considered functionally as end arteries. In the growing person, the amount of necrosis is determined by the arterial system, into which the bacterial embolus enters. In the adult, the epiphyseal and diaphyseal arteries communicate with each other much more freely, and the pictures of osteomyelitis in children are very different from those in adults. If Ritter's facts are true and if his reasoning is sound, the article has an important bearing on treatment. It would seem not only to be unnecessary, in many cases, to open the medullary cavity, but also to be dangerous to do so, unless necrosis within the cavity could be proved. He claims to have cured many patients suffering from early osteomyelitis by single or repeated simple drainage operations, sequestration never occurring. Bier is quoted as having reached similar conclusions.

[Ed. Note.—It will be remembered that in the fifteenth Report of Progress we commented on a collection of articles advocating conservative rather than radical bone operations in early acute osteomyelitis on the basis of results obtained by these conservative methods. One of the editors has performed an operation in a case of early osteomyelitis attacking the tibia of a child. The abscess was evacuated by a free incision. The tibia, which was necrotic to a large extent, was not touched. The wound was closed without drainage as an experiment. Healing by first intention occurred, and no sequestration. Another of the editors has observed a similar case, also occurring in the tibia, following measles. In this case, a small opening into the bone near the upper end of the tibia had been made before the patient was seen. The roentgenogram revealed an involvement of almost the entire shaft, which appeared necrotic. There was no temperature or pain and very little discharge. The small opening in no way provided ample drainage for the shaft, but the case went on to complete reformation of the tibia and complete healing, without further operation, except the removal of a small sequestrum which was lying loose in the head of the tibia at the point at which the first opening into it had been made. We are not prepared to advocate such extreme conservatism as a routine, but the cases seem suggestive in the light of Ritter's article.]

Clinical Considerations of Osteomyelitis.—Ochsner and Crile[129] review the gross and microscopic anatomy, physiology, and pathology of bone as necessary to an understanding of the osteomyelitic process.

129. Ochsner and Crile: Surg., Gynec. & Obst. **31**:263 (Sept.) 1920.

The conditions of blood circulation in bone make easy the formation of abscesses, because the nature of the tissue allows for no swelling, and surrounding inflammation and infarction result. These authors maintain that in acute cases the medulla should invariably be freely opened, and hot packs and dry heat should be subsequently applied. In well advanced severe cases, however, they believe surgical intervention should be confined to opening the periosteum throughout the whole area of infection. The use of hot packs and dry heat should follow. In chronic cases complete surgical obliteration of the cavity and removal of all sequestrums is the procedure to be followed, preceded by a search for all possible sources of focal infection elsewhere in the body.

Kidner [130] and Ryerson [131] hold much the same views as to treatment as Ochsner and Crile. Ryerson has been pleased with the results of secondary closures in chronic cases in which, after "saucerization" of the cavity and Dakin-Carrel sterilization, a muscle and fat flap has been turned in.

Heinemann [132] describes his successful closure of bone cavities by the following technic: During the week preceding the operation the bone cavity is cleaned and thoroughly rubbed with tincture of iodin. The sinus is exposed widely through normal tissue if possible. The bone cavity is freely exposed so as to be accessible in all its extent. This cavity is next curetted and wiped out with tincture of iodin. The next step is to cover the soft tissue with wet compresses while the cavity is thoroughly dried by a hot air blower. The hot air vaporizes the iodin, enhancing its antiseptic qualities and thoroughly removing it from the cavity. A flap of fat tissue cut out of a suitable part of the patient previous to the handling of the cavity is now made to fill the sterilized cavity and the soft tissues closed in two layers over the fat. Three cavities of the humerus have been thus closed successfully. He attributes his success, as did Mosetig-Moorhoff, to the peculiarly careful sterilization of the bone cavity before, and at the time of, operation.

AMPUTATIONS

Corner [133] calls attention to the great simplification of amputation operations which the unfortunately large number of war cases has brought about. Discarding the elaborate and varied textbook amputations, he believes that in the lower limb there remain to be advised and practiced only (1) the Syme operation; (2) lower leg amputation 4 or more inches (10 cm.) above the ankle joint with ample skin flaps; (3) amputation of the thigh with long anterior and short

130. Kidner: J. Orthop.Surg. **2**:470 (Aug.) 1920.
131. Ryerson and Beeson: J. Orthop. Surg. **2**:499 (Sept.) 1920.
132. Heinemann: Arch. f. klin. Chir. **113**:811. 1920.
133. Corner: Lancet **1**:114 (Jan. 15) 1921.

posterior skin flaps, and (4) a new amputation through the neck of the femur. In the arm, (1) amputation of the forearm with equal skin flaps; (2) circular amputation of the upper arm, and (3) Spence's amputation at the shoulder are practicable.

Cathcart[134] thinks well of the classical Chopart's amputation in the foot and of amputations through the knee joint.

[Ed. Note.—Chopart's amputation was found generally unsatisfactory by most surgeons during the war, and we see no immediate reason for passing over this experience, but amputations through the knee joint, which have also been somewhat discredited, may have become so because of lack of experience with them. It is generally agreed that in very high lower leg amputations, the best prosthetic result can be obtained by flexing the short stump and bearing weight on the bent knee. Amputation through the knee joint is certainly a less shocking operation than bone section; and if the knee joint is infected, as it frequently is, this method of procedure avoids opening up new channels and provides drainage. It is possible that this mode of amputation should have a definite place.]

Borchgrevink[135] gives testimony to the value of excision of the fibula in all amputations below the knee. The method was employed during the war in the American Army, in all cases in which there were short stumps, and unquestionably it provides a better weight-bearing surface for an artificial limb, by making available the under surface of the external tuberosity of the tibia.

Rockey[136] reports a case of cinematization of the biceps tendon of the arm by the tunnel motor method, in which an excursion of 2 inches (5 cm.) and an ability to lift 75 pounds (34 kg.) was obtained. A satisfactory prosthesis was furnished the elbow, the motion of which was controlled by the opposite shoulder, while the fingers at rest kept open with a spring, can be closed by the biceps motor.

Salomon[137] has been employing with satisfaction a modification of Trendelenburg's procedure for persistent pain and paresthesia following amputation. The nerve is exposed in the stump, its end covered with a thin lead pencil hood and frozen for four minutes. It is then allowed to thaw, and the freezing process repeated once. Pain may be severe for a few days, but has been permanently relieved in all but two cases which were of the neuralgic type, suggesting a more centrally located cause.

---

134. Cathcart: Edinburgh M. J. **25**:281 (Nov.) 1920.
135. Borchgrevink: Ann. Surg. **71**:697 (June) 1920.
136. Rockey: Northwest Med. **19**:209 (Aug.) 1920.
137. Salomon: Deutsch. med. Wchnschr. **46**:1390 (Dec. 9) 1920.

Todd,[138] in the course of a very good discussion of the pathology of amputation stumps, says that he has employed for six years the alcoholic injection of the nerves, and advocates it most strongly.

NEOPLASMS

Total Excision of Clavicle for Sarcoma.—Coley[139] presents the statistics of eighteen personally observed and eighty-seven collected cases of sarcoma of the clavicle, in which the operation of total excision had been performed. Sixty per cent. of the cases occurred before the age of 30, and there was a history of trauma and rapid growth in the majority. The tumors of the clavicle are as a rule of central origin. Coley pleads for the operation of total excision, stating that the operative mortality in these cases was about 8 per cent., and that the functional disability following and the deformity were slight. Postoperative treatment by radium in combination with Coley's toxins he considers important. Only eight out of the 105 patients whose cases he reports have been apparently cured. The course is very rapid, death ensued in several cases five to six months after the tumor was first discovered.

Cofield,[140] discussing the difficulties in the diagnosis of osteosarcomas, considers the deep boring pain, often severe and unrelieved by fixation, to be the most characteristic symptom. He states that the pain of the periosteal sarcomas is likely to be less severe than that of the medullary type.

Blume[141] reports that 37 per cent. of twenty-eight patients having sarcoma who showed retrogression under roentgenologic treatment have been free from all symptoms for periods varying from eighteen months to five years. Twelve of the twenty-eight patients showed recurrences; seven were unaffected by treatment. When there was recurrence, the seat of the tumor was not involved.

Myxomas.—Bloodgood,[142] reviewing his own cases and those of his colleagues at Johns Hopkins, finds that, in every case of myxoma in which the tumor has been removed "piecemeal," there has been recurrence, and that several patients have died of metastases. He believes, therefore, that myxoma must be classed as a malignant tumor and that the presence of myxomatous tissue in any bone tumor is an indication for active radical treatment. If complete excision is to be attempted, there should always be microscopic examination of the margins of the growth. Amputation may well be the safest procedure.

138. Todd: Brit. J. Surg. **8**:88 (July) 1920.

139. Coley: Ann. Surg. **72**:231 (Aug.) 1920.

140. Cofield, R. B.: Some Difficulties in Diagnosis of Osteosarcoma. J. A. M. A. **75**:1264 (Nov. 6) 1920.

141. Blume: Ugesk. f. Læger **82**:943 (July 22) 1920.

142. Bloodgood: Ann. Surg. **72**:712 (Dec.) 1920.

Exploration for diagnosis he considers justifiable, with immediate examination by frozen section. He lays great stress on cauterization of the area from which the diagnostic bit is taken, on account of the danger of operative transplantation of cells. The actual cautery or phenol (carbolic acid) may be employed. It is a rare tumor of periosteal or central origin. Of 270 bone tumors, nine were myxomas and three chondromyxomas. At the present time not a single patient in whose case curetting alone was the operation is well and free from recurrences.

Benign Cysts and Osteitis Fibrosa.—Bloodgood,[143] reviewing 158 cases of central primary bone tumors, in which were included chondromas, myxomas, central giant cell tumors, central sarcomas, and bone cysts (osteitis fibrosa), finds fifty-four cases of bone cysts. The microscopic examination of the fibrous lining, connective tissue lining, and the tissue of the dilated haversian canals, is identical, and points to an inflammatory nature rather than to a neoplasm. It is not quite clear why, in some cases, osteitis fibrosa becomes cystic, but apparently the cystic change is the manifestation of the terminal reaction of which the bone is capable, the next stage going on to endosteal reaction and healing. The microscopic picture is sometimes confusing, the cellular areas which sometimes exist in the fibrous tissue in a case of osteitis fibrosa often being responsible for a diagnosis of fibrosarcoma. The natural termination is to spontaneous healing, fracture or a perforation of the cortex. In the latter case the escaped fluid may cause a soft part and periosteal reaction which may simulate sarcoma. Cartilage cells are sometimes found, but never any myxomatous tissue. A rather tough egg-like lining membrane and an absence of hemorrhage suggest a bone cyst. Myxomatous tissue has the appearance of tapioca stippled with blood. The presence of a distinctly hemorrhagic cyst points to malignancy.

It is often difficult to differentiate bone cysts, in the roentgen-ray picture, from myelomas and central sarcomas. The bone cyst generally attacks the shaft, while the myelomas and central sarcomas are more common in the region of the epiphyses. When healing begins, in the case of a cyst, new endosteal bone formation becomes evident, whereas in myelomas and sarcomas these appearances are not found. The bone cysts occur most often during adolescence, and the spontaneous fractures which may occur are painless. Bone cysts do not recur. The so-called recurrences are usually reported on the basis of unnecessary operations undertaken while the slow process of healing is taking place. This process may occupy a period of two or three years. The femur was the most frequent seat in Bloodgood's thirty-three cases, the tibia next, and the humerus third. As to treatment, the author advises

143. Bloodgood: Southern M. J. **13**:888 (Dec.) 1920.

simple protection to prevent fractures, in patients less than 15 years of age. If fracture occurs, it may lead to healing, and it is treated as an ordinary fracture. In older patients, if the condition is progressive with no roentgenologic evidence of ossification, an exploration should be advised, under most rigid asepsis.

Xanthoma.—Merrill [144] reports a case of xanthoma presenting multiple bone lesions. The findings confirm the previously held opinion that the disease is a systemic condition, in which many of the body tissues may be involved, the more prominent skin lesions being only a surface manifestation, the bones and other tissues frequently sharing in the condition.

Multiple Cartilaginous Exostoses.—Honeij's [145] detailed analysis of sixty-six cases of multiple cartilaginous exostoses has shown a positive hereditary history in all but three. In four cases, a study of the calcium and magnesium metabolism was made and there was found to be an excessive excretion of the alkali earths. No evidence of infectious origin was found.

Maynard and Scott [146] report sixteen cases occurring in four generations of one family. They conclude that the condition is hereditary and that no infectious cause is suggested.

DISLOCATIONS

Recurrent Dislocation of the Shoulder.—Sever [147] states that the portion of the capsule between the insertion of the triceps on the lower edge of the glenoid fossa and the subcapsularis above is the portion most frequently torn in dislocations of the shoulder. A weakness in the capsule in this region results, and if an atrophy of the triceps and subscapularis occurs, these muscles having a direct action in retaining the head in the glenoid, we have an ideal condition for recurring dislocation. The head usually slips out as the arm is elevated and abducted, and its exciting cause, Sever thinks, is a forward pull of the lower portion of the pectoralis major. For treatment of this annoying condition, the author advises a tenotomy of the pectoralis major, without subsequent suture, and a shortening of the tendon of the subscapularis tendon. He considers capsulorrhaphy of secondary importance. Sever says he has completely divided the pectoralis major

144. Merrill: Am. J. Roentgenol. **7**:480 (Oct.) 1920.

145. Honeij, J. A.: Study of Multiple Cartilaginous Exostosis, Arch. Int. Med. **25**:584 (June) 1920.

146. Maynard, H. H., and Scott, C. R.: Hereditary Multiple Cartilaginous Exostosis, J. A. M. A. **76**:579 (Feb. 26) 1921.

147. Sever, J. W.: Recurrent Dislocation of Shoulder Joint, J. A. M. A. **76**:925 (April 2) 1921.

in about forty cases, with no untoward results, it being possible to adduct the arm quite as well as before; and no essential loss of function has resulted.

Thomas [148] reports his results in twenty-six cases of recurrent dislocation of the shoulder, making a total of forty-four, with his previous report of eighteen. His operation, it will be remembered, consists in reefing the capsule at its inferior portion. Of twenty-four non-epileptic patients, eighteen have shown no recurrences, and four others, on whom more than one operation was performed, may be classed as cured, making a total of twenty-two successful results out of twenty-four. Eighteen shoulders of epileptic patients were operated on and seventeen capsule operations were performed, with a successful outcome in eleven. Thomas says that the approach to the inferior portion of the capsule by the anterior axillary or subpectoral route is very difficult, and he advises the posterior route as the route of approach.

Sandes [149] has devised and successfully performed, in five cases, an operation for control of recurrent dislocation of the shoulder. An anterior incision in the pectoral deltoid sulcus is made and the capsule defined. A strip of fascia lata, 30 by 4 cm., is removed from the thigh, and after being rolled up into a band, is passed through a drill hole made in the head of the humerus, horizontally backward, to emerge through the posterior portion of the greater tuberosity. The band is burrowed through the deltoid, brought up over the clavicle and sewed taut to its other end, while the arm is held abducted 45 degrees. This ligament suspends the humerus approximately through its axis of rotation in abduction to a fixed osseous buttress above. The arm is supported in a sling and rested for six weeks.

Gibson [150] reports seven patients successfully relieved of recurrent dislocation of the shoulder, on whom he performed the Clairmont-Erlich operation. The operation consists of employing a portion of the posterior part of the deltoid muscle as a sling about the neck of the humerus to prevent the usual downward dislocation. The longest time which has elapsed since these operations is more than two years.

Subluxation of the Head of the Radius.—Grossman [151] considers this accident quite common and often overlooked, or else diagnosed as a sprain of the shoulder or wrist. It occurs only in children less than 5 years of age, and is almost always the result of pulling or lifting the child by the wrist. It has been called "traumatic palsy" because of the apparent flaccid paralysis, due to the extreme relaxation of the muscles,

148. Thomas: Surg., Gynec. & Obst. **32**:291 (April) 1921.
149. Sandes: South African M. Rec. **19**:27 (Jan. 22) 1921.
150. Gibson: Canad. M. A. J. **11**:194 (March) 1921.
151. Grossman: Med. Rec. **98**:981 (Dec. 11) 1920.

in order to relieve pain. The head of the radius has slipped out of the orbicular ligament, and it may usually be replaced with a "click" by extreme forcible supination. This is the only treatment necessary. The article is based on a study of thirty-seven cases.

Dislocation of Carpal Bones.—Coues [152] reports a case of dislocation of the carpal scaphoid with partial luxation of the semilunar. The patient was seen several weeks after injury, and excision was advised but refused. There was marked disability of the wrist and thumb. Two other cases of dislocation of the carpal scaphoid associated with luxation of the semilunar were found in the literature. In both of these the bones were excised, with great improvement in function. Hönigschmied's experiments on the cadaver lead Coues to believe that intercarpal ligamentous injury with lateral torsion of the wrist would best account for this rather unusual lesion.

Stern,[153] writing on dislocation of the semilunar bone, considers the condition not infrequent. The dislocation is susceptible of reduction in the recent cases by overextension and the use of the Thomas wrench, under complete anesthesia, the bone being held in place by fixation in extreme flexion. Old intractable dislocations should be excised.

Traumatic Dislocation of the Knee Joint.—Platt [154] reports a carefully followed case of true complete traumatic dislocation of the knee joint in a man of 47. Reduction was accomplished and the knee immobilized in plaster for four months, and by a walking caliper for the six weeks following. The patient returned to work in seven months with no instability of the knee, but with flexion limited to 20 degrees. He was seen four years later, after he had served two years in the army. At the time he had from 100 to 110 degrees of flexion and a sound and stable knee. Platt suggests that prolonged immobilization should bring about the same happy result in fresh cases of rupture of both crucial ligaments.

Pathologic Dislocation of the Hip.—Flament [155] calls attention to the not uncommon pathologic dislocations of the hip which occur during or following certain infectious diseases. He has collected eighty cases and finds the relative frequency in the different diseases as follows: typhoid fever, thirty-two; acute articular rheumatism, twenty-four; scarlet fever, thirteen; smallpox, three; Neisser infection, three; influenza, three; erysipelas, one; empyemia, one.

---

152. Coues: Boston M. & S. J. **183**:260 (Aug. 26) 1920.

153. Stern, W. G.: Dislocations of Carpal Semilunar Bone, J. A. M. A. **75**: 1389 (Nov. 20) 1920.

154. Platt: Brit. J. Surg. **8**:190 (Oct.) 1920.

155. Flament: Rev. d'orthop. (July) 1920.

FRACTURES

Results in the Treatment of Simple Fractures.—Estes [156] reviews the statistics which he collected as chairman of the committee on fractures of the American Surgical Association. Of the 739 cases analyzed, 120 only were the result of direct violence, and 619 the result of indirect violence. In the British and American groups, the incidence as to age varied considerably, the British showing more than twice as many cases in patients less than 10 years as in any other decade, while the decade of greatest incidence in the American reports was from 20 to 30. In comparing the operative with the nonoperative results, Estes finds that more perfect anatomic alinement was secured by operation, but that the functional recoveries were higher in the cases of patients who were not operated on. The average length of the period of disability is also interesting. For the shaft of the humerus, the period was fourteen weeks; for the head and neck of the humerus, eleven and one half weeks; for the condyles of the humerus, nine weeks; for the shafts of both bones of the forearm, ten and four fifths weeks; for the femur (all sites), seven and thirty-seven hundredths months; for the fractures of the lower leg (all sites), four and three-fourths months.

A Study of Bone Grafting Operations in U. S. Army Hospitals.—Walker [157] has compiled some incomplete but suggestive statistics from the records of the Surgeon-General's office. There were about 25,000 fractures as a result of war wounds in the A. E. F., and 15,165 of these were of the long bones. There have been reported thus far 906 cases of nonunion, and of these, 611 were treated by bone grafting operations. Walker concludes from a study of the results as reported that the autogenous grafts from the tibia have given the best results, and that it is reasonably safe to perform this operation four months after complete healing has taken place. In the ratings for disability which have thus far been made, about one half of the cases (48 per cent.) have shown less than 25 per cent., and about one-fourth (22 per cent.) more than 35 per cent., and 8 per cent. more than 50 per cent. of disability.

Union of Septic Compound Fractures.—Gallie [158] maintains that sepsis favors union in compound fractures rather than prevents it. His investigations have convinced him that inflammation, either caused by infection or resulting from severe trauma with comminution, increases the amount of callus. Bone infection may interfere with union when the bone ends are necrotic. Gallie does not approve of

156. Estes: J. M. Soc. New Jersey **17**:291 (Sept.) 1920.
157. Walker: Ann. Surg. **73**:1 (Jan.) 1921.
158. Gallie: Canad. M. A. J. **10**:407 (May) 1920.

the commonly employed methods of removing sequestrums, cleaning up the sepsis, and allowing the wound to heal and remain healed for several months before any attempt is made to overcome the pseudarthrosis. The method which he has employed in Toronto in the large number of war cases, and of which he speaks most enthusiastically in light of the results, was to remove the sequestrums and at the same time to shorten the limb by approximating the freshened fragments after excising all the scar tissue, suturing the ends with kangaroo tendon. Bony deformities resulting from malunion were corrected by osteotomy at the same time that the patient was operated on for the coexisting osteomyelitis. He points to the great saving of time which this method accomplishes, and says that union practically always occurs.

Schrock [159] believes that after an intra-articular fracture has been reduced with or without operation, the muscles about a joint should be stimulated to active contraction by the second or third day, while the limb is in a splint. He also believes that slight active (never passive) motion of from 5 to 10 degrees should be encouraged, if painless, on the fourth or fifth day, and that on the tenth day, active motion up to half normal should be the goal, increasing to 90 per cent. of the normal range by the third week. No passive motion is to be given and no pain is to be caused.

Compression Fractures of the Lower End of the Radius.—Stevens [160] advocates giving up the name Colles' fracture, and calling the common fracture of the lower end of the radius "compression" fracture. He thinks that there is little actual impaction in most cases; the jamming together of the two portions causes an actual loss of substance; and while deformity can be corrected, it is often impossible to secure absolute anatomic reposition. He urges the importance of early motion, getting rid of all splints, and using a wrist strap only at the end of two weeks. He presents records of four cases.

Troell [161] also concludes that the majority of radial lower end fractures are compression fractures, or are due to hyperextension of the wrist.

Fracture of Tip of Distal Phalanges of Fingers.—Maddren,[162] on the basis of twenty-seven cases, calls attention to the fact that fracture of the tip of the distal phalanx is not a trivial injury. The roentgen ray alone often makes the diagnosis possible. The first symptoms are often mild; but, of twenty-seven patients, one lost 196 days from

159. Schrock, R. O.: Early Active Motion in Intra-Articular Fractures, J. A. M. A. **75**:1320 (Nov. 13) 1920.

160. Stevens: Ann. Surg. **71**:594 (May) 1920.

161. Troell: Ann. Surg. **72**:428 (Oct.) 1920.

162. Maddren, R. F.: Fracture of Tip of Distal Phalanx, J. A. M. A. **75**: 1198 (Oct. 30) 1920.

work, and seventeen others lost an average of sixty days each. The reason for this disablement, in 66 per cent. of the cases, was persistent tenderness and late infection. Early recourse to surgery is indicated. As soon as the diagnosis can be made, an incision should be made into the connective tissue sac about the fracture, to relieve pressure. The route under the nail or a lateral incision may be employed, deep enough to open this sac. The results in his twenty-seven consecutive and unselected cases have been excellent, disability averaging only six and three-tenths days. No man was incapacitated more than thirty days.

Fractures of the Femur,—Speed's [163] excellent article on fractures of the femur analyzes 526 cases. About half were fracture of the neck or through the trochanters, and about half fractures of the shaft. There were 56 deaths, a mortality of 11 per cent. Half of these deaths were due to pneumonia. Intertrochanteric fractures were a little more common than fractures of the neck. Fifty-one operations were performed, with a mortality of 8 per cent. He advocates the abduction treatment in all cases of neck and intertrochanteric cases. He considers that alinement is the most difficult in cases of subtrochanteric fracture, because of the flexion and abduction of the proximal fragment. It is necessary to treat this type by a combination of traction, flexion and abduction of the distal fragment. In fracture of the shaft, after union has been secured by reduction and maintenance in the Thomas or some other splint, or by direct skeletal traction, a walking caliper should be applied before the patient is allowed to walk.

Campbell,[164] in ununited fractures of the neck of the femur, has made a trial of numerous methods. In seven cases, a wire nail was driven through the trochanter, neck and head. In two patients the results were successful, one was improved, and in four the operation was a failure. In twenty cases, tibial grafts were employed, with successful results in fourteen, improvement in one, and two failures. In three cases the results are unknown. In two, the head of the femur was excised and the trochanter placed in the acetabulum after the method of Brackett, with good results.

Fractured Patella.—Hertzler [165] has employed with satisfaction, in transverse fracture of the patella, a method attributed to Dr. G. A. Nickelson of Plains, Kansas. Two stout steel pins are put through the infrapatellar and suprapatellar tendons, as close as possible to the bone fragments, and these projecting ends are approximated by bandages or adhesive plaster. The author presents the roentgenograms

163. Speed, K.: Treatment of Fracture of Femur, Arch. Surg. **2**:45 (Jan.) 1921.

164. Campbell: Southern M. J. **13**:585 (Aug.) 1920.

165. Hertzler: Surg., Gynec. & Obst. **32**:273 (March) 1921.

in a case of transverse fracture with considerable separation of the fragments, in which good apposition and bony union resulted. These pins were not painful to the patient. The leg was supported in a splint, but this was removed from time to time, and the knee exercised. The joint is not opened by this method.

Fractures of the Tibial Spines.—Jones [166] reviews the literature of this rather rare injury, sustained from a severe trauma, acting directly on the knee joint. When the injury is acute, there may be crepitus, tenderness over the inner side of the knee, and locking. The treatment consists of manipulation in order to gain complete extension, and immobilization in plaster for from two to three months.

Stave Fracture of the First Metatarsal Bones.—Cooperman [167] reports a case of stave fracture of the first metatarsal and compares it with the stave fracture of the first metacarpal (Bennett's), which penetrates into the joint between the trapezium and the metacarpal, owing to force acting on the end of the thumb. In the stave fracture of the foot, the fracture penetrates into the joint with the internal cuneiform, but is due to a force exerted on the heel while the first metatarsal head is fixed by weight bearing.

ROENTGENOLOGY

Angle of Epiphyseal Line Between Head and Neck of Femur.—Cramer [168] finds a very wide variation in the angle which the epiphyseal line between the head and neck of the femur makes with the horizontal line. He has examined, roentgenologically, sixty-eight children from 1 to 17 years old. The angle varies from 0 to 50 degrees. Fifty per cent. of the cases showed an angle of approximately 15 degrees.

Bucky Diaphragm.—Potter [169] calls attention to the greatly improved roentgenograms of the spine, which are now possible by the use of the Bucky diaphragm, and to their enhanced value as diagnostic aids. They not only give a heightened contrast between bone and soft parts, but also a greater clearness of outline in the more delicate bony framework of the spine.

[ED. NOTE.—We would go so far as to say that the use of this apparatus has become a sine qua non if we desire to obtain from roentgenograms the greatest amount of information concerning deep bone structures. Its principle is the construction of a parallel grid which moves between the patient and the tube during an exposure, absorbing most of the fogging secondary rays, its own shadow

166. Jones: Colorado Med. **17**:217 (Aug.) 1920.
167. Cooperman: Ann. Surg. **73**:215 (Feb.) 1921.
168. Cramer: Ztschr. f. orthop. Chir. **40**:366, 1920.
169. Potter: Am. J. Roentgenol. **8**:61 (Feb.) 1921.

neutralized by its movement. Plates of the spine taken by this method are in a distinct class by themselves when compared with plates taken by the old technic.]

Diagnosis of Syphilis in the Fetus.—Shipley, Pearson, Seech and Greene [170] have examined, by roentgenograms, about 300 white fetuses, varying from the age of 6 months to, nearly, term, with the purpose of studying the variations from normal. They make the surprising statement that of the first 100 plates studied, fifteen revealed evidence of advanced syphilitic osteochondritis. Ten gave signs of less marked syphilitic disease, and thirty-one revealed one or more bones which varied from the normal and were noted as suspicious. Briefly, 25 per cent. revealed, according to these investigators, marked skeletal signs of syphilis. Practically all the bones may be affected by the syphilitic process; but, even in advanced cases, it seems to interfere very little with skeletal growth.

RESEARCH

Compression Trauma as an Entity.—Nathan [171] has carried out a series of experiments on animals to determine the morbid conditions which ensue in those subjected to different kinds of contusion injuries. He believes these conditions may be expected after fractures. They are twofold: (1) the direct injury to the tissues at the time the force is applied, and (2) the secondary conditions brought about by the tension within the tissue, resulting from the extravasation of blood and the inflammatory exudate. The muscle and nerve fibers, with their end organs, are exceedingly sensitive to compression and irritation, and these secondary conditions are quite likely to lead to disabilities quite out of proportion to the damage from the original compressive force. In the main they consist of: (1) more or less marked and persistent neuromuscular, neurotrophic, and vasomotor disturbances; (2) inhibition of joint motion, with signs of intra-articular injury and intro-articular and peri-articular inflammation; (3) inhibition of joint motion, with the signs of intra-articular inflammation appearing when attempt is made to reestablish joint mobility.

Immunologic Distinctions Between Encephalitis and Poliomyelitis.—Amoss [172] believes that these two diseases can be distinguished by the power of the blood serum of convalescent cases of poliomyelitis to neutralize the virus of poliomyelitis; whereas the blood of convalescent patients in cases of epidemic encephalitis is devoid of this power. He believes that, at the present time, the evidence points toward these two

170. Shipley, Pearson, Seech and Greene: Bull. Johns Hopkins Hosp. **32**: 75 (March) 1921.

171. Nathan: Surg., Gynec. & Obst. **32**:62 (Jan.) 1921.

172. Amoss: J. Exper. M. **23**:187 (Feb.) 1921.

conditions being integrally distinct affections. They both may be infections, the main lesions of poliomyelitis being present in the spinal cord, while those of encephalitis are found in the midbrain.

Strength of Nerve Suture.—Miller [173] has attempted to determine the tensile strength of experimental end-to-end nerve suture, employing the sciatic and popliteal nerves of dogs. These nerves were recovered at varying intervals after suture, and subjected to tests of tensile strength. It was found that this strength was as great after the end of the third week as after the fourth or fifth, being roughly proportionate to the diameter of the nerve. The epineural sutures of silk or catgut seem to play little part after the second week. The investigator advises waiting, in human cases after suture of the sciatic, from six to eight weeks before putting strain on the suture line. In the median and the ulnar, extension of the forearm should be delayed until four weeks have elapsed.

Infection of Tubercle Bacilli into the Metaphyses of Long Bones.—Oliver,[174] discussing Ely's claim that peculiarities in the structure of the bone marrow determine the localization of tuberculous infection in long bones in the epiphysis and metaphysis, states that this is in contrast to the more diffuse process seen so often in the pyogenic infections. Lexer's theory has been that the embolic deposit of bacteria is favored by the anatomic arrangement of the arteries. Oliver's experiments seem to confirm the view that the common localization of the tuberculous infection in the metaphysis and epiphysis is due to the peculiarities of structure of the bone marrow. This tissue in the metaphysis, in contrast to the fatty marrow of the diaphysis, is rich in cells which are peculiarly concerned in the reaction to infection by the tubercle bacilli.

Regeneration of Long Bones.—Martin's [175] experiments on dogs seem to show that regeneration of bone can proceed from the endosteum alone. If there is destruction of the periosteum and cortex, regeneration will, however, not be complete and eventual pseudarthrosis results. The periosteum alone cannot fill the defect as well as the endosteum. The endosteum lining the haversian canals plays a distinct part in the regenerative process. Further experiments by Martin have shown a great difference in the power of the periosteum to produce new bone in growing and adult animals. It is only in the growing dogs that the periosteum seems able to produce callus without the help of the cortex and marrow. If a circular resection of the periosteum and cortex is performed, a pseudarthrosis results. A callus was formed, but a gap

173. Miller, E. M.: Nerve Suture: An Experimental Study to Determine the Strength of Suture Line, Arch. Surg. **2**:167 (Jan.) 1921.
174. Oliver: J. Exper. M. **32**:153 (Aug. 8) 1920.
175. Martin: Arch. f. klin. Chir. **113**:1, 1920; **114**:668, 1920.

persisted between the fragments. The surrounding bone tissue showed a regressive change, and the interesting observation was made that a similar regressive metamorphosis occurred in the parallel bone of the forearm or leg and may proceed to actual pseudarthritis at the same level as on the bone operated on.

Rôle of Cancellous Tissue in Bone Healing.—Todd,[176] after studying cases of chronic osteomyelitis, believes that cancellous bone plays such an important part in regeneration that its integrity ought to be carefully preserved whenever possible. Its activity as a regenerating structure is greatest as the middle of the shaft is approached. Todd thinks we should be most careful in our "disinfection" of cavities, as this procedure often kills the remaining tissue, from which regeneration must be expected.

Autogenous and Homogenous Transplants of Bone in Dogs.—Brooks and Hudson [177] have found that a defect in the shaft of a bone in a dog may be permanently regenerated by a bone transplant removed from another dog. These homogenous transplants were successful in 76.8 per cent. of the experiments, while autogenous transplants succeeded in 84.8 per cent. of the cases.

Recognition of Dead Bone.—Phemister [178] has made physiologic and roentgen-ray studies, attempting to discover characteristics by which dead bone may be recognized in the living body. In the main the characteristics are: 1. Color. Dead bone becomes eventually white instead of purplish, but this whiteness is not an early change; moreover, spongy bone may retain old blood or granulation tissue and appear dark until washed. 2. Erosion. If the dead bone is in contact with an involucrum, either from the inside or outside, its surface may become eroded. 3. Density. This is usually greater than that of living bone, but often deceptive in the roentgenogram if erosion has occurred and a thin flake is roentgenographed on the flat. 4. Line of demarcation. This can usually be detected by the roentgen ray, or at operation, and one of the helpful signs is the preservation, on the dead bone, of the original sharp points or jagged line of fracture. 5. Sinuses lead down to dead bone.

APPARATUS

Fracture Band.—Collins,[179] striving to avoid the ringlike constriction of the bone which the simple Parham band exerts and which, in certain instances, seems to cause bone atrophy, has devised a band

176. Todd: Ann. Surg. **72**:452 (Oct.) 1920.

177. Brooks, B., and Hudson, W. A.: Studies in Bone Transplantation, Arch. Surg. **1**:284 (Sept.) 1920.

178. Phemister: Ann. Surg. **72**:466 (Oct.) 1920.

179. Collins, A. W.: Fracture Reduction and Fixation with a Specially Designed Band, Arch. Surg. **2**:354 (March) 1921.

applied in the same way as the Parham, but shaped like a fenestrated square at one end. This distributes the pressure and avoids the ring-like constriction. He reports its use in a hundred cases, with eight removals.

Protractor.—Robinson,[180] of Pittsburgh, like his fellow townsman Silver, has devised a protractor for measuring the range of joint motion. Silver's pattern (unpublished) is the better, since one may adjust the instrument to measure from the center of joint motion, while the protractor is stable. Robinson's is, however, very convenient, and of vest pocket size and entirely practical.

[ED. NOTE.—We cannot urge too strongly the use of some accurate recorder of joint motion and angles of joint or bone deformity. The experiment of asking any group of well-trained surgeons to estimate by sight alone the range of any given motion or the angle of any deformity may be tried. It will be found that these estimates of sight will vary from 10 to 45 degrees. If records which purport to record progress or retrogression are to be kept, or the patient is to be stimulated to an effort to increase his mobility, a protractor of some sort is absolutely essential. No surgeon can possibly keep accurate records without one.]

MISCELLANEOUS

Adventitious Ligaments Simulating Cervical Ribs.—Law,[181] on operative exploration of four cases of arm pain in which a short or rudimentary cervical rib was present, has found adventitious ligaments stretching from their forward ends to the first rib or sternum. In all the four cases there was pinching of the nerves and vessels between this adventitious ligament and the scalenus anticus muscle. The ligaments were all taut and varied in their points of insertion, one entering the scalene tubercle of the first rib with the muscle, another the costoclavicular ligament, and a third near the head of the clavicle. After operative intervention, the neuralgia persisted for a short time, quickly becoming less severe and finally disappearing.

Bone Typhoid.—Bohmansson[182] cites a case in which multiple foci of bone infection suggesting typhoid lesions led to the diagnosis. There were almost no other suspicious clinical symptoms. Positive cultures were made from a bone focus. The case suggests that the severity of the primary disease is no index to the likelihood of bone lesions in typhoid.

Anatomic Variations in the Lumbar Spine.—Goldthwait,[183] presenting sixteen illustrative roentgenograms, suggests that more frequent

180. Robinson: J. Orthop. Surg. **3**:41 (Feb.) 1921.
181. Law: Ann. Surg. **72**:497 (Oct.) 1920.
182. Bohmansson: Ann. Surg. **72**:486 (Oct.) 1920.
183. Goldthwait: J. Orthop. Surg. **2**:416 (July) 1920.

roentgenograms of the dorsolumbar region will probably reveal, if properly interpreted, the explanation of many obscure low back and "kidney" pains. We know that many sacral and sciatic pains can be relieved by changing the posture. In the slender, "lanky" individual, with a sagging, visceroptotic posture and a narrowed costosternal angle, the lower ribs may be seen to impinge on a long transverse process. Most cases can be fairly easily relieved when the true mechanical conditions are recognized.

There is a good deal of French literature at present dealing with the abnormalities of the fifth lumbar vertebra as a cause for backache and sciatica. Thus, Nové-Josserand and Rendu [184] report nineteen cases, and conclude that, while the operative removal of a portion of a projecting transverse process has given relief in certain cases, it is usually unnecessary.

Mauclaire [185] has operated on one patient unsuccessfully, but apparently still believes in the operation, suggesting a gallows-shaped incision, vertical in the midline and transverse at the top.

Richards [186] held "sacralization" of the fifth lumbar vertebra responsible for low back pain in 90 per cent. of sixty cases. He thinks that only operative treatment is effective.

[Ed. Note.—The authors who advocate this serious operation, i. e., the removal of transverse processes, as a routine measure for the relief of symptoms referable to anomalies of the fifth lumbar vertebra seem to us to miss the significance of the fact which, strangely enough, they frequently mention, namely, that the symptoms are often of very recent onset, while the abnormality has, of course, existed since birth. It may be that in certain cases long continued slight irritation may cause hypertrophy of bone and that these overgrowths may cause the nerve-root pressure. As a rule, however, we believe that the two great exciting causes of the symptoms are some sudden back strain or trauma, or the gradual strain, sagging and impingement which an habitually faulty posture brings about. Now, unless actual bony changes in the way of overgrowth have occurred, it has been our experience that conservative treatment by means of the protection afforded by belts or braces and the gradual persistent correction of the posture by means of exercises are quite sufficient to relieve the symptoms. When a strain is superimposed on a vertebral abnormality and unnatural lines of leverage are emphasized by the trauma in this place of lessened resistance, recovery may be more slow than that following a strain of a normal back. A lumbosacral joint of abnormal contour may always be a *locus minoris resistentiae,* but not necessarily one which demands a serious operation.

184. Nové-Josserand and Rendu: Presse méd. **28**:514 (July 28) 1920.
185. Mauclaire: Paris méd. **11**:81 (Jan. 29) 1921.
186. Richards: Bull. et mém. Soc. méd. de hôp. de Paris, July 30, 1920.

Pelvic Articulations During Pregnancy.—Lynch[187] has made a roentgenologic study of the pelvic articulations during pregnancy and labor and the puerperium. He finds that, while it is comparatively rare for the symphysis pubis to be widened during pregnancy, the sacro iliac spaces are almost constantly widened.

Growth Epiphysitis.—Froelich[188] considers that the growth lesions of the tibial tubercle (Osgood-Schlatter disease), Köhler's disease of the scaphoid, apophysitis of the os calcis, trochanteritis, epicondylitis, epiphysitis of the base of the fifth metacarpal, etc., should all be grouped under the one name of growth epiphysitis. He considers them all mild forms of osteomyelitis, whose importance is their liklihood of being mistaken for tuberculous bone lesions.

[ED. NOTE.—We are in accord with the proposal to group all these conditions, now frequently erroneously designated by the name or names of the men who first described them, under some such name as growth epiphysitis, with the exception of Köhler's disease. This seems to us still to be unexplained in its etiology and not to belong to this large group. Köhler, at the Radiographic Congress at Wiesbaden, in 1908, first described this peculiar lesion of the scaphoid bone of the foot, and Mouchet and Roederer[189] and Regaud[190] recently have added to our knowledge. It is a peculiar change in the structure and apparently represents a developmental abnormality of a nontraumatic and noninfectious origin, since the two bones may be affected at the same time in one person. The bone is narrowed in width, sometimes almost disk-shaped, and of far greater density than normal. We do not agree with Froelich that the probable cause of what he designated growth epiphysitis is a low grade osteomyelitis. It seems to us that it is entirely unnecesary to suppose an infection, both from the speedy relief from protection alone and from the absence of other signs of infection. We consider it most likely to be merely an irritation of a growing center by a strong muscle pull. They all occur in regions in which a powerful muscle is attached to a small ununited center of bone growths. We believe them to be, generally speaking, indirect traumatic inflammations in subjects who have not attained full growth, and in the neighborhood of those epiphyses that are not yet united and subjected to powerful muscle traction.]

Curative Play.—Schauffler[191] describes an excellent curative play system in force at the Mercy Hospital in Kansas City. He is enthusiastic over the results obtained in cases of weakened muscles and stiff

187. Lynch: Surg., Gynec. & Obst. **30**:575 (June) 1920.
188. Froelich: Paris méd. **10**:430 (Dec. 4) 1920.
189. Mouchet and Roederer: Rev. d'orthop., July, 1920.
190. Regaud: J. de radiol. et d'electrol. **4**:453 (Oct.) 1920.
191. Schauffler: J. Orthop. Surg. **3**:98 (March) 1921.

joints by thus inducing the use of the limbs under the stimulation of various games and competitive exercising machines, such as velocipedes and "kiddie cars."

Presidential addresses, delivered by men who have played no small part in the advancement of this branch of surgery, demand comment in the report of orthopedic progress. Col. Clarence Starr [192] of Toronto, before the American Orthopedic Association, made a strong plea for the more thorough training of orthopedic surgeons in general surgery, and the gradual widening of the scope of the specialty to include the surgery of the extremities and spine in general. Fractures and osteomyelitis and the standardization of methods of physiotherapy seem to him most promising fields for investigation.

Major-Gen. Sir Robert Jones,[193] in a presidential address before the British Orthopedic Association, defines what seems to him the scope of orthopedic surgery; (1) fractures, recent, malunited, and ununited; (2) congenital and acquired deformities of the extremities; (3) paralysis of the extremities, and (4) diseases and disabilities of the joints, including the spine. He suggests a scheme for hospital organization. In a general hospital of 300 beds, he believes forty is a fair proportion to allocate to orthopedic surgery, with beds in the country for children, the general surgeon having a right to treat any case or group of cases of extremity surgery in which he is especially interested. His aim, as is the aim of all fair-minded orthopedic surgeons, is not to take away from the general surgeon any group of cases in which he is interested and to the treatment of which he is willing to bring devotion and skill, but to bring about a more speedy restoration of function by stimulating the interest and developing the skill of a certain group of surgeons to whom this type of case appeals both as an interesting surgical problem and as a humanitarian necessity.

---

192. Starr: J. Orthop. Surg. **2**:381 (July) 1920.
193. Jones: Brit. M. J., Nov. 20, 1920.

ARCHIVES OF SURGERY

VOL. 4 MARCH, 1922 No. 2

VENTRICULOCORDECTOMY

A NEW OPERATION FOR THE CURE OF GOITROUS PARALYTIC LARYNGEAL STENOSIS *

CHEVALIER JACKSON, M.D.

PHILADELPHIA

The literature of laryngeal stenosis is so burdened by the premature reports of cases that I have waited for the lapse of time to prove the permanency of what I believe to be an ideal operation for the cure of that form of stenosis associated with bilateral recurrent paralysis when the stenosis is due solely to the paralysis. In these cases, tracheotomy has usually been already performed for urgent dyspnea and the patient comes to the laryngologist for decannulation.

PREVIOUSLY DEVISED OPERATIONS

The ideal operation would, of course, be the reestablishment of nerve continuity by resection and anastomosis, with or without transplantation. Obviously, this procedure would be limited to peripheral cervical lesions. It would be impracticable in laryngeal paralysis due to central or the usual mediastinal lesions. It has been done with an excellent result in a case of monolateral paralysis by J. Shelton Horsley and Clifton M. Miller.[1] Neuroplastic surgery directed to anastomosis of the recurrent with the pneumogastric nerve may yet be demonstrated as useful. Any procedure designed to restore motility must be done within a year after the complete loss of abduction, because after a certain period, usually only a few months, loss of motility is followed by neural and muscular atrophy, after which resumption of motion even with reestablishment of nerve continuity becomes hopeless. Complete recurrent paralysis and lost tonus evidenced by a cadaveric position of the cords render it hopeless to expect any motility; but in most of these cases the stenosis has been relieved by the greater glottic area afforded. This has led to attempts at creating the cadaveric

* Read before the American Laryngological Association, Atlantic City, N. J., June, 1921.

1. Horsley, J. S., and Miller, C. M.: Suture of the Recurrent Laryngeal Nerve, Tr. South. Surg. & Gynec. A., December, 1909.

position by section of the recurrent nerves; the results, however, have been disappointing in not creating the desired cordal position. Extirpation of a section of the nerve in one case, suggested by myself, was followed by the cadaveric position. The chief objection to this procedure is that with a cadaveric position of the cords the expectoration is very imperfect, and if tracheobronchial or pulmonary sequelae or intercurrent conditions develop, the patient may even drown in his own secretions, as I previously pointed out.[2]

Endoscopic evisceration[2] is quite effectual in relieving the stenosis and readily brings about decannulation; but the expectorative and vocal results following such a procedure are not so good as those following ventriculocordectomy.

Laryngostomy is very effectual in restoring oronasal breathing, and the expectorative and vocal results are usually good; but there is not the necessity for the prolonged period of after-care in paralytic cases that exists in the cases of cicatricial laryngeal stenosis. When, however, the paralytic stenosis is complicated by cicatrices, as for instance from a high tracheotomy, the operation of laryngostomy may be necessary; but even here the cicatricial part of the trouble, if not too extensive, may, in many cases, yield to bouginage after ventriculocordectomy has removed the cordal obstruction.

Bouginage has no effect whatever on paralytic stenosis, the cords freely separating to admit the bougie and promptly collapsing on its withdrawal, giving much the same appearance as "making a hole in water."

Intubation has no permanent effect on the stenosis, but is often suggested as a substitute for tracheotomy for the relief of the dyspnea in abductor paralysis. Such use is, however, exceedingly dangerous because of the probability of an asphyxiating dyspnea should the tube be coughed out in the absence of an expert intubator to replace it.

Cordectomy, the excision simply of the cord, has been tried and found unsatisfactory by Gleitsman and others. I have had success with it only in a very few cases. It was performed many years ago, and I now believe that the successful cases included more tissue than the cord alone, and were in fact a ventriculocordectomy imperfect and incomplete because of the difficult method of work with the mirror or through the Kirstein autoscope. So far as the latter instrument is concerned, possibly the results in this and other operations might have been better if employed with the technic and manipulative experience since acquired.

---

2. Jackson, Chevalier: Peroral Endoscopy and Laryngeal Surgery, St. Louis, Laryngoscope Company, 1914; Drowning of the Patient in His Own Secretions. Editorial, Laryngoscope **21**:641 (Dec.) 1911.

DYSPNEA IN BILATERAL RECURRENT PARALYSIS

This is due, of course, mainly to the paralysis of the crico-arytenoidei postici; but there is another factor which I believe I was the first to point out. It is a purely mechanical one, due to the shape of

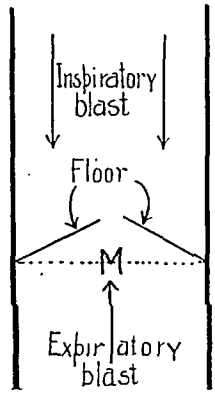

Fig. 1.—Schema illustrating the tight closure of the glottic chink by the inspiratory blast in bilateral abductor paralysis, on the mechanical principle of a check-valve. The expiratory blast opens the glottic chink wider. During inspiration, pressure on the ventricular floor narrows, or even tightly closes, the chink.

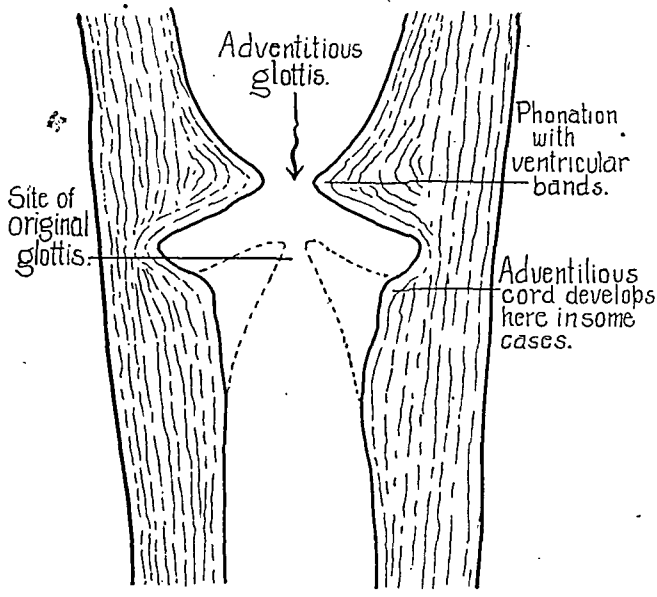

Fig. 2.—Schema showing probable coronal cross-section of larynx after ventriculocordectomy, judging by appearances on mirror examination in cases in which there was no formation of an adventitious cord.

the ridge of tissue supporting the cord and forming the floor of the ventricle. The tapering shape of the subglottic airway (Fig. 1) encountered by the upward moving expiratory blast widens the flaccid

glottic margins; whereas, on inspiration, the flat floor of the ventricles is depressed, throwing the cordal edges together and thus tending to close the glottis tighter. The more sudden and strenuous the effort to inspire, the quicker and tighter the closure. This is one of the chief reasons why the patient's distress is less, the more quietly he breathes; whereas panic and strenuous efforts lessen the actual amount of air he can pull through the glottis. It seems quite likely that a portion of the good results obtained by ventriculocordectomy are due to the alteration in the shape of this ridge of tissues at each side of the glottis. Exactly what the cross-sectional shape is after cure by this operation I have not yet been able to demonstrate, because there has as yet been no opportunity to obtain a postmortem examination in any of the cases; but judging by the laryngoscopic appearance, the flat floor of the ventricle is replaced by a sloping wall and the cross-section is probably similar to that shown in Figure 2.

BILATERAL ABDUCTOR PARALYSIS DUE TO GOITER

Most of the cases of bilateral laryngeal paralysis of peripheral origin that have come to the Bronchoscopic Clinic have been caused by goiter. Very rarely has the paralysis been the result of the thyroidectomy. Usually laryngeal motor trouble has been present before operation, though not always detected because the larynx was not examined. In quite a number of cases, I have been able to protect the surgeon by careful analysis of the history. The necessity for an examination of the larynx before every goiter operation, first strongly urged by myself, is now quite generally recognized.

VOCAL, PROTECTIVE AND EXPECTORATIVE RESULTS OF VENTRICULOCORDECTOMY

The three chief functions of the larynx are phonation, protection and expectoration. Any laryngeal operation proposed must be considered in its results on these three functions. In all of the seven selected cases in which operation was performed by this method, a voice louder than an ordinary whisper has been obtained. In four cases the voice has been loud enough to be heard across a large room. Including these four there have been, altogether, six patients that had a voice loud enough to carry on ordinary conversation in a reasonably quiet room. The voice, while rough and of a "stage-whisper" quality in some, was in others smoother but deep in pitch. In the latter group of cases, the ventricular bands took on the function of the vocal cords. This vicarious functioning of the ventricular bands is quite regularly seen in other than paralytic conditions, often having in such cases the full approximating excursions of a pair of true vocal cords; but since the bands lack tension and thinness, the voice is usually deep

and rough. In the class of cases now under consideration, which were paralytic, full active excursion was not to be expected; yet an unexpected degree of approximation of the ventricular bands was present during forced phonation, possibly from the partial action of muscles (chiefly the crico-arytenoideus lateralis), to which unparalyzed filaments of the recurrents functioned, or to external accessory muscles not innervated by the recurrent nerve. One pair of muscles that was palpably active in most of the cases was the cricothyroidei. The arytenoid cartilages in all of the cases certainly showed some degree of rotation on the crico-arytenoid joint, whatever may have been the muscular mechanism. In two cases the motion was so nearly normal in range, and the adventitious cords so nearly resembled normal cords that it would have been difficult without the history to realize that an abductor paralysis had been present and that the normal cords and their support had been excised. In these cases on theoretical grounds I assumed that the crico-arytenoideus lateralis had retained full functional activity, dragging out and forming an adventitious cord

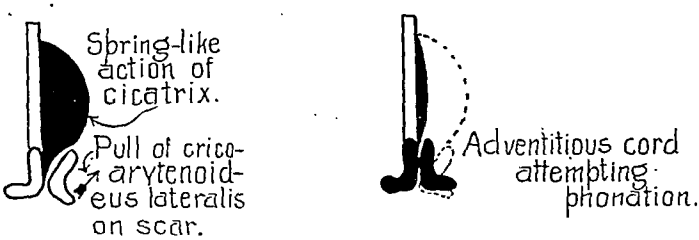

Fig. 3.—Schematic representation of the author's theory of development of an adventitious cord.

from the cicatricial tissue that resulted from the ventriculocordectomy, just as happens so often after thyrotomic excision for cancer (Fig. 3).

On theoretical grounds, I have assumed that by excising the cordal tissues that can no longer be pulled out of the way because of the paralysis of the crico-arytenoideus posticus we substitute the elasticity of a scar for the activity of the paralyzed muscle, the elasticity producing the abduction while the still active crico-arytenoideus lateralis produces the abduction, just as in the common mechanical reciprocal movement, positive forward with spring return. The only evidence against this theory is that we would expect a certain percentage of the patients to show a later loss of motility of the ventricular bands or adventitious cords due to the subsequent paralysis of the crico-arytenoideus lateralis, and this did not occur. Whether or not this series of cases happened to include no case of later paralysis of the crico-arytenoideus lateralis it is impossible to say. So far as the ventricular bands are concerned it is by no means clear that a large part of their vicarious motility may not have been due to the drag of a muscular

synergistic combination of which the crico-arytenoideus lateralis is not a part. To what extent a movement of the thyroid and cricoid cartilages, one upon the other, contributed to the result I have been unable to determine. There is certainly a difference in the laryngoscopic postoperative appearance of the cases here reported as compared to what I have called the "wooden" appearance of the paradoxical "living cadaveric" larynx. Part of this difference consists in the squeezing together of the upper laryngeal orifice in the ventriculocordectomized larynx. The degree of this "orbicular narrowing," as I have called it, is probably dependent somewhat on the degree to which the arytenoideus is innervated by the superior laryngeal nerve. The participation of this nerve in the motility is probably subject to wide individual variations, participating largely in some and not at all in others. The superior laryngeal seemed not to be implicated in any of the cases in the series on which this article is based.

Leaving all these theoretical considerations for future determination, there can be no question as to the clinical fact that the phonetic, protective and expectorative condition of the patient is very much better than that of patients whose recurrent paralysis has reached the complete stage known as cadaveric. In view of this clinical fact, though founded on but seven cases, it becomes a question as to the advisability of delay after it is clear that the crico-arytenoideus posticus will not resume its function.

CASES SUITABLE FOR VENTRICULOCORDECTOMY

Innumerable failures to secure satisfactory results always follow operation in unsuitable cases. To this rule, ventriculocordectomy is no exception. It cannot be too emphatically stated that if success is expected from ventriculocordectomy alone its performance *must be limited to cases totally free from cicatricial stenosis.* At first thought it might be considered strange that cicatricial stenosis could occur in case of true laryngeal paralysis. But it must be remembered that bilateral laryngeal paralysis usually occasions such a severe degree of dyspnea that tracheotomy is required, and unfortunately, as first pointed out by myself,[3] tracheotomy is usually performed too high, hence a paralytic stenosis is usually followed by a cicatricial stenosis due to inflammatory reaction, perichondritis, chondral necrosis, division of the cricoid cartilage, etc.[4] The latter error is little short of a calamity. Not infrequently, the tracheotomy is in reality a laryngotomy

3. Jackson, Chevalier: Binnie's Regional Surgery, Philadelphia, P. Blakiston's Son & Co., 1915, pp. 401-473.

4. Jackson, Chevalier: High Tracheotomy and Other Errors the Chief Causes of Chronic Laryngeal Stenosis, Surg., Gynec. & Obst. **32**:392 (May) 1921.

and the tracheotomic cannula is actually inserted through the larynx.[4] In many cases of laryngeal stenosis that have come to the Bronchoscopic Clinic, the cannula could be seen, by mirror laryngoscopy, lying between the cords, in a few even above the cords.[4] My only concern with these matters here is to state that while the new operation of ventriculocordectomy may secure a good result in a few such cases the success that I have obtained in seven cases in which there was no stenosis, save that due to the cord and its support, has led me to the decision to apply the operation only in those cases of laryngeal paralysis in which a full-sized bronchoscope can be passed readily through the larynx and down to the carina. If future operators will follow this test in the selection of the cases and follow my technic before attempting deviations therefrom, I feel sure they will get the same satisfactory results. In the selection of cases, naturally the recent cases, having some hope of recovery of laryngeal motility, would be excluded. Patients with only a moderate degree of dyspnea because the paralysis is monolateral in most cases had best wait the possible involvement of the other cord. During the waiting period, they should, of course, be in close touch with a tracheotomist for the emergency.

The usually moderate degree of dyspnea when the cords have assumed the cadaveric position of complete paralysis usually does not call for relief of laryngeal stenosis, unless it is of a cicatricial type due to errors in tracheotomy or its after-cure. Patients in whom but one cord at a time has been paralyzed and has assumed the cadaveric position present themselves with a bilateral cadaveric cordal position without ever having had a tracheotomy. In such cases, if the area of the glottis is insufficient, it may be increased by ventriculocordectomy on one or both sides. The operation is particularly adapted to the cases of laryngeal abductor paralysis associated with goiter or following goiter operations, because these patients have usually a long life expectancy. The same is true of cases resulting from benign neoplasms. In tabes and disseminated sclerosis, the expectancy may or may not be so long, according to the stage of the disease at which the paralysis appears in the bilateral form. Decision as to whether or not operation is worth while in such cases must rest upon this and upon the patient's feeling in the matter after the situation is stated to him. Ventriculocordectomy has the advantage over all other operations that relatively it is quite a minor one, with no prolonged after-treatment, such as is required by laryngostomy, hence it would seem well worth while in those early-discovered cases of tabes and disseminated sclerosis in which the laryngeal paralysis is several years in advance of the serious stages of the disease. In cases of aneurysm the same principles apply. In tumors and other intracranial lesions of grave prognosis, of course, no operation for decannulation is worth while.

CONTRAINDICATIONS

Recent onset of the paralysis is a contraindication. Until a year has elapsed we cannot be sure that at least a degree of motility will not reappear. Such recovery is rare after six months and probably never occurs in cases in which there is no sign of returning motility after the lapse of a year. The desirability of waiting applies to adults and, with even more force, to children. In the latter, I believe it justifiable to wait a year and a half, or even two years. If the tracheotomy has been done sufficiently low (below the second ring) and a daily toilet of the wound is carried out, there will be nothing lost by so long a wait. If the tracheotomy has been too high, as is almost always the case,[4] a second tracheotomy should be performed at the proper place and the fistula of the faulty high tracheotomy allowed to heal. Then there will be nothing lost by a wait of two years. Most of the spontaneous recoveries have been in children. George L. Richards reports an especially interesting case of this kind.[5] I have incomplete notes of eleven such cases that have come to the Bronchoscopic Clinic. Of these eight were congenital. Of the latter, four were due to enlarged thymus gland, congenital goiter and mediastinal conditions. In the thymic cases recovery followed diminution of the bulk of the gland by roentgen-ray therapy. One case was due to unknown causes. The other three I thought were due to injury of the recurrent laryngeal nerves during instrumental delivery. Two of these patients recovered cordal movement some months after tracheotomy.

CASES IN WHICH THE CRICOID HAS BEEN DIVIDED

It is a great misfortune that tracheotomy is almost always badly performed. One of the most frequent errors is the division of the cricoid cartilage.[4] This altogether unnecessary and calamitous fault cannot be too strongly or too frequently condemned. The other cases in which the cricoid cartilage has been cut are those that reached the Bronchoscopic Clinic after an attempt at thyrotomy had been made elsewhere to relieve the stenosis. In these, also, cutting of the cricoid was a mistake. The cricoid is the only complete ring in the air passage, and it is like the steel-tube casing in a tunnel in maintaining the full extent of all transverse diameters. When it is divided, and especially when necrosis has shortened its perimeter, diminution of the lumen is inevitable, not only from the concentric pressure of the surrounding tissues, but even more from the contraction of the internal and external cicatrices that have resulted from the faulty surgery.

5. Richards, G. L.: J. Laryngol., Rhinol. & Otol., October, 1906.

PRELIMINARY EXCLUSION OF CURABLE SYPHILIS

This is not required in two classes of cases:

1. Those in which there is a cadaveric position of the cords. In such cases resumption of motility has never occurred in my experience. The cadaveric position in most cases gives air enough so that relief of stenosis is not often imperatively demanded unless cicatricial stenosis has been added with high tracheotomy.

2. Those in which there is an obvious peripheral lesion, such as goiter or other tumor, or in which there is a history of onset after a cervical operation. In all other cases, notwithstanding negative histories and negative Wassermann tests, a thorough course of yellow mercurous iodid of two months' duration should precede decision to operate, the patient being kept "saturated" just under the point of ptyalism. In cases in which there is no laryngeal inflammation there is not the contraindication to potassium iodid that usually exists in laryngeal lesions; and there is a clear indication for its administration in addition to, but not to the exclusion of, mercury.

ANATOMIC STRUCTURES SACRIFICED IN VENTRICULOCORDECTOMY

Although very important to a normal larynx, these are of little importance in the hopelessly paralyzed larynx. They may be considered under two heads, namely, the cord and the supporting tissue of the cord (Fig. 4). The cord proper, which consists of elastic tissue, is by its vibration the chief factor in normal phonation. The loss of one cord in monolateral ventriculocordectomy was followed by huskiness but not complete aphonia, even temporarily, except in one patient that quickly recovered a husky voice. In two cases, the monolateral operation gave the patient almost sufficient airway; but for greater comfort and to allow a margin of safety during any future intercurrent acute laryngitis, the other side was also operated on. In all cases, the operation was performed first on one side, then, after healing, on the other. The most important element in the supporting tissue of the cord is the thyro-arytenoid muscle. As this muscle is, in the normal larynx, of use only as a tensor or relaxor, or, as I have thought, a nodal regulator of tension, its function concerns not so much the mere production of sound as the refinements of pitch and quality of tone. Furthermore, when we consider that it is usually paralyzed when we have a paralysis of the crico-arytenoideus posticus, the usefulness of the thyro-arytenoideus narrows down to the support its bulk affords for the cord; and as this bulk is the chief element in protruding the cord into the airway of the larynx, it becomes an element in the obstruction. When the completely paralyzed state of tonal deficiency, known as a cadaveric paralysis, is reached, its bulk is probably more or less diminished by atrophy; but these cadaveric cases are not the

cases in which ventriculocordectomy is called for. The other muscular structures in the operated region, the cricothyroideus and the crico-arytenoideus lateralis, are located so far externally and are so protected by the cartilages that with a little care and the use of the forceps as shown in Figure 5 they are unharmed in the operation. It has

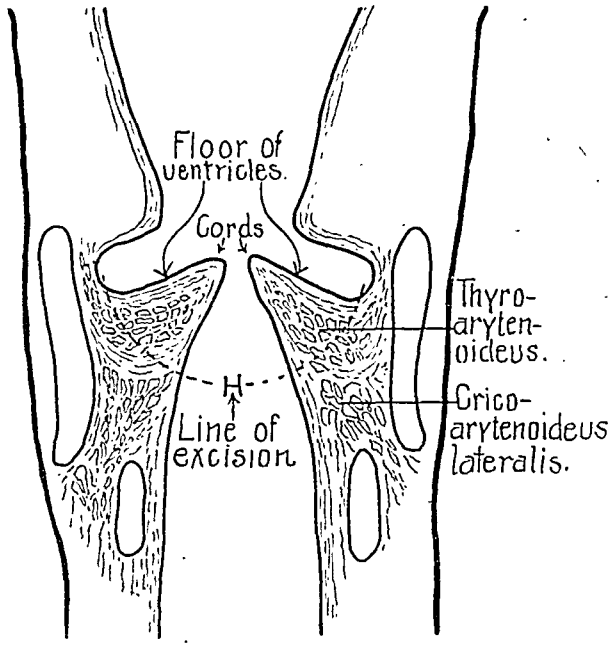

Fig. 4.—Schematic drawing of coronal section of the larynx showing the tissues removed in ventriculocordectomy.

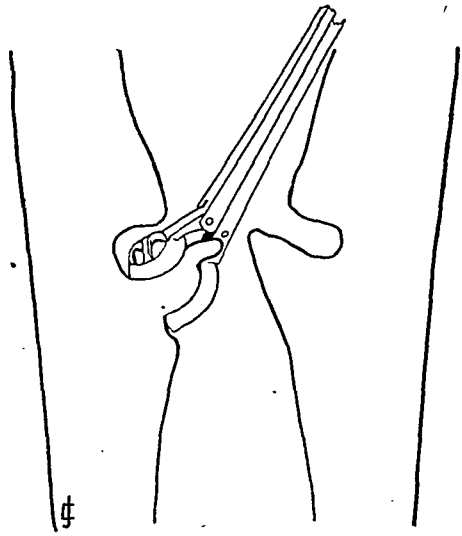

Fig. 5.—Technic of ventriculocordectomy: the ventricular band is elevated and the forceps are applied beneath it to the cord and the entire ventricular floor anterior to the vocal process and antero-external surface of the arytenoid; the tissues are excised at one clip.

seemed to me quite essential that they be left intact, and especially is this true of the cricothyroideus as it is innervated by the superior laryngeal, and hence its motility is unimpaired. With the cords gone, the importance of its functional activity might be questioned if it were not for the fact that in spite of an undoubted stenotic recurrent paralysis of long standing the tissues remaining in the larynx after ventriculocordectomy do show a certain amount of movement on "phonation" or attempts thereat, and the value of the postoperative vocal results seems to be more or less proportionate to the degree of movement. While this movement cannot be clearly demonstrated to be due to the activity of the cricothyroideus, this muscle can be distinctly felt to swell during forcible efforts at phonation; and, moreover, it is logical to preserve every unparalyzed muscle, regardless of the more or less theoretical nature of its function in the normal larynx. For these reasons also it has seemed to me that the crico-arytenoideus lateralis had better not be injured, notwithstanding the fact that, on theoretical grounds, it might be argued that as it is the unopposed action of this muscle that causes the stenosis when its antagonist is paralyzed there would be the same advantage in destroying it as accrues from the cadaveric state of the cord when the paralysis has reached the complete stage. Moreover, it has seemed to me, as elsewhere herein mentioned, that the resiliency of the scar tissue at the site of the excised cordal tissues furnished the reciprocal return after relaxation of the tonic contraction of the crico-arytenoideus lateralis (Fig. 3). One cannot close a shut door. The glottis remaining closed gives little work for the lateralis to do; but if a springlike action of the scar tissue tends to pull the glottis open, as I believe it does, the crico-arytenoideus lateralis has work to do that keeps it from atrophy; and the hundreds of pulls daily drag out, in time, an adventitious cord.

TECHNIC

No anesthetic, general or local, was used in children. In adults cocain was painted on with a swab and a sedative or morphin (¼ grain [0.016 gm.]) was given, hypodermically, an hour before operation.

The larynx was exposed with the direct laryngoscope and through it the punch forceps were inserted. The ventricular band was elevated and the forceps applied as shown in Figure 5. Thus the floor of the ventricle and part of the mucosa of its outer wall were removed at one clip. A clean cut is necessary. The tissues must not be hacked. In some cases the ventricular bands were in tight opposition, so that the forceps were insinuated between them before expanding the jaws. Great care should be taken to avoid getting too far outward between the thyroid and cricoid cartilages lest the crico-arytenoideus lateralis be injured. With the forceps used this accident is easily avoided. Great

care should also be taken not to excise any part of the arytenoid cartilage. The clipping off at the extreme tip of the vocal process of the arytenoid was necessary in some of the cases because of the shortness of the cord; but the excision of more than this is unnecessary and should be avoided. It may not be amiss here to state that, judging from experience in post-graduate teaching at the Bronchoscopic Clinic, few laryngologists seem to realize how far the vocal process of the arytenoid projects forward toward the anterior commissure.

The technic is so simple in theory that it can be understood from the illustrations (Figs. 4, 5 and 6). To perform the operation, however, requires education of the eye and the fingers in endoscopic technic. Of course, the excision of the cord and the ventricular floor can be done by laryngofissure; but here we have, though not a serious operation, yet one that will appear much more formidable to the patient. I have always found patients glad that it is "unnecessary to go in through

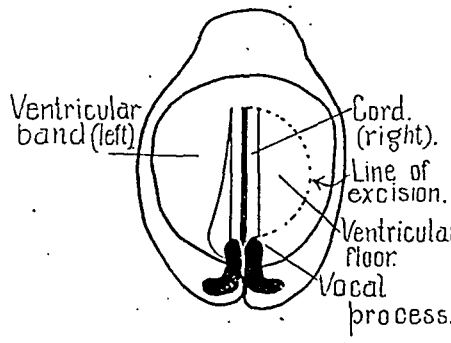

Fig. 6.—Schematic drawing of tissues removed in ventriculocordectomy, as could be seen through the direct laryngoscope (recumbent position) if the ventricular band did not obscure the view of the ventricular floor. The removal is in rounded form and anterior to the vocal process. After healing of one side, the other side is similarly operated on.

the neck." The assurance of an operation through the mouth, one that is no more disagreeable than having a tooth filled and one that will not require more than a minute, appeals strongly to the patient. Facility in direct laryngeal operating will enable the utmost accuracy of excision.

No after-treatment is necessary. The surface of the wound is covered with an exudate under which healing by granulation progresses. In one case a granuloma appeared at the site of the wound. It was excised lest it later lessen the lumen of the airway. In two cases there was a slight degree of perichondritis after the excision of the second cord and ventricular floor; but it subsided spontaneously in about a month. In one case the lumen of the airway was not quite sufficient; and prolonged treatment with the McKee divulsor was necessary to

increase it. Bouginage can be used for this purpose after ventriculocordectomy, though it or any other form of dilatation is useless before removal of the obstructive cord and its supporting tissues.

THE DURATION OF THE OPERATION AND AFTER-CARE

The duration of the operation when performed endoscopically, on one side only, was never more than one minute, not counting the time required to paint on the cocain solution. The healing has not required more than three weeks in most cases, and in some cases healing was completed in ten days. In some cases recurrent formation of granulomas had to be combated by excision and delayed for a number of months the operation on the other side.

Decannulation is accomplished by the author's system of corking. When the laryngeal airway seems ample, the partial corking of the cannula is commenced. Ordinary corks, either of bark or rubber, are

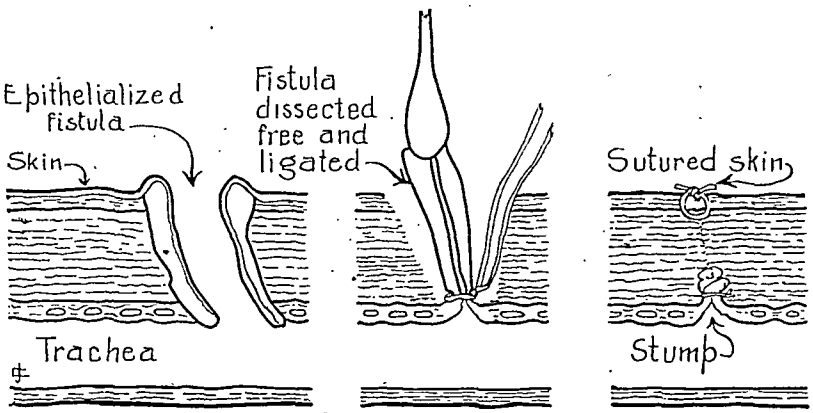

Fig. 7.—Plastic operation for closing a tracheotomic fistula.

friable and involve risk of aspiration of fragments. A chemist's cork of good rubber, with a central perforation, is sometimes obtainable to fit an adult cannula; but for general use it is better to get what is known to the rubber trade as "pure cord" of suitable diameter, and from this to grind a proper cork on an emery wheel.[6] One side is ground off flat or grooved to permit leakage of air past the cork to the desired degree. At the Bronchoscopic Clinic we usually start with a "half-cork." New corks are then made from time to time with less and less by-passage space until a "whole cork," completely occluding the cannula, can be worn night and day. The cork is worn in the outer cannula and for convenience the cork has a braided silk tether to prevent loss. With a proper cannula there is plenty of room around it in the trachea for the air to pass upward to the larynx without the

6. Jackson, Chevalier: Treatment of Laryngeal Stenosis by Corking the Tracheotomic Cannula, Laryngoscope **29**:1 (Jan.) 1919.

very objectionable fenestrum. The cannula should not be abandoned until after the patient has been able to wear a "full-cork" night and day for a month. Parenthetically, it may be stated the cork is frequently removed for cleansing and the cannula is replaced by its sterilized duplicate daily. The daily toilet of a tracheotomic cannulated fistula is necessary not only for decent cleanliness, but to prevent irritation and inflammatory thickening with inevitable subsequent cicatricial contraction.

PLASTIC CLOSURE OF THE TRACHEOTOMIC FISTULA

If in six months after decannulation, a fistula remains open and the laryngeal lumen is ample, the fistula may be closed by a plastic operation if the patient so desires. After having worn a tracheotomic cannula for a long time the fistula has a firm cicatricial wall with more or less epithelialized surfaces that will not unite, though contraction of the cicatricial walls usually narrows the lumen until the leakage of air and secretions is trivial. Of the many plans of closure none is so simple and effective as that shown in Figure 7. The fistula is dissected free in tube-like form, drawn out, ligated close to the trachea and cut off to a very short stump, which may be touched with pure phenol (carbolic acid). The soft tissues are then drawn together over the stump with deep sutures and the skin wound is closed by sutures without drainage. Primary union is to be expected and only rarely will the wound open and leakage be reestablished. In the latter case reoperation will be effective.

MORTALITY AND RESULTS

In the series of eighteen cases of bilateral recurrent paralysis in which I performed an endoscopic ventriculocordectomy there was no operative mortality and no later mortality. All patients were ultimately relieved of dyspnea. The vocal, protective and expectorative results are considered above.

REPORT OF CASES

In eleven of the eighteen cases in which I did ventriculocordectomy the operation failed to restore an ample lumen and the operation had to be supplemented by other means—bouginage, laryngostomy or intubation—because the paralytic stenosis had been complicated by a cicatricial stenosis due to high tracheotomy, faulty after-care, improperly shaped or fenestrated cannulas, etc. It would be misleading to expect these as failures of ventriculocordectomy, inasmuch as they were, as I learned, not the kind of case in which to expect a cure by this operation alone. In view of this, and considering the space saved, it seems best for illustrative purposes to report here only those cases to which the operation was suitable.

CASE 1.—*Bilateral Recurrent Paralysis Due to Goiter.*—A woman, aged 31, from whom a goiter had been removed two years prior to admission, and who was said to have been in imminent danger of asphyxia on the operating table, required tracheotomy the night after operation to relieve severe dyspnea. No laryngoscopic examination had been made before operation. On admission to the Bronchoscopic Clinic for decannulation, mirror examination revealed not the slightest abduction on inspiration; but there was a slight flutter of the arytenoids on attempted phonation. This I thought might be due to retention of some degree of innervation of the crico-arytenoideus lateralis and thyro-arytenoideus. I therefore advised waiting in hope of resumption of function of the crico-arytenoideus posticus. After a year, the conditions in the larynx were precisely the same, the flutter being of about the same degree; and there seemed no progress toward complete or cadaveric paralysis. The cricothyroideus could be felt contracting on forced attempts at phonation. Bronchoscopy revealed no obstruction other than the paralyzed cords. Ventriculocordectomy was performed, first on one side and then on the other, after three weeks' interval. The patient was decannulated six months later and a plastic operation was performed to close the fistula. The voice was a loud "stage whisper." There was no return of the stenosis one year after operation; but the voice had not improved beyond the "stage whisper." The cricothyroideus could be felt powerfully contracting on attempted phonation.

CASE 2.—*Bilateral Recurrent Paralysis Due to Goiter.*—A woman, aged 32, in whom removal of a goiter two years before admission had failed to restore movement to the cords, was sent in for decannulation. Mirror examination showed the true cords almost motionless in the median line. Phonation was excellent, but seemed to be deepened in pitch by the failure of perfect tension and approximation, one being slightly above the other. The ventricular bands had a degree of movement which led me to advise waiting at least a year in the hope that abduction of the cords might in some degree return. At the end of fourteen months, not the slightest improvement of motility was noticeable in the true cords; the movement in the ventricular bands was, if anything, rather less. Bronchoscopy excluded the possibility of cicatricial stenosis. Ventriculocordectomy enabled me to decannulate this patient with a good vocal result and a cure of the stenosis that was still satisfactory to the patient when she was last seen one year after operation. A pair of adventitious bands, with fairly good movements, had appeared at about the level of the original cords. The laryngeal function in cough and expectoration seemed good during an intercurrent acute tracheobronchitis.

CASE 3.—*Bilateral Abductor Laryngeal Paralysis Due to Goiter.*—A woman, aged 42, had suffered from severe dyspnea that had come on suddenly eighteen months before. Tracheotomy had been performed by a general surgeon at that time, and shortly thereafter he performed a thyroidectomy for a large retrotracheal goiter. Since the laryngeal stenosis continued, the patient was referred to me for decannulation. Mirror examination showed both cords incapable of abduction, but remaining separated about 1 mm. On phonation they would approximate and emit a fairly loud sound of rather deep register and rough quality. A 9-mm. bronchoscope was passed through the larynx and down to the tracheal bifurcation without encountering any abnormal resistance. Ventriculocordectomy was performed on the right side through the direct laryngoscope after applying to the larynx one swab moistened with 10 per cent. cocain solution. Two months later, the same operation was performed on the left side. The first operation enabled the patient to wear a "half-cork;" the

second operation, after the lapse of four weeks, allowed the patient to wear the tracheotomic cannula completely corked when sleeping or when going about slowly. At the end of one year, the narrowest part of the laryngeal airway was even wider than when the patient was discharged, and she had a voice quite as loud as before the laryngeal operation. The pitch was much deeper. Phonation was with the ventricular bands. When last seen, five years later, the laryngeal stenosis had not recurred. The cannula had been abandoned. A slight fistula remained, but the patient declined to have me perform a plastic operation for closure.

CASE 4.—*Paralytic Laryngeal Stenosis, Cause Unknown.*—A man, aged 38, was admitted suffering with extreme dyspnea. All of his time and attention had to be given to voluntarily controlled breathing, so that he could neither eat nor sleep. Any attempt at deep or quick inspiration prevented any air from entering. Low tracheotomy was performed by me immediately. The cords were in close approximation. Careful study and observation of this case by internists and roentgenologists, extending over two years' time, failed to disclose any cause for the abductor paralysis. No sign or symptom of any peripheral or central lesion could be discovered. Ventriculocordectomy was performed on one side, then on the other, three months later. Recurrent formation of granulomas delayed the performance of the second operation. A good, but very deep, voice resulted. Phonation was with the ventricular bands, the movement on phonation being a narrowing of the whole upper laryngeal orifice with close approximation of the free edges of the ventricular bands. When about to speak, the patient always dropped the head and neck slightly downward to one side, and the muscles of the whole neck seemed to be contracted. At the end of two years after operation, there was no return of the stenosis and the cause of the bilateral paralysis still remained undetermined.

CASE 5.—*Bilateral Abductor Paralysis Probably Due to Contraction of Cervical Scars.*—A man, aged 28, had had a tracheotomy performed fifteen months before admission. Masses of tuberculous (?) glands had been removed from the neck two years before the dyspnea developed. The lungs showed no signs of active tuberculosis. Mirror laryngoscopy revealed a separation of the cords of about 2 mm. on quiet respiration; on phonation they moved slightly toward the median line, but did not quite approximate. The voice was rough and deep. There was no infiltration anywhere in the larynx and an adult bronchoscope passed freely to the bifurcation. The trachea and bronchi were normal. Ventriculocordectomy performed on one side at a time enabled the patient to dispense with the tracheotomic cannula. One year after operation, the voice was loud, but rough and high pitched. Adventitious cords developed on both sides, which showed a degree of motility; but from laryngeal examination during phonation, the sound seemed to be produced by the ventricular bands.

CASE 6.—*Congenital Laryngeal Stridor Due to Paralysis.*—A baby, admitted as a "blue baby," three days after forceps delivery, was examined in consultation. I observed that the intense dyspnea was clearly obstructive in character. The direct laryngoscope revealed close contact of the cords. Respiration ceased. The bronchoscope, which was in readiness, was promptly inserted and respiration was reestablished by a few compressions of the chest with the hand. I then performed a tracheotomy with the bronchoscope still in situ. As I had previously tracheotomized a number of patients with congenital laryngeal stridor due to paralysis from the trauma of forceps delivery, and they had all completely recovered, I was surprised in this case to find at the end

of a year and a half that the child could not be decannulated, the direct laryngoscopic appearances being about the same as when first examined. With a four weeks' interval between, I performed a ventriculocordectomy on each side. When seen one year later the child could cry almost as loudly as any child of its age. Direct laryngoscopy revealed a pair of adventitious cords closely resembling normal cords in color, but with a less range of motion. When the laryngoscope was introduced, the laryngeal orifice was closed tightly by the ventricular bands. When a deep inspiration took place, with the tracheotomic cannula corked, the ventricular bands would separate and reveal the adventitious cords. The mechanism of the cordal movement could not be determined. On theoretical grounds, I assumed that it was the result of activity of the crico-arytenoideus lateralis opposed by the resiliency of the scar tissue at the site of the operation, though the patient being a child I could not be sure that some degree of movement had not returned in the crico-arytenoideus posticus. A movement of the thyroid and cricoid cartilages in relation to each other may have contributed, as may also contraction of the arytenoideus.

CASE 7.—*Tabetic Bilateral Abductor Paralysis.*—A man, aged 56, after exposure overnight in the rain during alcoholic stupor, six months before admission, discovered that he was very hoarse. The night before admission he awoke struggling for air. He thought he would "choke to death" before morning. He was carried into the hospital sitting upright on the gripped hands and wrists of two men, keeping himself upright by holding to their shoulders with his hands. He had fallen from weakness, becoming "blind" and almost unconscious, on attempting to walk. He was blue-black in color and the stridor could be heard all along the corridor. He was carried to the operating room, repeating over and over, "Don't lay me down; I'll choke." For temporary relief I inserted a bronchoscope while he was in the sitting position to avoid laying him down. To attempt even local anesthesia would have been a fatal mistake and would have been quite unnecessary. The bronchoscope completely relieved the dyspnea and went deeply into the trachea without resistance. It was noted that the larynx was engorged with cyanotic blood; the cords were in contact, but not otherwise abnormal. I then performed a low tracheotomy with the bronchoscope in situ. The next day the patient was examined thoroughly; the station, gait and reflexes pointed clearly to a tabes that evidently had antedated the paralysis of the first cord, which probably was the cause of the hoarseness noticed six months previously. The Wassermann examination was negative. Spinal fluid Wassermann examinations were not then in vogue. Rest, mercurial iodids, good food and abstention from alcohol in six months had so greatly improved all the tabetic symptoms that only careful examination could demonstrate them. The patient was very desirous of getting rid of the cannula. He stated that even if he had only a few years to live he did not "want to live this way." At the end of a year after the tracheotomy, there being no improvement in the laryngeal stenosis and no exacerbation of the tabetic symptoms, I consented to perform a ventriculocordectomy. One side was operated on at a time, three weeks intervening between the two. During an attack of infective epidemic tracheobronchitis the patient could cough and expectorate as well as before operation. The voice, at first a whisper, became a "stage whisper" in a few months. When last seen, about a year after operation, he was able to phonate so as to be heard in the adjoining room. The tabes had progressed somewhat in spite of constant treatment.

CONCLUSIONS

1. In ventriculocordectomy I believe we have a simple endoscopic operation that can be performed under local anesthesia and that will cure almost every patient with laryngeal stenosis that is due solely to abductor paralysis, if the case is not complicated by a faulty tracheotomy.

2. Ventriculocordectomy is indicated in cases of stenosis resulting from a hopelessly paralyzed larynx.

3. This or any other form of operative clearing of the airway is contraindicated in the first six months of abductor laryngeal paralysis. In most cases it is wise to wait a year.

4. The best means of affording relief of dyspnea and safety of the patient during this waiting period is by prompt *low* tracheotomy. High tracheotomy is the cause of more cases of cicatricial laryngeal stenosis than any other one thing. With a low tracheotomy, a pair of proper cannulas and a daily toilet of the fistula, there is nothing lost by waiting.

5. Out of eighteen cases in which ventriculocordectomy was performed the seven that were uncomplicated by cicatricial stenosis were afforded satisfactory relief of dyspnea by this procedure alone. One required divulsion in addition.

6. The chief functions of the larynx are phonetic, protective and expectorative. Considered in the light of the degree of preservation of these functions, ventriculocordectomy not only surpasses any previously devised operation, but is simply ideal for those cases in which neural and muscular atrophy has rendered resumption of normal cordal motility hopeless by either spontaneous recovery or neuroplastic surgery.

128 South Tenth Street.

PAPILLOMA OF THE LARYNX IN CHILDREN

A REPORT OF ELEVEN CASES *

S. J. CROWE, M.D., AND M. L. BREITSTEIN, M.D.
BALTIMORE

Virchow,[1] in 1863, and later Stoerk,[2] in 1880, classified laryngeal papilloma as a benign tumor of connective tissue origin and suggested that the generic name for the tumor should be "fibroma," with the term "papillary" used as a descriptive adjective. This led to a long controversy as to whether there should be any pathologic distinction between a true papilloma of connective tissue origin and a papillary hypertrophy of epithelial origin.

It may be difficult to distinguish between these conditions histologically; but clinically, the difference is very striking. Papillary hypertrophy is commonly seen in adults; is almost invariably located in the posterior half of the larynx, and is the result of a chronic irritation of the mucous membrane due to syphilis, tuberculosis or a long-standing catarrhal inflammation. The true papilloma, on the other hand, is most frequently found in young children and is sometimes congenital. The growth may arise from the vocal cords or from any part of the mucous membrane of the epiglottis, larynx or trachea. Its most striking characteristic is the rapid recurrence after removal and the tendency to transplant itself to any adjoining area of mucous membrane that may be injured during operation.

Microscopically, the papilloma consists of a branched connective tissue framework, which is well developed in the flatter types but less marked in the more elongated types of the growth. This connective tissue framework contains arteries and veins, and, according to Harmon Smith, nerve fibers. The outer layers of epithelium vary in type and thickness. Sometimes, there are many layers of squamous cells, with a typical horny layer on the surface, while in other specimens, the epithelium is columnar. The size and arrangement of the cells, the appearance of the nuclei, the presence of a basement membrane, and the absence of invasion into the central connective tissue framework all differentiate the benign from the malignant papilloma. These changes should be particularly looked for at the point of attachment of the tumor.

---

* From the Surgical Clinic of the Johns Hopkins Hospital.

1. Virchow: Die krankhaften Geschwülste, Berlin **1**:1863. Spec. Path. u. Therap., Nothnagel **13**:234.

2. Stoerk, Carl: Klinik der Krankheiten des Kehlkopfes, der Nase und des Rachens, Stuttgart, 1880, p. 396.

Schrötter[3] offers an interesting explanation for the retrogressive changes that may account for the spontaneous disappearance of a papilloma. He believes that the location of the tumor and its mobility result in an injury to the delicate vessels that supply it. The injury may be in the form of a ruptured vessel with an extravasation of blood throughout the connective tissue framework, or a twisted pedicle that leads to thrombosis. He describes specimens in which there are accumulations of yellowish brown pigment and isolated fat droplets.

Unlike the benign papillary tumor of the larynx in adults, this type of growth in children is very difficult to cure. The difficulties of treatment by operative removal are due to: (1) the small lumen of the larynx and trachea in children; (2) the tendency of the growth to recur locally after excision and, in addition, to transplant itself to adjoining areas of mucous membrane that were free from growth before the operation, and (3) the necessity for tracheotomy in nearly every case. As a rule, the tracheal tube must remain in place for months or years and this may further complicate the cure of these cases, as will be more fully discussed later.

Fortunately, laryngeal papilloma is not common in children; but unless it is recognized early and treated intelligently and conservatively, it is certain to result either in death from suffocation or in a fibrous stenosis of the larynx. The rarity of the affection is shown by the following statistics: Rosenberg, in 1896, from Fränkel's clinic in Berlin, reported sixteen cases of papilloma of the larynx that had been observed in a series of 5,808 children under 13 years of age. Schrötter found only ten cases among 7,324 children under 10 years of age. Only twenty-three cases were seen in Chiari's[4] clinic in Vienna during the twenty years from 1892 to 1912. The records of the Massachusetts General Hospital[5] indicate that the incidence of papilloma of the larynx is approximately 1:1,000 in children under 14 years of age. Harmon Smith,[6] in 1914, reported the eight cases that had been seen at the Manhattan Eye, Ear and Throat Hospital during a period of fifteen years. At the Johns Hopkins Hospital, we have seen, since 1912, only eleven cases. A review of the literature indicates that the mortality rate of papilloma of the larynx in children under 5 years of age is equal to, if not greater than, that of carcinoma of the larynx in adults.

---

3. Schrötter, L.: Vorlesungen über die Krankheiten des Kehlkopfes, Vienna, W. Braumüller, 1892, p. 269.

4. Chiari, O.: Papillome im Larynx der Kinder, Wien. med. Wchnschr. **63**:2468-2475, 1913.

5. Clark, J. P.: Papilloma of the Larynx in Children, Tr. Am. Laryn. Assn. **27**:185-199, 1905.

6. Smith, Harmon: Papilloma of the Larynx, J. A. M. A. **63**:2207-2211 (Dec. 19) 1914.

The papilloma, while rare, is still the most common type of new growth in the larynx of children. This growth may appear at any age, and according to Gerhardt [7] approximately one fifth of the cases in young children are congenital. Boys are more frequently affected than girls. In our series, every case was in a boy.

Nothing definite is known concerning the etiology. The infectious diseases that are associated with a lesion on the mucous membrane of the upper air passage, such as measles, chickenpox, scarlet fever and diphtheria, and the diseases that cause excessive coughing, are all regarded as etiologic factors. The general hygienic surroundings of the child may be of etiologic importance. All of our cases were from the class of people that apply to the free dispensary for treatment. Children of this class are exposed to dust, extremes of heat and cold, are improperly fed and are certainly more prone to chronic catarrhal conditions of the upper air passage than are the children that receive better care. It has never been proved that syphilis, tuberculosis or gonorrhea are responsible for the presence of these growths in newborn infants.

Possibly the best method of gaining a clear idea of the seriousness of this condition in children and the successes and failures of the various methods of treatment is to relate in some detail the clinical experience of laryngologists in this country and in Europe.

Elterich [8] reports the case of a child, aged 2 years, with complete aphonia, and a history of hoarseness and attacks of dyspnea that were first noticed at 7 months of age. The parents would not consent to an operation of any kind; and a few days later the child died of asphyxia before a physician could reach the home. The larynx and upper part of the trachea were opened and found to be almost entirely occluded with papillomatous growths.

Broca and Roland [9] conclude that no method of treatment is satisfactory in all cases. The papillomas of the larynx come and go in the arbitrary and mysterious manner of warts on the skin. They sprout as if grown from seed sown by the primary source and behave in the larynx in much the same way as do papillomas in the bladder. Removal of the growths through the mouth is preferable to any other method of treatment; but, as a rule, the operation must be repeated during months or even years. Even if the growth is cured by tracheotomy, thyrotomy or laryngostomy, a fibrous stricture of the larynx often necessitates a permanent tracheotomy or, at least, a long and tedious

7. Gerhardt: Kehlkopfgeschwülste, Spec. Path. u. Therap., Nothnagel **13**:16.
8. Elterich, T. J.: Papillomata of the Larynx in an Infant, Arch. Pediat. **21**:840-843, 1904.
9. Broca and Roland: Traitment des papillomes du larynx chez l'enfant, Rev. de chir. **43**:281-301, 1911.

series of treatments in order to reestablish breathing through the normal passages.

In addition to the danger of suffocation from the growth, there is danger of a suddenly fatal inhibiting reflex. Broca and Roland quote a case of papilloma of the larynx reported by Boris Frankel, in which a child of 6, with no history of dyspnea, developed symptoms of laryngeal obstruction suddenly during the night and died within a few minutes. They also give the statistics of the forty-eight cases compiled by P. Bruns: More than half the children died before the age of 3, and only five reached the age of 10 without operation.

The spontaneous subsidence of the papilloma may explain the cure in some cases; and the possibility of this justifies expectant treatment for a reasonable time after tracheotomy.

We agree with the following generalizations of Broca and Roland. If a child has dyspnea, a tracheotomy should be performed as soon as the condition is recognized, and should precede all other therapeutic measures. It is of the greatest importance to bear in mind two points: (1) The tracheotomy must always be performed under local anesthesia. (2) The opening in the trachea must be midway between the isthmus of the thyroid and the top of the sterum. The reasons for these two points are fully discussed later.

McCoy [10] reports the case of a boy, aged 5 years, whom he saw in October, 1912. There was a history of increasing hoarseness for two years, and dyspnea for six months.

Oct. 10, 1912, under chloroform anesthesia, a large mass of papilloma was removed with the aid of a direct laryngoscope. The entire larynx was involved, both above and below the cords. The respiration became practically normal after the operation.

October 19, operation was again necessary on account of the rapidly increasing dyspnea. Tracheotomy was performed; and again large masses of papilloma were removed by endolaryngeal methods.

March 17, 1913, the entire larynx was filled with growth. It was decided to try the combination of surgical removal and fulguration. The growths were excised and their point of attachment fulgurated, once each month, from March, 1913, to June, 1914. The tracheal tube which had been worn for fifteen months was removed in June, 1914; and at the time of the last note, four months later, there was considerable hypertrophy of the laryngeal tissues but no recurrence of the papilloma.

This case illustrates the marked tendency of these growths to recur after surgical removal. In general, it is not advisable to use chloroform, when a series of operations is necessary, on account of its

10. McCoy, J. B.: A Case of Multiple Laryngeal Papillomata in a Child Treated by Direct Laryngoplasty and Fulguration, Internat. J. S. 28:116, 1915.

toxic effect; but, in this case, it was the only general anesthetic that would permit the use of the high frequency spark.

Our experience has shown that it is always wise to leave the tracheal tube in place for several months after the papillomas have apparently disappeared. One of our patients (Case 3) died on the train on which he was returning to Baltimore. In this case, the growths had been removed; their points of attachment fulgurated on four occasions, and, finally, the interior of the larynx treated with 100 mg. of radium on two occasions, once for one hour and again for one and one-half hours. On direct inspection, the larynx seemed to be free from growths, and the tracheal tube was removed. Dyspnea came on suddenly, six months later, and the child died before he could reach the hospital. Necropsy demonstrated that the entire larynx was filled with growths.

Harris[11] reports the case of a boy, aged 11, who was suspected of having tuberculosis on account of dyspnea, hoarseness and fever. There was a history of measles and pneumonia; but otherwise he had always been well. The examination of the chest was negative. A papilloma situated below the vocal cords was discovered on direct laryngeal examination. Attempts to remove the tumor endolaryngeally under local anesthesia, and later under ether, were not successful. It was decided to remove the growth by an external operation; but before they were ready to open the trachea, the child stopped breathing and an emergency tracheotomy through the cricothyroid membrane was necessary. Further operation was then abandoned, and the patient was returned to the ward. It was feared that a permanent cicatricial stenosis would result on account of the high tracheotomy. Two months later, however, the edema had subsided and it was found that the growth had disappeared. The tube was removed. The voice became clear and strong, and, at the time of the last note, he was apparently well.

This case emphasizes the danger of giving a general anesthetic to a patient with an obstruction anywhere in the trachea or larynx. The tracheotomy must always be performed under local anesthesia.

Other cases have been reported in which the growth disappeared after a tracheotomy; but, in the great majority of the reports, additional measures have been necessary. The fact should not be ignored, however, that some of these children have been cured by tracheotomy alone; this suggests a safe, simple and conservative form of treatment.

In Sargnon's[12] case, that of a child, aged 5, there was a history of dyspnea for one and one-half years and recently attacks of suffocation.

---

11. Harris, T. J.: A Case of Subglottic Papilloma Cured by Laryngotracheal Fistula, Tr. Am. Laryngol. Assn. **30**:28-31, 1908.

12. Sargnon: Papillomes récidivants du larynx; papillomes intrathoraciques; curettages endoscopiques. Lyon méd. **114**:1003. 1910.

Under general anesthesia, the papillomas were removed through the mouth, on several occasions. After each operation, they recurred rapidly and finally involved the epiglottis and the subglottic area, which were originally free from growth. A tracheotomy tube was then introduced; but in a short time, the papillomas had grown downward into the trachea to such an extent that further measures were necessary. Sargnon repeatedly removed the growths in the trachea, using a local anesthetic and a bronchoscopic tube. After each operation, they recurred and involved the trachea at a lower level. Finally, the left bronchus was involved; and in spite of frequent operations, the child died.

Fortunately, not all cases of papilloma of the larynx exhibit this tendency to spread. Some of the benign papillomas of the urinary bladder in the adult transplant themselves to apparently normal mucous membrane after surgical removal of the original growth, and each operation results in an increase, until finally the bladder is filled with tumor. These bladder papillomas are now cured by fulguration or radium applied through a cystoscope. It was hoped that similar measures would be equally successful in the treatment of laryngeal papilloma.

The local application of radium is perhaps the best method of treatment for a benign papilloma of the larynx in an adult; but in children, both fulguration and radium have so far given disappointing results. It is probable, however, that further experience with the use of radium in these cases will establish a more suitable dosage and method of application than we now possess.

Payson Clark[5] reports fourteen cases from the Massachusetts General Hospital. Of these, nine were in boys and five were in girls. The symptoms dated from birth in one case; and in another, the trouble was first noted when the child was 3 months of age. Of the remainder, five were under 2 years of age. Treatment without previous tracheotomy was attempted in four cases. One of the children died during the operation; one never returned after the first operation; one was cured, and in one, after several successful operations, an emergency tracheotomy was necessary for a sudden attack of dyspnea. Preliminary tracheotomy was performed in each of the remaining ten cases. Of these patients, four died, three of pneumonia and one of suffocation, due to a recurrence of the growth after the condition had been apparently cured and the tube removed. In a later paper, Clark[13] gives the details of some cases that well illustrate the difficulties of treatment.

In Case 9, that of a boy, aged 6 years, who had suffered from hoarseness and dyspnea for one year, tracheotomy, with removal of the papillomas through

13. Clark, J. P.: Papilloma of the Larynx in Children—A Further Consideration of the Subject, Tr. Am. Laryn. Assn. **30**:283-299, 1908.

the mouth, was performed in February, 1901. In October, 1901, the larynx was again filled with growth. Large masses of papilloma were removed. February, 1902, no papilloma was found above the vocal cords; but there was a large mass below the cords. Nothing was done. Frequent examinations during the next two years showed that the growth was slowly diminishing in size. In June, 1905, under ether anesthesia, the remaining growths were removed from the larynx and trachea by means of a Killian tube introduced through the tracheotomy opening. March, 1906, the larynx and trachea were free from growth. The tracheotomy tube was removed, and the tracheal opening closed. Two years later, there was no recurrence.

In Case 10, that of a boy, aged 9 years, with a history of hoarseness for six months and dyspnea for two weeks, tracheotomy was performed in August, 1904; but no growth was removed at this time. In September, 1904, and February, 1905, large masses of papilloma were removed; but they rapidly recurred, and further operation was abandoned. May, 1906, the growths in the larynx had shown no tendency to spread and had not increased in size. Under ether anesthesia, the remaining papillomas were removed. The tube was removed after having been worn for one year and nine months. June, 1907, there had been no recurrence. The vocal cords were normal in appearance and the voice was good.

In Case 14, that of a girl, aged 2 years, with a history of hoarseness and dyspnea, and in whom the larynx was almost filled with papillomas, a tracheotomy was performed in August, 1904. In October, 1904, the growth was thoroughly removed through the mouth. In February, 1905, the larynx was again filled with growth, so it was decided that further operation at that time was not advisable. In September, 1905, papilloma was appearing at the tracheal opening when the tube was removed. No operation was performed. In January, 1906, while changing the tube, the child was nearly asphyxiated, owing to closure of the tracheal opening with papilloma. A portion of the growth was removed. In March, 1907, July, 1907, and February, 1908, it was necessary to remove the growth around the tracheal opening. In April, 1908, the growth had not recurred in the trachea. The tube was removed. In September, 1908, the larynx and trachea were free from growth.

These cases show that a cure may be obtained without recourse to radical surgical operations. Our experience has convinced us that an external operation for papilloma of the larynx in children is never justifiable. The growth may be cured by this method; but a stenosis of the larynx results.

An early tracheotomy is necessary. The growth should be removed through the mouth and under direct vision. A Jackson laryngoscope or a swinging laryngoscopy apparatus may be used. Care must be taken not to injure the surrounding mucous membrane. Even sponging with gauze or cotton will, in some cases, result in a spread of the growth. Actual or chemical cauterization should be avoided; they will not prevent recurrence, and will result in scarring or stricture.

Tracheotomy, removal of the growths when necessary, the careful use of the roentgen ray and radium, general hygienic measures, and, above all things, patience, are the essential features in the therapy of papilloma of the larynx in children.

Harmon Smith[6] reports the case of a boy, aged 3½ years, who had complained of severe attacks of hoarseness and dyspnea for eighteen months and in whom the entire larynx was filled with papillomas.

From July 11 to Sept. 12, 1912, the growths were fulgurated on six occasions under chloroform anesthesia. After each of these treatments, the tumors would disappear but would recur rapidly. September 12, it was decided to make a severe test of this method of treatment. The local reaction, however, was so marked that a tracheotomy was necessary five days later. The larynx was then treated with another series of fulgurations, but with no permanent benefit. Jan. 20, 1913, about 4 a. m., the child pulled out the tracheotomy tube and died from asphyxia before the house surgeon could reach the ward.

We could add an indefinite number of cases from the literature on this subject; but these few illustrate clearly the difficulties encountered in the treatment of this condition.

TRACHEOTOMY IN CHILDREN

The one important method of treatment of papilloma of the larynx is the introduction of a tracheal tube. Before discussing this, however, in relation to the treatment of papilloma of the larynx in children, we will digress from our original topic long enough to point out the dangers and complications that may arise from this apparently simple operation.

Chevalier Jackson[14] has recently called attention very forcibly to the *discouraging end-results* of the tracheotomies that have been successful in their primary object of tiding the patient over a critical period. He states that throughout the period of thirty-four years in which he has been interested in the treatment of chronic laryngeal stenosis, at least five sixths of the total number of his cases of chronic stenosis have been due to faulty tracheotomy or improper postoperative care. This is in marked contrast to the results in his own series in which more than 100 patients were tracheotomized for some acute laryngeal condition without the occurrence of a single case of chronic laryngeal stenosis as an end-result. In other words, if a tracheal tube is properly inserted, it will not only save the patient's life, but will prevent the months or years of tedious and painful treatment that are often necessary in order to remove the tube and reestablish breathing through the larynx.

The main points to bear in mind in order to perform a safe tracheotomy are:

---

14. Jackson, Chevalier: High Tracheotomy and Other Errors, the Chief Causes of Chronic Laryngeal Stenosis, Surg., Gynec. & Obst. **32**:392-398 (May) 1921.

1. A patient with obstructive dyspnea should *never* be given a general anesthesic in order to introduce a tracheal tube. Jackson states that of the thirty surgical textbooks examined in regard to this point, all mentioned general anesthesia, but not one condemned it. A dyspneic patient depends on the aid of his accessory respiratory muscles. When he passes under the influence of a general anesthetic, he loses this accessory aid and suddenly becomes cyanotic or respiration ceases. Infiltration of the skin with a 1:400 solution of procain, to which is added a few drops of epinephrin, will make the operation practically painless. Even when the operation is performed under local anesthesia, we do not think it wise to try to abolish the cough reflex by the administration of narcotics or the intratracheal injection of cocain, as recently recommended by St. Clair Thomson.[15]

2. A *low tracheotomy* is the operation of choice; and in children, it is the only location in which a tracheal tube should be inserted. There are many reasons for this:

(*a*) Division of the cricoid cartilage removes the only ring support of the larynx, and also interferes with the subsequent development of the larynx. Perichondritis due to secondary infection is more likely to occur after division of the cricoid than it is when the tracheal rings are divided.

(*b*) The subglottic space is the narrowest portion of the larynx and the inevitable secondary infection and granulations that result from the wearing of a tube over a long period results in stenosis. Even if the cricoid is not divided and the opening is made through the first and second rings of the trachea, the tube is still too near the subglottic space; and fibrous laryngeal stenosis is likely to result.

(*c*) The thyroid isthmus in a child lies much higher than in an adult; and, in addition, it is firmly adherent to the trachea. This offers another complication to high tracheotomy, especially if the operation is performed rapidly.

(*d*) In performing a low tracheotomy, care must be taken not to make the opening in the trachea too low. If a roll is placed under the patient's shoulders and the head retracted, about 1 inch (2.5 cm.) of the thoracic trachea is drawn upward into the neck. It is easy under these conditions to insert the tube so low that when the patient assumes the upright position it will be found that the tracheal opening is below the sternal notch. This results in a poorly fitting tube, subcutaneous emphysema, and often a mediastinal infection. If properly performed, however, a low tracheotomy is as quickly and as safely performed as the high operation.

---

15. Thomson, St. Clair: Tranquil Tracheotomy by Injecting Cocain Within the Windpipe, J. A. M. A. **73**:1032-1033 (Oct. 4) 1919.

Neumann[16] reports 133 cases of high tracheotomy, in 9 per cent. of which a laryngeal stenosis resulted, and 292 cases of low tracheotomy in only 1 per cent. of which a stenosis developed.

3. If the mechanical principles are ignored and the after-care of the wound and tube is neglected, a stricture is likely to result even with a low tracheotomy. The cartilaginous rings do not extend around the entire circumference of the trachea; the posterior wall has no rigid support. When the cartilages are divided anteriorly and spread apart for the introduction of a tube, the posterior wall bows forward and materially reduces the lumen of the trachea. If the tube does not have the proper curve, or if it contains the utterly useless fenestra in its posterior wall, an ulcer may form on the posterior wall of the trachea and cause a stricture.

It is not uncommon to have serious complications result from a badly fitted tube. Roger[17] reported twenty-two cases in which necropsy disclosed ulcerations of the tracheal wall due to pressure of the tube. The decubitus was on the anterior wall, opposite the tip of the tube in sixteen, on both the anterior and posterior wall in four, and on the posterior wall in two. Taute[18] collected the reports of seventy-two cases of fatal hemorrhage after tracheotomy. The bleeding was due to the erosion of the tracheal wall, and secondarily of one of the large vessels by the constant pressure of the end of the tube. Of these seventy-two cases, the innominate artery was eroded in fifty-five, the common carotid in four, the inferior thyroid artery in three, and the innominate and inferior thyroid veins in two.

4. Subcutaneous emphysema is an occasional early complication of a tracheotomy. It is due to certain conditions:

(*a*) The opening in the trachea is larger than the tube and the escaping air spreads along the fascial planes in the neck. This applies to either a vertical or a transverse incision in the tracheal wall.

(*b*) The tube is too short and is coughed out of the trachea.

(*c*) If emphysema once appears as a result of either of these causes, the swelling of the tissue will cause an otherwise well-fitting tube to become too short. The tube may be coughed out and thus favor the spread of the emphysema. Mediastinal emphysema usually results in the death of the patient.

---

16. Neumann, A.: Mitteilungen über Diphtherie, Deutsch. med. Wchnschr. **19**:154-157, 1893.

17. Roger, quoted by Chiari: Chirurgie des Kehlkopfes und der Luftröhre, Neue Deutsche Chirurgie, Stuttgart, F. Enge **19**:109, 1916.

18. Taute, quoted by Chiari: Chirurgie des Kehlkopfes und der Luftröhre, Neue Deutsche Chirurgie **19**:103, 1916.

5. The use of a trocar to perform an emergency tracheotomy is never justifiable. The use of a cautery to divide the skin and tissue overlying the trachea is dangerous on account of delayed hemorrhage.

6. The excision of a piece of the tracheal wall the size of the tube is followed by an excessive formation of granulations and a local stricture at this point is apt to result when the tube is removed (Chiari).

Methods of Treatment

The fact that there are so many methods of treatment for papilloma of the larynx in children indicates clearly that the therapy of this condition is universally unsatisfactory. The principal forms of treatment have been indicated in the preceding illustrative cases from the literature. For the sake of clearness, however, we will review the therapeutic measures that have been advocated and add the results of our experiences.

TRACHEOTOMY WITHOUT LOCAL TREATMENT

Hansberg[19] reports a series of cases, all of them were children that were treated by tracheotomy alone. "Good results" were reported in seven cases; in three, the tube was worn for six months; in one, for two years; in one, for seven years, and in one the time is not mentioned. "No results" were reported in four cases. One child died of pneumonia. In two cases, the tube was worn for seventeen and twenty-two years, and the growths finally were removed endolaryngeally.

Ferreri[20] describes a case, in a girl 3 years of age, in which tracheotomy was performed and the tube left in for "several months" in order to see whether the tumors would disappear as some authors assert. "On the contrary they increased in size." Operative removal ultimately resulted in a cure. The duration of the cure is not mentioned.

Gray[21] reports the case of a child, 3 years of age, in which a tracheotomy was performed in July, 1905. In July, 1906, the growths had involved the trachea, and the dyspnea was marked. Roentgen-ray treatments throughout the next two years resulted in an apparent cure. Gray also describes another case, in a boy of 6, in which there was no improvement in the laryngeal condition two years after the introduction of the tracheal tube.

---

19. Hansberg: Handbuch d. Spez. Chirurgie und der oberen Luftwege. Würzburg **4**:395, 1913.

20. Ferreri, G.: Procédés d'excision des papillomes laryngiens, Arch. internat. de laryngol., otol., etc., Paris **32**:1-6. 1911.

21. Gray, A. L.: Remarks on the X-Ray Technic in the Treatment of Laryngeal Papillomata in Children, Ann. Otol., Rhinol. & Laryngol. **19**:348-350. 1910.

Bruns [22] reports the cases of twenty-six patients treated by tracheotomy alone, with seven deaths and nineteen patients improved.

Langmaid,[23] of Boston, described the case of a child, aged 5, in whom tracheotomy alone was followed by a cure after five years.

Broca and Roland conclude that tracheotomy and rest will not cause the growths to disappear.

Harmon Smith concludes that a tracheal tube without some collateral aid will *not* result in the disappearance of the growth.

Payson Clark is a strong advocate of tracheotomy and noninterference locally—"while a cure is possible in a large number of cases by simple tracheotomy and time, removal of the papilloma (intralaryngeally) when it has become quiescent hastens the cure."

Dungas Grant [24] reports a case in which a girl underwent a tracheotomy when four months of age. At the age of 22 years, she was still wearing a tube and the larynx was filled with papillomas. These growths were removed at one sitting and never recurred.

A tracheotomy was necessary sooner or later in every case of papilloma of the larynx in a child that we have seen. As soon as a diagnosis is made, the first step in the therapy should be the introduction, under local anesthesia, of a well placed, carefully fitted tracheal tube. An intubation tube cannot be used with safety in this condition. Several cases have been reported in which the introduction of an intubation tube was followed by bronchopneumonia, presumably due to the aspiration of a piece of the growth.

OPERATIVE REMOVAL

There are three methods of operative removal: (*a*) endolaryngeal removal; (*b*) laryngofissure with immediate closure, and (*c*) laryngostomy or permanent opening of the larynx.

The last two methods are probably never justifiable in a child. Either of these two procedures may result in a cure of the papilloma; but an even worse condition—a laryngeal stenosis—is substituted (Case 1 of our series).

Endolaryngeal removal is the operation of choice, and every writer has emphasized the importance of traumatizing as little as possible the mucous membrane adjoining the growth. Trauma certainly encourages the multiplication and spread of these laryngeal papillomas.

---

22. Bruns, P., quoted by Chiari: Chirurgie des Kehlkopfes u. der Luftröhre, Neue Deutsche Chirurgie **19**:360, 1916.

23. Langmaid, in discussion on Coakley: Tr. Am. Laryngol. Assn. **29**: 126-141, 1907.

24. Grant, Dungas: The Etiology, Treatment and Prognosis of Innocent Laryngeal Growths, J. Laryngol., Rhinol. & Otol. **19**:637-652, 1904.

It has been the general experience that repeated removals are necessary over a long period of time in order to effect a cure. Dr. Robert Lynch,[25] however, seems to have had extraordinary success by removing the growths with the aid of his suspension apparatus. He reports sixteen cases of papilloma of the larynx (six in children under 5 years of age), in all of which the voice returned perfectly. The growths in children were all multiple. He did not operate after the period of active growth had ceased, but took the cases just as they came. No local applications were used, other than tincture of benzoin at the time of operation.

Dan McKenzie[26] reports one case, in a boy aged 7, in which the papillomas had been removed several times by the usual intralaryngeal methods, but always with recurrence. One removal with the suspension apparatus resulted in an apparent cure, since there has been no recurrence in a year.

Albrecht has had uniformly good results after removal with the suspension apparatus in nine children.

Dr. Robert Levy,[27] of Denver, reports the case of a child, 8 months of age, in which a localized growth in the anterior commissure was removed under direct suspension. This was thought to be a particularly favorable case; but the growth rapidly recurred with "increased activity."

The experience of the great majority of French, German, Austrian, English, Italian and American writers is that when the growths are removed endolaryngeally with any kind of curet or forceps, they almost invariably recur, and the operation must be repeated throughout months or years.

OTHER METHODS

Fulguration gives such favorable results in the treatment of papilloma of the bladder that it has been given an extensive trial in papilloma of the larynx. The results, however, are unsatisfactory. Several of our patients were anesthetized with chloroform, and the high frequency spark applied under direct vision. The improvement has always been temporary. Removal with an electric cautery not only fails to cure but results in a fibrous stenosis of the larynx. The local application of alcohol, recommended by Delavan, Chevalier Jackson and others, is apparently of value in some cases. The use of formaldehyd, castor oil, the chemical caustics and astringents is of

25. Lynch, R. C., in discussion on Hubbard: Tr. Am. Laryngol. Assn. **37**: 52-66, 1915.

26. McKenzie, Dan: Papilloma of the Larynx in a Child Treated Under Suspension Laryngoscopy, Proc. Roy. Soc. Med. **9**:Laryngol. Sect., p. 53, 1915.

27. Levy, Robert, in discussion on Smith, Harmon: Papilloma of the Larynx. J. A. M. A. **63**:2207-2211 (Dec. 19) 1914.

little value. The internal administration of arsenic, potassium iodid, calcined magnesia, and tincture of thuja each has a few enthusiastic adherents. Many encouraging results of roentgen-ray and radium treatment have been reported from this country and Europe. Great caution must be used, however, in the administration of these agents, and particularly in the intralaryngeal application of radium.

Duffy [28] reported in detail the postmortem findings in one of our cases (Case 4) in which the intralaryngeal application of radium resulted in a sloughing of the posterior laryngeal wall and a tracheo-esophageal fistula *without causing a disappearance of the papilloma.* The amount of radium used in this case was: Sept. 28, 1915, 103 mg. of radium for forty-five minutes; November 5, 103 mg. of radium for one hour and thirty minutes; November 20, 103 mg. of radium for two hours, and December 20, 103 mg. of radium for one hour and fifty-five minutes.

Jan. 1, 1916, the tracheotomy tube was removed. January 13, there was difficulty in swallowing, and February 5, bronchopneumonia developed. The patient died ten days later.

Since this experience, we have never employed radium without the expert advice of Dr. C. F. Burnam, and we have had no further burns; but on the other hand, it is doubtful whether or not we have had a permanent cure. Case 8 is a good example. The patient was anesthetized for each treatment, and the radium applied to the growths under direct vision.

Dec. 13, 1917, 500 mc. was applied for five minutes; Jan. 3, 1918, 600 mc. was applied for one and three-fourths minutes; January 19, 542 mc. was applied for three and one-half minutes, and February 9, 1,065 mc. was applied for three minutes.

During March the patient had whooping cough without complications. June 15, a heavy external radiation was applied over the front and both sides of the larynx. November 20, 700 mc. was applied for five minutes; Jan. 23, 1919, large masses of papillomas were removed through the mouth and tracheal opening. February 10, 879 mc. was applied to the larynx through the tracheotomy opening for ten minutes. November 21, 700 mc. was applied to the larynx from above for ten minutes. In addition to these intralaryngeal treatments, several heavy external radiations were applied.

Jan. 20, 1920, large masses of papilloma were excised from the larynx and trachea. June 21, large masses of papilloma were excised from the larynx and trachea. June 8, 1921, large masses of papilloma were excised from the larynx and trachea. September 15,

28. Duffy, W. C.: Papilloma of the Larynx, Johns Hopkins Hospital Reports **18**:417-438, 1919.

the patient breathed freely with the tube corked. Small masses of papilloma were removed from the trachea.

Plum,[29] from Schmiegelow's Clinic in Copenhagen, has recently reviewed the literature of papilloma of the larynx in children, and gives a list of eighty-four references. Very few articles have appeared on this subject since 1914. While the results have been encouraging in isolated cases, sufficient data have not been collected regarding the amount of radium used, the method of application and the ultimate results.

Polyak,[30] for example, reports the case of a child, 9 years of age, in which the papillomas had been removed repeatedly, and finally by laryngofissure. In fifteen treatments, a "small quantity" of radium was applied to the interior of the larynx for a total of twenty-one hours. The growths disappeared, but recurred four months later. Another series of treatments for a total of eight and one-half hours resulted in a cure. No mention is made of the period of observation nor of the amount of radium and the character of the screen.

Abbe [31] reports the case of a young child, with recurrent papillomas that filled the larynx. Tracheotomy was followed by an extension of the growth to the trachea. "Strong radium" was applied under ether for one-half hour. A second application was made six months later. About one third of the original growth remains below the vocal cord.

Ferreri [20] reports a case of papilloma in a child, 6 years of age. The growths recurred after excision, tracheotomy and laryngostomy. During two months, twenty radium treatments were given. The amount of radium used is not mentioned. The growths disappeared but later recurred; again a series of radium treatments caused them to disappear. They recurred, but removal with a curet then effected a cure. Radium in the hands of an expert is a valuable therapeutic agent. Reports of favorable results, however, without data as to the dosage and the precautions taken to prevent a burn, encourage those who have had no experience with radium to employ it in their cases. This will inevitably lead to many serious complications and fatalities.

METHODS USED BY THE AUTHORS

The treatment of papilloma of the larynx in children is so unsatisfactory that a detailed report of the various methods of treatment employed in our cases is justifiable in order to point out the mistakes and successes.

---

29. Plum, A.: Les papillomes du larynx chez l'enfant, Acta oto-laryn. **2**:119-143, 1920.

30. Polyak: Radium bei Papillom, Verhandl. d. internat. Laryngo-Rhinol.-Kong., Berlin, 1911.

31. Abbe, Robert: Papilloma of the Vocal Cords, St. Luke's Hosp. M. & S. Rep., New York **3**:22-24, 1911.

We have tried external operations on the larynx with subsequent skin graft of the interior of the larynx in two cases. This cured the papillomatous condition but left a permanent laryngeal stricture. We have tried repeated endolaryngeal extirpations of the growths; but they always recurred, and usually in increased numbers. Fulguration of the growths, under chloroform anesthesia and through a direct laryngoscope, resulted in temporary benefit or no improvement. Extirpation of the growths and fulguration of their points of attachment was of no value.

Finally, radium alone, or in combination with various of the methods outlined above, was tried in seven of our cases. It is of vital importance to determine the exact amount of radium that should be employed and the interval between the applications that will give the best therapeutic results. We have radiated too heavily in some of our cases. In one case death was due to a tracheo-esophageal burn. In other cases, the radiations were probably not sufficient to produce the best result.

It is possible that the growths in some persons are less sensitive to radium than they are in others; if so the difference cannot be recognized by any variation in the gross or microscopic appearance of the papillomas.

The ideal treatment for papilloma of the larynx in children is one that will restore the voice and cause the growths to disappear rapidly and permanently, with no danger of a complicating pneumonia or an ultimate laryngeal stricture. Our experience encourages us to believe that radium, properly administered, may bring about this result. It is probable, however, that even an ideal therapy will not eliminate the preliminary tracheotomy, because so many of these cases in children are not recognized until complete aphonia or alarming symptoms of respiratory obstruction bring them to the physician.

In this connection, it should be emphasized again that the method of tracheotomy employed in children is of the greatest practical importance and must be observed in order to obtain uniformly good end-results.

REPORT OF CASES

CASE 1 (Surg. No. 29853, 30275, 34290).—A boy, white, aged 2 years, was brought to the hospital, May 13, 1912, with urgent dyspnea. The difficulty in breathing began two months before admission and rapidly became worse. He had had measles at 1 year of age, but otherwise, no illness of any kind. It was noted soon after birth, that the cry was hoarse. The hoarseness had gradually increased, and for several weeks he had been unable to speak above a whisper. The condition on admission necessitated an emergency tracheotomy.

May 19, 28 and June 2: On each of these dates, the child was anesthetized with chloroform, and the growths were fulgurated under direct vision. These treatments had no appreciable effect.

May 30: The tonsils and adenoids were removed. They were much hypertrophied, and we wished to remove all sources of irritation to the larynx.

July 26: The papillomatous masses seemed to have increased in size and number as a result of the previous treatments. Under ether anesthesia, the larynx was opened externally and the papillomas removed, together with all the mucous membrane from which they arose. The denuded area was then cauterized with a hot iron.

This one operation cured the papillomatous condition; but for the last nine years, we have been trying to reestablish the lumen of the larynx. The scar tissue was first dissected out with aid of the Killian suspension apparatus and an attempt was made to maintain and dilate the lumen with intubation tubes. This was a very tedious procedure, for even with strings attached at each end, the tubes were kept in place with difficulty. Inability to swallow food without contaminating the wound was a trying complication, and much of the time nasal feedings were necessary.

Later, a second external operation was necessary. The scar tissue was removed and a Thiersch graft applied to the interior of the larynx. An intubation tube wrapped in iodoform gauze was left in the larynx in order to hold the graft in place. In spite of nasal feedings and frequent dressings, the wound became infected and the intubation tube was removed after four days. A two-way silver tracheal tube was then inserted and worn most of the time for three months. This also necessitated nasal feedings for two weeks; but after that, the child had no trouble in swallowing liquid or solid food. Luckily, no respiratory infection occurred during this period.

At present (August, 1921), the child still wears a tracheal tube. He can speak only in a hoarse whisper; can breathe through his mouth with the tube closed, but cannot exercise with the tube closed. His general health is excellent. He has developed normally and has had no illness of any kind during the nine years he has been wearing the tube.

SUMMARY OF TREATMENT

1. Emergency tracheotomy was performed under local anesthesia.

2. Fulguration: Three treatments under general anesthesia were given with no benefit.

3. Tonsils and adenoids were removed.

4. Laryngofissure was performed with excision of the papillomas, together with all the mucous membrane from which they arose. Cauterization of the denuded area with the actual cautery.

5. This procedure cured the papillomas but resulted in a stricture of the larynx, which subsequent treatment has failed to cure.

6. The patient has been under observation for nine years.

CASE 2 (Surg. No. 30499).—A colored boy, aged 3 years and 9 months, was admitted to the hospital, Sept. 6, 1912, with marked inspiratory and expiratory dyspnea and complete aphonia. The difficulty in breathing was first noticed when the child was 8 months old. For several weeks, he had had severe attacks of dyspnea; these usually occurred at night and were associated with profuse sweating. No history was obtained of any of the acute infectious diseases.

The general physical examination was negative, with the exception of a large umbilical hernia. There was no evidence of tuberculosis or syphilis.

The tonsils and adenoids were removed four months before admission, with the idea that the difficulty in breathing was due to hypertrophied adenoids.

A low tracheotomy was performed under local anesthesia on the day of admission. Laryngeal examination showed the entire glottis filled with growth. The larynx was opened ten days later, and the entire glottis and subglottic area as far as the ring of the cricoid was found thickly studded with papillomatous growths. All the involved mucous membrane was removed in one piece and a large Thiersch graft applied to the denuded area. The graft was held in place with gauze wrapped in protective. The wound was left open. In this case, also, nasal feedings were necessary; but it is our impression that the entire graft was lost as a result of infection due to contamination of the wound with saliva and vomitus.

The external wound closed by granulation within three weeks. Dilatations were attempted, but were soon abandoned owing to lack of cooperation by the parents.

At present (August, 1921), the child has a complete stricture of the larynx, but is otherwise well.

SUMMARY OF TREATMENT

1. Tracheotomy was performed under local anesthesia.

2. Laryngofissure, with removal of all involved mucous membrane was performed, and a Thiersch graft applied.

3. The graft was probably lost owing to infection. Permanent stricture of the larynx resulted.

CASE 3 (Surg. No. 37713).—A white boy, aged 4 years, was admitted, March 14, 1914. He had always been "sickly." He did not cry until he was 2 months of age. He began to talk at 11 months, but the voice was never clear. There was a history of measles at 11 months of age. One year ago he had an acute respiratory infection, and since that time, the voice had become progressively worse. During the last three weeks, he had had a rise of temperature from 99.6 to 104 F.; the voice was much worse; he had had attacks of dyspnea, and was rapidly losing weight.

On admission, the child was given antitoxin, although no definite evidences of diphtheria were ever discovered. The physical examination and the roentgen-ray examination of the chest were both negative. Examination of the blood revealed 9,800 leukocytes. The Wassermann reaction was negative, but the skin tuberculin test was strongly positive.

Examination of the larynx disclosed two or three small papillomas sharply localized in the anterior commissure.

March 18: Papillomas removed with the aid of a Jackson laryngoscope; tracheotomy seemed unnecessary.

April 7: Papilloma again removed. They were still sharply localized in the anterior commissure. Patient allowed to go home.

Aug. 21, 1915: For the last few months, the former symptoms have gradually recurred. Emergency tracheotomy was necessary today on account of the sudden onset of severe dyspnea with cyanosis; the entire larynx apparently filled with growth.

August 26, September 2 and 16: On each of these dates, the child was given chloroform and the growths fulgurated. On the latter date, all papillomas were removed and their bases fulgurated.

September 23: The growths have recurred and again fill the entire larynx. Radium,[32] 103 mg., enclosed in a soft rubber catheter was placed in the larynx and left for one hour.

October 9: Radium, 103 mg., held between cords for one and one-half hours.

October 11: The growths had decreased to such an extent that the patient could breathe normally through the mouth; tracheotomy tube removed.

October 26: Patient discharged; tracheal wound closed; voice strong but husky.

The patient had pneumonia in January, 1916, at home. Following this, the voice became worse and the attacks of dyspnea returned.

March 16, 1916: Tracheal tube again inserted. The larynx was again filled with growth.

April 1: Tonsils and adenoids removed, indications being: (1) frequent attacks of tonsillitis; (2) enlarged cervical glands, and (3) positive tuberculin test.

April 12: Radium, 103 mg., intralaryngeally for forty-five minutes.

April 21: Radium, 103 mg., intralaryngeally for fifteen minutes.

May 3: Radium, 103 mg., intralaryngeally for forty-five minutes.

The growths have almost disappeared. The vocal cords can now be seen.

May 8: Tracheal tube removed and wound allowed to close; breathed normally through the mouth and the voice was much improved.

May 10: Mother took child home to West Virginia today, although urged to leave him here for several weeks longer.

May 20: Letter stated that he was rapidly becoming worse. A few days later the child died on the train while on his return to Baltimore. The larynx was opened by the family physician and the entire subglottic space as far as the first ring of the trachea was found to be filled with growth.

SUMMARY OF TREATMENT

1. Excision of papillomas by intralaryngeal methods. They recurred and were removed again three weeks later. Tracheotomy was not necessary at this time.

2. Patient had very little trouble for a year. Emergency tracheotomy necessary sixteen months after first operation.

3. Four treatments by fulguration under general anesthesia were given with no benefit.

4. Radium, 103 mg., for one hour and later for one and one-half hours, intralaryngeally, caused all obstructive symptoms rapidly to disappear and the tracheal tube was removed.

5. Symptoms recurred after pneumonia; tracheal tube again inserted six months after its removal.

6. Radium again caused the growths to disappear and the tube was removed. Recurrence was rapid, however, and the child died of asphyxia while on the train.

---

32. All intralaryngeal applications of radium mentioned in this paper were screened with 2 mm. of brass and 2 mm. of rubber. In all extralaryngeal treatments, the radium was enclosed in a capsule of brass, 2 mm. in thickness. and a lead box 2 mm. in thickness and one thickness of box-board.

CASE 4 (Surg. No. 36509).—A colored boy, aged 1 year and 9 months, entered the hospital, March 9, 1915, on account of hoarseness of four or five months' duration and difficulty in breathing. He had pertussis at 11 months but no other infectious disease. A tracheotomy was not necessary on admission. The general physical examination was negative, aside from rachitis. The Wassermann and Pirquet tests were negative. There was one large mass of papillomatous growth in the larynx that seemed to arise from the true cord on the right. He had suffocating attacks only when asleep.

March 10: Radium, 500 mg., externally, over the larynx at a distance of one-half inch (12.7 mm.) for six hours.

March 15: The papillomas have not decreased in size.

March 27: Radium, 564 mg., externally, over the larynx at a distance of one-half inch (12.7 mm.) for six and three-quarters hours. This resulted in a second degree burn of the skin under the chin and just above the sternum.

April 17: The growths were much smaller. The true cords could be clearly seen for the first time since admission.

May 13: The voice was much clearer than on admission.

June 10: Laryngeal examination showed that the papillomas were increasing in size and number. The difficulty in breathing was more marked than on admission.

June 26: Tracheotomy was necessary. The growths in the larynx were fulgurated under chloroform. Killian suspension apparatus was used.

July 13: Laryngeal examination showed a marked increase in the number of papillomas.

July 22: Radium was used intralaryngeally, 500 mg., for two and one-half minutes.

August 7: Fulguration was used after removal of large masses of papillomas.

August 27, September 10: Fulguration and Killian suspension apparatus were used, with chloroform anesthesia.

September 25: The laryngeal condition showed no improvement.

September 28: Radium, 103 mg., intralaryngeally, in a metal case covered with a soft rubber catheter, held between cords for forty-five minutes under ether anesthesia.

October 30: Radium treatment, intralaryngeally, attempted; but the larynx was so filled with growth that the radium carrier could not be introduced between the cords.

November 5: Radium, 103 mg., intralaryngeally, for one and one-half hours.

November 20: Radium, 103 mg., intralaryngeally, for two hours.

December 1: The papillomas were much smaller and were pale gray in marked contrast to the former pink color.

December 20: Radium, 103 mg., intralaryngeally, for one hour and fifty-five minutes. Examination showed that all the growths had disappeared with the exception of one small tag on the right cord.

December 23: Tracheotomy tube removed.

December 27: Necessary to replace tracheal tube. Patient had severe coughing attacks when eating.

December 28: When patient attempted to swallow milk, it returned through the tracheal tube; temperature 101.6 F.

December 29: Attempts to feed through nasal tube not successful: the tube always entered the trachea. A septic temperature and an abundant purulent discharge through the tracheal tube continued until death, Feb. 16, 1916.

Necropsy[33] disclosed an extensive ulceration of the interior of the larynx and a tracheo-esophageal fistula at the upper end of the trachea. Several papillomas were found in the right pyriform sinuses. There was an extensive bronchopneumonia and a chronic diffuse thyroiditis.

SUMMARY OF TREATMENT

1. External radiation that resulted in a second degree skin burn and, temporarily, in a marked decrease in the size of the papillomas was used.

2. The growths reappeared in increased numbers and a tracheotomy was necessary.

3. Fulguration was employed on three occasions with no apparent benefit.

4. The papillomas were removed intralaryngeally on one occasion. They rapidly recurred.

5. From September 28 to December 20 he had four intralaryngeal treatments. On each occasion, 103 mg. of radium was used and the total exposure was eight hours and ten minutes.

6. These treatments resulted in an extensive intralaryngeal burn, the formation of a tracheo-esophageal fistula and death from bronchopneumonia.

7. At necropsy, papillomas were still present in the right pyriform sinus.

CASE 5 (Surg. No. 43200).—A colored boy, aged 8 years, was admitted, July 13, 1917, on account of aphonia and "noisy breathing at night." These symptoms appeared after an operation in November, 1916, for removal of tonsils and adenoids. He had always been a mouth-breather. He had had measles when 7 years of age (so this disease might have been an etiologic factor).

Laryngeal examination showed a large mass of papillomas; but they involved only the anterior half of the true cords.

Under ether anesthesia, these growths were removed without injury to the surrounding mucous membrane. Tracheotomy was not necessary.

We have been unable to trace this patient, and so the result is doubtful.

CASE 6 (Surg. No. 44334).—A white boy, aged 4 years, was admitted, May 25, 1917. The symptoms, hoarseness and difficulty in breathing, began without any apparent cause, when the child was 3 years of age. He had never had an acute illness of any kind. The general physical examination was negative aside from the laryngeal condition.

May 25: Papilloma excised, using a Jackson laryngoscope. There was free breathing for seven weeks.

August 25: Papillomas had recurred; again excised.

December 11: Papillomas had returned; low tracheotomy performed under local anesthesia and primary chloroform.

December 13. Radium, 500 mc., intralaryngeally, for five minutes.

---

33. For a full report of the necropsy, refer to article by Duffy, W. C.: Johns Hopkins Hosp. Rep. **18**:417-438, 1919.

Jan. 3, 1918: Radium, 600 mc., intralaryngeally, for one and three-quarters minutes.

January 19: Radium, 542 mc., intralaryngeally, for three and one-half minutes; no change in the size or number of the growths.

February 9: Radium, 1,065 mc., intralaryngeally, for three minutes. Radium apparently had no effect on the growths in the larynx.

March 2: Excision of papillomas through mouth.

March 13: Radium, 1,118 mg., direct to throat externally—three areas—twenty minutes each.

May 27: Radium, 926 mg., in lead box on 1 inch (2.54 cm.) gauze applied to larynx—two areas—one-half hour each.

June 15: Complete aphonia; papillomas have recurred; again excised. Radium, 1 gm., externally, in front and on each side of larynx for thirty minutes; lead 3 mm. in thickness interposed; distance one-half inch (12.7 mm.); total exposure one and one-half hours.

July 10: Radium, 584 mg., in lead tube with three-fourths inch (19.05 mm.) gauze applied to larynx—three areas—twenty minutes each.

August 7: Radium, 150 mg., applied to neck at three-fourths inch (19.05 mm.) distance for one hour.

August 28: Radium, 150 mg., three-fourths inch (19.05 mm.) distance, applied to larynx—three areas—one-half hour each.

September 25: Radium, 150 mg., at three-fourths inch (19.05 mm.), applied to larynx for one-half hour.

October 31: Radium, 1,535 mg., at one-eighth inch (3.17 mm.), applied to three areas on neck for fifteen minutes.

November 20: Radium, 700 mg., *in a tube with open end,* placed directly on papillomas for five minutes. A profuse purulent bloody discharge is coughed out of the tracheal tube. Larynx contains perhaps more papillomas than on admission.

Jan. 23, 1919: Papillomas in trachea both above and below the tracheal tube. These were removed under local anesthesia.

February 10: Radium, 879 mc., applied through tracheal opening directly to growths in larynx and trachea for ten minutes.

November 21: Entire larynx filled with growth. Radium, 700 mc., applied directly to growth *in an open-end tube* for ten minutes.

Jan. 20, 1920: Excision of papillomas from larynx and trachea. One large pedunculated mass at lower end of tracheal tube almost completely occluded the trachea.

June 12: Voice slightly improved; still difficulty in breathing owing to growth in the trachea; large pedunculated masses again excised from trachea above and below the tube.

June 8, 1921: Examination under ether; marked improvement—only one pedunculated growth seen in glottis. This was attached to the left vocal cord. It was removed. No evidence of any recurrence seen in trachea; general health excellent; wears tube constantly though often closed with a cork; voice much improved; goes to the public school and plays baseball and other games without difficulty; has had whooping cough and measles without complication since the tracheotomy tube was introduced in December, 1917.

Case 7 (Surg. No. 43522).—A Jewish child, aged 3 years, was admitted Aug. 15, 1917, with profound respiratory distress of six days' duration, marked cyanosis and complete aphonia. It had always been sickly, having had a

severe attack of tonsillitis, acute cervical adenitis and double otitis media in December, 1915. The adenoids were removed after this attack. It had had chickenpox in December, 1916, and the voice had been hoarse since that time. It had had measles in May, 1917.

August 21: Tracheotomy; laryngeal examination showed the entire glottis filled with growth.

August 25: Excision of papillomas with the aid of a Jackson laryngoscope; ether anesthesia.

August 30: The growths rapidly recurred; again excised.

December 8: Radium, 510 mc., for two and one-half minutes intralaryngeally.

December 29: Radium, 695 mc., for two minutes intralaryngeally. Laryngeal examination showed that the growths were paler but there was no evident decrease in size.

Jan. 9, 1918: Radium, 542 mc., for four minutes intralaryngeally.

April 13: Radium externally, 1 gm., over the front and each side of the larynx at a distance of one-half inch (12.7 mm.) for twenty minutes; lead filter 3 mm. in thickness; total exposure one hour.

May 7: No improvement; laryngeal examination showed large masses of growth on both aryteno-epiglottic folds, both true cords and in the subglottic region. When the tracheal tube was removed papillomatous masses immediately filled the opening. Further operative treatment not advisable.

October 16: The child died of pneumonia during the influenza epidemic of 1918. Necropsy was not permitted.

Case 8 (Surg. No. 44329).—A white boy, aged 3½ years, was admitted, Nov. 28, 1917. Hoarseness had begun six months previously. For three months he had had aphonia and gradually increasing dyspnea. He had had none of the acute infectious diseases. His health had been excellent up to onset of present trouble.

November 28: An emergency tracheotomy was necessary on admission. On direct examination of the larynx, no normal landmarks were seen; large pink masses of papillomas filled the entire glottis.

December 8: Radium, 510 mc., intralaryngeally, for two and one-half minutes.

December 29: Radium, 695 mc., intralaryngeally, for two minutes. Laryngeal examination showed the papillomas were paler in color but not appreciably diminished in size or number.

Jan. 19, 1918: Radium, 542 mc., intralaryngeally, for four minutes. There was still no evident change in the size or number of the growths in the larynx.

February 12: Parents refused permission for further intralaryngeal radium treatments. Under chloroform anesthesia all papillomas were removed by intralaryngeal methods.

February 23: Radium, 1 gm., externally, at a distance of one-half inch (12.7 mm.) to each side of the larynx for one hour.

February 26: Tracheal tube had been tightly corked for a week; the tube removed and tracheal opening allowed to close.

February 28: Discharged; voice hoarse but much better than on admission; had no difficulty in breathing.

April 19: Letter: "Has had no trouble with breathing. Voice is steadily improving."

April 4, 1921: Letter: There has been no evidence of recurrence of the papillomas. The voice is still husky. His general health is not good, appetite poor; has a chronic dry cough; is under-weight and under-size; averages only three days a week at school.

CASE 9 (Surg. No. 45463).—A white boy, aged 4½ years, was admitted, April 29, 1918. He had been a normal, healthy baby. He had had "tracheitis" at 7 months, otherwise no illness of any kind. Hoarseness was first noticed when he was 2½ years old. Examination of the larynx at this time was reported as negative. The voice gradually became worse, and in January, 1917, an examination revealed papillomas on the true cords. These were removed. In April, 1917, it was necessary to perform a tracheotomy on account of the increasing dyspnea. The Wassermann reaction at that time was said to have been positive; he was given mercury and iodids. The parents were not examined. When we first saw him in April, 1918, the Wassermann reaction was negative. There were no stigmas of congenital syphilis, and the papillomas excised at this time showed no histologic evidence of syphilis.

April 30: Removal of growths from larynx through a Jackson laryngoscope.

May 8: Radium, 904 mg., externally on each side of larynx for one-half hour; lead, 2 mm. thick; distance, three-fourths inch (19.05 mm.); total exposure one hour.

June 19: Radium, 1 gm., externally on each side of larynx for forty minutes; distance 1 inch (2.54 cm.).

May 13, 1921: Letter from Dr. John A. Whittle of Rochester, N. Y., saying, "General condition much improved. Still wears the tracheal tube, but can breathe with difficulty with the opening closed. Cannot speak above a whisper. On the advice of Dr. D. R. Ingersoll has had three or four roentgen-ray treatments during the last year."

August 17: Another letter from Dr. Whittle states that the child died, Aug. 6, 1921. For several weeks before death, he had symptoms suggesting a pulmonary abscess. Necropsy refused.

CASE 10 (Surg. No. 48331).—The papillomas in this case were possibly different from those in the preceding cases, although microscopically no difference was apparent.

A white boy, aged 2 years, was admitted, May 17, 1919. There was no illness previous to onset of present trouble in March, 1919. At that time he was said to have had laryngeal diphtheria, although the only symptoms were difficulty in breathing. The voice was never hoarse. It was necessary to intubate him three times during the first week and several times during the following week because the tube was coughed out.

On admission, he had extreme dyspnea. Leukocytes numbered 15,000; culture from throat and larynx was negative.

May 18: Tracheotomy under local anesthesia; large mass of papillomas below cords; small piece removed. This was followed by pneumonia, with fever, leukocytosis, râles and dulness over the left side of the chest.

June 10: Entirely recovered from the pneumonia; larynx condition unchanged; no local treatment.

October 25: Larynx examined under general anesthesia; growths had entirely disappeared, but there was a partial paralysis of the left vocal cord.

June 6, 1920: Still wore tube; but it was closed with a cork much of the time; general health good; no growths to be seen in the larynx; still weakness of the left cord.

November 15: Tracheal tube removed and opening allowed to close.

August 22: Well.

CASE 11 (General No. 147459).—A white boy, aged 19 months, was admitted, March 9, 1921, with extreme dyspnea. There had been a history of respiratory difficulty since the child was 2 months of age; this gradually increased with occasional exacerbations. The dyspnea had been much worse during the last four months.

There was no history of any of the infectious diseases. The dyspnea was both inspiratory and expiratory; temperature was 99.4 F.; the lungs were clear. The skin tuberculin test was negative. There was no evidence of diphtheria.

March 10: Tracheotomy under local anesthesia.

March 17: Examination of the larynx under ether anesthesia showed large masses of papillomas on both vocal cords, but most abundant in the anterior commissure. The largest masses were removed. Radium, 850 mc., for ten minutes, intralaryngeally.

April 9: Sudden rise of temperature to 105 F. with cyanosis. Tube changed with no relief. Smears made from the tube showed Klebs-Löffler bacilli; 6,000 units of antitoxin given.

June 3: All acute symptoms disappeared within a few days after the antitoxin was given; but there was still a positive tube culture.

June 23: Smears from the tube were negative for the first time since April 9.

August 9: Papillomas had recurred in increased numbers. Under general anesthesia, all the largest tumors were removed by direct laryngoscopy. Radium, 994 mg., for eight minutes intralaryngeally.

September 7: Again a sudden elevation of temperature to 102 F., but without respiratory distress. Culture negative for diphtheria, but 5,000 units of antitoxin was given intramuscularly as a precautionary measure.

September 11: Temperature normal; general condition good. Is still in the hospital.

STUDIES IN EXPERIMENTAL TRAUMATIC SHOCK

V. THE CRITICAL LEVEL IN A FALLING BLOOD PRESSURE*

W. B. CANNON, M.D., AND McKEEN CATTELL, PH.D.
BOSTON

Gesell has distinguished between the *initiating* and the *sustaining* factors in shock. The previous paper of this series [1] was concerned with evidence for a toxic agent developed in damaged tissue and acting as an initiating factor in the onset of shock. The present paper is concerned with a sustaining factor—low blood pressure.

The low blood pressure in both experimental and clinical shock is explained by a diminution of blood volume, an actual decrease in the amount of fluid which is kept circulating. In the early stages of secondary shock, however, the diminished volume may not be associated with a reduced arterial pressure. The only way in which the pressure can be maintained in the presence of a smaller amount of circulating fluid is by a lessening of the capacity of the circulatory system. This diminished capacity is the consequence of extra activity of the vasoconstrictor center causing greater contraction of peripheral vessels. When the blood pressure begins to fall, there may also be passive contraction of these vessels because they are no longer distended by the internal pressure which normally prevails. With further development of shock, there is a fall of arterial pressure below the limits of normal variation, a fall which is accounted for by reduction of the blood volume below the minimal capacity of the system and by a final relaxation of vascular tone as the vasomotor system becomes less active.

The effects of the changes above outlined are fundamentally important to an understanding of the sequence of events in shock. In order to comprehend their significance, it is necessary to refer to the principles of the circulation. We must keep in mind the fact that the blood circulates in order to supply with food and oxygen the tissues which are remote from the alimentary tract and the lungs, and to carry waste from the tissues to surfaces where it may be excreted. The interchange between the flowing stream and the active tissues occurs in the *capillary* portion of the circulatory system. This is the essential region. All other parts of the circulation—heart, arteries and veins—exist in order to provide a continuous flow of blood through the capil-

---

* From the Laboratory of Physiology of the Harvard Medical School.

1. Cannon, W. B.: Studies in Experimental Traumatic Shock, Arch. Surg. **4**:1 (Jan.) 1921.

laries. The high head of pressure normally maintained in the arteries serves, first, to keep a constant flow passing through the capillaries in all parts of the body no matter what extra demands are placed on the general supply of blood by organs which, becoming active, have dilated vessels. Secondly, this high head of pressure assures speed in the passage of blood from the heart back to the heart again. And since the function of the blood as a common carrier depends on the number of trips which it makes from places where it is loaded to where it is unloaded, the speed of the circulation is evidently an important determinant of the capacity of the blood for service in the body.

THE EFFECTS OF DECREASED BLOOD VOLUME

With a decreased volume of blood, the blood pressure may still remain at its normal level because of compensatory vasoconstriction. One might suppose from the restored blood pressure that the blood supply to all parts of the organism is occurring at its normal rate. The admirable investigations of Gesell [2] have shown, however, that this is far from being the case. The vasoconstriction which takes place when, in consequence of hemorrhage or tissue injury, the blood volume is reduced, is not uniform throughout the vascular distribution. Gesell's observations prove that under such circumstances the volume-flow through the submaxillary gland, for example, is greatly diminished. In one instance, a removal of 10 per cent. of the estimated blood volume of the animal caused a reduction of the volume-flow per minute through this gland amounting to 60 per cent. of the basal flow (i.e., the amount passing through the gland when at rest). This occurred even though there was no fall of arterial pressure. The volume-flow is obviously of the utmost importance in the delivery of oxygen to the tissues, for each red blood corpuscle is a carrier. If the number of carriers is reduced to this great degree as a consequence of slight hemorrhage or slight reduction of blood volume, it is obvious that the tissues are in danger of an insufficient supply.

It should not be supposed that all parts of the body are affected in the same way as the submaxillary gland when vasoconstriction compensates for diminished volume. There is good evidence [3] that in the presence of normal arterial pressure the blood vessels of the central nervous system and the heart do not undergo contraction. The effect, therefore, of a peripheral constriction which would shut down the volume-flow in peripheral structures would serve to maintain an adequate volume-flow in the essential organs.

2. Gesell, R.: Am. J. Physiol. **47**:502 (Jan.) 1919.

3. Wiggers, C. J.: Modern Aspects of the Circulation in Health and Disease, New York, Lea and Febiger, 1915, pp. 83, 84.

THE EFFECTS OF DECREASED ARTERIAL PRESSURE

Gesell's studies prove that the volume-flow to peripheral organs is more diminished by reduction of blood volume than by reduction of blood pressure. When blood pressure begins to fall, however, the force which is driving the blood through the capillaries begins to become less effective, consequently the rate of flow will, as a rule, steadily diminish as the pressure falls. Thus the volume-flow not only to peripheral structures but also to the essential organs, such as the central nervous system and the heart, becomes gradually less and less.

Diminished blood volume, therefore, results in a lessened blood supply to peripheral tissues because of a primary vasoconstriction; and lessened blood pressure results in diminished blood supply both to peripheral tissues and to central organs because of a slower flow. All parts of the body may then begin to suffer from disturbances of the circulation, initiated by diminished volume of blood and continued as the volume becomes less and less.

The materials delivered to the tissues by the flowing blood may be classified into food, water and oxygen. The degree of dependence of cells on these materials varies with the materials and also with different groups of cells. Thus there may be prolonged absence of fresh food supply in the blood without disturbance of function. A less prolonged absence of fresh water supply in the circulating stream is also endured without serious damage. The need for oxygen, however, is quite different from the need for either food or water. It is urgently necessary that oxygen be continuously delivered if tissues are to be kept active. It becomes a matter of importance, therefore, to inquire into the evidence that there actually is an insufficient oxygen supply delivered to the tissues when the flow of blood through the capillaries is much reduced.

RELATION OF REDUCED ALKALI RESERVE TO BLOOD PRESSURE

In 1910, Henderson[4] pointed out that in the absence of an adequate supply of oxygen the development of acid substances in the tissues might be expected, in consequence of the partial asphyxia. Later, Crile[5] and his co-workers reported results which indicated that a condition of "acidosis" is present in various clinical states, including shock. And in 1917, during a study of the toxemia of gas gangrene, Wright[6] observed a reduction of the alkalinity of the blood serum as determined by titration with acid to a certain end point. Patients suffering from gas gangrene have many of the symptoms of shock, and Wright argued

4. Henderson. Yandell: Am. J. Physiol. **27**:167, 174, 1910.
5. Crile, G. W.: The Origin and Nature of Emotions, Philadelphia, W. B. Saunders Company, 1915, p. 227.
6. Wright, A. E.: Lancet **1**:8 (Jan. 6) 1917.

that the "acidemia," as he called it, of this condition was the cause of these symptoms.

During the summer of 1917, at Béthune, one of us (W.B.C.) made use of the then newly described method and apparatus introduced by Van Slyke,[7] and obtained estimates of the sodium bicarbonate, or alkali reserve of the blood plasma in wounded men suffering from the low arterial pressure which accompanies shock, hemorrhage and gas gangrene.[8] The results given by the Van Slyke instrument are expressed in percentage by volume of carbon dioxid which can be separated from the plasma after it has been exposed to an atmosphere containing 5.5 per cent. of the gas (the concentration existing in the pulmonary alveoli and present in the final air of an extreme expiration). Any figures lower than 50 per cent. by volume of carbon dioxid in the plasma of adults indicates a reduction of the alkali reserve below the normal range of variation. In the sense defined by L. J. Henderson[9] and by Van Slyke and Cullen,[10] readings below this normal range may be regarded as marking a condition of "acidosis." The expressions "reduction of the alkali reserve" and "reduction of the carbon dioxid capacity" may be used interchangeably with the reduction of blood alkali. In the Béthune cases, observations were made on the relation of reduced alkali reserve to blood pressure, to pulse, and respiration, and to other attendant conditions.

In forty-five different coincident determinations of blood pressure and carbon dioxid capacity, a rough relation between the two was found; in general, the lower the blood pressure, the lower the alkali reserve. This relation is illustrated in Table 1.

TABLE 1.—Relation Between Blood Pressure and Carbon Dioxid Capacity

No. of Cases	Carbon Dioxid Capacity Percentage by Volume	Systolic Arterial Pressure in Millimeters of Mercury
6	50 to 59 (av. 53)	90
25	40 to 49 (av. 44)	75
8	30 to 39 (av. 35)	72
6	20 to 29 (av. 24)	59

It is noteworthy that in thirty-nine of the forty-five cases, the average systolic pressure was 75 millimeters of mercury, or less, and that in all these there was a carbon dioxid capacity of less than 50 per cent. by volume, i.e., below the normal range. Furthermore, as the average carbon dioxid capacity was low, the average systolic pressure

7. Van Slyke, D. D.: J. Biol. Chem. **30**:347 (June) 1917.

8. Cannon, W. B.: Acidosis in Shock, Hemorrhage and Gas Infection, J. A. M. A. **70**:531 (Feb. 23) 1918.

9. Henderson, L. J.: Science, **37**:389, 1913.

10. Van Slyke, D. D., and Cullen, G. E.: J. Biol. Chem. **30**:292 (June) 1917.

was likewise low. In the cases mentioned above, some process had been going on for hours, often six or eight, that had brought about the state observed on admission of the patient. The progressive character of the process was shown in one instance in which the carbon dioxid capacity one hour after the wounding was 50 per cent., and five hours later, with no corrective treatment, it had fallen to 40 per cent. The condition has a gradual rather than an acute onset.

EXPLANATION OF THE DIMINISHED ALKALI RESERVE

Two explanations have been offered to account for the reduction of the bicarbonate of blood plasma: one that nonrespirable acid, such as lactic acid, develops in the tissues because of oxygen want, and, uniting with the sodium of sodium bicarbonate, drives off carbon dioxid, which is breathed out; the other that excessive respiration diminishes the carbonic acid in the blood with consequent *alkalosis,* and that thereupon the extra alkali disappears into the tissues, or diffuses into body fluids outside the blood, or escapes through the kidneys. The former process has been designated by Henderson as the "acidotic," the latter as the "acapnial" reduction of blood alkali.

There is a good deal of evidence that an insufficient oxygen supply to the tissues results in formation of lactic acid. Zillesson,[11] 1891, noted that when the blood supply of the muscles or liver was limited, lactic acid was formed in these organs. Araki[12] proved that lactic acid (lactates) were present in the urine of dogs and rabbits in conditions of oxygen lack brought about by breathing carbon monoxid or by a low percentage of oxygen in the inspired air. In an artificially produced anemia, Irisawa[13] found that the lactic acid content of the blood increased as the oxygen lack became more severe. More recently, Milroy[14] and Penfield[15] have reported that reduction of blood alkali appears typically after a severe hemorrhage. And within the last few years, a number of workers have published papers on experimental shock in which there is agreement that a decreasing alkali reserve is associated with a falling blood pressure (McEllroy,[16] Guthrie,[17] Erlanger and Gasser[18] and Gesell[19]). The low blood pressure in the late stages

11. Zillesson: Ztschr. f. physiol. Chem. **15**:404, 1891.
12. Araki: Ztschr. f. physiol. chem. **19**:447, 1894.
13. Irisawa: Ztschr. f. physiol. chem. **17**:340, 1893.
14. Milroy: J. Physiol. **51**:272, 1897.
15. Penfield, W. G.: Am. J. Physiol. **48**:121 (Feb.) 1919.
16. McEllroy, W. S.: Acidosis in Shock, J. A. M. A. **70**:847 (March 23) 1918.
17. Guthrie: Am. J. Physiol. **45**:544, 1918.
18. Erlanger, J., and Gasser, H. S.: Am. J. Physiol. **50**:116 (June) 1919.
19. Gesell, R.: Am. J. Physiol. **47**:459 (Jan.) 1919.

of experimental shock, according to Macleod,[20] is associated with a demonstrable increase of lactic acid in the blood—an effect attributed by him to anoxemia because of depression of both the respiratory and the circulatory functions. All the conditions described above, which are associated with an increase of lactic acid or a reduced alkali reserve, are characterized by diminished blood volume, or diminished blood pressure, or decreased carrying power of the corpuscles, so that the delivery of oxygen to the tissues is reduced. It is well proved that in the absence of adequate oxygen supply the lactic acid which accompanies muscular contraction, for example, is not burned to carbon dioxid and water.[21] The liberation of such acid would produce the effects which have been observed—a demonstrable increase of lactates in the blood, and a diminution of sodium bicarbonate. It may be, as Wertheimer, Fabre and Clogne[22] have noted, that diacetic acid is present in some instances.

The other explanation for the reduced blood alkali attributes the change to relative increase of pulmonary ventilation. Henderson and Haggard[23] have reported that if they permit an animal to breathe to excess, as it naturally does during the development of shock from trauma of the abdominal viscera, failure of the circulation and death are induced. This is associated with a lowering of both the carbon dioxid content and the carbon dioxid capacity of the blood and also a lowering of the arterial pressure. In explanation of these results, Henderson and Haggard[24] have found that when animals are subjected to progressively decreasing oxygen percentages, the first effect is an abnormally large loss of carbon dioxid from the body due to excessive breathing and that thereafter alkali passes out of the blood to compensate for the alkalosis thus developed. In other words, when the carbonic acid of the blood is lowered, sodium bicarbonate also falls. A modification of this view has been suggested by Moore,[25] who assumes that as a consequence of shock there is a general lowering of metabolic activity to about one-third the normal rate. If then the lungs continue functioning at their usual rate, or even less, there will be removed from the blood an excess of carbon dioxid over that which is produced, and the blood will be altered in the alkaline direction.

---

20. Macleod, J. J. R.: Am. J. Physiol. **55**:190 (March) 1921.

21. Fletcher and Hopkins: J. Physiol. **35**:298, 1907.

22. Wertheimer, Fabre and Clogne: Bull. et mém. Soc. de chir. **45**:9, 1919.

23. Henderson, Yandell, and Haggard, H. W.: J. Biol. Chem. **33**:371 (Feb.) 1918.

24. Henderson, Yandell, and Haggard, H. W.: J. Biol. Chem. **43**:3 (Aug.) 1920.

25. Moore, B.: Lancet, **2**:474 (Sept. 13) 1919.

Thereupon, the kidneys and tissue cells remove alkali from the circulation; and if the blood is examined for circulating sodium bicarbonate, a lower figure than the normal is obtained.

With reference to the argument in the foregoing explanations, we may admit at once that excessive breathing due to oxygen want may have the effect which Henderson has reported. Further, we may admit that in the presence of an excess of alkali, the tendency of the tissues, and of the kidneys, in case there is sufficient blood pressure to permit them to act effectively, would be to remove the excess from the blood stream. There is some question, however, whether the hyperpnea assumed by Henderson, or the continued normal breathing in the absence of adequate stimulation (i.e., the normal carbonic acid content of arterial blood), assumed by Moore, are actually present in cases of shock in human beings. Certainly the method of inducing excessive respiration in experimental shock which Henderson employed, that of positive overventilation of the lungs or vigorous manipulation of the diaphragm, does not represent the conditions attending the onset of

TABLE 2.—Relation of Carbon Dioxid Capacity to Respiration

No. of Cases	Carbon Dioxid Capacity	Average Respiratory Rate
17	40 to 49 (av. 44)	24
7	30 to 39 (av. 35)	28
6	20 to 29 (av. 24)	44

shock as seen in man. The classic descriptions of shock refer to respiration as being shallow and feeble, interrupted by occasional sighs. Such was the character of the breathing noted in numerous cases of shock at Béthune. The rate, as shown in Table 2, is likely to be much more rapid than normal; but since the breathing is shallow, the result is not likely to be an effective ventilation of the lungs.[26] In three cases of shock in man observed by Aub, the ventilation per minute ranged between 5.77 and 7.19 liters. In three other wounded men with normal blood pressures, the average figure was 8.2 with a range of from 6.81 to 9.59 liters per minute. It is unfortunate that it was impossible to obtain more evidence regarding the volume of ventilation in shock observed in human beings. If respiration is shallow, however, it seems probable that there would be no reduction or relatively slight reduction of the alveolar carbon dioxid, and a consequent lessening of the concentration of carbon dioxid in the blood. According to Henderson and Haggard,[27] morphin, by depressing respiration, tends to cause accumulation of carbonic acid in the blood, and therefore prevents the lowering of the

26. Edsall: Boston M. & S. J. **167**:647, 1912.

27. Henderson, Yandell, and Haggard, H. W.: J. Biol. Chem. **33**:344 (Feb.) 1918.

alkali reserve. In the cases of human shock, as observed in Béthune, morphin was given as a routine procedure shortly after the men were wounded. In Table 3 are presented figures showing the systolic and diastolic blood pressures, the carbon dioxid capacity and the morphin dosage in eleven typical cases. These figures demonstrate that prompt administration of morphin, even in doses of one-half grain (0.0324 gm.) may not prevent a reduction of the alkali reserve.

Besides doubt as to whether excessive respiration is present in human shock, there is further question whether it would have, if present, a causal relation to the onset of the shock state. Aub [28] found that the volume of respiration per minute, in experimental shock produced by muscle injury, increased in ten experiments 54 per cent. above the average for the controls. This was, however, before the onset of shock. When the condition of shock became established, the increase

TABLE 3.—SYSTOLIC AND DIASTOLIC BLOOD PRESSURES, THE CARBON DIOXID CAPACITY AND THE MORPHIN DOSAGE IN ELEVEN TYPICAL CASES

Blood Pressure		Carbon Dioxid Capacity	Morphin Dosage, Grain
Systolic	Diastolic		
92	70	49	¼
79	56	30	½
64	40	21	½
76	46	41	¼
42	28	40	¼
72	48	38	½
80	58	43	¼
56	20	26	¼
92	62	47	¼
68	42	36	½
75	46	36	¼

was only 14 per cent. above the controls. One might assume that this indicated that the increased volume of respiration was causally related to the development of low blood pressure. Aub repeatedly observed, however, a rapid breathing with a large increase of the ventilation rate per minute under urethane anesthesia without the onset of shock. Furthermore, uniform artificial respiration may be given to an animal while passing into the state of shock, and under these circumstances no diminution of the carbon dioxid capacity of the plasma occurs until the blood pressure falls. Thus, the respiratory factor is not permitted to vary, and the excessive respiration, as postulated by Henderson, is not capable of producing the changes which he regards as the consequence of hyperpnea. Nevertheless, a low pressure develops, and as the pressure continues to fall, there is a reduction of the alkali reserve. In one such instance, the blood pressure fell in half an hour from 110 to 40 millimeters of mercury with a decline in carbon dioxid capacity of 12 per cent. by volume. In the later stages of this fall of

28. Aub, J. C.: Am. J. Physiol. **54**:388 (Dec.) 1920.

pressure, there might have been a lessening of the carbon dioxid content of the blood because of uniform respiration in the presence of diminished metabolism, but the drop of pressure could hardly be accounted for on the basis of hyperpnea. From all this evidence, it seems probable that the conditions Henderson established in his experiments do not account for the results observed in cases in human beings, and that the reduced alkali may be explained as a consequence of diminished volume-flow to the tissues.

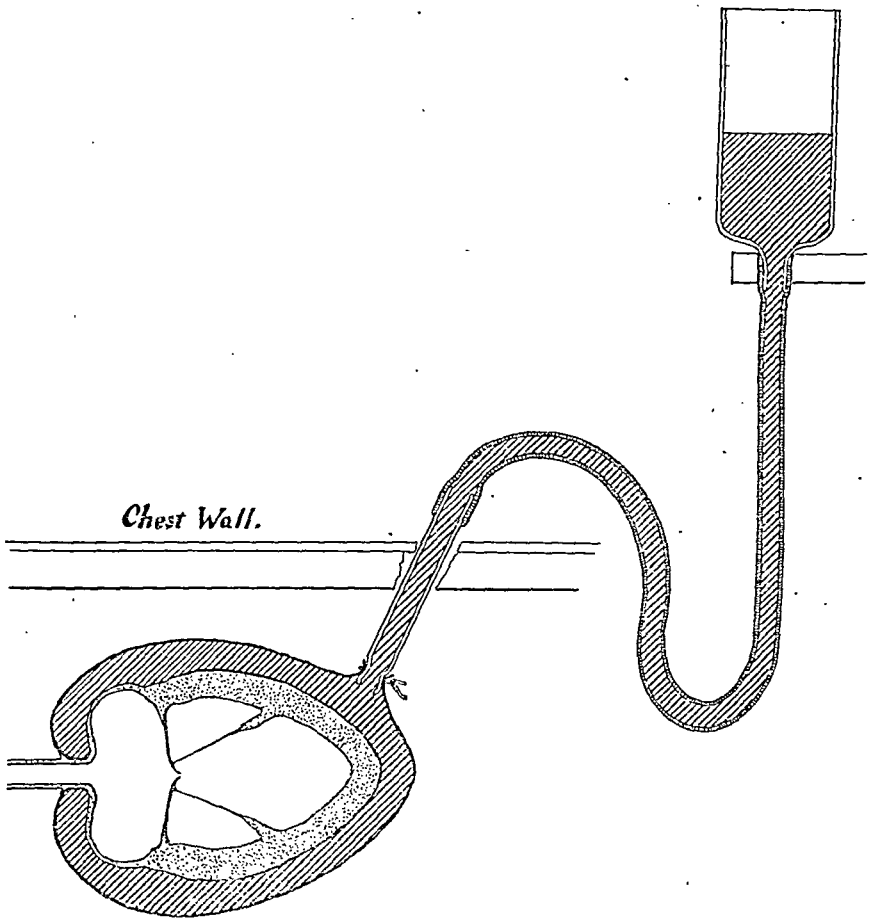

Fig. 1.—Arrangement for controlling the cardiac output and consequently the height of arterial pressure by means of increasing or decreasing intrapericardial pressure.

So far as Moore's contentions are concerned, there is no evidence that the metabolism in shock is reduced to any marked degree until there is a considerable fall of arterial pressure.[28] In other words, the low metabolism may reasonably be regarded as a consequence of the diminished oxygen supply. The reduction of the alkali reserve which has been observed to accompany a diminished oxygen supply may be satisfactorily explained, therefore, on that basis, rather than on the

28. Aub, J. C.: Am. J. Physiol. **54**:388 (Dec.) 1920.

assumption that with continued normal respiration and a diminished carbon dioxid production a primary alkalosis results, followed by escape of the excess alkali.

SIGNIFICANCE OF REDUCTION OF THE ALKALI RESERVE IN SHOCK

Experiments by Dale and Richards [29] and also by Gesell [30] have shown that a large amount of acid may be injected into the blood stream, and the alkali reserve thereby reduced to a low degree without any fall of blood pressure to a shock level. The concomitant fall of blood pressure and reserve alkali in shock, therefore, should not be regarded as indicating that a cause of shock is to be found in the lessened alkali content of the blood. Perhaps when this process reaches an extreme degree, there may be an increase of the H-ion concentration and a consequent damage to the tissues from the altered state of the blood; but in any moderate alteration of the blood, such as occurs in most cases of shock, it is probable that the diminished alkaline content in itself has no harmful influence.

On the other hand, no matter how the reduction of the alkali reserve is accounted for—either as a consequence of excessive production of acid or as a consequence of overbreathing, due to oxygen want—it is an indication of a fundamental difficulty occurring in the body, namely, an insufficient oxygen supply. We have already pointed out the need of continuous delivery of oxygen to the tissues. The failure of delivery of sufficient oxygen to the brain is likely to affect profoundly the normal metabolism of nerve cells in particular, and to lead to a disturbance of their functions. It becomes a matter of importance, therefore, to know at what point in an impaired circulation the oxygen delivery to organs becomes inadequate.

Although a reduction of blood volume affects to a great degree the volume-flow of blood to peripheral organs, as Gesell has proved, it is interesting to note that in several of the experiments which he reports [30] (Figs. 3 and 4), there is no marked reduction of the carbon dioxid content of arterial blood in a series of determinations, until the blood pressure falls to the neighborhood of 80 or 90 millimeters of mercury. Raymund [31] likewise has reported cases of experimental shock in which, after the initial reduction of the blood alkali attributable to etherization, a further reduction does not take place until the blood pressure falls below approximately 80 or 90 mm. of mercury. A similar relation is seen in several experiments performed by Henderson and Hag-

29. Dale and Richards: Report of the Shock Committee, English Medical Research Committee, October, 1918, Series No. 25, p. 250.

30. Gesell, R.: Am. J. Physiol. **47**:481 (Jan.) 1919.

31. Raymund, B.: Am. J. Physiol. **53**:127, 130 (Aug.) 1920; Figures 2, 3 and 5*b*.

gard.[32] These results are in interesting agreement with both experimental and clinical studies which were carried on in France. This concordant testimony has practical importance. In the first place, it signifies that, though the reduced volume-flow is a highly disturbing condition, the final touch in rendering the circulation inefficient is ascribable to a slowing of the blood flow as the arterial head of pressure falls. In the second place, the observation has significance because of the ease of determining the head of arterial pressure by clinical

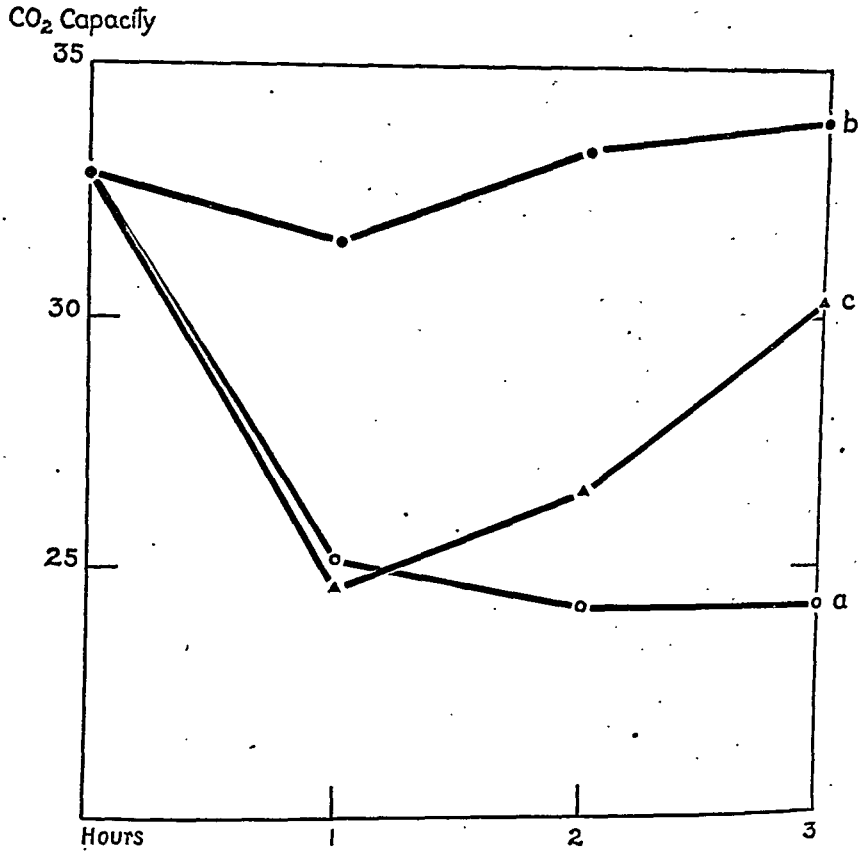

Fig. 2.—Changes in percentage by volume of carbon dioxid (the alkali reserve) of the blood plasma in cases in which the blood pressure was lowered to 60 millimeters of mercury for three hours; in *a* without other action, in *b* with previous injection of morphin, and in *c* with morphin injected after one hour of low pressure.

means and thus having a basis for a judgment as to whether the impairment of the circulation has reached a dangerous degree.

EXPERIMENTAL DETERMINATION OF THE CRITICAL LEVEL

In order to produce experimental conditions which would be as closely as possible analogous to those which analysis has shown to be

32. Henderson, Yandell, and Haggard, H. W.: J. Biol. Chem. **33**:365 (Feb.) 1918.

true for shock, and yet preserve the possibility of controlling accurately these conditions, we have made use of the arrangement illustrated in Figure 1, a modification of the method employed by Johansson and Tigerstedt[33] for recording the volume changes of the heart. Under artificial respiration, the thorax was opened between the ribs on one side at the level of the lower end of the sternum. A small slit was cut in the pericardium and a glass cannula tied in place. The thorax was then tightly closed and the animal allowed to breathe naturally. A small funnel was connected with the cannula by means of rubber tubing and filled with physiologic sodium chlorid solution or with 6 per cent. acacia in physiologic sodium chlorid solution. The pressure of the column of fluid was transmitted to the outside of the heart in the pericardial sac, and thus affected directly the filling of the organ and conse-

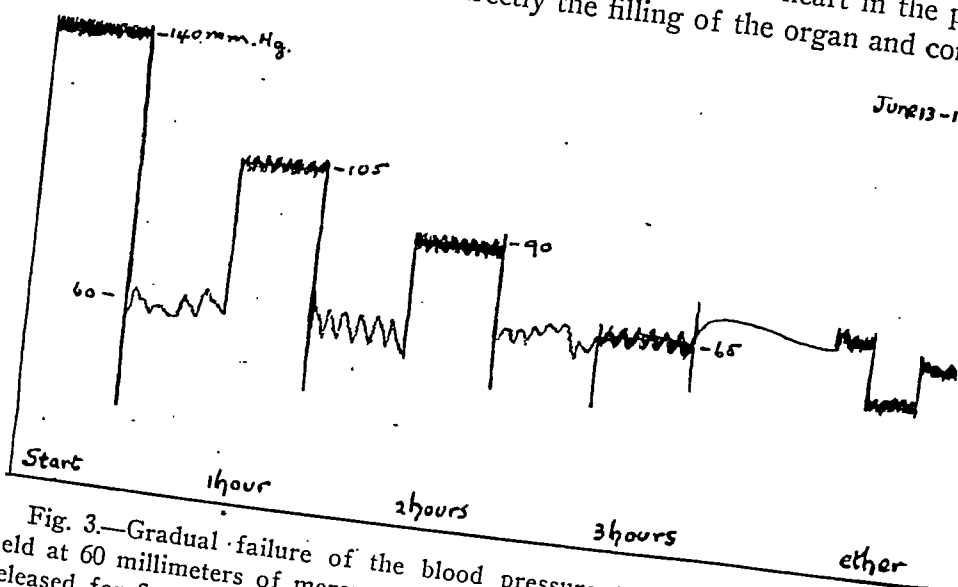

Fig. 3.—Gradual failure of the blood pressure to rise as the pressure is held at 60 millimeters of mercury for successive periods of one hour and then released for five-minute intervals.

quently its output. By raising or lowering the funnel, any desired arterial pressure could be produced and maintained. In a few experiments, the arterial pressure was regulated by compression of the heart by means of a clamp applied to the chest. This method gave similar results, but was inferior in that it interfered with the respiratory movements.

Most of the experiments were performed on cats; but in a few cases, rabbits or dogs were used. Ether was found to be a satisfactory anesthetic, for preliminary observations showed that under the conditions of our experiments it produced no effect on the alkali reserve. A cannula was placed in the pericardium to control the arterial pressure,

33. Johansson and Tigerstedt: Skandin. Arch. f. Physiol. 1:344. 1889.

as described above. The blood pressure was recorded by a mercury manometer connected with one carotid; a second cannula was placed in the other carotid or in the femoral artery to obtain samples for the bicarbonate determinations. For each determination, about 3 c.c. of blood was taken in a graduated tube, centrifuged, and the alkali reserve of the plasma determined by the Van Slyke [7] method. A sample of blood was usually taken immediately before reducing the blood pressure and at intervals of an hour throughout the course of the experiment. As a rule, no difficulty was experienced in keeping a constant arterial pressure at any desired level. Sometimes, just after reducing the pressure, it was necessary to adjust the funnel repeatedly in order to hold the arterial pressure constant, but usually an equilibrium was reached in a short time. A few experiments had to be discarded on account of irregularities in pressure.

Throughout the whole series of observations, a satisfactorily constant relation was found between the degree of reduction of the alkali reserve and the lowering of blood pressure. The most marked reduction was found at low pressures, whereas above 80 millimeters of mercury the state of the blood remained unchanged. These differences can be shown by a few illustrative protocols.

PROTOCOLS OF EXPERIMENTS

EXPERIMENT 2.—May 10, 1918, cat, 3.6 kilograms. Ether; cannula in both carotids.

10:08: Blood pressure 178 mm.; temperature 36 C.
10:22: Blood pressure 160 mm.
10:23: Sample A, 3 c. c. blood; carbon dioxid reading 39 per cent. by volume.
10:24: Blood pressure 160 mm.
10:26: Arterial pressure reduced to 80 mm. by external pressure on chest.
11:27: Sample B, 3.2 c. c. blood; carbon dioxid reading 37.
12:24: Sample C, 3.0 c. c. blood; carbon dioxid reading ?; sample lost.
12:57: Sample D, 3.5 c. c. blood; carbon dioxid reading 38.
1:29: Pressure reduced to 60 mm.
2:28: Sample E, 2.7 c. c. blood; carbon dioxid reading 35.
3:01: Pressure removed from thorax; blood pressure gradually rose until 4:00 when it reached 112 millimeters of mercury.
4:01: Sample F, 4.5 c. c. blood; carbon dioxid reading 40.

EXPERIMENT 3.—May 11, 1918, cat, 2.9 kilograms. Ether; cannulas in both carotids; cannula in pericardium.

9:51: Blood pressure 124 mm.
9:53: Sample A, 5.0 c. c.; carbon dioxid reading 30.
10:00: Blood pressure fell to 80 mm.; kept at the level by intrapericardial pressure.
11:02: Sample B, 4.5 c. c.; carbon dioxid reading 31.
11:04: Pressure reduced to 60 mm.
12:03: Sample C, 4.0 c. c.; carbon dioxid reading 20.

12:08: Intrapericardial pressure removed; blood pressure rose to 116 millimeters of mercury.

12:31: Sample D, 4.0 c. c.; carbon dioxid reading 25.

12:32: Pressure reduced to 70 mm.

1:31: Sample E, 4.5 c. c.; carbon dioxid reading 23.

EXPERIMENT 16.—May 25, 1918; dog, 6.73 kilograms.

7:35: Morphin 0.056 gm.

8:45: Operation started; cannula in pericardium; carotid cannulas.

9:50: Sample A, 3.0 c. c.; carbon dioxid reading 33.

9:52: Blood pressure 120 mm.

10:12: Blood pressure 116 mm.

10:17: Blood pressure reduced to 60 mm. by intrapericardial pressure (gum-salt).

11:17: Sample B, 4.5 c. c.; carbon dioxid reading 22.

12:22: Sample C, 6.0 c. c.; carbon dioxid reading 20.

1:22: Sample D, 6.2 c. c.; carbon dioxid reading 19.

2:31: Sample E, carbon dioxid reading 20.

TABLE 4.—BLOOD PRESSURE REDUCED TO 80 MM.

Exp.	Animal	Orig. Blood Pressure	Carbon Dioxid Reading			
			Start	1 Hour	2 Hours	3 Hours
5/10	Cat	178	39	37	..	38
5/11	Cat	124	30	31	..	..
5/15	Dog	80	35	35	..	..
5/16	Dog	160	20	20	17	..
			Av. 31.0	30.8		

TABLE 5.—BLOOD PRESSURE REDUCED TO 70 MM.

Exp.	Animal	Orig. Blood Pressure	Alkaline Reserve				
			Start	1 Hour	2 Hours	3 Hours	4 Hours
5/11	Cat	116	25	23	..	..	..
5/13	Cat	170	33	31	25	..	..
5/27	Cat	142	30	27	32	34	35
6/14	Cat	168	34	29	29	32	33
			Av. 30.5	27.5			

The results for the series of experiments are summarized in Tables 4, 5, 6, 7 and 8. Cases in which the blood pressure was reduced to 80 millimeters of mercury are given in Table 4. In every case, the alkali reserve was unaffected by pressure at this level for an hour. Table 5 shows the effects at 70 mm. pressure. Here there is a slight reduction in the alkali reserve—an average fall of 3 per cent. by volume of carbon dioxid. In the two cases in which observations were continued for four hours, a recovery took place. This occurred in a certain number of cases, even at lower blood pressures. The phenomenon will be referred to again. The next two tables present the results for an arterial pressure reduced to 60 millimeters of mercury, Table 6 giving

figures for cases in which the low pressure was continued for only one hour, and Table 7 for cases of low pressure for three hours. With this pressure, it will be noted that there was a marked fall in the alkali reserve during the first hour, indicating that the circulation was no longer adequate to maintain normal oxidation in the body. During the second hour, the average of the results shows a slight further fall; but during the third hour, there is no further change. Table 8, giving

TABLE 6.—Blood Pressure Reduced to 60 Mm. for One Hour

Exp.	Animal	Orig. Blood Pressure	Alkaline Reserve		
			Start	1 Hour	2 Hours
5/10	Cat	178	38	35	..
5/11	Cat	124	31	20	..
5/24	Rabbit	...	27	18	..
6/ 5	Cat	...	37	20	..
7/15	Cat	136	30	19	18
7/16	Cat	114	26	19	..
			31.5	21.8	

TABLE 7.—Blood Pressure Reduced to 60 Mm. for Three Hours

Exp.	Animal	Orig. Blood Pressure	Alkaline Reserve				
			Start	1 Hour	2 Hours	3 Hours	4 Hours
5/ 9	Cat	130	39	36	32	32	..
5/25	Dog	120	33	22	20	19	20
5/29	Cat	128	35	32	33	33	..
6/13	Cat	140	31	14	18	19	..
7/13	Cat	118	37	29	29	27	29
7/20	Cat	109	33	30	25	27	..
			34.7	27.1	26.1	26.1	

TABLE 8.—Blood Pressure Reduced to 50 Mm.

Exp.	Animal	Orig. Blood Pressure	Alkaline Reserve			
			Start	1 Hour	2 Hours	3 Hours
5/28	Cat	174	27	14	11	..
6/ 5	Cat	...	37	19	..	..
7/18	Cat	86	28	20	23	21
7/23	Cat	96	41	29	..	17
			Av. 33.2	20.5		

effects of the reduction of the blood pressure to 50 millimeters of mercury, reveals a still greater fall in the alkali reserve; at the end of one hour, the percentage by volume of carbon dioxid reached the low figure of 20.5.

An examination of the data presented in the accompanying tables shows a normal bicarbonate reserve in the cat of from 39 to 25, the average being about 32. This is a much lower figure than that found in normal human plasma, where a reading below 50 is generally considered to be pathologic. The most rapid fall in the alkali reserve occurs

during the first hour of reduced pressure, after which it soon reaches a stationary low level. In a few cases, there is an actual recovery after several hours. It may be that by lessened cellular activity the organism adapts itself to the condition of low pressure; and then, because the oxygen requirement becomes less, the acids may be reduced by oxidation. There is another possibility which might be considered. Clearly, if the pressure is artificially kept constant throughout an experiment, it is possible that after several hours a peripheral dilatation takes place, due to lessened vasomotor tone or to direct effect of metabolites, and thus with a constant pressure the blood flow would be increased.

The alkali reduction produced by an inadequate circulation is not permanent, but rapidly disappears when the blood pressure is allowed to return to normal, as is shown above in the first two protocols. In a number of other instances, the blood pressure was raised by injection of gum-salt solution, and the alkali reserve was restored.

TABLE 9.—RESULTS OBTAINED IN FOUR ANIMALS IN WHICH PRESSURE WAS REDUCED TO 80 OR 90 MM. AFTER REMOVING 20 PER CENT. OF BLOOD

	Blood Pressure		Alkali Reserve		
Exp.	Orig.	Final	Start	1 Hour	2 Hours
5/14	175	80	31	26	23
5/21	150	80	20	16	..
5/23	100	90	37	35	35
6/16	150	90	33	33	..

Many cases of low blood pressure in wounded men were complicated by hemorrhage. The question arose as to whether loss of blood modified the critical level of the blood pressure. This was somewhat difficult to determine experimentally because in many animals the combination of an operation and the loss of blood reduces the blood pressure below the desired level. Satisfactory results were obtained in four animals (Table 9). In each case, they were bled 20 per cent. of their calculated blood volume before reducing the pressure. The two cases with arterial pressure reduced to 80 millimeters of mercury showed marked indications of an inadequate circulation, while those with a reduction to only 90 mm. showed less effect. It seems probable, therefore, that when hemorrhage complicates a low blood pressure the critical level is higher than when no loss of blood has occurred.

From these experimental results we conclude that the *critical level,* that is, the level at which the blood pressure is no longer capable of maintaining an adequate volume-flow to the tissues, and thus serving the normal oxidations of the body, is *approximately* 80 millimeters of mercury. Above 80 mm. reduction of the alkali reserve is not likely to appear; but as the pressure falls below this, a reduction will probably occur, which is more marked and develops the more rapidly the lower

the pressure. If there has been a loss of blood, the circulation becomes inadequate before the pressure falls to 80 millimeters of mercury, i.e., the critical level is raised. In this connection, the observations of Markwalder and Starling[34] are of interest. They found experimentally that cardiac contraction begins to weaken when the arterial pressure falls below 90 millimeters of mercury. Gruber[35] noted a marked decrease in the height of contraction of muscle which was being uniformly stimulated when he reduced the blood pressure to 90 millimeters of mercury. Above this level, however, changes in pressure produced practically no effect on muscular contraction. The results reported by Gesell, by Raymund and by Henderson and Haggard, mentioned above, likewise point to a pressure of 80 or 90 millimeters of mercury as being necessary for a sufficient blood flow.

Aub has studied the decrease of the metabolic rate in shock. In eight cases of severe shock, the average decrease was 33 per cent.[28] It was a matter of interest to learn whether the fall of metabolism was related in any way to the critical level of arterial blood pressure, as indicated by the appearance of acidosis. Aub found, indeed, that as a rule the critical level for metabolism was associated with a blood pressure in the neighborhood of 75 or 80 millimeters of mercury. At that level, the metabolism might be within the normal rate of variation; but usually when this was the case, the blood pressure had been remaining stationary or was rising. In other instances, he noted that when the blood pressure was at this level, or occasionally higher, the metabolism might be considerably reduced; but when this was the case, the blood pressure was in the process of falling. With a blood pressure below 75 millimeters of mercury the metabolism was invariably reduced beyond the common normal variations. These observations are confirmatory of the evidence already adduced in placing the threshold of adequacy of arterial pressure at approximately 75 or 80 millimeters of mercury.

THE EFFECT OF MORPHIN

As shown in Table 7, reduction of the blood pressure to 60 millimeters of mercury for three hours causes a marked and lasting reduction of the alkali of the blood plasma. Experiments performed by one of us (M.C.) at Dijon proved that morphin can modify this effect in a striking manner. A comparison of the average figures in Tables 10 and 11 with those in Table 7 is given graphically in Figure 2. The curves of each condition have been shifted so that they have a common initial point at the average of the first readings (32.8). Figure 2 *a* represents the results detailed in Table 7—a fall and continued low level of the

34. Markwalder and Starling: J. Physiol. **47**:279, 1913.
35. Gruber: Am. J. Physiol. **32**:227, 1913.

blood alkali when the blood pressure is held down to 60 millimeters of mercury. Figure 2 *b* represents Table 11, and Figure 2 *c* Table 10. In the former case, morphin sulphate (20 mg. per kilogram) was given subcutaneously just before the pressure was lowered; the alkali reserve was not reduced. In the latter case, it was given after the pressure had been kept at 60 mm. for one hour; the alkali reserve, which had fallen as in *a*, began to rise, and after two hours was largely restored.

TABLE 10.—EFFECTS OF MORPHIN GIVEN ONE HOUR AFTER REDUCTION OF BLOOD PRESSURE TO 60 MILLIMETERS OF MERCURY

Exp.	Animal	Orig. Blood Pressure	Alkaline Reserve				
			Start	1 Hour	2 Hours	3 Hours	4 Hours
6/ 7	Dog	138	24	15	11	12	18
6/ 8	Dog	128	23	16	20	22	23
6/10	Cat	150	35	21	27	29	34
6/17	Cat	120	35	35	37	42	..
6/18*	Cat	118	30	20	21	31	..
6/19*	Cat	150	32	23	23	28	..
6/20	Cat	156	36	21	23	22	22
6/24	Cat	120	26	24	29	35	36
		Av.	30.1	21.9	23.9	27.6	

TABLE 11.—EFFECTS OF MORPHIN GIVEN JUST BEFORE REDUCING BLOOD PRESSURE TO 60 MILLIMETERS OF MERCURY

Exp.	Animal	Orig. Blood Pressure	Alkaline Reserve				
			Start	1 Hour	2 Hours	3 Hours	4 Hours
6/26	Cat	100	32	34	39	37	35
6/27	Cat	134	35	32	36	37	39
6/29	Cat	142	29	27	27	31	33
7/ 8	Cat	114	41	33	35	34	..
10/27*	Cat	128	30	34	33	32	..
10/29*	Cat	120	34	33	34	37	35
		Av.	33.5	32.2	34.0	34.7	

The explanation of this conserving influence of morphin is still obscure. Henderson and Haggard[27] have reported that when, by means of morphin, respiration is depressed and the alveolar carbon dioxid is raised, the alkali reserve of the blood also rises; and they suggest that this rise is due to a passage of alkali from the tissues into the blood to compensate for the increase in carbonic acid. The reactions represented in Figure 2 *b* and *c*, however, occur in animals in which the breathing is kept mechanically regular by artificial respiration. In Table 10, the experiments of June 18 and 19, and in Table 11, the experiments of October 27 and 29 (marked by asterisks) were of this character. They do not differ in nature from the other experiments in the series in which the respiratory mechanism of the animal was allowed to function. It seems, therefore, that slowing of the respiration is not solely responsible for the preservation of the normal alkali reserve.

EVIDENCE OF DAMAGE TO THE CENTRAL NERVOUS SYSTEM FROM LOW BLOOD PRESSURE

The testimony that insufficient blood supply injures the elements of the central nervous system is both morphologic and functional.

Morphologic changes as a consequence of diminished blood flow have been reported by Dolley,[45] who found that after repeated hemorrhage the Purkinje cells of the cerebellum underwent a sequence of alterations exactly identical with those observed in shocked animals. Mott[46] has reported studies of the cell changes in cases of shock in which some hours before death there was low blood pressure, and has found that there is general chromatolysis, a change which he attributes to the prolonged anoxemia. Besides the chromatolysis, Mott noted that many of the cells of the medulla and also some of the Purkinje cells show a tendency to profuse purple staining when a double stain, such as a basic blue and eosin dye, is used. This alteration in the staining reaction denotes a biochemical change, possibly different in character from that associated with the diffusion of the Nissl substance.

The functional evidence of injury to the nervous system from low blood pressure has come mainly from examination of disturbances in vascular reflexes during the development of shock. W. T. Porter and his collaborators proved that after a prolonged low blood pressure in shocked animals stimulation of afferent nerves could cause either a rise or fall of blood pressure.[47] They concluded, therefore, that even in extreme shock the vasomotor center is still active. It was not, however, until perfusion experiments were performed on peripheral vessels still connected with the vasomotor center that direct proof was obtained showing whether the center was overactive or underactive. Such perfusion experiments conducted by Erlanger, Gesell and Gasser,[48] and more recently by Cattell,[49] have demonstrated that although in the early stages of shock, whether due to abdominal injury or to crushing of muscle, the vasomotor tone is increased. In the later stages, there is practically invariably diminished tone and lessened peripheral resistance. The tendency of the vasomotor center, when the blood pressure becomes low, is to compensate by increased activity. The failure of the center to respond thus to the stimulus of a low pressure in the late stages of shock must be regarded, therefore, as signifying that the center has become injured to such a degree that it is incapable of responding.

---

45. Dolley: J. M. Research, **16**:96, 1909.
46. Mott: Report of the Shock Committee, English Medical Research Committee, March, 1919, Series No. 26, p. 46.
47. Porter, W. T.: Am. J. Physiol. **20**:399, 1907; ibid. **20**:500, 1908.
48. Erlanger, J.; Gesell, R., and Gasser, H. S.: Am. J. Physiol. **49**:151 (July) 1919.
49. Cattell, McKeen, quoted by Cannon, W. B.: Arch. Surg. **4**:1 (Jan.) 1922.

Bayliss [50] has pointed out that the vasomotor center is not the only bulbar center that suffers from low blood pressure and the consequent sluggish blood flow. He noted that when the average blood pressure remained below 58 millimeters of mercury in cats, not only were vasomotor reflexes abolished but the rate of respiration fell to 6 or less per minute. Various other experiments showed that when the blood pressure was less than 70 millimeters of mercury from one and a half to two hours, more or less, a paralysis of the bulbar centers would occur. The respiratory center in the cat appears to suffer before the vasomotor center, though it may continue to discharge at the slow and ineffective rate of 3 or 4 per minute when the vasomotor center has lost its excitability. Bayliss suggests that different animals probably behave differently as regards the order in which their vital centers fail and that in man the vasomotor center may begin to lose its functional stability before the respiratory center.

In order to secure evidence as to the progressive nature of the damage done to the nervous control of the circulation in consequence of an insufficient blood flow, we have made observations on the effects of reducing the blood pressure to 60 millimeters of mercury for varying times by the method of intrapericardial compression of the heart (see p. 314). When the pressure had been thus reduced to that level it was held there for an hour. The compression of the heart was then released by lowering the fluid column. Usually, when this is done, the blood pressure will be restored completely or nearly completely to its normal level (Fig. 3). If then the pressure is again lowered to 60 mm. and held there for an hour, it does not rise so high; and when held to this low level for another hour, it may not rise at all.

It might be supposed that the failure of the pressure to rise after being held persistently low for three hours would be due to a loss of blood volume by escape of plasma into the tissues through more permeable capillary walls. Observations with the hematocrit in these cases, however, suggest that this was not an important factor. In Table 13 are the average hematocrit readings when the pressure was reduced to different levels and held there for periods of one, two and three hours. As the figures clearly show, the percentage of corpuscles gradually fell, indicating that there was a dilution, rather than a concentration, of the arterial blood.

The explanation which appears most reasonable to account for the failure of the pressure to rise after persistence at the low level is that the nervous agencies which control the circulation have suffered damage —a damage due to inadequacy of the circulation itself. The reason-

50. Bayliss, W. M.: Intravenous Injections in Wound Shock, London, New York, Longmans, Green & Co., 1918, p. 11.

ableness of the conclusion is supported by observations on relaxation of vascular tone in late shock,[49] and by tests of the responsiveness of the vasomotor center to stimulation by asphyxia. At an early stage in shock, there may be an asphyxial rise of pressure, and later, though the heart still beats and respiration is still active, the asphyxial rise does not occur, i. e., the vasomotor cells are no longer excited by the blood

TABLE 13.—HEMATOCRIT READINGS AFTER REDUCTION OF THE BLOOD PRESSURE BY INTRAPERICARDIAL COMPRESSION

No. of Cases	Pressure Reduced to Mm. Hg	Average Hematocrit Readings (Percentage of Corpuscles)			
		Start	1 Hour	2 Hours	3 Hours
4	70	47	46	46	47
12	60	40	37	31	27
4	50	38.5	34.5	26	26

changes. LaCroix[51] has noted that in cases of shock after severe wounds there may be total immobility of the pupil, no matter how intense the light. This failure of the pupillary reaction points to a block of the nerve impulses along the reflex path involved in the reaction and is further indication of injury to the nervous elements.

IMPORTANCE OF THE TIME FACTOR IN THE DEVELOPMENT OF SHOCK

Experiments cited above have definitely proved that with an acute lack of oxygen nerve cells abruptly cease to function. The loss of consciousness when one faints is a common example of the close dependence of nervous elements on continuous oxygen supply. The experimental and clinical observations on the effects of prolonged low pressure point to the fact that these sensitive cells may be gradually harmed, if, instead of acute anemia, there is prolonged partial anemia.

The gradually damaging effect of persistent low blood pressure is of the utmost importance both in understanding and in treating shock. When the vasomotor center has lost its capacity to maintain vascular tone, there is no sort of remedial agent which can be applied to bring the blood flow back to its normal condition. If, in an animal, the medulla is destroyed, the blood pressure falls to approximately 40 millimeters of mercury and there remains. Intravenous injections of blood or other fluid will raise the pressure for only a few moments. An incredible amount of fluid may thus be introduced into the vessels without any lasting rise of pressure. When a man has been in a state of shock for a long time, so that the vasomotor center fails to hold the blood vessels in a state of moderate contraction, he reacts much as the experimental animal does when the bulbar centers are destroyed.

51. La Croix: Bull. et mém. Soc. de Chir. de Paris, 44:906, 1918.

Transfusion leads to no permanent gain—the beneficial effect is fleeting. When that stage has been reached, the secondary harm from insufficient oxygen has been too great to permit resuscitation.

The foregoing considerations emphasize the prime importance of early treatment of the low blood pressure of shock. As Pike and Coombs [52] have stated, injured nerve cells require a better blood supply for their restoration than uninjured nerve cells do for their maintenance. Thus, though the tissues may not suffer until blood pressure has fallen below a critical level of approximately 80 millimeters of mercury, it is desirable, when the pressure has fallen below this level and has shown no evidence of rising, that it be raised to the normal level of 120 millimeters of mercury, if possible, in order to provide the most favorable conditions for repair of the damage which has been done.

---

52. Pike, F. H., and Coombs, H. C.: Relation of Low Blood Pressure to a Fatal Termination in Traumatic Shock, J. A. M. A. **68**:1892 (June 23) 1917.

POSTOPERATIVE INTRA-ABDOMINAL HERNIA

CHARLES H. MAYO, M.D.

AND

JAMES A. H. MAGOUN, JR., M.D.

Fellow in Surgery, Mayo Foundation

ROCHESTER, MINN.

Moynihan,[1] in his monograph on retroperitoneal hernia, directs attention to the possibility of herniation of the small intestine into the lesser peritoneal cavity through an abnormal aperture in the transverse mesocolon. Four such hernias have been reported, one by Boettcher[2] in 1878. In 1885, von Hacker[3] suggested the advisability of performing a gastrojejunostomy by the posterior route, making the anastomosis in the posterior wall of the stomach through an opening in the transverse mesocolon. Thus, seven years before the retrocolic method of gastrojejunostomy was advocated, attention had been directed to the possibility of the small bowel herniating through an opening in the transverse mesocolon. This fact, evidently, was lost sight of, because it was only after fatalities from such hernias that surgeons began to suture the stomach or jejunum to the transverse mesocolon. Mayo-Robson,[4] Moynihan,[1] Mikulicz,[5] and others have reported cases of this type. In the older textbooks,[6] suturing the opening in the transverse mesocolon to the stomach or jejunum before making the anastomosis (between the stomach and the jejunum) was advised. Of late years, this procedure has been reversed: the anastomosis is made first, and the sutures are placed afterward. MacArthur,[7] however, for some time has reverted to the older method, considering it more advantageous to close the opening before performing the anas-

1. Moynihan, B. G. A.: Retroperitoneal Hernia, Ed. 2, London, Bailliere, Tindall and Cox, 1906, pp. 162-163.

2. Boettcher, A.: Hernia bursae omentalis mit im Mesocolon Transversum befindlicher Bruchpforte, Arch. f. path. Anat. u. Physiol. u. f. klin. Med. **72**:642-644, 1878.

3. Von Hacker: Zur Casuistik und Statistik der Magenresectionen und Gastro-enterostomieen, Arch. f. klin. Chir. **32**:616-625, 1885.

4. Mayo-Robson, A. W., and Moynihan, B. G. A.: Diseases of the Stomach, London, Bailliere, Tindall and Cox, 1904, pp. 257-258.

5. Von Bergmann, E.: von Bruns, P., and von Mikulicz, J.: System of Practical Surgery, Philadelphia, Lea & Febiger **5**:439, 440, 444, 1904.

6. Von Bergmann, E.; von Bruns, P., and von Mikulicz, J.: Footnote 5. Kocher, T.: Operative Surgery, London, Adam and Charles Black, 1911, p. 571. Bryant, J. D.: Operative Surgery, New York, D. Appleton & Co. **2**:913, 1905.

7. MacArthur: Personal communication.

tomosis, for in this manner the posterior portion of the aperture may be securely closed.

As the number of gastrojejunostomies increased, another form of internal hernia was observed. The small intestine slipped behind the loop of jejunum which is formed by every anastomosis, whether it is antecolic or retrocolic. Mikulicz [5] recognized this and stated that the symptoms produced were due to compression of the root of the mesentery rather than to incarceration of the intestine. Mayo-Robson and Moynihan,[4] in speaking of a case occurring after anterior gastrojejunostomy, reported by W. J. Mayo,[8] say, "The passage of the small intestine through the loop formed by the juncture of the jejunum and stomach is probably only possible, certainly only probable, after the anterior operation."

Moschcowitz and Wilensky,[9] in 1915, collected seven cases from the literature reported by Steudel,[10] Petersen,[11] W. J. Mayo,[8] Gray,[12] Gordon,[13] and Barker,[14] and one of their own. Bryan,[15] in 1920, reported a similar case occurring twelve days after posterior gastrojejunostomy, in which the small intestine had passed from right to left, behind the anastomosis. The hernia was reduced by operation. Four days later, a similar herniation occurred and a third operation was necessary. The patient recovered. Deaver and Ashhurst [16] reported a case, without details. They consider that the complication is more likely to occur after a long loop posterior gastrojejunostomy than after a short loop.

A summary of the ten cases reported from the literature shows that the hernia occurred in six cases following the posterior type of gastrojejunostomy (four with short loops and two with long loops); in two cases following the anterior type, and in two the type was not given.

---

8. Mayo, W. J.: Complications Following Gastro-Enterostomy, Ann. Surg. **36**:231-244, 1902.

9. Moschcowitz, A. V., and Wilensky, A. O.: Intestinal Obstruction Consecutive upon Posterior Retrocolic Gastro-Enterostomy, with Description of a Method to Avoid Similar Complications, Surg., Gynec. & Obst. **21**:390-393, 1915.

10. Steudel: Die in den letzten Jahren an der Czernyschen Klinik ausgeführten Magenoperationen und die Endresultate der früheren Operationen, Beitr. z. klin. Chir. **23**:1-88, 1899.

11. Petersen, W.: Ueber Darmverschlingung nach der Gastro-Enterostomie, Arch. f. klin. Chir. **12**:94-114, 1900.

12. Gray, H. M. W.: A Cause of Intestinal Obstruction After Gastro-Enterostomy, Lancet **2**:526, 1904.

13. Gordon: Lancet **2**:1477, 1905.

14. Barker, A. E.: A Remarkable Sequel to a Case of Gastro-Enterostomy, Lancet **2**:1277-1278, 1904.

15. Bryan, R. C.: Recurrent Internal Hernia Following Gastro-Enterostomy, Surg., Gynec. & Obst. **30**:82-85 (Jan.) 1920.

16. Deaver, J. B., and Ashhurst, A. P. C.: Surgery of the Upper Abdomen, Philadelphia, P. Blackiston's Son & Co. **1**:435, 1909.

The more frequent occurrence of the hernia following the posterior operation might seem ambiguous were it not explained by the fact that a far greater number of posterior gastrojejunostomies are performed than anterior.

In seven cases, the hernia started on the right side and traveled toward the left. In one case it started on the left side and traveled toward the right. The time elapsing between the gastro-enterostomy and the second operation was six days in four cases; eight days in one; twelve days in two; fourteen days in one; one year in one, and two years in one. Four patients died, and four recovered; the final results were not stated with regard to two. We have not found, in the literature, mention of this form of internal hernia following colostomy. The possibility that this catastrophe may follow the Polya operation, anterior or posterior, should, however, be considered. Two cases of internal hernia following gastrojejunostomy, and one following colostomy are reported herewith.

REPORT OF CASES

CASE 1 (A 357800).—*History.*—Mr. R. D., aged 35, came to the clinic, May 11, 1921, complaining of having had a dull, heavy feeling in the epigastrium for ten years. The pain occurred from three to four hours after meals, and was relieved by food and soda. The patient was nauseated but did not vomit. The attacks lasted for about one month; he was then perfectly well for about six months. The bowels had been constipated for ten years.

Examination.—The patient had lost 11 pounds (5 kg.) in six months. The systolic blood pressure was 124 and diastolic 76. The urine contained an occasional red blood cell. Blood examination revealed: hemoglobin 77 per cent.; erythrocytes, 4,690,000, and leukocytes, 9,300. The Wassermann reaction was negative. Examination of the gastric contents revealed: total acids, 42, and free hydrochloric acid, 40. Duodenal ulcer was revealed by the roentgen ray.

Operation.—May 18, 1921, an ulcer was found on the anterior wall of the duodenum just below the pylorus. It was impossible to perform a posterior gastro-enterostomy on account of the short mesentery of the transverse colon. The jejunum was brought up over the colon (12-inch [30.5 cm.] loop), and attached to the stomach, making an anterior gastro-enterostomy. The stomach and gallbladder appeared to be normal. The appendix, which was chronically inflamed, was removed.

Course.—The first three days of convalescence were uneventful. On the evening of the third day, however, the patient felt nauseated. The stomach tube was passed and 15 ounces (444 c.c.) of bile-stained fluid was recovered. During the night, he hiccuped and frequently vomited small amounts of bile-stained fluid. The stomach tube was passed in the morning, and 24 ounces (710 c.c.) of the same kind of material was obtained. The evening of the fourth day, only one-half ounce (15 c.c.) of greenish material was recovered and the patient appeared to be better. On the following day, he was able to take ginger ale without nausea or vomiting. His condition remained about the same until the morning of the eighth day when 12 ounces (355 c.c.) of

greenish fluid was recovered by the stomach tube. One ounce of castor oil was given, which was promptly vomited. The morning of the ninth day, the patient vomited 2 ounces (59 c.c.) of dark green fluid; and a few hours later 24 ounces (710 c.c.) was recovered by the stomach tube. The patient continued to be nauseated, and his general appearance indicated mechanical obstruction. The abdomen was opened and the condition described below was found.

The upper jejunum at a point distal to the gastro-enterostomy had slipped from right to left through the opening between the mesentery of the jejunum at the point where the gastro-enterostomy had been made and the transverse mesocolon. The entire small intestine from this point down to within a few inches of the ileocecal valve had followed the jejunum through the opening and was lying on the left side. This had produced torsion on the mesentery; and the jejunum for a distance of 1½ feet (46 cm.) distal to the gastro-enterostomy was quite dark and distended. The intestine was pulled back through the opening and the obstructed bowel immediately regained its normal color. The opening through which the bowel had slipped was closed with interrupted catgut sutures. The gastro-enterostomy was adherent to the anterior abdominal wall and to the tissues surrounding it; and in elevating the stomach, the jejunum was separated from the stomach along the suture line of the gastro-enterostomy. This opening, which was about 2 cm. long, was closed with two rows of chromic catgut. The loop of jejunum lying proximal to the gastro-enterostomy was not involved in the obstruction. When the wound was opened, seropurulent material appeared in the subcutaneous and deep tissues. The opening, which was made through the former incision, was closed with difficulty. The patient did not recover (Fig. 1).

Case 2 (A 111382).—*History.*—Mr. J. C., aged 54, came to the clinic, July 25, 1914. He had complained of a dull aching pain in the epigastrium for two months. He had belched gas freely and his bowels had been constipated. The night before examination, he had taken a saline laxative. At 4 o'clock the following morning he was awakened with a very severe knifelike pain in the middle of the epigastrium, accompanied by vomiting. The abdomen was rigid; and two hypodermic injections of ¼ grain (0.016 gm.) of morphin gave no relief. A diagnosis of perforating duodenal ulcer was made. At operation, an acute perforating ulcer of the duodenum was found. The perforation was closed with silk sutures and a posterior gastro-enterostomy (Mayo) was performed. The patient was well Aug. 23, 1920, when he had a sudden seizure of severe abdominal pain in the region of the umbilicus. He vomited a brownish, foul material continuously. He was given enemas and a purge by his family physician without relief.

Examination.—This revealed rigidity of the muscles of the upper left abdominal quadrant and tenderness to the left of the umbilicus. A provisional diagnosis of acute obstruction was made.

Operation.—Through a high rectus incision the upper jejunum, just distal to the gastro-enterostomy, was found to have slipped back between the portion of the jejunum which had been left between the origin of the jejunum and the point where the gastro-enterostomy was made and the transverse mesocolon. The entire jejunum and more than half of the ileum had followed this loop through the opening. The bowel was in good condition and was not discolored. There was a small amount of bloody fluid in the abdominal cavity. The bowel was pulled back and a few sutures were placed between the mesentery, at the

origin of the jejunum and the transverse mesocolon, so as to close the opening. The patient's recovery was uneventful (Fig. 2).

CASE 3 (A 348789).—*History.*—Mr. A. M., aged 61, was examined Feb. 8, 1921. He had been operated on elsewhere in December, 1920, for hemorrhoids, and the diagnosis of cancer of the rectum was made. After the operation, there was less pain on defecation, but blood and mucus persisted.

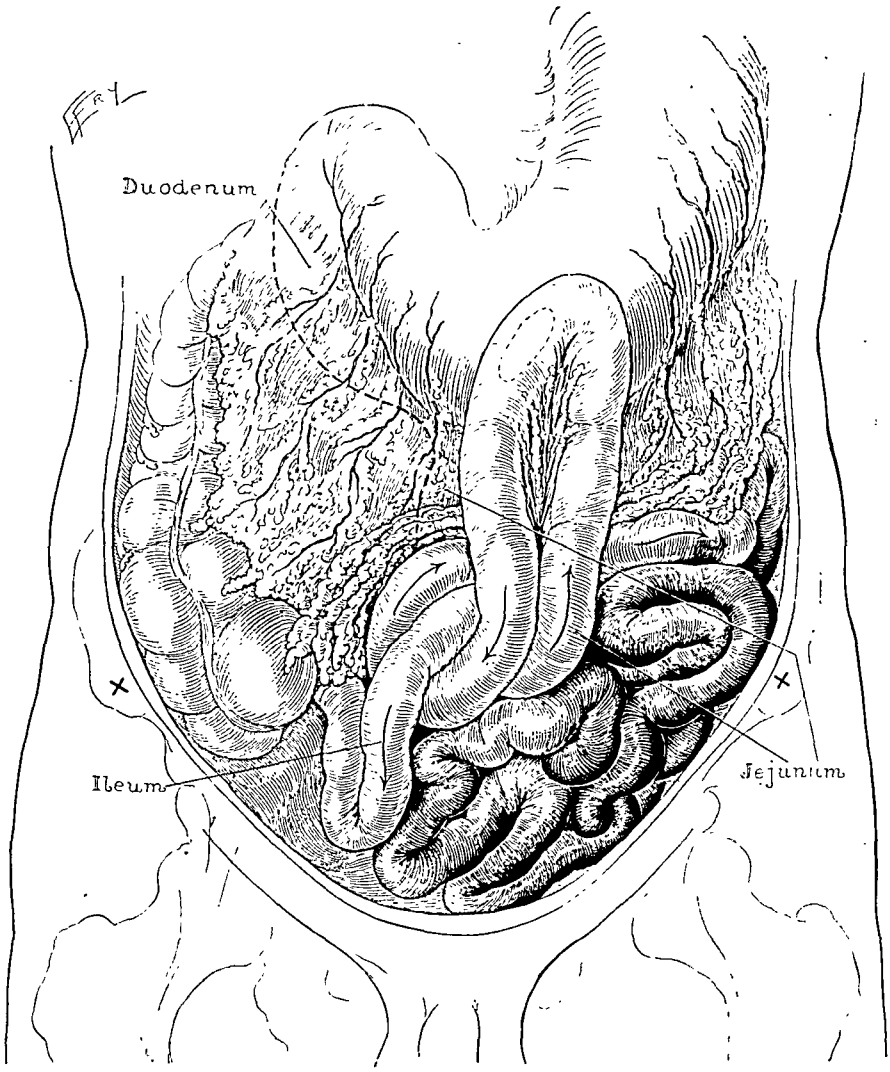

Fig. 1.—Hernia of the small intestine behind anastomotic loop of jejunum, following anterior gastrojejunostomy.

Examination.—The patient appeared to be fairly well nourished. The blood pressure was 154 systolic and 90 diastolic. The thyroid was enlarged. A large papillary mass appeared in the rectum. The urine showed a trace of albumin. Blood examination revealed: hemoglobin, 70 per cent.; erythrocytes, 4,500,000; leukocytes, 7,500. Roentgen-ray examination of the chest for metastasis was negative.

Operation and Result.—Feb. 17, 1921, a left rectus colostomy (Sistrunk method) was performed. The patient's convalescence was uninterrupted for six days, when his abdomen became markedly distended, especially on the left side. He passed very little gas and vomited greenish material several times. His pulse was 120, his temperature was subnormal.

A second operation was performed, February 26. The small intestine was greatly distended. The cecum and ascending colon were empty. Exploration

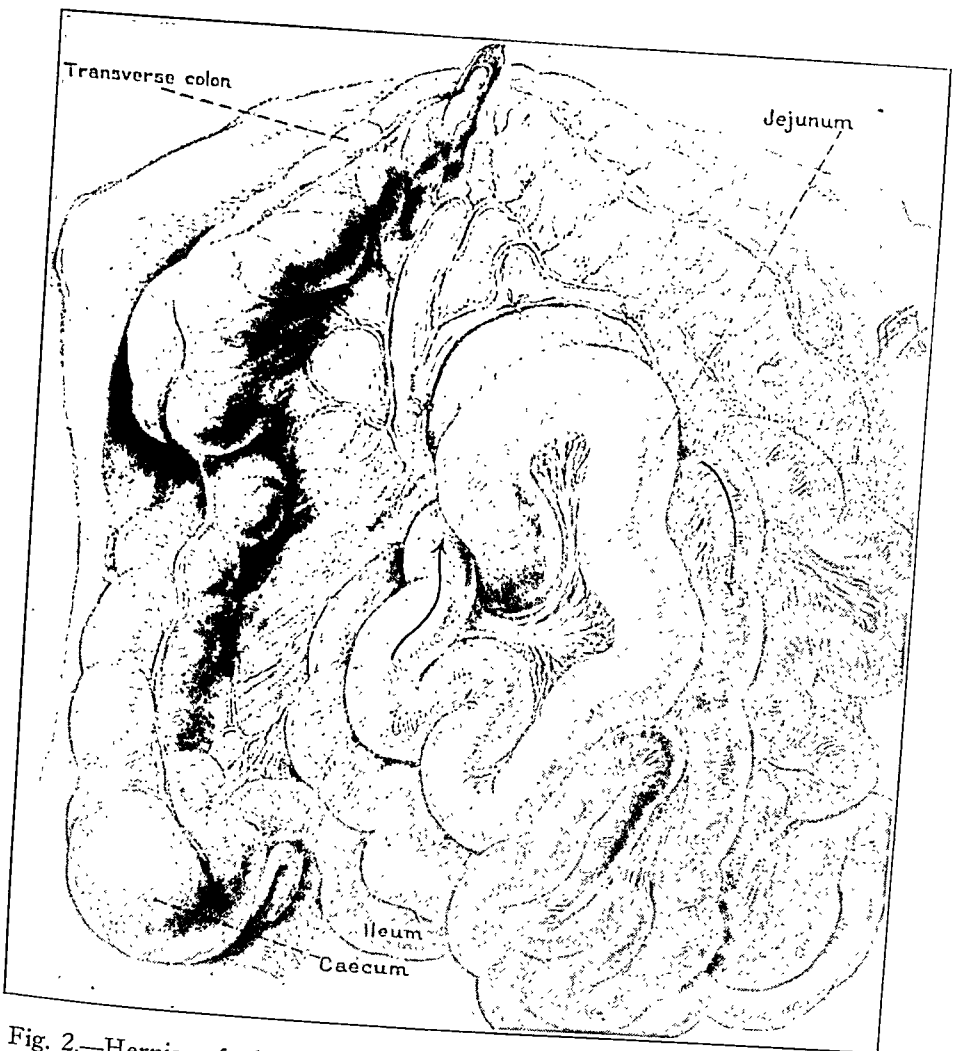

Fig. 2.—Hernia of the small intestine behind short anastomotic loop of jejunum following posterior gastrojejunostomy.

revealed that the entire small intestine had crawled completely around the colostomy (attachment of the sigmoid in the colostomy). The intestine, which was black, was reduced with difficulty and the abdominal wound was closed with through-and-through sutures. Color returned to the intestine after the reduction. Considerable free fluid was found in the peritoneal cavity. Following the operation, the patient was given an intravenous injection of 400 c.c. of saline solution. He failed to rally and died the same day (Fig. 3).

COMMENT

The symptoms from this type of internal hernia do not appear to differ from the usual symptoms of high intestinal obstruction of acute onset. The complication is more likely to occur in cases in which some form of chronic obstruction has distended and enlarged the loops of bowel.

To prevent this form of intra-abdominal hernia, Moschcowitz and Wilensky advised suturing together the margins of the opening, using

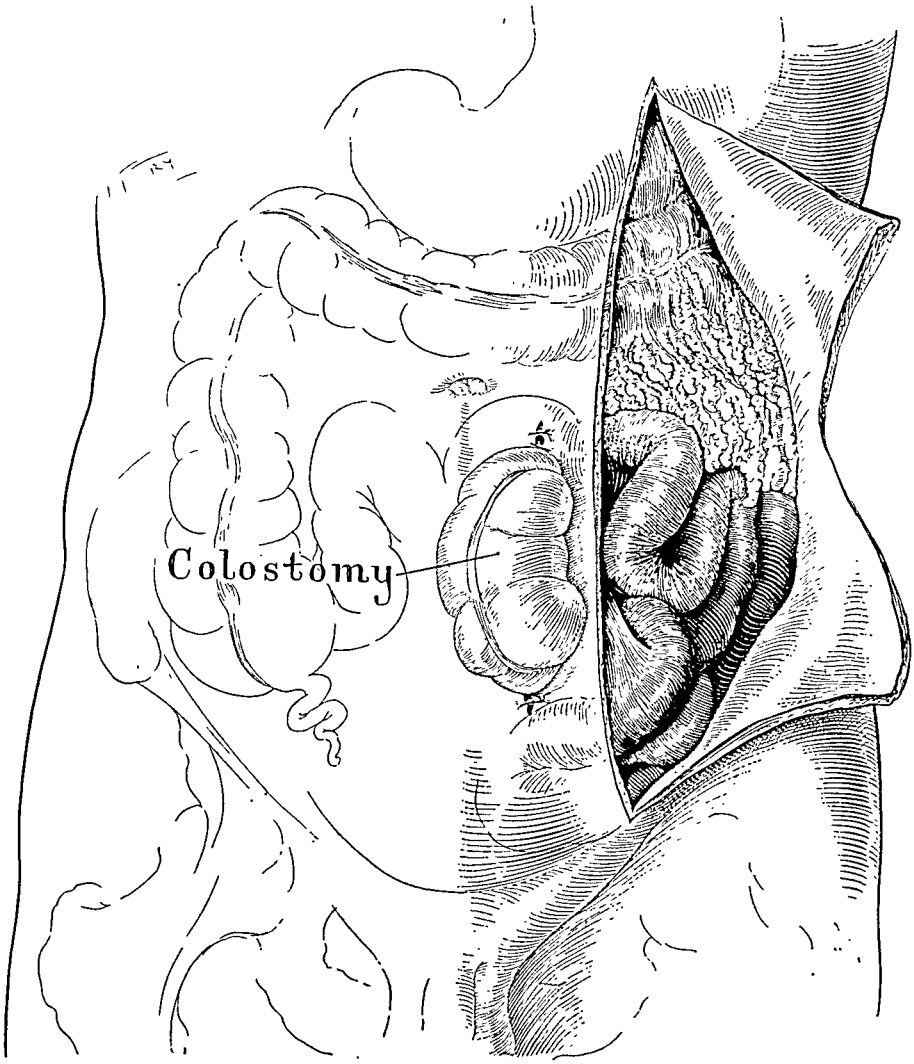

Fig. 3.—Hernia of the small intestine around colostomy.

the afferent loop of the jejunum and the inferior leaf of the mesentery. Bryan sutured the small intestine to the right lateral abdominal wall with several silk sutures. The latter method, however, should not be advocated. The practice followed in the clinic is described below:

In the anterior type of gastrojejunostomy, the abdominal toilet is carefully completed before the abdomen is closed. It is noted that no

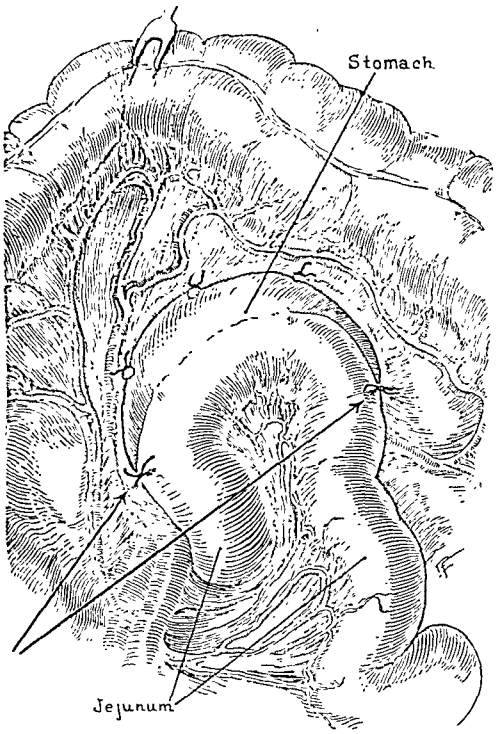

Fig. 4.—The arrows indicate the position of the sutures which would prevent the hernia shown in Figure 2.

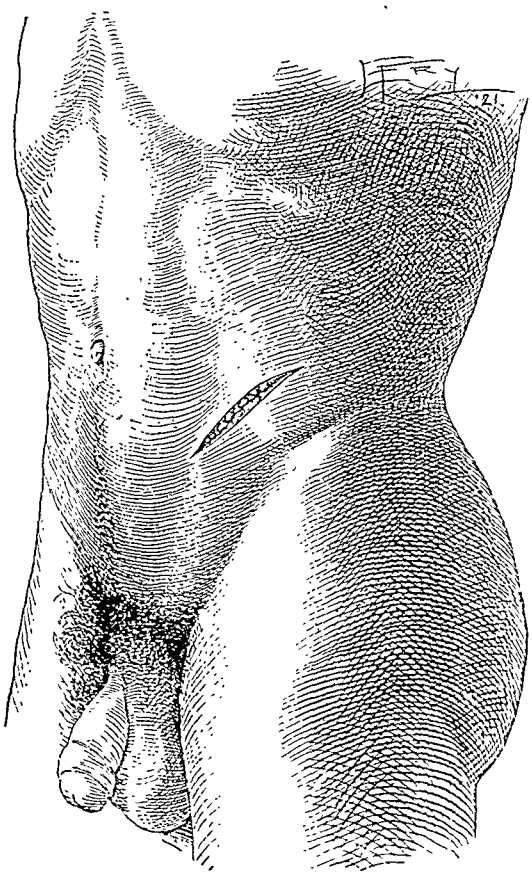

Fig. 5.—Incision for colostomy.

loop of bowel has passed behind the anastomosis either from right to left or from left to right. The omentum is placed around the loop of the anastomosis as securely as possible. Whether or not several sutures should be placed between the mesentery of the loop and the omentum is an open question.

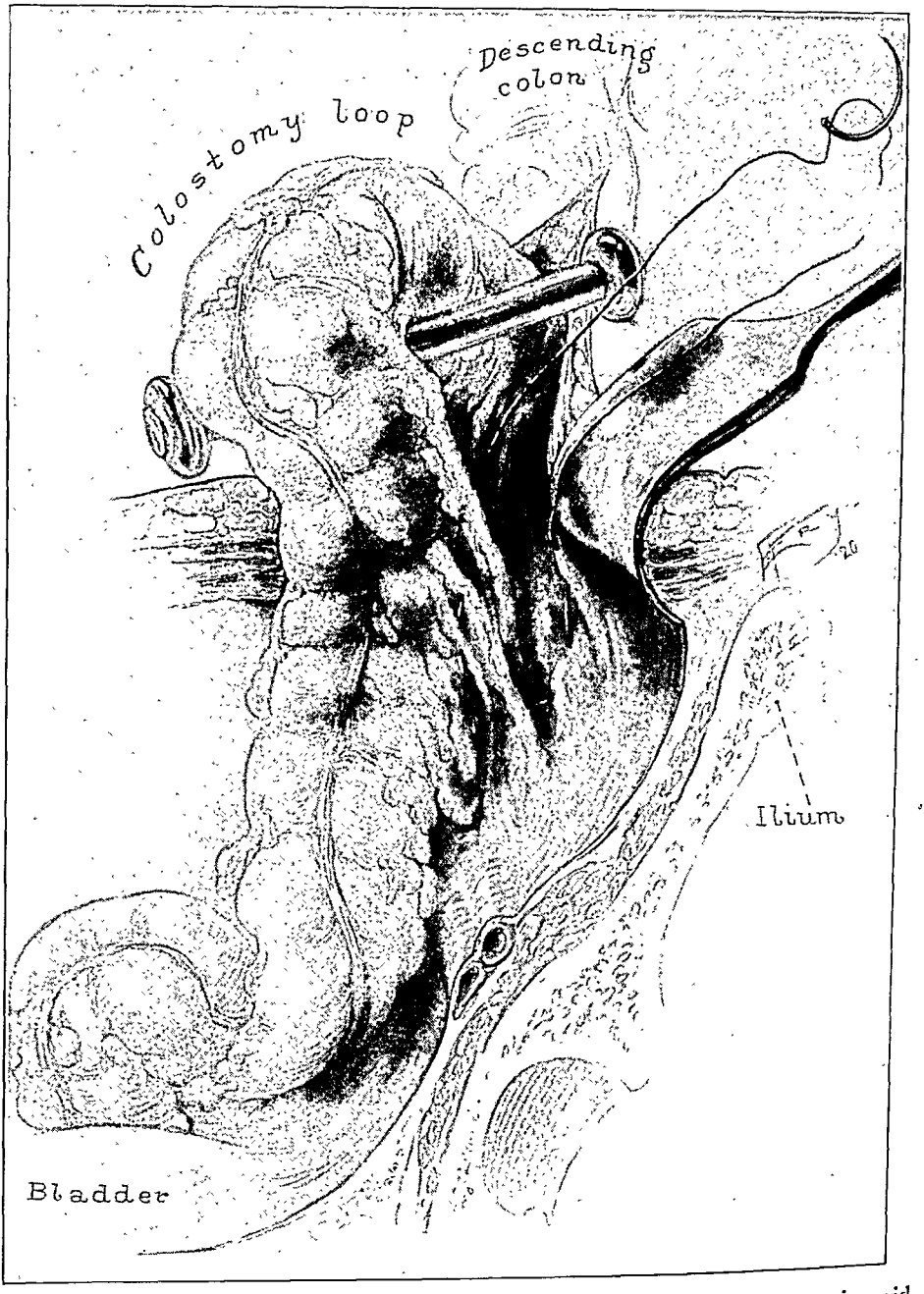

Fig. 6.—Continuous suture between parietal peritoneum and mesosigmoid, closing space on suture of colostomy.

In the retrocolic short loop gastrojejunostomy (the long loop retrocolic method is no longer performed), the space behind the anastomotic

loop through which herniation takes place is closed by placing a suture between the afferent loop and the transverse mesocolon on the stomach about 2.5 cm. above the gastrojejunal juncture, and another suture 2.5 cm. below (Fig. 4).

To prevent herniation following colostomy, the colostomy is made far to the left, on a line about one third of the distance between the left anterior superior spine and the umbilicus (Fig. 5). The Maydl-Littlewood type of colostomy is usually employed. After the loop of

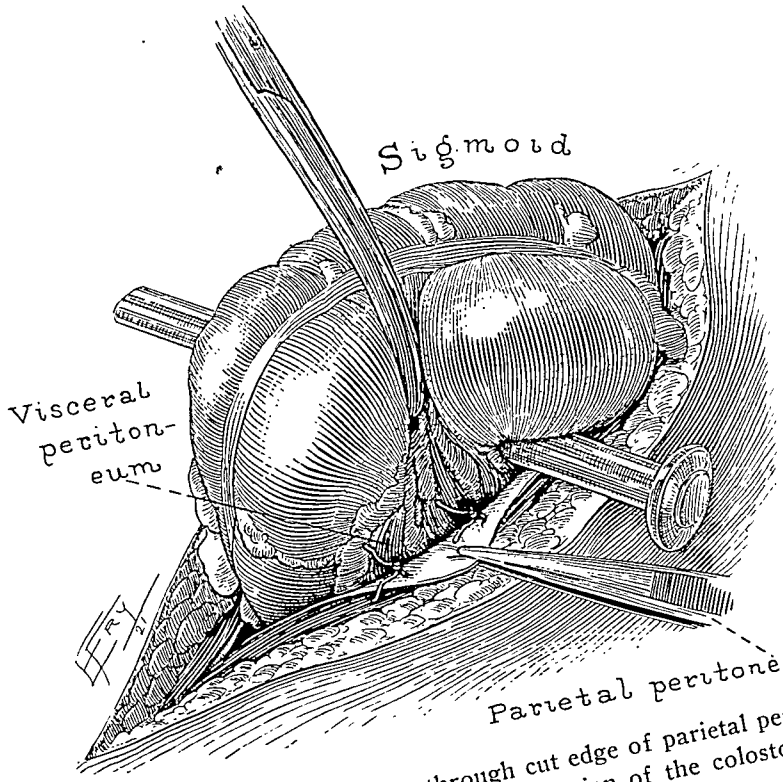

Fig. 7.—Two interrupted sutures through cut edge of parietal peritoneum and upper portion of mesosigmoid to prevent retraction of the colostomy loop.

sigmoid has been brought out of the abdomen, the mesosigmoid is sutured to the left parietal peritoneum by a continuous puckering suture (Fig. 6). Two interrupted sutures are then placed at the juncture of the sigmoid and its mesentery and just below the outer cut edge of peritoneum (Fig. 7). This procedure makes it impossible for the small intestine to pass around the colostomy, either from above or below. Such technic, especially if the small intestine is distended, tends to prevent postoperative complications, which, although rare, are extremely severe and result in a high mortality.

THE RADICAL CURE OF TUBERCULOSIS OF THE SEMINAL TRACT *

I. BRIEF SURVEY OF THE LITERATURE

HUGH HAMPTON YOUNG, M.D.
BALTIMORE

In a paper which I presented three years ago ("Presentation of a Radical Operation for Tuberculosis of the Seminal Tract"), I discussed at some length the operative treatment of genital tuberculosis. I referred to the fact that beginning with the first seminal vesiculectomy by Ullmann in 1889 reports of thirty-two cases were to be found in the literature during the next twelve years; but the results which were obtained by the various technics employed were so unsuccessful that I was forced to the conclusion that the radical operation for tuberculosis of seminal vesicles should be abandoned. A further review of the literature showed that the testicle was rarely involved, except late in the disease, and that epididymectomy gave as radical results as castration. Von Bügner's plan of injecting the vas with glycerin containing iodoform was approved; but his plan of forcible evulsion of the vas was shown to be bad by published reports of cases in which both fatal infections and hemorrhages had occurred. I proposed a new method of permanent drainage of the deeper tract, by bringing the upper end of the vas deferens out through the upper end of the wound in the groin, where I advised that it be subsequently injected with oil containing iodoform or phenol, which I also employed.[1]

Following this paper, Belfield added great interest to the question of treating the seminal vesicles and ampullae by vasostomy in cases of chronic infection, and in 1909 Cunningham[2] brought up again the question of treatment of tuberculosis of the seminal vesicles by means of injection of phenol through the vas deferens, reporting thirty-four cases in which good results were obtained by this procedure. In my recent paper,[3] in 1918, I called attention to the fact, that, at my clinic, studies of the cases as years passed by showed that whereas many good surgical results were obtained by removal of the external focus (epididymectomy or castration), in many other cases very unsuccessful results were obtained, many of the patients dying in great misery from tuberculosis, urogenital or generalized.

---

* From the Brady Urological Institute and the Johns Hopkins Hospital.

1. Legueu: Traité chirurgicale d'urologie, 1910.
2. Cunningham, J. H., Jr.: Surg., Gynec. & Obst. **23**:385 (Oct.) 1916.
3. Young, H. H.: Surg., Gynec. & Obst. **26**:375 (April) 1918.

I, therefore, urged the adoption of a radical operation for tuberculosis of the seminal vesicles and presented a simplified method which I had carried out with a special, delicate, long tractor, which can be introduced through the penile urethra into the bladder and which greatly facilitates successful removal of the entire tract.

This article has called forth objections from many of my friends who are urologists; but believing that the time is now ripe for reopening the question and for a thorough study of the problem, both from a pathologic and a clinical standpoint, and especially as to the results obtained, I am, therefore, again presenting these most important questions: What is the primary seat of infection, its mode of progression to other organs, and the appropriate operation in genital tuberculosis?

Turning to the French literature, I find that Guyon,[4] the father of modern urology, stated many years ago that the tuberculous process begins generally in the seminal vesicles. He cited twenty-six necropsies in which the seminal vesicles were found to be primarily the site of disease; in two cases only the seminal vesicles were involved and in ten cases the prostate was infected simultaneously with the vesicles. In one case, the prostate alone was involved. In 220 clinical observations of patients suffering from urogenital tuberculosis which Guyon examined personally, forty cases were isolated genital tuberculosis, seventy-four were cases of tuberculosis of the urinary organs and 108 were combined urinary and genital tuberculosis. In 127 clinical cases in boys suffering from urogenital tuberculosis before the age of puberty, Guyon found the prostate involved in fifty-six, prostate and seminal vesicles in eleven, epididymides twice and all of the genital organs fifty-eight times. Guyon asserted his belief that the tuberculous process begins most frequently in the seminal vesicles and that the involvement was from within outward, toward the external genitalia.

Guelliot[5] reported that in fifty-nine cases of tuberculosis of the seminal vesicles the lungs were involved in forty-nine, the prostate in thirty-six, the testicle and epididymis in thirty-four and the bladder and urethra in twenty-nine.

More recently, Legueu[1] stated his preference for epididymectomy in unilateral cases, but he believed that in cases in which the vesicles are involved and in bilateral epididymal infections the entire seminal tract should be removed. He believed that such operations were not contraindicated by involvement of the bladder or even of the lungs.

At the Thirtieth Congress of the German Surgical Association, the subject of tuberculosis of the seminal tract was thoroughly discussed.

4. Guyon, cited by Walker, MacFarland: Lancet **1**:435 (Feb. 15) 1913.
5. Guelliot: Presse méd. **33**: 1898.

Bruns reported 111 cases, in seventy-eight of which unilateral castration had been performed and in thirty-three double castration. A study of these unilateral castration cases showed that the second testicle was involved in 34 per cent. of the cases in three months; in 40 per cent. in four months, and in 60 per cent. in the later cases. He stated that in the seventy-eight cases in which unilateral castration had been performed, the other testicle became involved in 26 per cent. of the cases. As to results obtained by castration, his statistics showed that after unilateral castration only 45 per cent. of the patients were cured and after bilateral castration only 56 per cent.

Simon stated that in 107 cases, sixty-one remained cured after castration (57 per cent.). Koenig, who opposed this operation, advised, in the treatment of tuberculosis of the epididymis and testicle, "vesiculoprostatic resection, the best means of access for which consists in osteoplastic resection of the sacrum, the last piece of the sacrum and coccyx, being included in the flap." He gave no figures regarding results.

Boguljüboff [6] reported 166 cases with tuberculosis of the epididymis or testicle and stated that in 137 cases the other side became tuberculous within an average time of fourteen months.

Berger [7] gives the results in forty-seven cases which were followed over a period of from one to twenty-five years (Table 1).

TABLE 1.—RESULTS IN FORTY-SEVEN CASES

	Number	Now Apparently Well	Stationary	Dead	Dead, per Cent.
1. Not operated	1	0	—	1	100
2. Resection of epididymis	3	3	—	—	0
3. Single castration	34	20	4	10	29
4. Double castration	9	6	—	3	33
Total	47	..	..	14	29

Berger asserts that of the forty-three single or double castration cases, twenty-six patients (60.4 per cent.) are well up to the present, but some have been followed only two years or less.

In England, Thompson Walker [8] presented a study of 100 cases of genital tuberculosis in fifty of which the genital organs were involved, in thirty-seven the genital and urinary organs, and in thirteen there was genital or other tuberculosis (lung, etc.). Of the 100 cases, the epididymis was affected in seventy-two; in sixteen the prostate and seminal vesicles were also involved; in fourteen the seminal vesicles, and in sixteen the prostate alone, was involved. We have, therefore,

6. Boguljüboff, cited by Whiteside, G. S.: Northwest Med. **18**:83 (May) 1919.

7. Berger: Arch. f. klin. chir. **68**:915, 1902.

8. Walker, Thompson: Surgical Diseases and Injuries of the Genito-Urinary Organs, London, Cassell & Co., 1914.

forty-six cases, out of seventy-two (64 per cent.), in which the region of the prostate and vesicles was involved. He believes that the infection may reach the epididymis by the blood stream and also by the vasa deferentia. Thompson Walker also states that tuberculosis of the epididymis invariably involves the second epididymis after a year or more. He concludes:

My practice is to treat chronic tuberculosis with tuberculin and to limit operative procedures to opening and scraping abscesses when they arise. Such treatment must invariably lead to chronic discharging sinuses. If the disease appears to be spreading in spite of the tuberculin treatment, epididymectomy is performed and if it is already very extensive and has involved the testicle, this organ is removed. I have not found it necessary to perform extensive operations for the removal of the pelvic portion of the vas deferens.

In a remarkable article, "The Paths of Infection in Genito-Urinary Tuberculosis," MacFarland Walker,[4] in 1913, presented the most careful historical, clinical and experimental study of genital tuberculosis. He states that, in a series of twenty-two cases of tuberculous epididymitis, involvement of the prostate and vesicles was discovered in twenty. Of the two exceptions one was that of a baby of 15 months and the other a boy who had undergone bilateral castration at the age of 14. Walker says that "in every one of these cases the first signs of disease were detected in the lower pole of the epididymis;" and that at the lower pole, the first signs of softening and breaking down are observed.

That the lower pole of the epididymis should be the commonest site of the primary deposits is only to be expected, if the tuberculous infection is a descending one. It is the first spot to be reached by the infective agent in its journey down the cord. The tuberculous testicle falls into the same category as a gonococcal one, and if we are prepared to admit a descending infection in the case of the gonococcus, we cannot rationally deny it in the case of the bacillus of tuberculosis.

Walker then details the experiments which he carried out with various bacteria. In one, he inoculated the anterior urethra of guinea-pigs with organisms; and, after twelve hours, abundant growth was obtained from the epididymis and a much scantier one from the testis. The same organisms were found in the vesicles and in the plexus of the lymphatics, running with the vas. A control cultivation of the blood gave a negative result. Microscopic sections of the tissues in these cases show the presence of numerous organisms in the lymphatics, surrounding the vas. In the lumen of the vas itself, few or no organisms were found.

Baumgartner's failure to produce a descending tuberculosis experimentally in rabbits is, in my opinion, no proof of any inability on the part of the tubercle bacillus to descend the cord, in a direction contrary to the secretions.

The inoculation of the urethra or even of the cord is insufficient; it is necessary also to prepare the testicle for the reception of the tubercle bacillus by previously injuring it.

Walker says that he inoculated the rabbit's urethra and exposed the left testicle to a certain amount of trauma. At the end of six weeks the epididymis was indurated and swollen on the injured side. Necropsy revealed tuberculosis of the epididymis and seminal vesicle, and microscopic examination showed tuberculosis in the epididymis but none in the body of the testicle.

The possibility of the lymphatics of the cord acting as the path along which a descending infection of the testicle may advance is supported to some extent by the appearance of specimens obtained from the postmortem room. The prostatic and the testicular extremities of the cord are markedly affected, while the intervening portion appears healthy. If transverse sections are made and examined microscopically, the following is found to be the exact distribution of the tuberculous lesions. Transverse sections of the prostatic extremity show that the vas itself is comparatively healthy but that it is surrounded by a thick shell of tuberculous tissue, due to infiltration of the lymphatics. As the testis is approached, this lymphatic infiltration gradually ceases. A section of the distal end of the vas, near its termination in the epididymis, shows a converse condition. Here the disease has affected the mucosa of the vas, whereas the surrounding lymphatics give little or no evidence of any lesion. This distribution suggests that the disease is disseminated from the prostate, by the lymphatics, and that having encountered in the epididymis a suitable soil in which to flourish, it produces a returning wave of infection in the vas through the agency of the secretions. It is interesting to note that microscopic examination of genital tuberculosis experimentally produced in the rabbit by urethral inoculation shows an exactly similar distribution. The prostatic extremity of the vas and the seminal vesicle on the diseased side were enclosed in a dense shell of tuberculous infiltration, the inner coat of the vas being healthy.

Apart, therefore, from other considerations, the distribution of the tuberculous tissues alone suggests the existence in these cases of two opposing waves of infection, a centrifugal and primary one, traveling from the prostate along the lymphatics; a centripetal and secondary one, in the lumen of the vas, due to the flow of infected secretions from the diseased epididymis.

From a consideration of the foregoing, it would appear that infection of the testicle (i. e., epididymis) takes place in tuberculosis, as in gonorrhea, by means of the cord and not by the blood stream. That cases of hematogenous infection occur cannot be denied, but they are few in number. The evidence in favor of the frequent occurrence of a descending genital tuberculosis may be tabulated thus:

Clinical Evidence: 1. It is extremely rare to find tuberculosis of the epididymis without discovering some indication of disease of the prostate or the vesicle. 2. Prostatic tuberculosis is not infrequently found without any lesions of the testicle. 3. The appearance of a tuberculous epididymitis is often preceded by symptoms of prostatitis or vesiculitis, the so-called prodromata of tuberculous epididymitis. 4. The earliest signs of tuberculous disease are found at the lower pole of the epididymis. This is the first position which opposes the line of march of the invading organisms. 5. Tuberculous disease of the

testicle is analogous to acute infections which are known to have been produced by extension from the urethra. The ordinary type of tuberculous epididymitis has no analogy to the hematogenous orchitis of mumps.

Pathologic Evidence: 1. Lesions of the testicle without disease of the prostate are rare; whereas tuberculous lesions of the prostate are not infrequently found unaccompanied by disease of the testicle. 2. When tuberculosis of the testicle is found in association with tuberculosis of the prostate, the lesions in the prostate generally appear to be older than the lesions in the epididymis. 3. Tuberculous nodules in the lower pole of the epididymis usually appear older than those in the upper pole. They are the first to soften and break down.

Experimental Evidence: 1. Micro-organisms and inanimate granules are rapidly absorbed from the urethra and carried to the testicle. 2. A tuberculous epididymitis may be experimentally obtained by inoculating the urethra after having damaged one of the testicles.

The experiments of MacFarland Walker are of utmost importance in that they show the futility of hoping *completely* to eradicate the disease by epididymectomy or castration.

A brief report of some of the most important articles in the American literature is of interest.

In 1907, E. L. Keyes, Jr.,[9] presented a careful study of 100 patients with tuberculosis of the testicle, fifty-three of the cases being bilateral. Speaking of the site of the first infection, he says:

> In only twenty-five cases was I able to obtain information on this point and yet in nineteen of them the nodule appeared in the tail of the epididymis and in only six did it begin in the head.

In eighty-seven cases, Keyes says that the opposite testicle was affected in fifty-three cases, and that in thirty-four it was affected when the patient was last seen. In ten patients in whom the testicle was involved at the time of operation, three relapses on the opposite side occurred within one year; two after one year and two more after two years, making seven relapses in all, while of the remaining three patients in whom the opposite testicle was not known to be involved, two were followed less than a year and one followed for two years.

Further evidence of the futility of attempting amputation of tuberculosis is the involvement of the other organs in two years, in unilateral orchidectomy, one case of urethral abscess, one of vesicular abscess, two of tuberculous kidney, one of acute prostatitis, and one of tuberculous inguinal adenitis. Such results simply confirm the belief that, though apparently localized in the testicle or elsewhere in the body, tuberculosis is a disseminated infection which cannot be amputated.

Keyes draws the following conclusions:

> Testicular tuberculosis is never an isolated lesion. Relapses in the opposite testicle occur within a few years in eight or nine out of ten cases. Be the operation ever so slight or ever so radical, relapses on the opposite side almost inevitably occur.

9. Keyes, E. L., Jr.: Ann. Surg. **45**:918, 1907.

In a series of important studies on genito-urinary tuberculosis, Barney [10] brings forth similar testimony. He states that in 821 cases in which the condition of the prostate and seminal vesicles were described, 75 per cent. were tuberculous. In 101 rectal examinations, in Barney's own series of cases of genital tuberculosis, seventy-six revealed tuberculosis of the prostate and seminal vesicles.

Barney states he has traced 113 patients with tuberculosis of the epididymis from one to twenty-five years after operation and that 27 per cent. of them died of some form of tuberculosis.

Eighty-one per cent. of these examined and 28.5 per cent. of those reached only by letter are still within the six-year period, and it is to be expected that the deaths from tuberculosis are not yet at an end.

Barney makes this very strong statement:

I have already pointed out the disastrous results of genital tuberculosis and the rapidity of recurrence. It has been shown that the second epididymis is attacked in 26.5 per cent. within the first six months after the involvement of the first side; that the disease invades prostate and vesicles in 30 per cent. within the same time; and that testicular tuberculosis within this period is found in 60.6 per cent. If one adds to this misfortune, the annoyance of bladder irritability and the affliction of sterility, the outlook is indeed gloomy. It is also to be remembered that a very large proportion of patients have the proverbial ax hanging over them in the form of tuberculosis of other organs.

In an interesting paper, in 1910, Whiteside [11] called attention to the fearful ravages of testicular tuberculosis and ineffectiveness of resection of the epididymis. He stated that from necropsies and from his own clinical experience, he believed involvement of the entire genital tract to be frequent and that epididymectomy was entirely inadequate. He stated that he had recently practiced a radical operation in such cases and cited the case of a man in a deplorable condition with involvement of both testicles, epididymides, prostate, seminal vesicles and bladder, in which a wonderfully satisfactory result was obtained by extirpation of the seminal vesicles as well as the external foci of involvement. Whiteside [12] has recently published another article on this subject, reciting several remarkable results in apparently desperate cases and calling attention to the value of a radical operation. In response to a personal letter of inquiry, he states that he is unable to get exact statistics of the number of cases or results, but he says:

My remote results, quoting from memory, are that those patients who have survived are well. They even tell me that they are sexually able to perform

10. Barney, in Cabot, Hugh: Modern Urology, Philadelphia, Lea & Febiger, 1918.
11. Whiteside, G. S.: California State J. M. **8**:88, 1910.
12. Whiteside, G. S.: Northwest Med. **18**:83 (May) 1919.

coitus. Those with good resistance to the disease have complete healing of all operative wounds and resultant sinuses before six months after operation. Those that are tuberculous elsewhere than in the genital tract have one or more sinuses in the perineum or groins for a year or more. These cases for which I advocate radical removal of everything tuberculous are advanced cases. Consequently, a large percentage of these have, or soon suffer from, further tuberculosis (lungs, kidneys, etc.) and many died within five years after operation.

Cunningham [2] states that of eighty-six patients showing tuberculous epididymitis forty-nine showed lesions of the prostate or vesicles. Cystoscopy was carried out in fifty-one of these eighty-six cases and showed tuberculosis of the bladder in sixteen, in nine of which one kidney was tuberculous and in five both kidneys were involved. Sixty-seven had distinct signs in the lungs.

Cunningham [2] says (p. 388):

> Barney's report, the most recent and complete in regard to end-results, showing a mortality of 85 per cent. within six years following such procedures (epididymectomy and castration) in an institution of the highest surgical efficiency, is far from satisfactory.

He then recommends the plan of von Büngner, of injecting the vas after epididymectomy, advising the use of pure phenol, and reports the cases of thirty-two patients thus treated, namely:

Of these thirty-two patients, seven, or 21.7 per cent., have died in ten years; twenty-five, or 88.3 per cent., are living; four have demonstrable tuberculosis in the genito-urinary tract; one has no demonstrable tuberculosis, but the inoculation test is positive; twenty, or 62.5 per cent., are locally free from the disease.

Following my paper [3] in 1918, there appeared an excellent article by Quinby [13] in which he reported seven cases in which operation was performed by a technic similar to that described by me, with excellent results.

II. STUDY OF CASES AT JOHNS HOPKINS HOSPITAL

A. In order to see what our own statistics show with regard to the various questions which have been brought up in this study of the pathology and surgical treatment of tuberculosis of the seminal tract, I have examined the records of eighty-six cases of genital tuberculosis in the general surgical department of Johns Hopkins Hospital. The operations performed on these patients were:

Castration: right, twenty-four, of which four had left epididymectomy, and one had previous right epididymectomy; left, twenty-nine, of which three had right epididymectomy, and there is no record of

13. Quinby, W. C.: Genital Tuberculosis, J. A. M. A. **71**:1790 (Nov. 30), 1918.

previous left epididymectomies; both, five. Epididymectomy: right, ten, of which one had right castration and three had left castration subsequently; left, six, of which four had right castration; right and left, five, with no note of castration subsequently. Nephrectomy, three. Perineal section, one. Suprapubic cystotomy, one, and no operation, fifteen.

I have been unable to secure sufficient replies from these patients to determine the results which have been obtained by the treatment which was given. Most of these patients were operated on a long time ago, before the operation of epididymectomy had been introduced into this hospital, and as a result, castration was more often employed. I have searched the pathologic records and found satisfactory pathologic reports as follows: Castrations, twenty-seven. In all of these the testicle, epididymis, vas and part of the cord had been removed. Gross and microscopic examination demonstrated tuberculosis of the epididymis in all of these cases and in twenty cases also tuberculosis of the testicle. In seven cases the testicle was reported to be uninvolved, although the epididymis was markedly tuberculous. Only two of these cases were bilateral.

B. I have next analyzed sixty-six cases of tuberculosis of the epididymis in patients who have presented themselves at my private clinic and which have been carefully studied by Dr. R. S. Young. The totals are as follows:

(*a*) *Involvement According to Clinical Examination.*—Epididymis: right 16, left 17, both 23, total 56; testis: right 7, left 4, both 0, total 11; vas: right 2, left 1, both 3, total 6; vesicles: right 6, left 1, both 11, total 18; prostate: 14; bladder: 24; kidney: right 5, left 11, both 2, total 18.

(*b*) *Operations Performed.*—No operation: 10; castration: right 7, left 10, both 0, total 17; epididymectomy: right 10, left 12, both 10, total 32; vasectomy: 1; suprapubic cystotomy: 0; nephrectomy: right 3, left 8, total 11.

(*c*) *Subsequent Operations.*—Castration: total 2; epididymectomy: double 1, single 2, total 3; nephrectomy: total 2; abscess of groin: total 2; suprapubic cystotomy: total 1; abscess of perineum: total 1.

(*d*) *Ultimate Results (Sixty-Three Cases).*—No information: 18; well: 8; improved: 14; not improved: 2; worse: 3.

Length of Time Followed Since Operation.—Under one year 2; between one and two years 7; two years 4; three years 2; four years 3; five years 1; six years 2; eight years 1; nine years 1; twelve years 1.

Fatal Cases.—Eighteen (not included in above dates).

Interval Between Admission and Date of Death.—In hospital 3, less than one year 6; one year 1; two years 2; three years 1; not stated 3.

Among fatal cases, no operation was performed in two cases.

C. Further analysis of cases (operative):

Region Involved.—Right epididymis 16, epididymectomy 10; no subsequent operations. Left epididymis 17, epididymectomy 12. Of these one required right epididymectomy two years later, a second required right nephrectomy for tuberculosis seven years later and developed tuberculosis of the left kidney six years later, a third underwent a right nephrectomy for tuberculosis one year previously and a fourth submitted to right castration one year previously. Both the right and the left epididymis were involved in twenty-three cases; double epididymectomy in ten. Of these one required left castration four and one-half months later, a second required castration three years later.

Region Involved.—Right kidney 5, nephrectomy 3; no subsequent operations. Left kidney 11, nephrectomy 8. Of these, 1 required left epididymectomy four months later, 2 others required double epididymectomy five and two months later.

D. Cases of bilateral involvement of the epididymides:

Region Involved.—Number of cases 23. Of these cases, the second epididymis involved was: (*a*) globus minor of second epididymis involved without any, or very little, involvement of the globus major 9; (*b*) globus major involved in second without any, or very little, involvement of globus minor 1; (*c*) both markedly involved, so that primary site in epididymis could not be told 9, and (*d*) history not clear in 4.

E. Cases complicated with: tuberculosis of kidney, 4; globus minor involved, 3; globus major involved, 0; and entire epididymis involved, 1.

In cases of tuberculosis of the epididymis with tuberculosis of the seminal vesicles and prostate: globus minor involved, 12; globus major involved, 3, and entire epididymis involved, 21.

F. An analysis of the cases of: one-sided epididymal tuberculosis in which there was no prostatic or seminal vesicle involvement made out, 10: according to history: swelling or pain began at upper end, 1; swelling or pain began at lower end, 2, and not determined, 7. At examination: involvement only of globus minor, 4; involvement only of globus major, 0, and involvement of entire epididymis, 6. At operation: involvement only of globus minor, 2; involvement only of globus major, 0, and involvement of entire epididymis, 4.

G. These statistics show conclusively the absence of isolated testicular tuberculosis and the rarity of testicular involvement when the epididymides are extensively involved. What is the point of primary involvement in the epididymides? Table 6 seems to show that even without discoverable involvement of vesicles and prostate, the globus minor is more often the point of primary involvement in the epididymis.

Table 5 seems to show very conclusively that when the opposite epididymis becomes involved, it is generally the globus minor which is first involved. This is also true in cases of epididymitis in which the vesicles were found to be involved on rectal examination. Can we not justly draw the deduction that in almost all cases the primary focus in genital tuberculosis is the seminal vesicle? The prostate is definitely shown to be very rarely the primary seat of involvement.

H. In another study of seventeen cases of castration, all were found to be tuberculous. No cases were found in which normal testes were removed. In one case of double epididymectomy, right castration was performed three years later (elsewhere).

Résumé.—Of 63 patients, 53 were operated on. Of these 18 are dead. Eighteen have not been heard from, and of the 45 patients heard from 13 have been operated on less than three years and 9 less than two years. There remain, therefore, out of 63 patients, only 27 who are known to be or have been alive three years or more since admission. Of these, only 22 are known to be well and improved. When we consider also that, with the exception of about 24 cases, the urinary tract was not involved and that the cases were, therefore, fairly early cases of tuberculosis of the seminal tract, the results obtained by epididymectomy or castration are, indeed, very poor. In many of these cases, the seminal vesicles were injected through the vas from one to four times during and after operation, either oil containing iodoform or pure phenol being employed.

I. Analysis of 28 cases of urogenital tuberculosis without involvement of epididymides or testicles. *Region Involved* (as made out at examination).—Prostate, 26; seminal vesicles: right 1, left 1, both 14, total 14; bladder: 16; kidney: right 2, left 2, both 1, total 5.

Previous Operations Performed.—Nephrectomy: right 2, left 1, total 3; suprapubic cystotomy: total 1. No operation on prostate or vesicles in any of these cases.

Results.—Only one of these patients is said to be well. He had tuberculosis of the prostate, bladder and both seminal vesicles and no operation was performed. Seven years have elapsed since he was here. He has not been examined personally. Four are said to be improved and have been followed six, seven, eight, and thirteen years, respectively. In all of these 4 the prostate was involved, in 2 the seminal vesicles, and in 2 the bladder. The kidney was involved in 1 case, and in the latter case nephrectomy was performed. In the other 3 cases no operation was performed. Repeated questionnaires have been sent out and 5 patients are known to have died. In 18 cases, no information can be obtained and it is probable that in many of these the patient has died.

Comment.—This is another melancholy record resulting from the nonoperative treatment of tuberculosis of the seminal vesicles and prostate.

III. ANALYSIS OF STATISTICS TAKEN FROM THE LITERATURE AND FROM OUR OWN SERIES OF CASES

Certain clinical and pathologic statistics taken from the literature are presented herewith in tabulated form to which we have added similar statistics from our own cases, the sixty-three mentioned before in B.

TABLE 2.—TUBERCULOSIS OF EPIDIDYMIS

	Number of Cases	Prostate or Vesicles Involved, per Cent.
Thompson Walker	72	64
MacFarland Walker	22	91
Barney	100	77
Cunningham	86	57
Young	55	60

Comment.—These statistics are sufficient to demonstrate that among patients presenting evidence of tuberculosis of the external genitalia more than 50 per cent. present definite evidence of involvement of the prostate or vesicles, or both. In view of the fact that early lesions in the vesicles are difficult to prove, we feel that the statistics of Barney and possibly of MacFarland Walker give more nearly the correct percentage. Among my cases, thirty are unilateral, which is additional confirmatory evidence that the seminal vesicles became involved early in testicular disease, if not preceding it. As a matter of fact, all statistics, and particularly those of MacFarland Walker, indicate that the seminal vesicles are the primary site of disease in a great majority of cases of tuberculosis of the epididymis.

TABLE 3.—PERCENTAGE OF BILATERAL INVOLVEMENT OF THE EPIDIDYMIDES OR TESTICLES IN CASES OF TUBERCULOSIS OF THE EPIDIDYMIS OR TESTICLE

Author	Cases	Bilateral	Percentage
Keyes	100	53	53
Bruns	111	42	38
Bogoljüboff	166	137	82
Berger	43	9	20
Barney	150	60	40
Koenig	...	..	75
Young	78	28	36

The figures in Table 3 simply confirm what has already been indicated: the great frequency of bilateral testicular or epididymal involvement and the frequency of simultaneous involvement of the seminal vesicles.

Table 4 is further proof that after removal of the disease on one side there remains a tuberculosis of the seminal vesicles from which the other testicle becomes involved, another argument showing the inadequacy of unilateral epididymectomy or castration.

TABLE 4.—Involvement of the Second Testicle After Operation

Author	Cases	Opposite Side Involved, per Cent.
Bruns	78	26
Keyes	87	53
Barney	106	15

We have next collected the statistics as regards cures which have been effected by castration or epididymectomy. In most instances, it is not possible to determine whether a single or double operation was performed, nor have the epididymectomies been separated from the castrations. There is also considerable variation as to what is considered a cure—a cure of the lesion in the scrotum is quite different from the entire disappearance of the disease from the whole genital tract. In my statistics I have included in Table 5 also cases of patients that were improved. If cures only were included, the percentage would be only 19 per cent.

TABLE 5.—Percentage of Cures Obtained by Castration or Epididymectomy

Author	Number of Cases	Unilateral Castration or Epididymectomy, per Cent.	Bilateral Castration or Epididymectomy, per Cent.	Bilaterality Not Specified, per Cent.
Bruns	111	45	56	
Berger	47	55	66	
Simon	107	..	..	57
Barney	113	..	..	73
Cunningham	32	..	..	62
Young	42	..	..	45

These statistics are proof of the ineffectiveness of castration or epididymectomy. Barney's words are most significant:

> Let us now see what encouragement can be held out to the patient with tuberculosis of the epididymis (by epididymectomy). I have traced 113 patients from one to twenty-five years after operation. Over 27 per cent. have died of tuberculosis. Within the period of six years after operation 41 per cent. of fifty-eight patients have died of this disease. Eighty-one per cent. of those examined and 28 per cent. of those reached by letter are still within the six-year period in which I have found that 85 per cent. of deaths occurred. It is to be expected that tuberculosis in this group is not yet at an end.

In order to determine the relationship between cure and the previous presence of tuberculosis of the prostate and vesicles, I have carefully

searched the records of our cases of epididymectomy and castration with the results given in Table 6.

TABLE 6.—CASES OF EPIDIDYMECTOMY OR CASTRATION IN WHICH THE PATIENT IS REPORTED AS WELL OR IMPROVED*

	Number of Cases	Prostate Involved	Seminal Vesicles Involved	Both Involved	No Involvement
Well	8	1	0	2	5
Improved	14	2	2	4	6
Dead	18	..	..	7	3

* Dead: Prostate and bladder, 1; vesicles and bladder, 1; vesicles, prostate and bladder, 2; kidney, 1; kidney and vesicles, 1; bladder, 1; bladder and kidney, 1.

Analyzing these tables, we see that in the cases of the patients that recovered 5 out of eight had no evident involvement of vesicles and in those that were recorded as improved there was no involvement in six out of fourteen, showing conclusively that a large percentage of the few good results from epididymectomy or castration are among those early or isolated cases in which the involvement of the prostate and seminal vesicles is either absent or too small to be detected, and the fact that among those patients who are reported dead only three out of eighteen have no involvement of the deeper structures is also strong evidence that the more radical operation should have been carried out in those cases.

Résumé of Argument.—The preceding statistics seem, therefore, to show conclusively that in the great majority of cases the primary involvement is in the seminal vesicles (or prostate), from which the epididymides or testicles are subsequently involved, the external disease being bilateral in from 30 to 50 per cent. of the cases. In a probably larger percentage of the cases, the involvement of the seminal vesicles is bilateral (61 per cent. of my cases in series B and probably higher). The disease reaches the epididymis generally by the lymphatics of the cord from the seminal vesicles and first involves generally the globus minor. It is probably erroneous to suppose that primary tuberculosis of the epididymis often occurs. It probably seldom occurs through blood stream infections, as so often asserted. The seminal vesicles are not only the primary focus from which the epididymides are involved, but from which also the prostate, bladder and the kidneys in many cases are involved. In fact, tuberculosis in the region of the prostate and vesicles is far more dangerous to the entire human organism than tuberculosis of the epididymides and is probably responsible for the fearful mortality which is variously estimated at from 27 to 60 per cent. in cases of genital tuberculosis. Therefore, it is the duty of the surgeon to attack the most dangerous focus of involvement, namely, that of the vesicles and prostate. Therefore, in tuber-

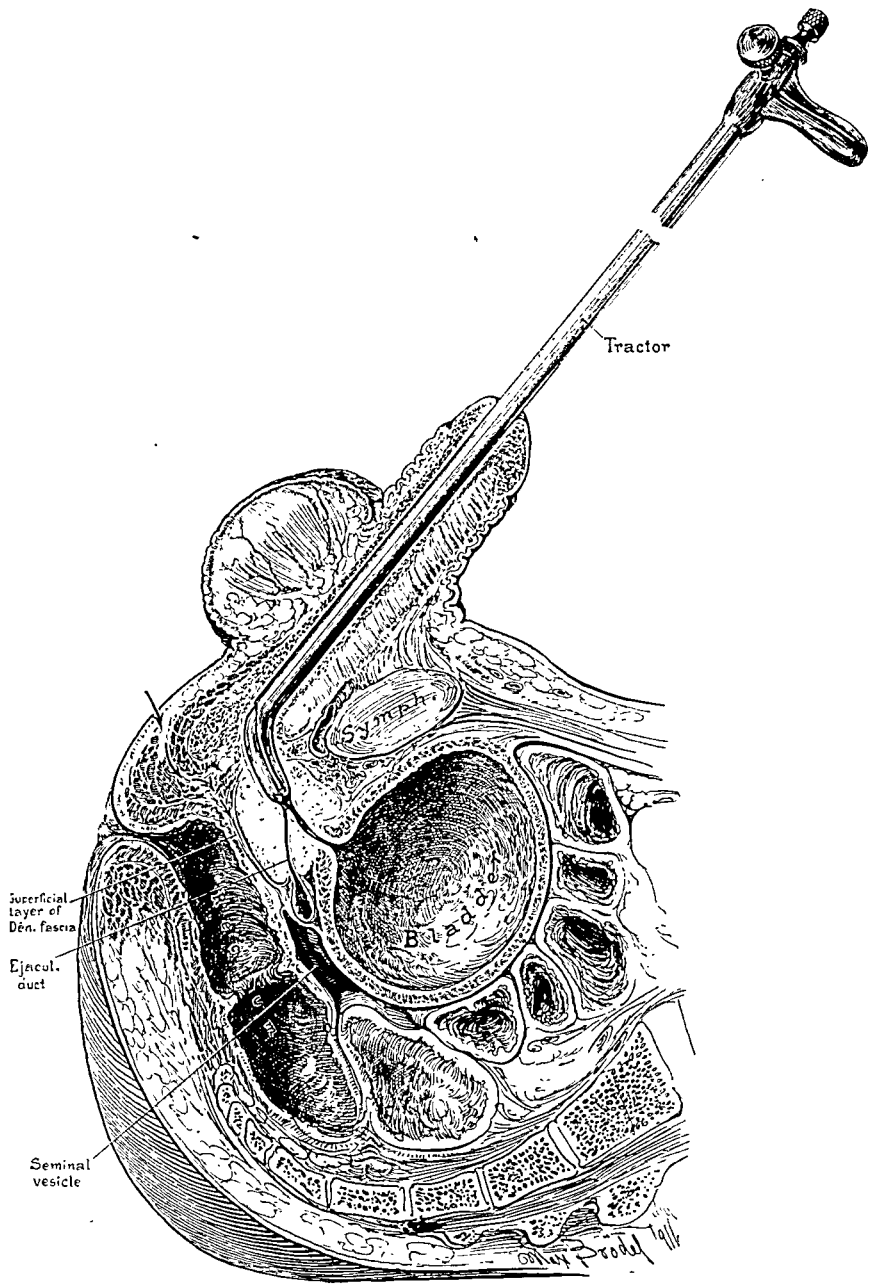

Fig. 1.—Anatomy of the region, arrows indicating route; tractor in urethra.

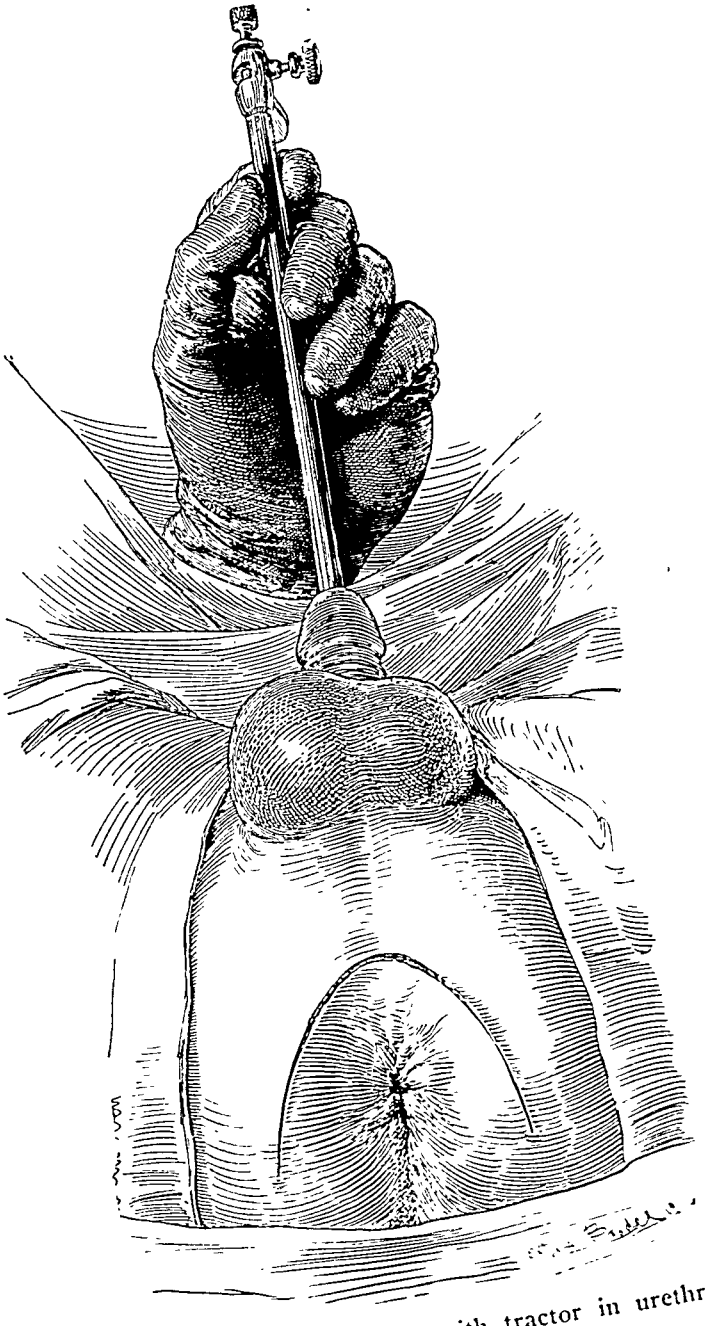

Fig. 2.—Cutaneous incision, with tractor in urethra.

TABLE 7.—RESULTS OF FIFTEEN RADICAL OPERATIONS FOR TUBERCULOSIS OF THE SEMINAL TRACT

Case Number	B. U. I. Number	Age	Lung Tuberculosis Before Operation	Tuberculosis of Kidney	Perineal Wound Closed	Interval Between Operation and Last Report	Postoperative Tuberculosis of Other Organs	General Health at Present	Final Operative Result
1	3515	28	None	Tubercle bacilli from right kidney before operation	5½ weeks	7 years	None	Excellent; slight pyuria; cause undetermined; coitus normal	Excellent local result; no sinus or fistula; micturition normal
2	4159	42	Old lung tuberculosis	None	Small fistula	Lived one year after radical operation	Lung tuberculosis before operation; abscess of chest wall, shoulder, epididymis, mediastinum later	Developed tuberculosis of mediastinum, chest wall, right shoulder; died 1 year later	Persistent urinary fistula; opposite epididymis involvement 1 year later
3	3632	22	Old lung tuberculosis	None	3 weeks	2 years, 7-8-16	Returned with tuberculosis of other epididymis, 2 yrs. later; epididymectomy, 6/30/16	General health excellent, 7/8/16; letters not answered and not returned	Involvement of other epididymis; cured by operation; condition otherwise excellent; no perineal fistula; urination normal
4	4322	..	None	None	5 weeks	Not heard from; letters not returned	None; patient refuses to answer letters	Condition good on discharge, 6 weeks after operation; wound not healed, fistula present before operation	No report since leaving hospital, condition good then
5	4330	30	None	None	Small fistula still open	6 years	None	Good; micturition normal; interval 3 hours	Excellent local result; second epididymis not involved; small urinary fistula persists
6	4980	34	None	None	Sinus still open; not urinary	5 years	None	Excellent; sexual powers normal; urination normal	Excellent result; small perineal sinus; no urinary fistula
7	7933	27	Old lung tuberculosis; suspicious fibroid tuberculosis	Left nephrectomy, 4 mos. previously	5 weeks	14 months	None since operation; previous kidney and bladder; tuberculosis, nephrectomy	Condition much improved; urination frequent but much improved; coitus normal	Excellent result; perineal sinus, not urinary

8	8486	51	None	None	4 weeks	1 year	None	Excellent; sexual powers satisfactory	Excellent local result; no sinus or fistula
9	8525	19	History of empyema; probable lung tuberculosis	None	3½ weeks	1 year	None (no flare up of old empyema or lung tuberculosis)	Good; no urinary complaint; sexual powers satisfactory	Excellent local result; no fistula; no sinus
10	8561	43	Suspicious fibroid tuberculosis	Pus and tubercle bacilli in urine, right kidney	Sinus still open; not urinary	1 year	None (no flare up of old suspected lung tuberculosis)	Excellent; much improved; micturition better; impotent before operation	Local result excellent; small sinus in scrotum; no fistula
11	8681	23	None	None	3 weeks	1 year	None	Excellent; sexual powers normal; micturition normal	Excellent local result; two small sinuses; no urinary fistula
12	8712	48	Chronic tuberculosis of lungs; state sanatorium	None	2 months	11 months	Old tuberculosis of lungs; condition still quiescent	Good; much improved; still has cystitis and frequency	No local recurrence; two discharging sinuses; no urinary fistula
13	8707	25	None	Present before; left nephrectomy, 3 mos. later	2 weeks	10 months	Tuberculosis of left kidney, present before, removed 3 months later	Improved but still suffers with pyelitis	Good local result; no urinary fistula; small sinus; cystitis
14	8729	30	Suspicious fibroid tuberculosis; arthritis (tuberculosis?) of spine, etc.	None	2 weeks	11 months	General arthritis before; involvement of rib, mastoid and foot since operation	Improved; now able to walk	Excellent local result; no fistula; urination good
15	5430	30	None	Right nephrectomy, 3 years previously	3 weeks	3 months	None	Good	Excellent local result; no fistula; urination normal

Tabulation: Number of cases, 15; lung tuberculosis present or suspected before operation, 7; kidney tuberculosis before operation, 5 (nephrectomy, 3); operative result excellent in all cases; operative mortality, 0; one death, lung tuberculosis, one year later; not heard from, 1; perineal urinary fistula, 1; persistent discharging sinus, 7; sexual powers normal, 5; impaired by operation, 0; not noted in reply, 10; operative failures, 0.

TABLE 8.—ABSTRACT OF PATHOLOGIC REPORT OF SEMINAL VESICLES, PROSTATE, ETC.

Case Number	B.U.I. Pathologic No.	Seminal Vesicles		Prostate		Vasa Deferentia		Ampullae	
		Right	Left	Right Lobe	Left Lobe	Right	Left	Right	Left
1	1780	Not removed.....	Many small and conglomerate tubercles	No evidence of tuberculosis	No evidence of tuberculosis	Not removed.....	Caliber diminished at upper end; many caseous tubercles at lower end	Not removed	Tuberculosis
2	1742	Not removed.....	Many small tuberculous cavities	Not removed.....	Extensive caseous tuberculosis	Not removed.....	Diffuse tuberculous process, attachment to globus minor	Not removed	Tuberculosis
3	1841	Indurated, nodular, caseous tubercles	Not removed.....	Fibrosis and a few small tubercles	No evidence of tuberculosis	Large nodule of caseous tuberculosis near ampullae	Not removed.....	Tuberculosis..	Not removed
4	2059	Caseous tuberculosis; much scar tissue	Scar tissue throughout; no evidence of tuberculosis	No definite evidence of tuberculosis; scar tissue	No evidence of tuberculosis	Many caseous tubercles	Fibrous throughout; no evidence of tuberculosis	Tuberculosis..	Much scarred; no evidence of tuberculosis
5	2064	Much enlarged; dense scar tissue; many caseous tubercles	Enlarged; small and large tuberculous abscesses	Somewhat fibroid; tuberculosis?	Much fibrosis; many caseous tubercles	Irregularities externally; caseous tubercles present	Nodular; tuberculosis present	Tuberculosis?	Tuberculosis
6	2363	Not removed.....	Small tubercles; much fibrosis	Not removed.....	Caseous tubercles	Not removed.....	Tuberculosis; mostly at lower end	Not removed	Tuberculosis
7	3344	Fibrous; small tubercles	Many caseous areas of tuberculosis	Not removed.....	Not removed.....	Uniform; no evidence of tuberculosis	Fusiform thickenings; caseous areas of tuberculosis	Tuberculosis..	Tuberculosis
8	3365	Hard; nodular; irregular; tuberculosis	Hard; nodular; irregular; tuberculosis	Fibrosis; tuberculosis	Fibrosis; tuberculosis	Uniform throughout; densely inflammatory; tuberculosis	Uniform throughout; densely inflammatory; tuberculosis	Tuberculosis..	Tuberculosis

9	3390	Somewhat enlarged; many tiny tubercles	Somewhat enlarged; many tiny tubercles	Tuberculosis.....	Tuberculosis.....	Not removed.....	Small, uniform in caliber; no evidence of tuberculosis	Tuberculosis..	Tuberculosis
10	3430	Enlarged; fibrous; irregular; many tubercles	Enlarged; marked fibrosis; few tubercles	Few small tubercles	Few small tubercles	Few tubercles at each end	Thickening and few tubercles near epididymis	Tuberculosis..	Tuberculosis
11	3471	Not removed.....	Firm; indurated; few tubercles	Not removed.....	Not removed.....	Not removed.....	Thickened; some nodules near ampullae; tuberculosis?	Not removed	Tuberculosis?
12	3482	Not removed.....	Enlarged; caseous tuberculosis	Not removed.....	Not removed.....	Not removed.....	Three nodules, upper, middle and extreme lower, contain tubercles	Not removed	Tuberculosis
13	3485	Enlarged; firm indurated; caseous tubercles	Enlarged; hard, nodular; caseous tubercles	Portion, tuberculosis	Portion, tuberculosis	Nodules of caseous tuberculosis in lower portion	No evidence of tuberculosis; uniform	Tuberculosis..	Tuberculosis?
14	3492	Tuberculosis.....	Not removed.....	Tuberculosis.....	Tuberculosis.....	Thickened throughout; lower portion tuberculosis	Not removed.....	Tuberculosis..	Not removed
15	3667	Small, fibrous tuberculosis	Much enlarged; caseous tubercles	Firm; fibrous; tubercles; caseation	Firm, indurated; tuberculosis	Lower portion removed; no evidence of tuberculosis	Uniform in caliber; no evidence of tuberculosis	Tuberculosis?.	Tuberculosis
Résumé									
Removed...		10	13	10	12	9	13	10	13
Involved.....		10	12	6	9	7	8	8	10
Uninvolved..		0	0	2	4	2	4	0	1
Doubtful.....		..	1	3	0	8	1	2	2
Not removed.		5	2	5	3	6	2	5	2

Bilateral vesiculectomy, 8; unilateral vesiculectomy, 7 (right 2, left 5); in 3 of these cases subsequently remaining epididymis was attacked.

TABLE 9.—ABSTRACT OF REPORT OF PATHOLOGIC TISSUES REMOVED: EPIDIDYMIDES, TESTICLES AND KIDNEYS

Case Number	Left Epididymis				Right Epididymis				Testicle		Tuberculosis of Kidney
	As a Whole	Globus Minor	Body	Globus Major	As a Whole	Globus Minor	Body	Globus Major	Left	Right	
1	Enlarged; tuberculosis	Conglomerate caseous tubercles	Caseous tubercles and small abscess	Destroyed by conglomerate caseous tubercles	Not removed	Not removed	Not removed	Not removed	Not removed	Not removed	Tubercle bacilli from right kidney before operation (once) but no further symptoms
2	Enormously enlarged; measures 3 inches in length; many tubercles	Greatly thickened; tuberculosis	Tuberculosis	Tuberculosis	Not removed at first, removed later; diffusely fibroid tubercle bacilli throughout	Removed later, tubercle bacilli	Removed later, tubercle bacilli	Removed later, tubercle bacilli	Enlarged; surrounded by hydrocele; tubercles in part adjacent to epididymis	Not removed	None
3	Enlarged; tuberculosis when removed 2 years later	.....	.....	.....	Enormously enlarged; conglomerate caseous tubercles	Caseous tubercles	Caseous tubercles	Caseous tubercles	Not removed	Tuberculous involvement of part adjacent to epididymis	None
4	Tuberculosis	Caseous tubercles; sinus to skin	Apparently normal	Apparently normal	Sinus present; tuberculosis	Large tuberculous abscess involving testicle and skin	Fibrous; tubercles in upper part	Extensively involved in tuberculous process	Not removed	Tuberculous abscess in lower pole; remainder normal	None
5	Removed one year preceding at another hospital	.....	.....	.....	Enlarged; tuberculosis	Large tuberculous abscess; fistula opening externally	Caseous tubercles	Enlarged, hard and indurated; caseous in portions	Not removed	Normal	None
6	Tuberculosis	Caseous tuberculosis	Caseous tuberculosis	Tuberculosis; least involved of any portion	Not removed	Not removed	Not removed	Not removed	Not removed	Not removed	None
7	Tuberculosis	Conglomerate caseous tubercles	Apparently normal	Apparently normal	Many large caseous conglomerate tubercles	Tuberculosis	Tuberculosis	Tuberculosis	Normal	Small portion removed shows caseous tuberculosis	Left nephrectomy, four months previously; tuberculosis

8	Tuberculosis	Fibrous tuberculosis	Fibrous tuberculosis	Tubercles	Tuberculosis, very extensive	Tuberculosis; fibrosis	Extensive caseation; tuberculosis	Large conglomerate tubercles	Small part of upper part of testes excised, tubercle bacilli	Small part of upper part of testes excised, tubercle bacilli	None
9	Tuberculosis	Enlarged; conglomerate tubercles	Enlarged; tuberculosis	Enlarged; tuberculosis	Removed previously with testicle; tuberculosis probable	Removed previously; tuberculosis probable	Removed previously; tuberculosis probable	Removed previously; tuberculosis probable	Not removed	Removed previously elsewhere; tuberculosis probable	None
10	Enlarged; irregular; caseous tuberculosis	Extensive induration; tuberculosis	Tuberculosis	Caseous tuberculosis	Enlarged tuberculosis	Tubercles	Tubercles	Tubercles	Early caseous tubercles present in portion adjacent to epididymis	Not removed	Pus and tuberculosis right kidney; process slight
11	Marked enlarged; tuberculosis; subcutaneous abscesses	Tubercles	Tubercles	Tubercles	Not removed	Not removed	Not removed	Not removed	Not removed	Not removed	None
12	Tuberculosis	Caseous tubercles	Tubercles	Tubercles	Removed later; tuberculosis	Removed later; tuberculosis	Removed later; tuberculosis	Removed later; tuberculosis	Very edematous; few early tubercles	Testicle removed 3 mos. later; tuberculosis	None
13	Enlarged; tuberculosis	Firm, hard and indurated; tubercles	Caseous tubercles	Enlarged; conglomerate caseous tubercles	Tuberculosis	Conglomerate caseous tubercles	Conglomerate caseous tubercles	Conglomerate caseous tubercles	Not removed	Portion removed; fibrous and caseous tuberculosis	Left nephrectomy three mos. later; tuberculosis
14	Not removed	Not removed	Not removed	Not removed	Enlarged; tuberculosis Not removed	Few tubercles	Caseous tubercles	Caseous tubercles	Not removed	Not removed	None
15	Greatly enlarged; tuberculosis	Hard and firm; nodular tuberculosis	Enlarged; caseous tubercles	Much enlarged; caseous tubercles		.....	.....	.....	.....	.....	Right nephrectomy 3 years previous; tuberculosis
Résumé											
Involved.....	13	13	11	11	11	11	11	11	4 (1 partly excised)	7 (3 partly excised)	5 (3 removed)
Uninvolved..	0	0	2	2	0	0	0	0	0	0	10
Doubtful.....	0	0	0	0	0	0	0	0	0	0	Removed
Not removed.	2	2	2	2	4	4	4	4	12 (1 partly)	11 (3 partly)	

Bilateral excision of epididymis or testicle 10 (3 being subsequent operations in cases of which corresponding ampulla and vesicle had not been excised).

culosis of the seminal tract in the great majority of cases radical operation not only should be the operation of choice but also should be practically imperative. A realization of the bad results obtained by epididymectomy or castration led me in 1913 to devise the radical operation, described herewith.

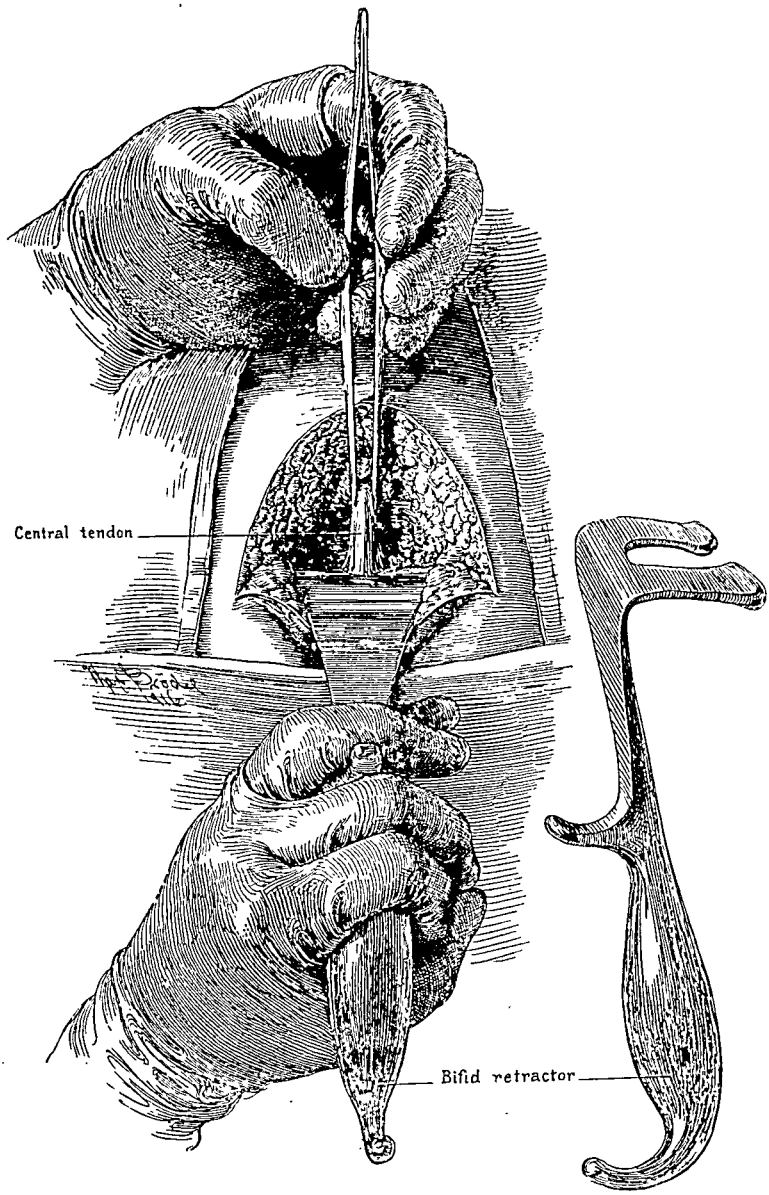

Fig. 3.—Central tendon put on tension by bifid retractor, previous to division.

IV. RADICAL OPERATION FOR EXCISION OF TUBERCULOSIS OF ENTIRE SEMINAL TRACT

The radical operation has been previously described; but it is necessary to refer to it again here (Fig. 1). The ordinary inverted U perineal incision (Fig. 2), which I have always employed for perineal prostatectomy, has been found entirely satisfactory, and after division

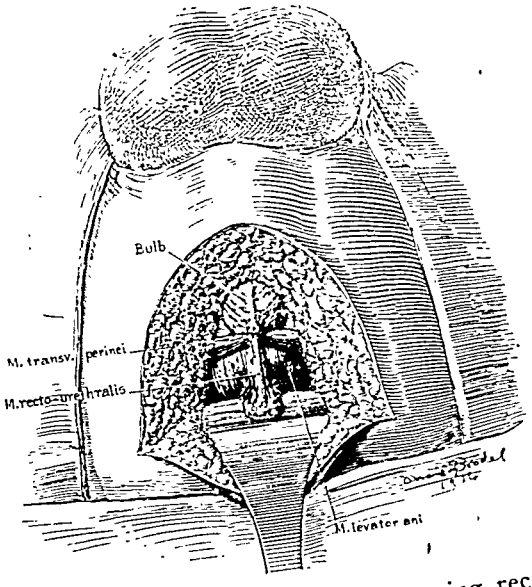

Fig. 4.—Central tendon has been divided, exposing recto-urethralis muscle, which is next divided.

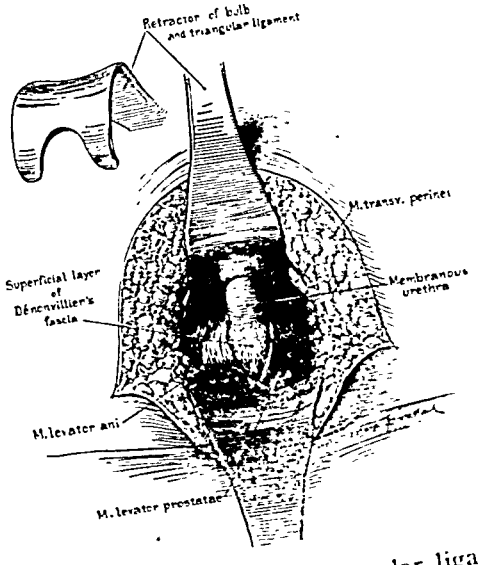

Fig. 5.—Special retractor of bulb and triangular ligament has been inserted, exposing membranous urethra, held up on tractor: the levator ani muscles being next pushed to each side, exposing the posterior or superficial layer of Dénonvillier's fascia.

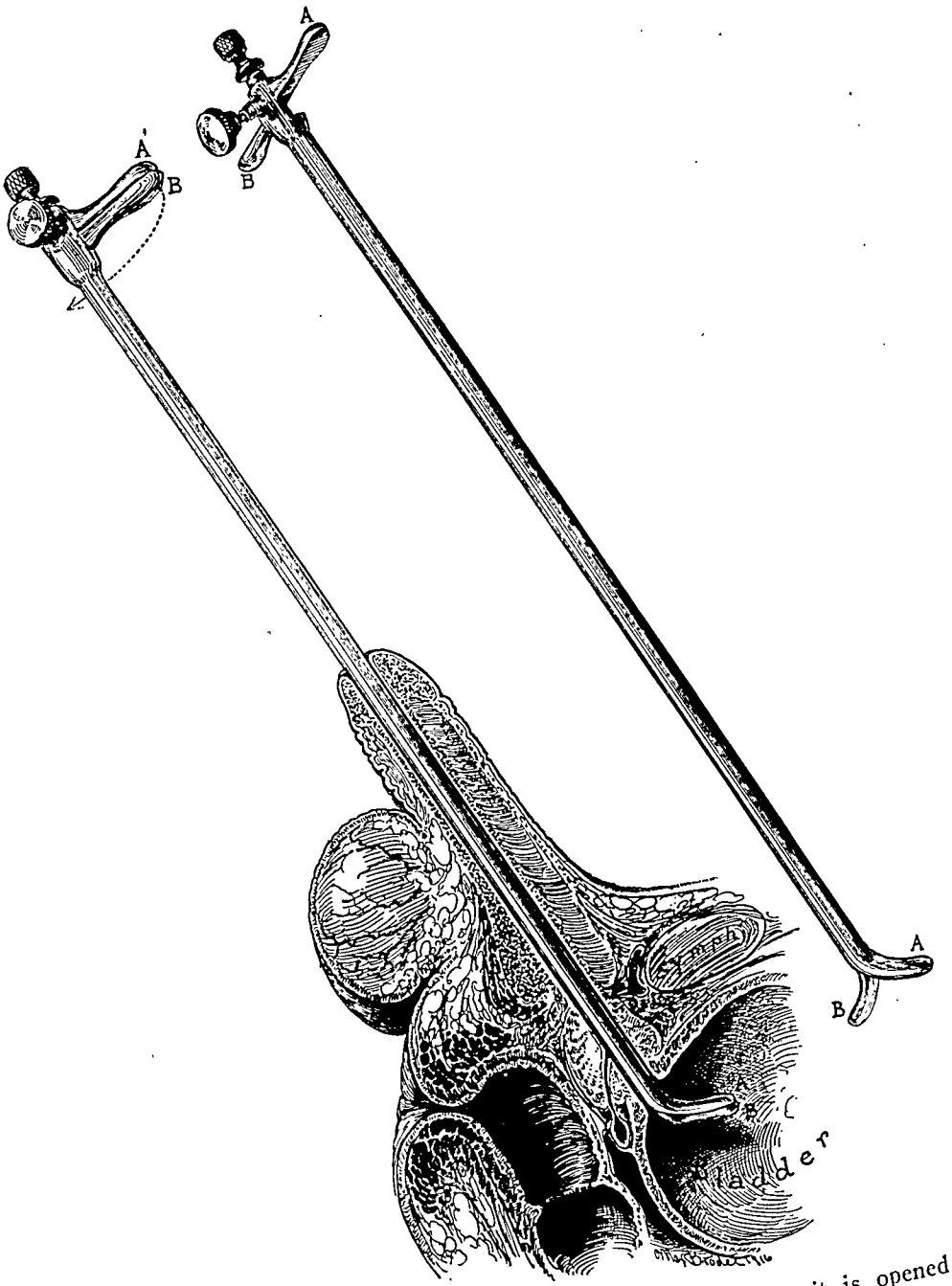

Fig. 6.—Urethral tractor carried into bladder, where it is opened out as shown in *A* and *B*.

of the central tendon and recto-urethralis muscle (Figs. 3 and 4), the membranous urethra and apex of the prostate are easily exposed without cutting the levator ani muscles (Fig. 5). Up to this point, the tractor has been introduced only sufficiently far to allow its beak to

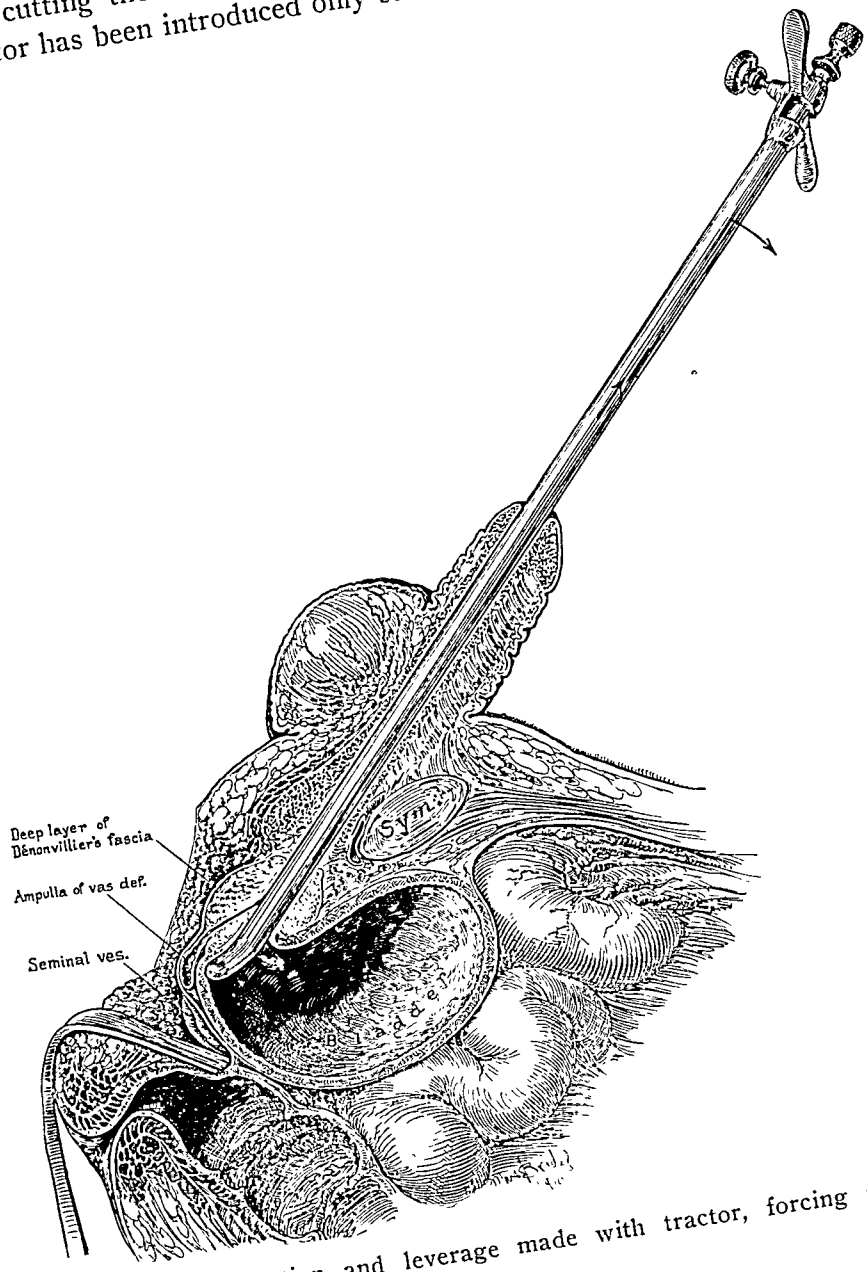

Fig. 7.—Traction and leverage made with tractor, forcing prostate and seminal vesicles into the wound.

lie in the membranous urethra, thus giving an index of this region. It is then carried into the bladder, opened out, traction made and pressure employed (Figs. 6 and 7), thus by leverage forcing the prostate and seminal vesicles up into the wound where little difficulty

is experienced in uncovering the fascia of Dénonvillier, the anterior layer of which forms the covering of, and index to, the seminal vesicles and vasa deferentia as well as the prostate. In this exposure, the levator ani muscle is drawn outward and backward with the rectum,

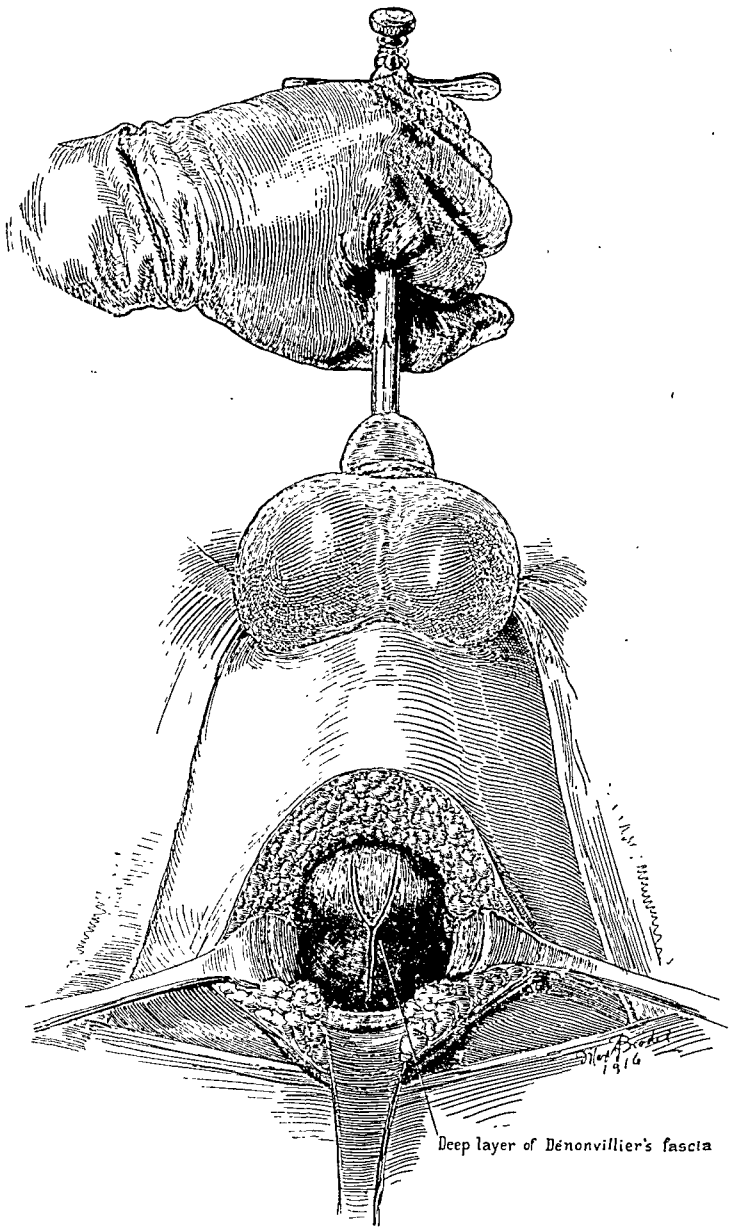

Fig. 8.—Levators and rectum drawn away, exposing fascia of Dénonvillier; Y-shaped incision through fascia.

exposing the superficial or posterior layer of Dénonvillier's fascia, which is divided near the apex of the prostate, thus uncovering the shining anterior or deep layer of Dénonvillier's fascia. The incision which must now be made through the fascia of Dénonvillier in order to

expose the vasa and seminal vesicles may vary somewhat according to the extent and character of the involvement, but as rule a Y-shaped incision (Fig. 8) has been found most satisfactory for nearly all cases in which both seminal vesicles, ampullae and lateral lobes of the prostate are involved. The fascia is then elevated on both sides, thus

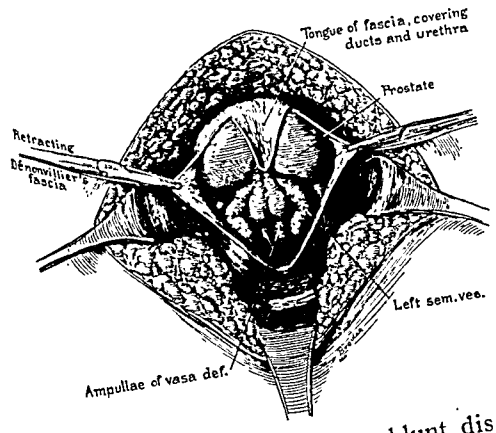

Fig. 9.—Fascia of Dénonvillier elevated by blunt dissector, exposing lateral lobes of prostate, seminal vesicles and vasa deferentia.

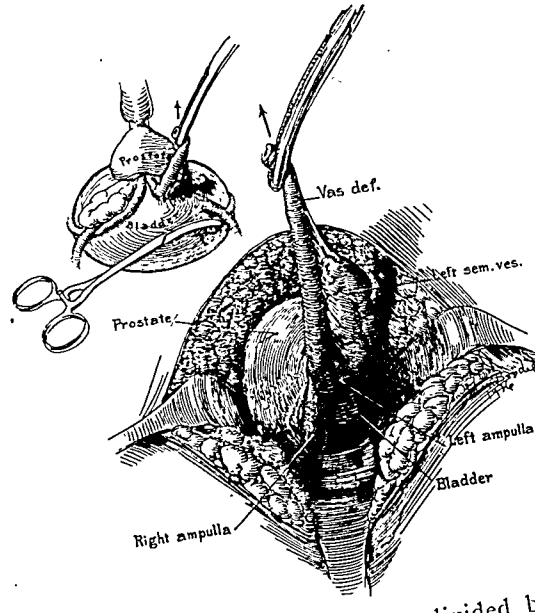

Fig. 10.—Left seminal vesicle freed, vas divided between clamps.

exposing the lateral lobes of the prostate, ampulla and seminal vesicles, and leaving the central portion of the prostate immediately beneath the urethra (in which the ejaculatory ducts lie) intact and covered by fascia, which aids in protecting them. An excellent exposure is thus obtained (Fig. 9), and it is possible to determine exactly how much

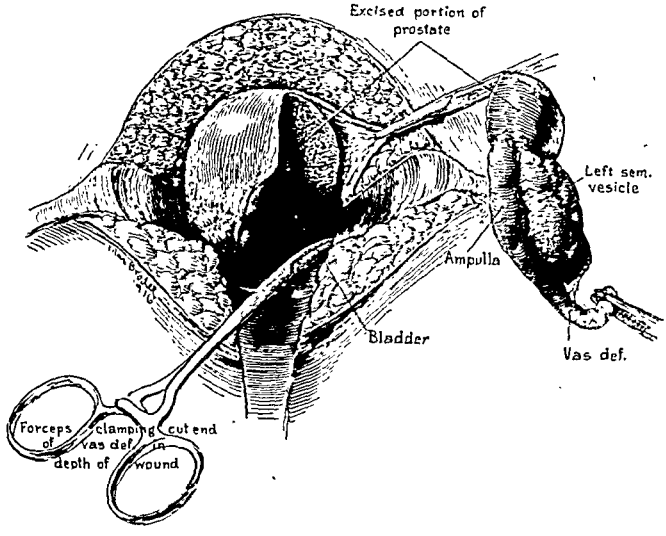

Fig. 11.—Vas, vesicle, and most of left lateral lobe of prostate have been removed in one piece; division of ejaculatory duct near urethra may be noted.

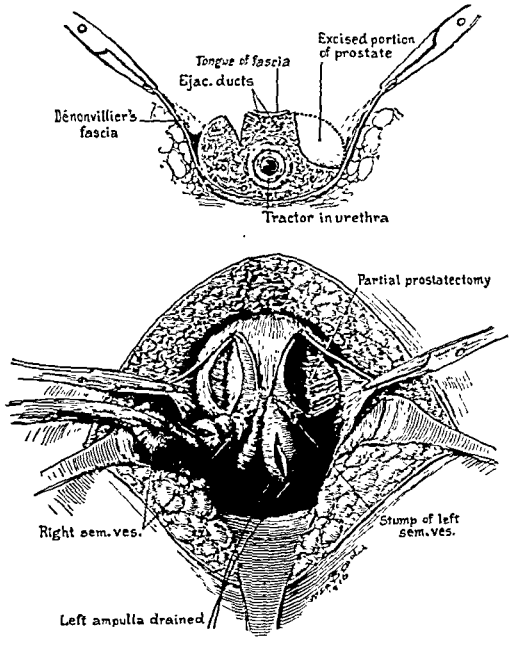

Fig. 12.—Variation: Left vesicle and lobe of prostate excised, and vas drained; right vesicle being freed; line of incisions in prostate may be noted.

should be removed, whether the disease is unilateral or bilateral, and whether one or both lobes of the prostate should be excised. Another advantage of this method is that the main blood supply which lies externally is thus drawn outward with the fascia and hemorrhage is avoided, making it possible to see well and to carry out a delicate and accurate blunt dissection without injury of the bladder, to which the ampullae and vesicles are often very adherent. The vas deferens should be freed well up toward the point where it winds around the ureter and then deeply clamped and divided, the upper clamp being left attached to assist in removal of the upper portion of the vas deferens, in case epididymectomy or castration is contemplated. The seminal vesicle on this side is then freed; firm adhesions being clamped

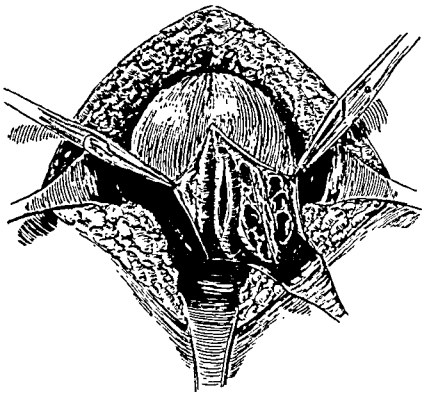

Fig. 13.—Variation: Showing drainage of vas and vesicle for chronic inflammation; posterior wall of vesicle excised.

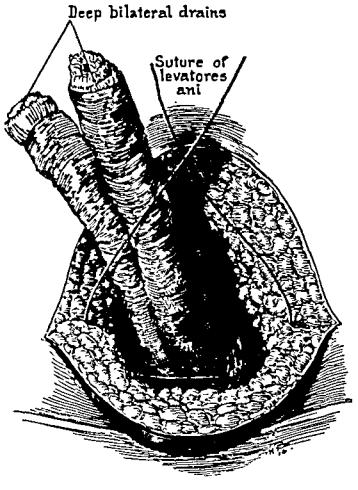

Fig. 14.—Drainage and suture.

and ligated after division in order to prevent bleeding; and, working from above downward, the seminal vesicle and ampulla are freed until the juncture with the upper portion of the prostate is reached (Fig. 10). If it seems desirable to remove a portion of the prostate, an incision is made parallel to, and at a distance of 5 mm. from, the urethra (and dividing the ejaculatory duct) but leaving sufficient tissue to avoid a urinary fistula (Fig. 11). After this, the prostate tissue is easily removed by enucleation from within its capsule, and the fascia, ampullae, seminal vesicle, and lateral lobe of the prostate are thus removed in one piece as shown in Figure 22. If the disease is bilateral, the same procedure is carried out on the opposite side (Fig. 21), working from above downward and not separating the ampullae and vesicles from one another, but removing in one piece the vesicles,

ampullae and lateral lobes of the prostate as shown in photographs of specimens removed. The wound is then partly closed, the long clamps being left attached to the upper ends of the vasa deferentia for traction later. In this closure, two iodoformized gauze drains are provided (Fig. 14), and the wound closed as in prostatectomy, leaving room

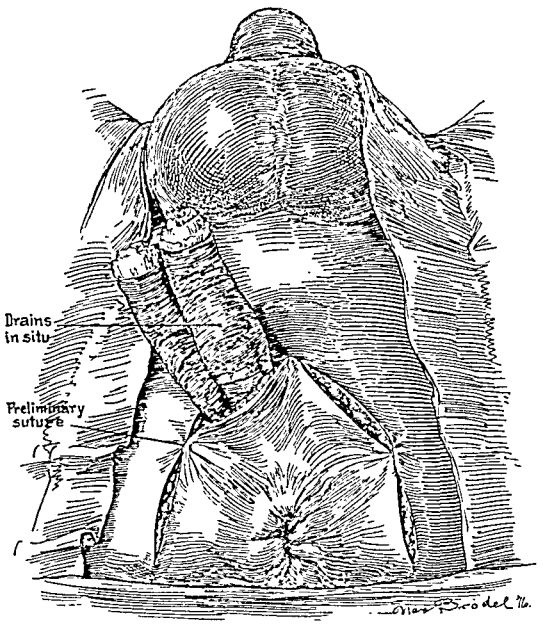

Fig. 15.—Closure and drainage of perineal wound.

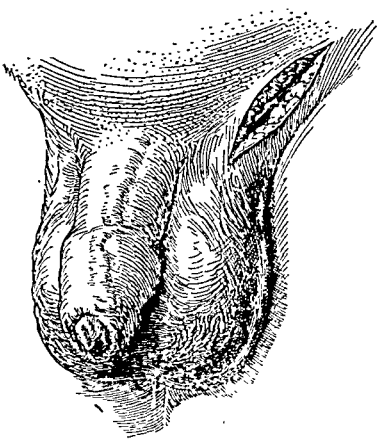

Fig. 16.—Incision in groin, with patient in horizontal position on back.

for drainage (Fig. 15). The patient is then placed on his back with the legs separated, and epididymectomy or castration carried out according to the extent of the lesion. This is also so well shown in the illustrations that detailed description seems unnecessary. The incision is usually made along the cord just below the external ring (Fig. 16)

and, after division of the dartos, the testicle is delivered (Fig. 17), the tunica vaginalis opened (Fig. 18), separation of vas and epididymis from veins and testicle carried out, and finally, division at the upper end of the epididymis made with a cautery (Fig. 19). After suturing the

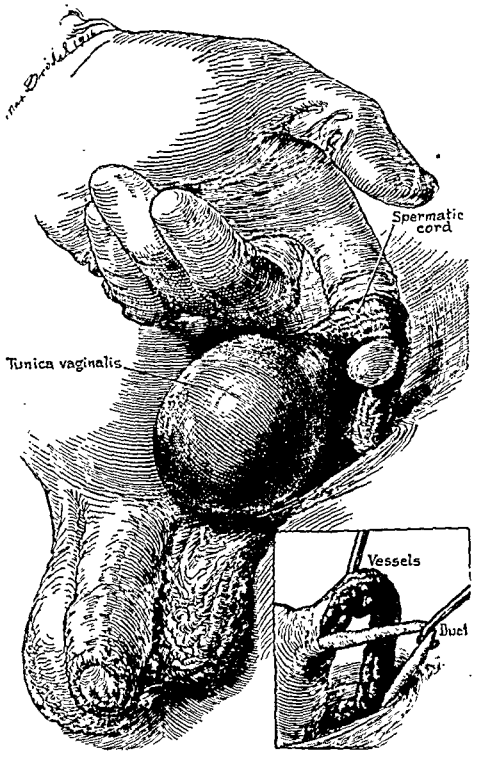

Fig. 17.—Cord and testicle delivered; separation of vas from vessels.

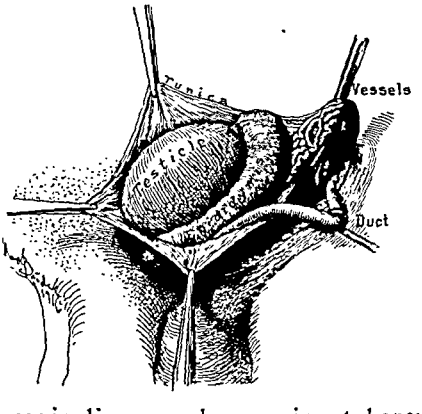

Fig. 18.—Tunica vaginalis opened, exposing tuberculous epididymis.

tunica vaginalis behind the testicle so as to avoid hydrocele formation, and after careful hemostasis, the testicles and veins are dropped back into the scrotum and the vas deferens, which has been exposed up to the external ring, is then freed from adhesions in its canal by a

to-and-fro traction (Fig. 20), produced by an assistant pulling upon the clamp (which I mentioned before as being left upon the lower end of the vas deferens), alternating with traction by the operator upon the vas deferens in the groin. In this way the vas is quickly freed, and, the vas having been liberated from the clamp by the assistant, is easily drawn out in its entirety through the groin, as shown in Figure 21. In this way is accomplished complete and radical removal of the entire seminal tract, with the exception of a few millimeters, the terminal portion of the ejaculatory duct, and we have also a conservative prostatectomy, leaving the urethra and bladder intact. This procedure, which is thorough and radical, is carried out with ease and is entirely under visual control.

Figures 25 and 26 show first of all the impossibility of satisfactory drainage through the natural passages in cases of tuberculosis of the seminal vesicles and the ampullae and epididymides. The tortuous,

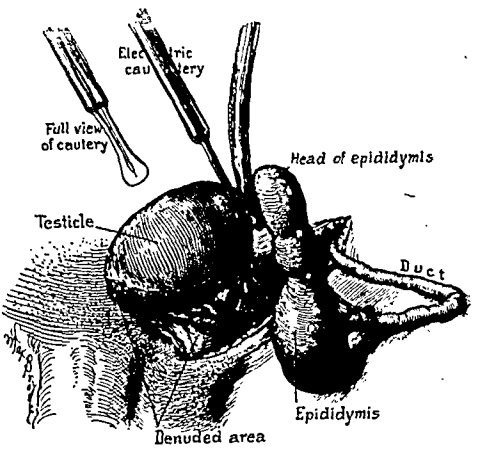

Fig. 19.—Excision of epididymis completed with electrocautery.

sacculated character of these structures is graphically shown in dissections, corrosion specimens, and roentgenograms after the injection of thorium nitrate. The importance of operations upon the vesicles in these conditions is clear.

V. HISTORIES OF FIFTEEN CASES OF EXCISION OF SEMINAL TRACT

A brief account of each of these cases, with operations, pathology and results is presented herewith. Later on an analysis is given.

REPORT OF CASES

CASE 1 (No. 3515, B. U. I.).—*History.*—C. K., aged 28, single, admitted, April 10, 1913, complained of pus in the urine. Twelve years previously he had had fever and night sweats and had lost weight, but there had been no hemoptysis. He had gonorrhea eight years previously, which lasted six weeks, complicated by rheumatism. There was no renal colic, stone or hematuria. Two

months previously, he was examined by a physician who found pus and tubercle bacilli in the urine. Cystoscopy and ureteral catheterization by a physician in New York were reported to have shown tubercle bacilli from the right kidney. He now suffered no pain, felt perfectly well and voided urine normally, and had passed no blood.

Examination.—The right kidney was apparently distinctly enlarged and felt firmer than normal; the left kidney was negative. Both testicles, epididymides, cords and groins were negative. The prostate was normal in size, smooth,

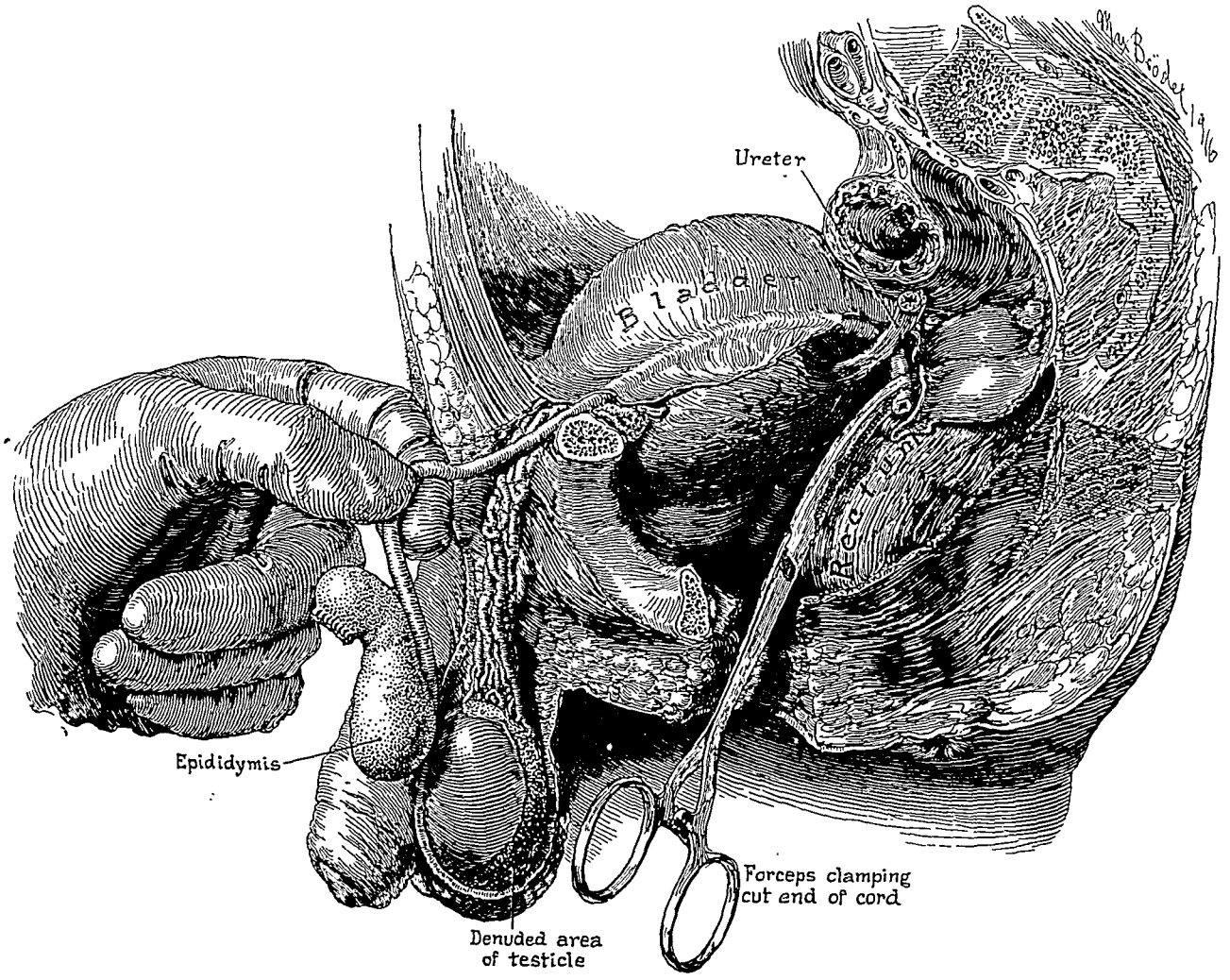

Fig. 20.—Method of traction (alternating between operator in groin and assistant pulling on clamp in perineal wound on vas) by which vas is freed and then drawn out through inguinal canal.

not indurated or tender. Both seminal vesicles were negative. The urine was clear; microscopically, there was only an occasional leukocyte. No tuberculosis was found. Cystoscopy revealed: no residual urine; bladder capacity 380 c.c.; no stricture. The left ureter was normal in appearance. The right ureteral ridge was slightly swollen, and the mucous membrane around the orifice was edematous. On the anterior wall of the bladder, very small red

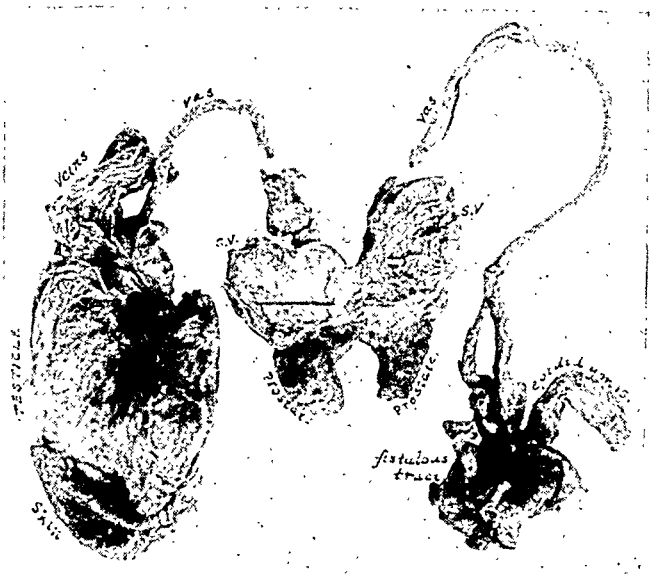

Fig. 21 (Case 4, No. 4322, B. U. I.).—Specimen, showing removal of both vesicles, vasa and lateral lobes of prostate; median portion and urethra preserved; castration on one side, epididymectomy on the other.

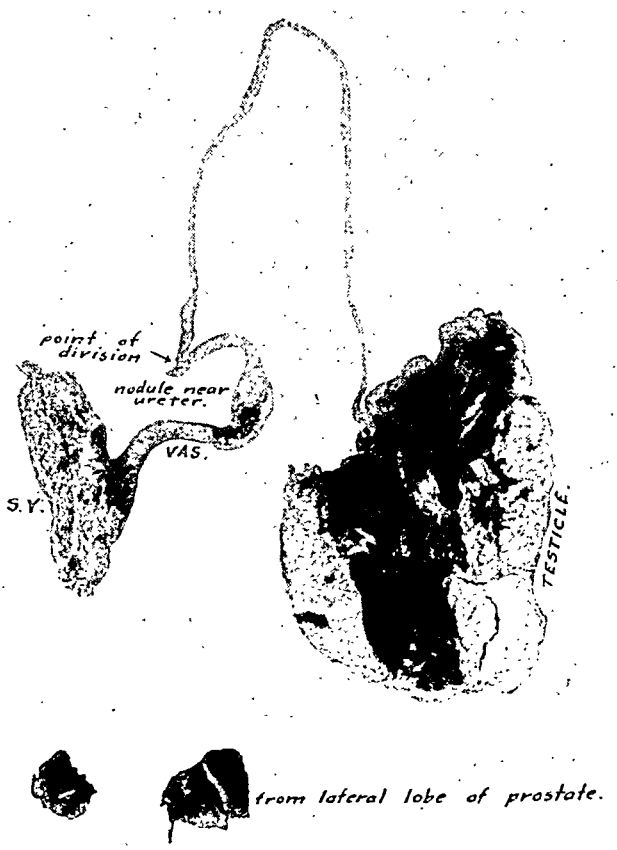

Fig. 22 (Case 3, No. 3632, B. U. I.).—Testicle with surrounding inflammatory tissue, vas, seminal vesicle, and a portion of prostate removed.

areas were seen in the mucous membrane. No ulceration was visible. The rest of the bladder was negative. The prostatic orifice was negative. Ureteral catheterization revealed: right side, urine cloudy; microscopically, epithelial cells, an occasional leukocyte. No bacteria were found. Urine from the left side was clear, and microscopically negative.

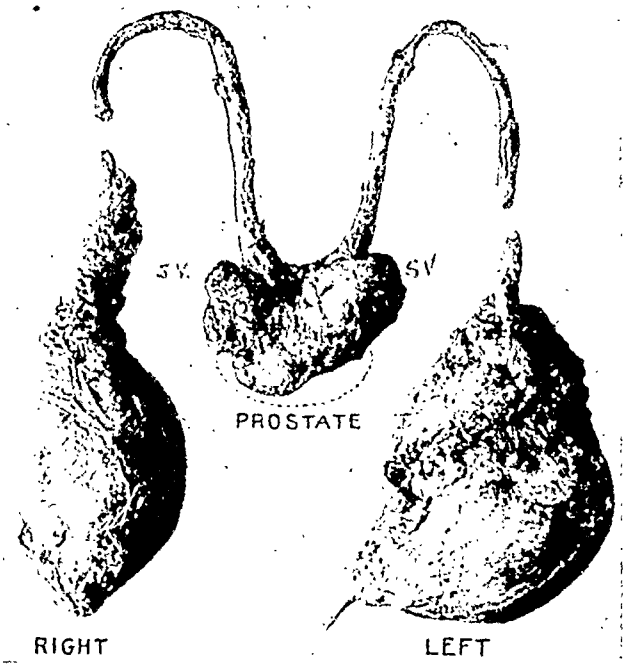

Fig. 23.—First total excision of seminal tract, bilateral, and part of prostate ever performed (1900).[14]

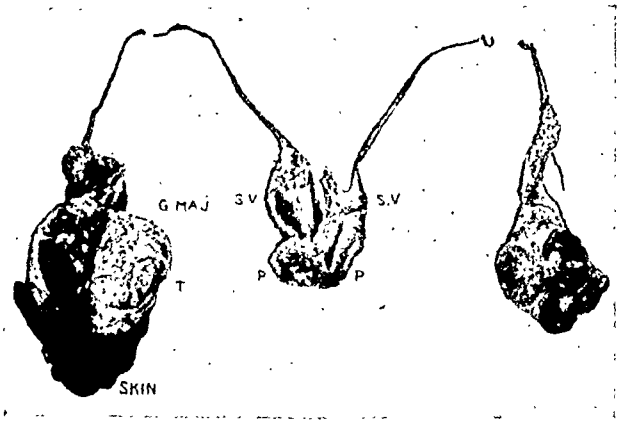

Fig. 24.—Specimen from second case in which removal was accomplished by suprapubic retrocystic extraperitoneal route.

The patient was advised to go to a mountain resort, Saranac Lake. Here pus and acid-fast bacilli were found in the urine; but animals injected with the purulent urine did not die of tuberculosis. March 24, 1914, a letter from this physician said: "Last catheterized specimen of bladder urine contained numerous tubercle bacilli." One month before, and two days after intercourse,

14. Young, H. H.: Ann. Surg. **30**:601, 1901.

there was a slight pain in the upper end of the left epididymis. The next day the swelling had increased very rapidly so that there was a marked enlargement, which seemed to involve the entire testicle and was very tender. Swelling has remained; but the pain has now disappeared. There is no difficulty or frequency of urination.

Urine voided in three glasses was clear, and contained only a few fine shreds in all three glasses. There was no urethral discharge. The right testicle, epididymis and vas were normal. The left side of the scrotum was

Fig. 25.—Injection of vesicles with thorium, showing tortuous cavities and impossibility of adequate drainage.

Fig. 26.—Corrosion specimens showing multiplicity of cavities in vesicles.

enlarged and reddened; there was a small hydrocele but the testicle did not seem enlarged or indurated. The entire epididymis was greatly enlarged, markedly indurated and moderately tender, but not adherent to the skin. The vas deferens was slightly enlarged, smooth and slightly indurated. Rectal examination revealed: prostate, normal in size and consistency; right seminal vesicle, palpable, possibly very slightly indurated and adherent; left seminal vesicle, indurated. The inner side of the vas deferens could be palpated for a distance of about 3 cm. above the prostate. Moderate adhesions were present.

Comment.—We were dealing with a definite tuberculosis of the left epididymis, vas and seminal vesicle. Tuberculosis of the right kidney was probable. It seemed wise to excise the seminal tract.

Operation (Young).—April 6, 1914, under nitrous-oxid, oxygen-ether anesthesia, the left seminal vesicle and ampullae and a portion of both lobes of the prostate were removed through the perineum. The right seminal vesicle, ampullae and prostate were not disturbed. The left epididymis with a portion of the skin around the discharging sinus and the entire vas deferens were removed through an incision in the left groin. The testicle was found not to be involved, and was not disturbed. Both wounds were packed and partially closed.

Pathologic Report.—There was extensive tuberculosis of the epididymis and lower portion of the seminal vesicle; the ampullae of the vas deferens were markedly tuberculous; the rest of the vas deferens was not involved.

Course.—May 14, 1914: The patient was discharged from the hospital. Convalescence was satisfactory. There was no urinary leak through the perineum. Both wounds were granulating nicely; there was no fistula. The left testicle was only slightly indurated. The patient retained urine for three or four hours and voided freely without pain. He had had no pain in the region of either kidney. The general health was excellent. There was no cough, expectoration or pyrexia.

Feb. 6, 1915: The patient had been treated with tuberculin and his general health had greatly improved. His chief complaint was the persistence of two small discharging sinuses. The urine was clear and contained microscopically only a few pus cells and no tubercle bacilli. Roentgenograms of the kidneys were negative. Examination of the chest was negative. The kidneys were not palpable or tender. There was a small sinus in the scrotum. The perineal wound healed solidly. Rectal examination showed a slight cicatrix but no evidence of tuberculosis.

Feb. 25, 1920: The patient returned for observation. He said his general health was excellent; he felt completely cured. Sexual powers were quite normal; he had intercourse every week. He passed urine every three or four hours; micturition was normal. He had no pain in either kidney; no fever, chills or night sweats. The right testicle, epididymis and vas were normal. The left testicle was normal in size, smooth and soft; the epididymis and vas were absent. There was no sinus. Rectal examination demonstrated the prostate to be about normal in size and consistency, slightly indurated at the upper end. The right seminal vesicle was apparently soft and normal. The left seminal vesicle was absent; there was slight induration in that region.

March 5, 1921: A letter said: "It is now seven years since operation. I am apparently completely cured, my only complaint being a slight irritation at neck of bladder, lasting a few seconds after urination. Urine voided normally about every three hours and once at night. I have had no trouble with my kidneys. Sexual powers normal. Urine contains pus. My physician still thinks that I may still have an infection of the right kidney."

CASE 2 (No. 4158, B. U. I.).—*First Admission.*—L. J. R. D., aged 42, married, admitted, Feb. 17, 1914, complained of a swollen testicle. He had had gonorrhea at the age of 25 and again at the age of 40; syphilis at the age of 37, treated by internal medicine. Four months previously, during "convalescence from typhoid," the left testicle began to swell. It was only slightly

painful in the beginning and since then there had been no pain except during the last few days. There was no complaint referable to the bladder or kidneys.

Examination.—The patient was of apparently excellent physique. The chest showed no definite areas of dulness; no increased fremitus. However, there were numerous râles, of coarse character, over both bases, especially marked between the fifth and sixth ribs, posteriorly. The penis was normal. The right side of the scrotum was normal; the left side was filled with a large rounded mass, consisting of hydrocele and considerably enlarged, indurated, nodular epididymis. The testicle could not be made out in the hydrocele. The vas deferens was indurated and enlarged. Rectal examination revealed: pros-

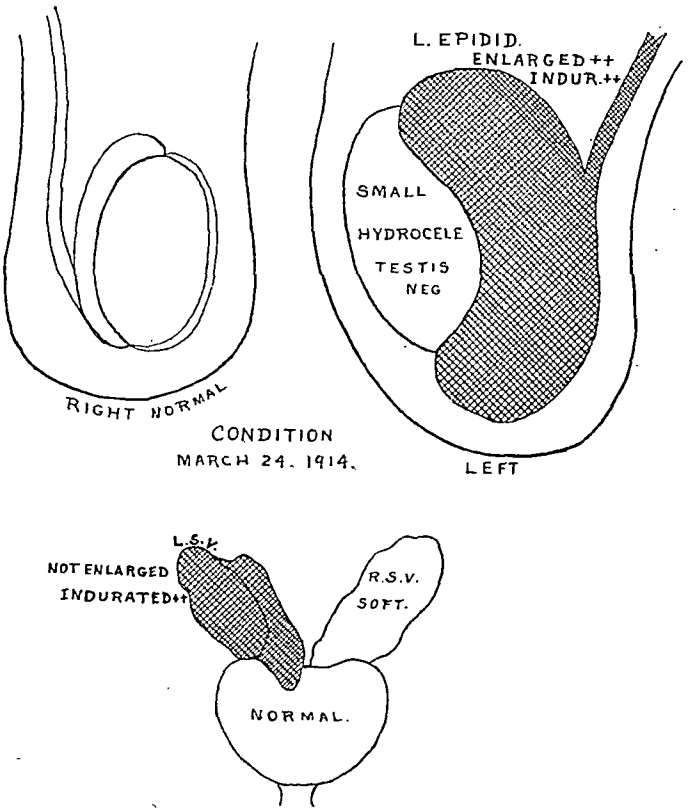

Fig. 27.—Scrotal and prostatic diagram showing regions found involved on examination before operation. This and subsequent diagrams of other cases were made during physical examination of the patient. Normal structures are white; slight induration is indicated by parallel lines; fairly marked induration by crossed lines. Adhesions are also shown.

tate, enlarged on the left side, nodular and very hard; right lobe of the prostate, negative. The left seminal vesicle was also considerably enlarged, indurated and nodular. The right seminal vesicle was only slightly indurated and not enlarged.

The urine contained a few pus cells but no bacteria. One per cent. tuberculin test was positive; Wassermann and luetin tests were negative. The results of the phenolsulphonephthalein test were: appearance time, ten minutes; first hour, 50 per cent.; second hour, 38 per cent. Cystoscopy revealed a normal

bladder. The ureters were catheterized; the urine from both sides was clear, and microscopically negative. This appeared to be a case of tuberculous epididymitis, vasitis and left seminal vesiculitis, and the left lobe of the prostate was affected. It seemed that a radical operation was indicated.

Operation (Young).—Feb. 27, 1914, under ether, a radical operation was performed. The left seminal vesicle (Fig. 28), the ampulla of the vas deferens and the left lobe of the prostate were excised through the perineum. The left testicle, epididymis, cord and the remainder of the vas deferens were removed through a left inguinal incision. Complete closure of the incision and partial closure of the perineal incision with gauze packs followed.

Comment.—The left seminal vesicle and left lobe of the prostate were greatly distended with pus, which escaped during the operation.

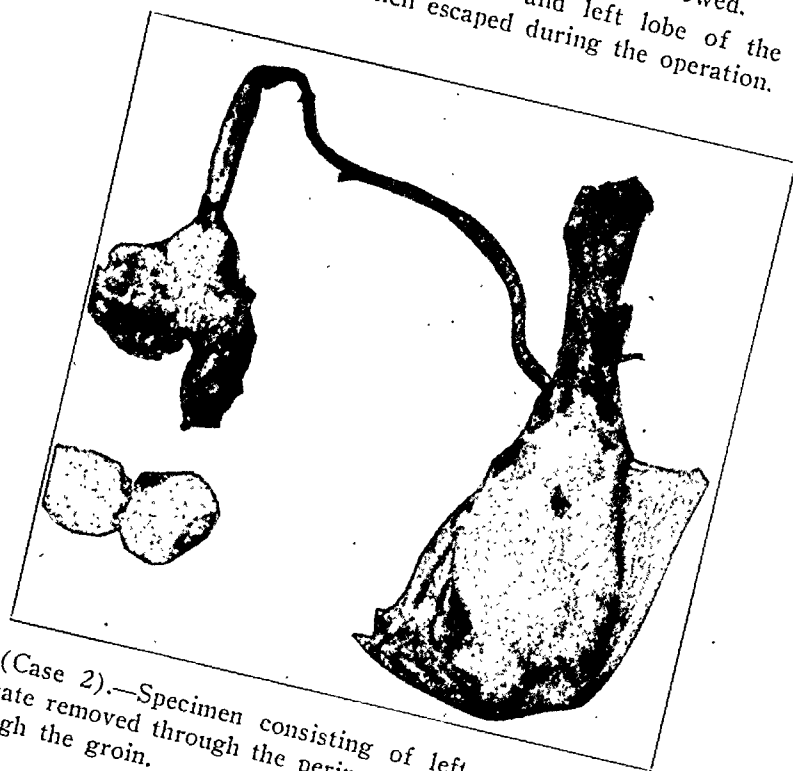

Fig. 28 (Case 2).—Specimen consisting of left vesicle, ampulla and left lobe of prostate removed through the perineum; castration and vasectomy performed through the groin.

Pathologic Report.—The left seminal vesicle and the 5 cm. (2 inches) of ampulla attached were markedly tuberculous. The prostatic tissue removed weighed 5 gm. and was markedly tuberculous, as were also the testicle and epididymis.

Course.—The patient made an excellent recovery from the operation and was discharged, March 22, 1914, with a perineal fistula through which a small amount of urine escaped at times.

Second Admission.—April 13, 1914, he was readmitted complaining of persistent perineal fistula, fever and night sweats. Examination revealed a small fistula in the perineum through which urine escaped. Rectal examination showed slight induration of the right lobe of the prostate and of the right seminal vesicle. The left seminal vesicle and left lobe of the prostate were absent. There was moderate cicatrix; but no fluctuation and no evidence of abscess.

The patient remained in the hospital until July 20. During this time he continued to have fever which ranged between 100 and 102.5 F. at night. The urinary condition seemed excellent. Beck's paste injected into the fistula was ineffectual. The temperature indicated deep-seated tuberculosis, probably of the lungs, but not definitely made out. The urinary tract was negative.

Third Admission.—Jan. 28, 1915, he complained again of perineal fistula. He had had night sweats off and on since his last discharge. For the last two months, he had had pain in the chest and swelling on the left side of the sternum in the region of the second rib.

Examination.—The patient was emaciated; anemic and pale. At the junction of the second costal cartilage with the sternum, there was a rounded fluctuating mass about the size of a small hen's egg, which was not tender. The chest was of the flat type; the infraclavicular fossa was well marked; expansion was poor. The percussion note and vocal fremitus were greater on the right than on the left. Expiration was harsher and more prolonged on the right than on the left. The kidneys were neither palpable nor tender. The penis was normal. On the left side of the scrotum, the testicle was absent, and there was a small discharging sinus. The right testicle was normal in size, shape and consistency. The right epididymis was slightly enlarged, irregular and indurated throughout. The vas deferens was about three or four times the normal size and indurated up to the external ring. In the perineum, there was a scar and a urinary fistula. Rectal examination revealed: right lobe of prostate, slightly irregular, indurated and adherent. In the region of the left lobe, there were adhesions which obscured the outline of the prostate. The tissues were not greatly indurated here nor enlarged. The right seminal vesicle was moderately indurated, enlarged and adherent. On the left side, the testicle was absent and there was only moderate cicatricial induration. The rectal wall was negative.

February 7, the patient was apparently going down hill and had tuberculosis of the remaining seminal vesicle and of the right epididymis. There was apparently also involvement of the lung and probably of the chest wall. It was thought wise to perform epididymectomy under local anesthesia and to inject the seminal vesicle with oil containing iodoform, through the vas deferens into the groin.

Operation (Frontz).—February 8, under local anesthesia (procain 1:400), an incision was made in the groin; the testicle and cord were withdrawn. Epididymectomy was performed, with removal of the vas up to the groin. The wound was closed.

Pathologic Report.—Examination of tissue revealed extensive tuberculosis of the epididymis.

Course.—February 11: Since operation, the patient had suffered with continuous hiccups. The temperature, which before operation rose to 102 or 103 F. every evening, had risen only to 99 F. The fluctuating mass in the chest wall had increased and now measured 8 by 13 cm. and extended from the lower border of the first rib to the upper border of the fourth rib on the left side of the sternum. This was aspirated for diagnosis, and pus withdrawn—no tubercle bacilli or other bacteria were found in it. The abscess was then incised and about 2 ounces (59.2 c.c.) of pus evacuated. Cultures were negative

February 13: A roentgenogram of the chest showed a mediastinitis; generalized involvement of both lungs, especially the upper left, with slight pleural thickening over this region. Both apexes were infiltrated, with some clouding of the right. There was a small consolidated area in the left upper lobe above the third rib. The right side of the diaphragm was "hooked up."

February 20: Hiccups had persisted. The evening temperature ranged between 98 and 101 F. Today, a fluctuating swelling, 3 by 5 cm., appeared beneath the skin of the right shoulder above the acromioclavicular joint. This was incised and about an ounce (30 c.c.) of greenish-yellow pus evacuated.

March 8: The patient had had no hiccups for the last ten days. The wounds in the shoulder and chest wall were still discharging. There was daily evening pyrexia. March 7, temperature was 101.8 F. The perineal fistula was not yet closed. There were no sinuses in the groins or scrotum. The patient was discharged. Owing to the extensive involvement in the chest, the prognosis was bad.

One month after leaving the hospital, the patient died.

Comment.—At the present time, in such a case, with involvement of the lungs, a general anesthetic would not be given; but local anesthesia would be employed as in Case 12.

CASE 3 (No. 3632).—*History.*—M. L., aged 23, single, admitted June 1, 1914, complained of pain in the scrotum. The patient denied gonorrhea. Ten months previously, he was treated for sexual weakness by urethroscopic applications of silver nitrate to the verumontanum and received a few massages of the prostate, which were discontinued on account of pain. He received no further treatment until Feb. 1, 1914, when the right "testicle became swollen and tender." There was no urethral discharge and a urologist diagnosed the condition as "lues." The Wassermann reaction was positive and the patient received two injections of arsphenamin. The enlargement did not diminish after treatment with arsphenamin and remained hard and tender. The patient had had no fever, no cough, no frequency or difficulty of urination and no hematuria.

Examination.—The patient was pale and thin. The chest was normal; expansion was free; the lungs, heart and abdomen were negative. Urine voided into three glasses was clear, with numerous shreds in the third glass. Careful examination for tubercle bacilli was negative. Tuberculin eye test was positive. There was no urethral discharge; the penis was normal; the left testicle was normal; the epididymis was slightly tender but not indurated. On the right side, the scrotum was considerably swollen; the testicle was surrounded by hydrocele but was apparently soft and normal. The right epididymis was enlarged throughout and about 1 inch (2.5 cm.) in diameter, hard, tender, with no adhesions to the skin, and no sinus. The vas deferens was apparently normal in size, only slightly indurated and not tender. Rectal examination revealed: left lobe of prostate, enlarged, very hard, particularly at the upper end; right lobe, hard with slight enlargement at the upper end. The lower portion of the right lobe was apparently normal. The right seminal vesicle was a little broader than normal, slightly irregular, slightly indurated and adherent. The left seminal vesicle was soft in its upper portion, slightly indurated and adherent; the lower portion apparently was not enlarged. Neither vas deferens can be made out distinctly.

Operation (Young).—June 5, under nitrous oxid, oxygen and ether, a radical operation was performed, consisting of removal through the perineum of the right seminal vesicle and both lateral lobes of the prostate, all of which were tuberculous. The urinary tract was not opened. Right castration and removal of the remainder of the right vas deferens (Fig. 22) were performed. The wound in the groin was closed completely. The perineum was partially closed and packed with gauze.

Pathologic Report.—The specimen consisted of the right seminal vesicle and ampulla, 11 cm. long, two portions of lateral lobes of prostate, testicle, epididy-

mis and vas, 17 cm. long. The seminal vesicle was indurated, nodular and filled with brownish serum. The ampulla contained a large yellow nodule containing creamy pus. The right lateral lobe of the prostate contained numerous tuberculous areas. The left lateral lobe of the prostate was fibrous; no tuberculosis was seen. The testicle and epididymis both contained numerous areas of caseous tuberculosis.

Course.—The temperature was 102 F. on the fifth day; after that it soon returned to normal. All drains were removed on the fifth day; there was no urinary leakage.

June 26: Convalescence was uneventful. There had been no urinary leakage since operation. The wound had healed. The patient was discharged in good condition.

Jan. 13, 1916: The patient returned much improved. He retained urine five hours and did not have to void at night; there was no urinary symptoms There was no perineal urinary fistula. The right testicle and epididymis were missing; the left testicle, epididymis and vas were negative. The right seminal vesicle and left lobe of the prostate (excised at operation) were moderately indurated and cicatricial; the left seminal vesicle was slightly enlarged and indurated. The urine was negative. Careful search for tubercle bacilli was made but none were found.

June 28: The patient returned complaining of recent swelling of the left epididymis. His general condition was good otherwise. There were no urinary symptoms, no sinuses or fistulas. Examination showed that the left testicle was normal, the globus minor of the epididymis was markedly enlarged, indurated and tender, the swelling was almost entirely limited to the globus minor. There was a slight induration of the globus major; the vas was slightly indurated, nodular and enlarged. The left seminal vesicle was markedly adherent, indurated and tender. The prostate was negative. The right vesicle was absent; there was moderate cicatrix. The urine was clear, with a few shreds.

Operation (Colston).—June 30, a left epididymectomy was performed through an incision in the groin. The globus minor was found to be markedly enlarged, with a small abscess between it and the testicle. The globus major and testicle were apparently negative. Complete epididymectomy was performed, with removal of the vas in the groin. The stump was cauterized with phenol and ligated. The wound was closed without drainage.

July 8: The patient left the hospital in six days. The postoperative course was uneventful. The wound healed by first intention. The general condition was excellent.

March 8, 1921: Numerous questionnaires have been sent to the patient. None was returned, although evidently they have been received. It is impossible to get any information as to the condition. The patient was probably alive, but outrageously unappreciative. Apparently, a good result was obtained.

Comment.—In this case and also in Case 2, both seminal vesicles and ampullae should have been removed. This would almost surely have prevented the subsequent involvement of the remaining epididymis and, possibly, have saved life in Case 2.

Case 4 (No. 4322, B. U. I.).—*History.*—J. E., aged 28, admitted, April 17, 1915, complaining of urethral fistula, gave no history of pulmonary disease. He had had gonorrhea seven years previously and again three years later, and for a third time one year previously. About three weeks after the begin-

ning of the last attack, the patient had pain and swelling in the perineum and urination became difficult, a catheter being required for two weeks. Shortly afterward, the patient developed enlargement of both sides of the scrotum. In December, 1914, the swelling in the perineum recurred and an operation was performed, an abscess being evacuated. Since then, the patient had had a perineal urinary fistula. Two weeks later, the "left testicle became soft and ruptured," leaving a discharging sinus. "The right testicle" remained swollen but not broken down. The patient voided urine with considerable difficulty, but most of the urine came through the meatus, a small amount through the perineal fistula. The urinary stream was weak and small; but he had no increased frequency of urination, and did not void at night. There was no history of renal pain or hematuria. Sexual powers were normal.

Examination.—The patient was a poorly nourished, pale man. The chest expansion was good and equal on both sides. The heart was negative. Neither kidney was palpable or tender. The penis was negative. The left testicle was normal in size; there was no hydrocele. At the lower end of the scrotum on the left side were two sinuses from which pus was escaping. They evidently were connected with the globus minor of the epididymis. The globus minor was enlarged about 1 inch (2.5 cm.) in diameter, and markedly indurated. The body and globus major of the epididymis were apparently not enlarged nor indurated. The vas deferens was slightly indurated, but not nodular nor enlarged. On the right side there was considerable swelling of the scrotum, and no sinus. There was a small hydrocele; the testicle was tender; its size was not accurately made out. The globus minor of the epididymis was greatly enlarged, about 1½ inches (3.8 cm.) in diameter and adherent to the skin, at places fluctuating. The body and globus major were also considerably enlarged, indurated and tender. The vas deferens was indurated, but not enlarged. In the perineum, there was a small fistula through which urine escaped. The prostate was broader than normal, irregular, indurated and adherent. The right seminal vesicle was considerably enlarged, indurated and adherent externally. The left seminal vesicle was also much enlarged, indurated and adherent. Between the two, there was an area of induration. The urine was cloudy; specific gravity was 1.011; it gave an acid reaction and contained leukocytes. The cystoscope entered with ease, there being no stricture. Residual urine was about 130 c.c. The bladder was slightly trabeculated; otherwise it was negative. The ureteral orifice negative; both ureters were catheterized. The urine obtained was clear and microscopically negative. The phenolsulphonephthalein test was good and equal.

Operation (Young).—April 15, 1915, under nitrous oxid, oxygen and ether anesthesia, a radical operation was performed, consisting of removal through the perineum of both seminal vesicles, ampullae and a larger portion of each lateral lobe of the prostate, in one piece, without injury to the urinary tract (Fig. 21). The perineal fistula was excised and the wound was partially closed with drainage. Right castration was performed by traction through the groin. Part of the scrotum was adherent to the epididymis and to most of the vas deferens. A portion broke off and did not come away. Left epididymectomy was performed and a section of the scrotum around the sinus was removed. The entire vas was removed by traction through a scrotal incision. The scrotal wound was partially closed, with drainage.

Pathologic Report.—Both seminal vesicles and the right ampulla were tuberculous. The lateral lobes of the prostate were not definitely tuberculous. There

was much scar tissue. The left globus minor was definitely tuberculous, but the body and globus major were apparently normal and the vas deferens appeared to be normal. On the right side, there was a large abscess which apparently involved the globus minor and partially involved the testicle. The remainder of the testicle was apparently normal. The body and globus major of the right side were tuberculous. Microscopic confirmation was obtained everywhere.

Course.—The drains were removed on the fourth day. A catheter was introduced into the urethra.

April 28, the patient had been having pyrexia, reaching as high as 101 F.; his condition otherwise was good. Most of the urine was voided through the urethra; the perineal fistulas were still open. The scrotal wounds were apparently healed.

May 10, the patient continued to have moderate pyrexia every evening. The leukocyte count was 10,000; the chest was negative; the cause of fever was not explained.

May 28, the patient was discharged. The general condition was good. Small fistulas in the perineum were still open and a small amount of urine escaped at urination. (This fistula was present on admission and before seminal vesiculectomy.)

March 15, 1921, numerous questionnaires and letters had been sent to the patient. They had not been returned. The patient is probably alive, but negligent.

CASE 5 (No. 4330).—*History.*—S. K., aged 30, married, admitted, April 24, 1915, complaining of swelling of the right testicle, gave no history of venereal disease, and no pulmonary history. The present illness began three and one-half years before with a "small swelling on the side of the left testicle," which gradually became bigger and finally formed an abscess and discharged pus. He consulted a surgeon who performed a left epididymectomy, and after that, the patient had remained entirely well until the present time. Two and a half months before, the right testicle began to swell and, ten days before, a small suppurating sinus appeared. There was no frequency, difficulty nor pain on urination; no history of pain in either kidney nor hematuria. Sexual powers had been normal until two months previously, since when there had been little desire. The patient's general health was good.

Examiation.—The patient was well-nourished, and weighed 170 pounds (77 kg.). The heart and lungs were negative. The kidneys were not palpable. Examination of the genitalia revealed no urethral discharge; the penis was normal; the right testicle was normal; the epididymis was indurated and enlarged; there was a small discharging sinus. The left epididymis was absent (previous epididymectomy); the testicle was negative. Rectal examination revealed considerable induration and enlargement of both seminal vesicles and a portion of the prostate. The right vas was apparently indurated and enlarged.

Operation (Young).—April 25, 1915, under nitrous oxid, oxygen and ether anesthesia, a radical operation was performed, consisting of removal through the perineum of both seminal vesicles, both ampullae and a large portion of the right lateral lobe of the prostate, without opening the urinary tract. All tissues removed were markedly tuberculous (Fig. 29). Gauze drainage was used, with partial closure. Right castration was performed, with removal of all the remaining vas deferens. Examination seemed to show involvement of the testicle as well as of the epididymis. The scrotal wound was drained with gauze and partially closed.

Pathologic Report.—Both ampullae and the lateral lobe of the prostate were markedly tuberculous. The epididymis was tuberculous; but careful examination of the testicle showed no evidence of tuberculosis. The testicle was obscured by a hydrocele and a very thickened tunica, but the testis was normal.

Course.—Considerable shock followed the operation. This was relieved by infusions. Drains were removed on the fourth day. The perineal wound broke down and was very slow in healing. On discharge, three months after operation, the patient had a persistent fistula through which all urine came when he was on his feet. Various methods, including a retention catheter, were employed without success in closing the fistula. His condition otherwise was excellent.

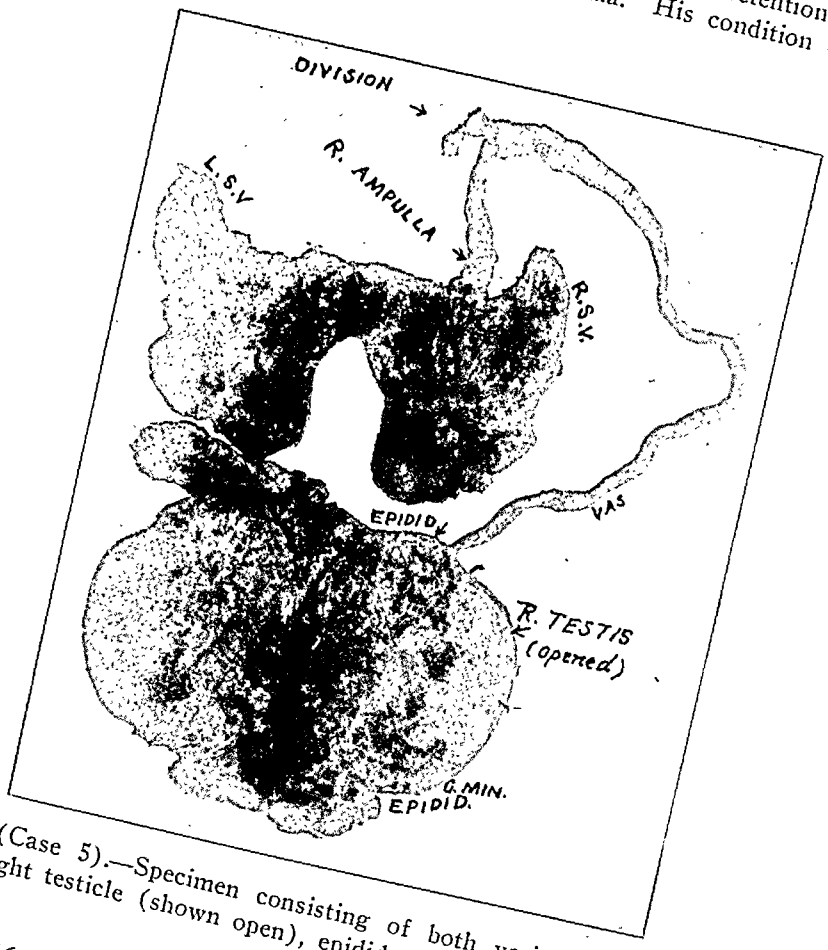

Fig. 29 (Case 5).—Specimen consisting of both vesicles and portion of prostate. Right testicle (shown open), epididymis and entire vas removed.

Sept. 6, 1916, one year after operation, the patient was in excellent health with the exception of a urinary fistula in the perineum. Operation, consisting of the excision of fistulous tract, was unsuccessful. On discharge, he still had perineal leakage.

May 27, 1920, a letter reported: "I void urine entirely without pain about every three hours during the day and twice at night. Urine is clear. I have no symptoms referable to either kidney. No fever nor sweats. General health good. With almost every urination, small amount of urine escapes through perineal fistula. Have no bladder trouble."

Feb. 6, 1921, a letter stated: "Condition same as at last report. General condition excellent. Small urinary fistula persistent. No escape of urine except when voiding and then only a small amount."

CASE 6 (No. 4980, B. U. I.).—*History.*—W. C., aged 34, single, admitted, March 21, 1916, complained of a swollen testicle and a discharging sinus. Pulmonary history was negative. He had had gonorrhea in 1901, but was cured in a few days. There was no epididymitis or stricture. The present illness began three months previously with swelling in the left testicle following traumatism; pain was never very acute. About three weeks previously, the swelling was incised and had since been draining pus. There was no history of any night sweats or loss of weight. Urination and sexual powers were normal.

Examination.—He was a healthy looking man. The lungs were negative with the exception that in the right posterior base, in the scapular line, there

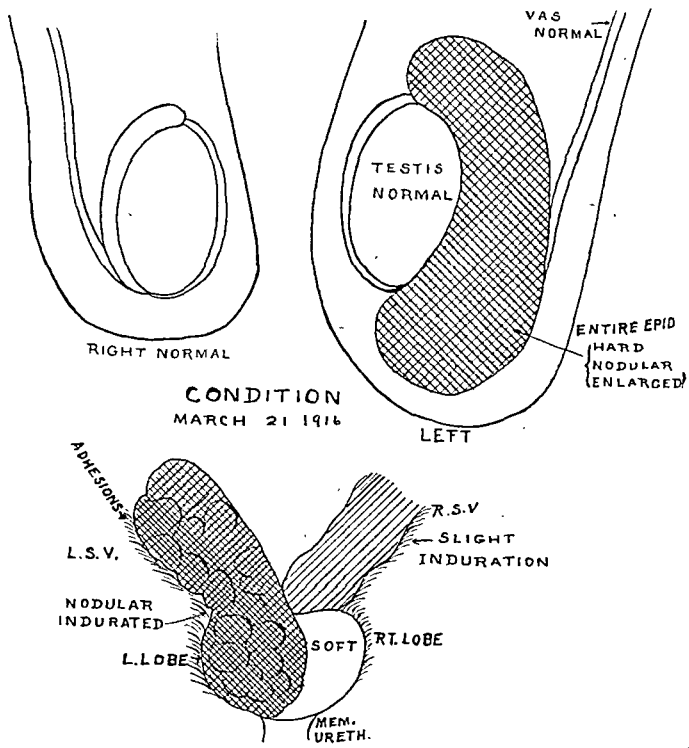

Fig. 30.—Clinical diagram of regions involved before operation.

was a small area in which inspiration had a tubular character. No râles were heard anywhere, even on coughing. The heart and kidneys were negative. The right testicle, epididymis and cord were negative (Fig. 30). The left testicle was surrounded by a soft hydrocele and was apparently negative. The epididymis showed considerable enlargement throughout its extent and was quite irregular, hard but painless; the point of greatest enlargement was in the globus minor, which was about an inch in diameter (2.5 cm.), and from this a small sinus extended through the skin. The left vas was normal. The prostate was not enlarged, but the right lobe was slightly irregular and indurated. The left lobe was a little larger than the right, quite irregular, almost nodular, moderately indurated and adherent. Induration extended up and was continuous, with considerable enlargement and induration of the left

seminal vesicle, which was nodular and adherent. The right seminal vesicle was definitely palpable, but appeared soft and not adherent. The urine was clear and acid; microscopically, a few leukocytes were found but no bacteria, on several examinations.

The impression was that of tuberculosis of the left seminal tract and prostate. Radical operation was indicated.

Operation (Young).—April 3, under nitrous oxid, oxygen-ether, a radical operation was performed consisting of removal through the perineum of the left seminal vesicle and ampullae and a portion of the prostate (Fig. 31). The rectum was very adherent, and a tear was made into it by the finger of the

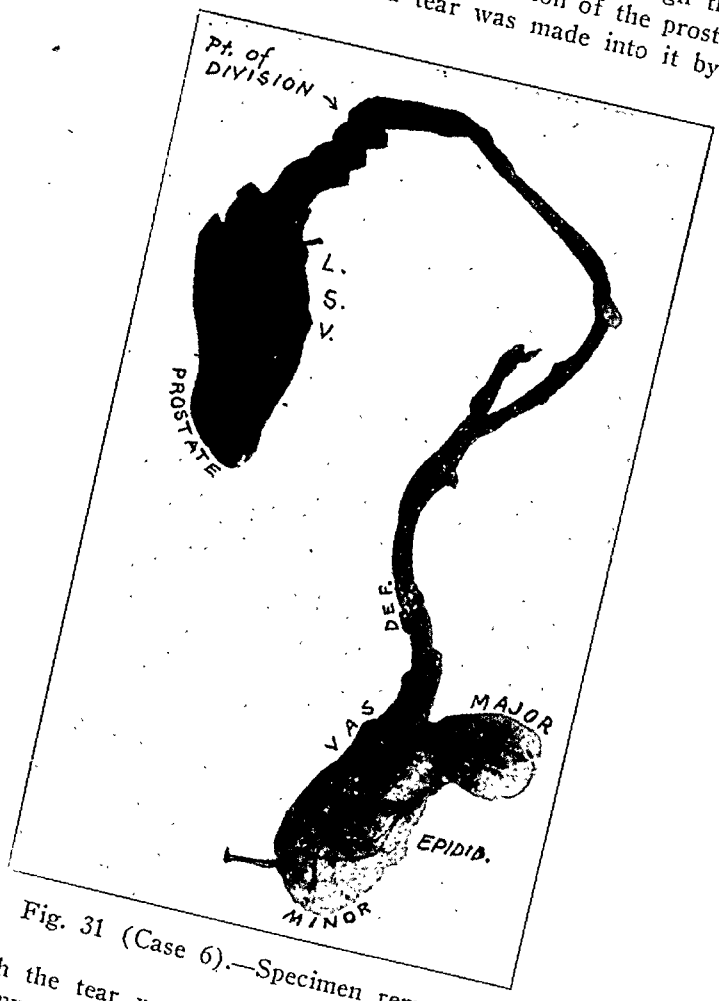

Fig. 31 (Case 6).—Specimen removed.

operator. Although the tear was extensive, it was decided to continue the seminal vesiculectomy, taking great care not to open the urinary tract. The vesicles were easily exposed. An incision was made beginning at the apex of the prostate on the left side and extending back over the left ampulla, after raising the fascia of Dénonvillier. The left vesicle and ampullae and a portion of the left lobe of the prostate were removed in one piece. The right seminal vesicle, ampullae and right lobe of the prostate were not interfered with. Through an incision in the groin, the entire left epididymis and the remainder of vas deferens were removed. The rectal tear was closed with chromicized catgut; packing was supplied for both perineal and rectal wounds.

Comment.—Examination at operation showed that the left testicle was not involved. The left ampulla was markedly tuberculous and about twice the normal size and very closely attached to the vesicle. The left lobe of the prostate was also markedly tuberculous.

Pathologic Report.—The tissues that were removed showed tuberculosis of the left epididymis, the vas deferens, the left seminal vesicle, the left ampulla and the portion of prostate removed.

Course.—May 20: The patient had been operated on forty-seven days previously. He carried a retention catheter in the urethra for ten days and the bowels were tied up with lead and opium pills. Regardless of this, the rectum broke down and the urinary fistula developed and has persisted.

July 18: The rectal fistula had healed; a small amount of urine escaped through the perineum at each voiding. The patient was able to retain urine for normal periods, had no pains and voided freely.

June 13, 1917, the patient entered the hospital on account of the urinary fistula. He was treated by urethral dilatations. No operation was performed, and he was discharged.

Feb. 1, 1921, a letter stated: "It is now five years since operation. Recto-urethral fistula closed. Perineal sinus persists but there is only a very slight discharge—a few drops of pus a day. No urinary leakage. Urination is normal, can hold urine all night. Sexual powers are normal. No pain after intercourse. Have gained 45 pounds in weight. Urine looks normal; have had no pain in either kidney or bladder. General health perfect."

CASE 7 (No. 7933, B. U. I.).—*History.*—A. R., aged 27, single, admitted, July 8, 1919, complained of bladder trouble. There was no history of pneumonia, pleurisy or tonsillitis. He had had gonorrhea twelve years previously, which lasted for three months. The present illness began two years previously, with pain on urination and passage of blood. Six months later he developed an epididymitis on the left side. The epididymis was opened, pus being evacuated. One month later, the right epididymis became involved. During the past six months, urination had become gradually more frequent and painful. At the time of examination, he voided urine about every hour, night and day, and had a marked urgency and dysuria. He had a persistent discharging sinus from the left epididymis. There was no history of renal colic or passage of calculi.

Examination.—The patient looked well. He had no cough or expectoration. The thorax showed slight retraction in the region of both apexes and an impairment on percussion in that region. The lungs were otherwise negative. The heart was negative. The lower pole of both kidneys was easily felt; apparently there was no enlargement or tenderness. The right side of the scrotum was markedly swollen. There was a tense hydrocele obscuring the testicle (Fig. 32). The right epididymis was markedly enlarged, indurated, irregular, particularly in the globus minor; the vas was normal. The left testicle was normal. The epididymis was markedly enlarged and indurated in the globus minor, the globus major being apparently quite normal. The vas was slightly irregular. There was a small discharging sinus leading to the left epididymis. The prostate was markedly broader than normal; the right lobe was irregular, indurated and adherent. The left lobe was markedly indurated and adherent. The seminal vesicles were entirely obscured by a broad plateau of induration which extended across from one side of the pelvis to the other.

The cystoscope entered easily. The bladder capacity was 50 c.c. The bladder was irritable. The prostatic orifice was slightly irregular but otherwise

negative. The trigon was contracted. The mucous membrane was red, with much mucus adherent and floating about, especially around the left ureteral orifice. The vesical mucous membrane was generally red and edematous; no ulceration was seen.

On the right side, the catheter was easily introduced up to the right kidney. On the left side it was impossible to introduce the catheter. A second attempt at catheterization was made, July 15. The right side was easily catheterized and the urine collected. On the left side, the catheter met an obstruction, 1 cm. above the orifice. No urine was collected from the left side. Analyses of urine collected from the right side revealed: color, amber; clear; no bacteria; an occasional leukocyte and red blood cell.

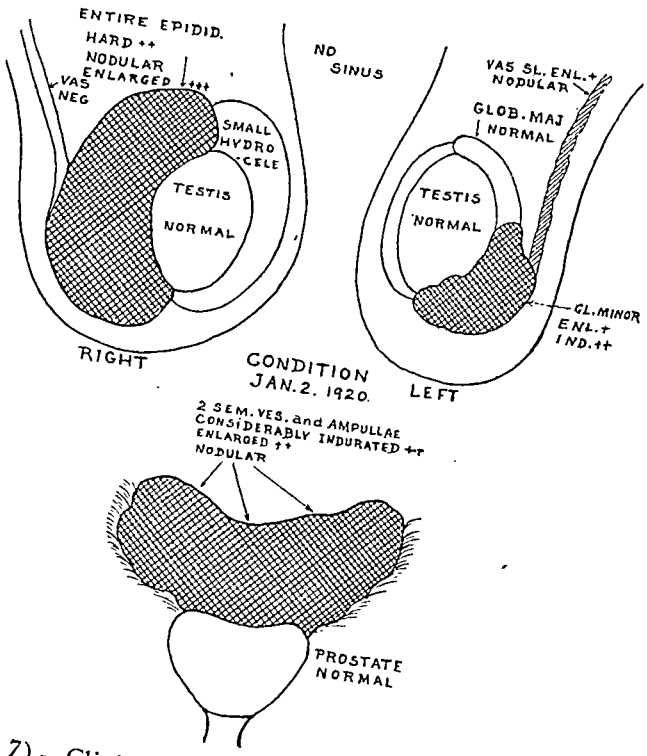

Fig. 32 (Case 7).—Clinical diagram of condition before operation.

August 9, a Garceau catheter was passed into the right ureter. The phenolsulphonephthalein test gave these results: appearance time, four minutes, and 40 per cent. phenolsulphonephthalein excreted in urine collected for one-half hour. During the same time, the transvesical phenolsulphonephthalein output was 5 per cent. Numerous tests for tubercle bacilli were negative; nevertheless, a diagnosis of tuberculosis of the left kidney was made.

Operation (Hain).—August 11, under nitrous-oxid-oxygen ether, a left nephrectomy, extraperitoneal, was performed for tuberculosis. The ureter was brought into the angle of the wound and held there by sutures. The wound was closed with drainage. Convalescence was satisfactory and the patient was discharged, Sept. 6, 1919. His condition was much improved; he retained urine for from two to three hours. The bladder capacity was 95 c.c. There was no dysuria. The scrotal condition was much improved.

Second Admission.—Dec. 30, 1919, the patient stated that during the past two months, frequency and pain on urination had gradually increased so that he voided every fifteen minutes. There was no hematuria or hesitancy, and no pain in the kidney. The patient stated that his sexual powers were good.

Examination.—The patient had lost weight and looked bad. The apexes of both lungs were impaired and a few râles were heard. The right kidney was palpable but not tender. The wound on the left side was well healed. The condition of the genitalia was not markedly changed. The globus minor of the left epididymis was moderately enlarged, very hard and nodular; the vas deferens was slightly enlarged and nodular. The testicle and globus major on the left side were normal. On the right side there was a small hydrocele. The testicle was normal. The epididymis was very much enlarged throughout, very hard and nodular. The vas was negative.

The prostate was slightly indurated and adherent. Both seminal vesicles were much enlarged, very hard, nodular and adherent. Urinalysis revealed cloudy, acid urine, with a specific gravity of 1.022. Microscopically, pus cells and bacilli were found. Culture revealed *B. coli.* The phenolsulphonephthalein test yielded 65 per cent. in two hours.

The impression was one of extensive tuberculosis of the seminal tract. A radical operation was advised.

Operation (Young).—Jan. 7, 1920, under nitrous-oxid-oxygen-ether, both seminal vesicles and ampullae were removed through the perineum. Retrovesical tuberculous involvement was very extensive and the right vas deferens was involved high up and broke away during the dissection. The prostate was not involved. The wound was packed and partially closed. Through an incision in the left groin, the left epididymis and remaining portion of the vas deferens were removed. The testicle was normal and carefully preserved. The entire right epididymis and remainder of vas deferens with the exception of about 2 inches (5 cm.) and a small portion of the right testis were removed through an incision in the right groin. The wound was closed without drainage on both sides.

Pathologic Report (Fig. 33).—There was tuberculosis of the epididymides, vasa deferentia and both seminal vesicles. The portion of the right testicle removed showed marked round-cell infiltration, evidently chronic inflammatory tissue.

Course.—Convalescence was satisfactory at first. One month after operation, the patient was up; the wounds were well healed. There was no urinary fistula; the patient voided about every one and one-half hours.

February 9: The patient complained of discomfort in the bladder. Rectal examination showed a fluctuating area above the prostate, back of the bladder. This was smooth, soft and not tender.

February 18: The rectovesical cold abscess persisted. This was aspirated through the perineum with a large needle and syringe under the direction of a gloved finger introduced into the rectum. Seventy-five cubic centimeters of pus was evacuated. At the same time, a small abscess beneath the skin at the external ring on the left side was opened and drained.

March 9: There was a small perineal discharging sinus at the point the needle was inserted to evacuate the pus. There was no urinary leakage. The urinary symptoms were much improved, the interval now being three hours. Rectal examination showed that the abscess had not recurred. The region of the prostate and seminal vesicles was negative. The right testicle was normal; the scrotal incision was well healed. There was a cicatricial nodule back of the

testicle at the upper and lower ends. On the left side, the testicle was normal; there was a small indurated nodule behind the testis. There was a small discharging sinus at the lower angle of the scrotum. The urine was cloudy and acid, and its specific gravity was 1.012. Microscopically, pus cells and considerable bacilli were found; but no tuberculosis. The patient was advised to live in the open air and take food in abundance.

Feb. 1, 1921, a letter stated that, one year since operation, the disease had not progressed and the testicles had not become involved. The remaining kidney (right) had given him no trouble. There was a small perineal sinus

Fig. 33 (Case 7, No. 7933, B. U. I.).—Specimen removed at operation.

which discharged pus but no urine. Erections and sexual powers were good. He continued to have trouble with the bladder. He voided urine about every half hour, night and day. There was no cough, fever or night sweats. His general health was poor, but much improved.

Comment.—The patient continued to suffer with cystitis and contracture of the bladder, which he had when he came here. His life apparently has been saved by nephrectomy and excision of tuberculous tissue of the entire seminal tract on both sides.

Case 8 (No. 8486, B. U. I.).—*History.*—J. K. O., aged 51, married, admitted Jan. 26, 1920, complaining of swelling of the right testicle and fever, gave no history of pulmonary disturbance nor of venereal disease. Present illness

began in 1911 or 1912, when the patient began to have slight difficulty and frequency of urination and finally had complete retention and for six days was catheterized twice a day. Six months later, retention returned and catheterization was again necessary for a time. He had a distinct hesitancy and slight difficulty of urination with a small stream until about October, 1918, when he was operated on for acute appendicitis. He stated that after the operation the frequency, hesitancy and dribbling disappeared until the present trouble, which began seven months previously. There was no history of pain in the region of either kidney, nor passage of calculi nor hematuria. Seven months previously the patient began to have swelling in the right side of the scrotum and since then had developed a swelling on the left side. In August, 1919, epididymectomy was performed on both sides for supposed double epididymitis, and since then he had had a suppurative sinus on the left side. At the time of examination, the patient complained of swelling in the scrotum and fever. He had no urinary symptoms and his general health was good. Sexual powers were normal.

Examination.—The thorax was well shaped; there were equal movements on respiration; the lungs were normal; the heart negative; the kidneys were not palpable nor tender. Roentgen-ray examination of the chest showed a moderate amount of fibrosis and slight dilatation of the aorta. There was no urethral discharge; the penis was negative. On the right side of the scrotum (Fig. 34) there was a small hydrocele. The testicle was normal; the epididymis was considerably enlarged throughout and markedly indurated. The surface was irregular and adherent to the skin at the site of the scar. There was slight enlargement and induration of the vas up to the external ring. On the left side, there were two suppurative sinuses in the skin which led to the globus major of the epididymis. There was a small hydrocele; the testicle was normal; the epididymis was considerably enlarged, irregular and markedly indurated throughout. The vas was apparently normal. Rectal examination revealed a prostate, moderately enlarged, irregular, moderately indurated throughout. The right seminal vesicle was slightly indurated and adherent, but it was not enlarged nor tender. The left seminal vesicle was considerably indurated and moderately enlarged. The induration extended upward and was continuous with the markedly indurated prostate. The urine was slightly cloudy, acid and gave no reaction, and the specific gravity was 1.008. Microscopically, leukocytes and tubercle bacilli were seen. The prostatic secretion contained red blood cells and diplococci.

Operation (Young).—Jan. 30, under nitrous oxid, oxygen and ether, a radical operation was performed, consisting of removal through the perineum of both lobes of the prostate, both seminal vesicles and both ampullae (Fig. 28). Through the groins, both epididymides and the remainder of the vas deferens were removed. The left seminal vesicle was very much enlarged and markedly tuberculous. The right vesicle was much smaller but also tuberculous. The right testicle was indurated, adjacent to the globus major, and a small portion was removed. The left testicle was also involved near the epididymis and partially excised. The membranous urethra was torn during the operation The perineal and scrotal incisions were partially closed and drained with iodoform gauze.

Pathologic Report.—Both seminal vesicles, ampullae, prostatic tissue and epididymides were tuberculous.

Course.—March 2, 1920, the patient had had a very satisfactory convalescence. Both scrotal wounds were healed completely. Both testicles were slightly indurated and enlarged; there was no fistula nor sinus. The patient voided urine with ease. The perineal wound was healed; there was no perineal fistula. Rectal examination revealed a moderate amount of induration in the region of the prostate and vesicles. The patient was walking about; he had no cough and the fever which was present before operation had ceased. The urine was cloudy in all three glasses. Microscopically, white blood cells and bacilli were noted.

May 22, the patient returned for observation. He said that he had greatly improved in health and strength. Urination was normal; there was no fever, no sweats, no pain. The right testicle was normal in size and consistency,

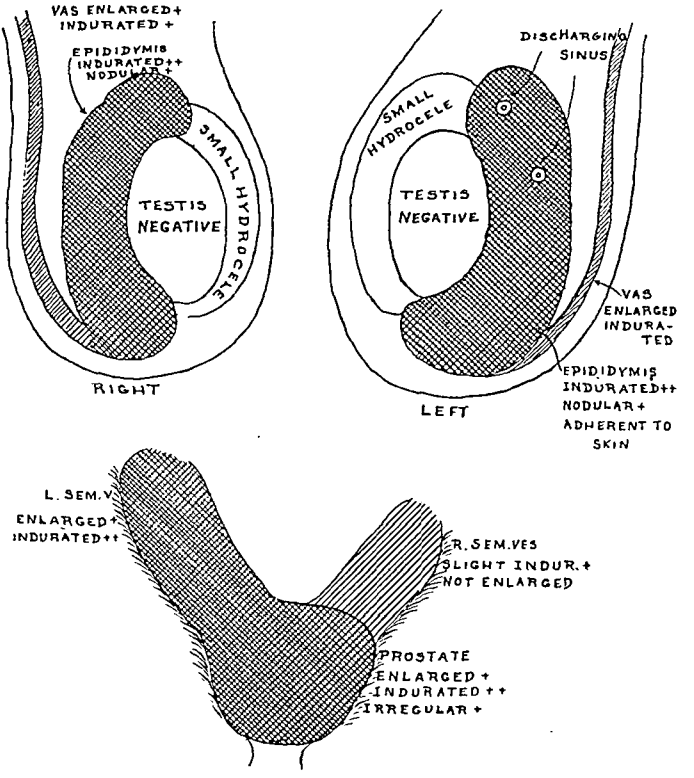

Fig. 34 (Case 8).—Clinical diagram of condition before operation.

except for slight induration of the upper posterior surface. The left testicle was slightly irregular, moderately indurated and adherent to the skin. There was no sinus nor suppuration. Rectal examination revealed only slight induration in the region of the operation on the seminal vesicles and prostate and no evidence of tuberculosis. A small perineal sinus, discharging pus, was still present. There was no urinary leakage. The urine was slightly cloudy. Microscopically, a few cocci but no tubercle bacilli were noted.

September 15: Examination revealed no sinuses or fistulas in the scrotum. Both testicles were negative except for slight induration at the upper ends.

March 10, 1921, the patient came for examination. He said he felt apparently well and entirely cured. All wounds were closed. There was no urinary fistula. His general health was excellent; there was no cough, no fever, and

no sweats. Micturition was normal. He did not have to void during the night. The urine was clear and microscopically negative. No bacteria were present. Sexual powers were normal. He has coitus about once a week. There was less ejaculatory fluid than usual but sensation was normal. Examination revealed slight induration of the posterior part of both testicles. There was no evidence of tuberculosis. There were no sinuses. The perineal wound had healed. There was slight excoriation of the skin from the use of a suspensory. He had gained 25 pounds (11.3 kg.) in weight. Apparently, he was well.

CASE 9 (No. 8525).—*History.*—C. R. H., Jr., aged 19, admitted Feb. 17, 1920. complained of a swollen left testicle. In 1917, the patient had empyema which required an operation—resection of a rib and drainage. Two years later, the right testicle became enlarged and castration was performed (July, 1919). There was no history of chronic cough, hemoptysis or night sweats. There was no history of venereal diseases. He had never had frequency, difficult or painful urination, or hematuria. Sexual history was normal.

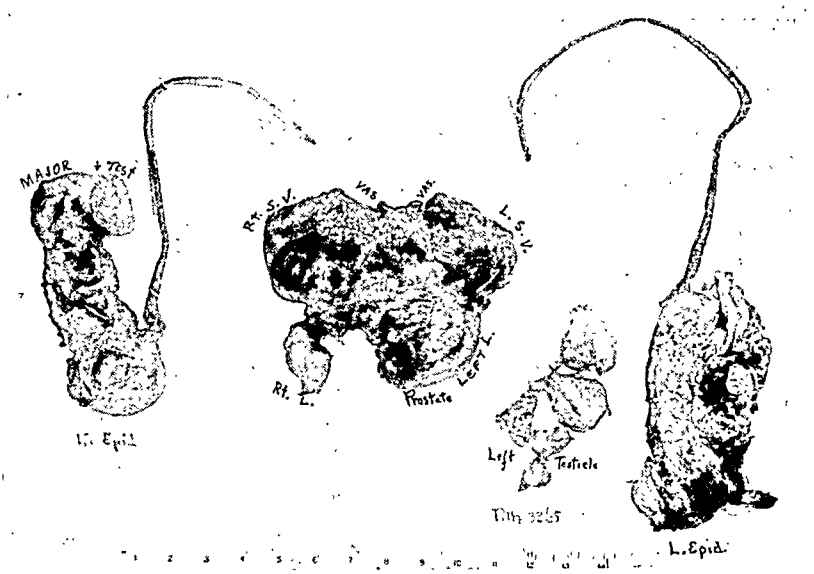

Fig. 35 (Case 8, No. 8,486, B. U. I.).—Specimen removed at operation.

The present illness began four days previously with pain and swelling of the left testicle. There was no history of injury. He still had a discharging sinus in the right scrotum as a result of the castration performed seven months before. The patient was suffering considerable pain in the left testicle, but there was no frequency of urination, no pain, no hematuria, and his general condition was excellent.

Examination.—The patient was well-nourished, height 5 feet and 10 inches (177.8 cm.), weight 155 pounds (70.5 kg.). The lungs were negative on percussion, palpation and auscultation. The heart and abdomen were negative. Neither kidney was palpable. The penis was negative. The right testis was absent (Fig. 36). There was a discharging sinus in the upper part of the scrotum. On the left side, the testis was normal; the globus major and body of the epididymis were negative. The globus minor was enlarged, considerably indurated and tender, and about 2 cm. in diameter. The vas and veins were negative. The urine, voided in three glasses, was cloudy with shreds. Microscopic examination showed pus and tubercle bacilli.

February 18: Cystoscopy revealed no stricture and residual urine. The bladder was negative; the ureteral orifices were normal—both were catheterized. The urine from each kidney was negative. Separate functional tests revealed slight reduction on both sides. Pyelograms were taken. The kidneys and ureters were negative; the outline of the kidneys was normal.

February 25: There had been a rapid increase in size and induration of the left epididymis and a considerable discharge of pus from the sinus in the right groin. Both the vesicles and right lobe of the prostate were considerably indurated and enlarged. Radical excision was advised.

Operation (Young).—March 1, under nitrous oxid, oxygen and ether, a radical operation was performed, consisting of removal through the perineum of both seminal vesicles, both ampullae and both lateral lobes of the prostate (Fig. 37).

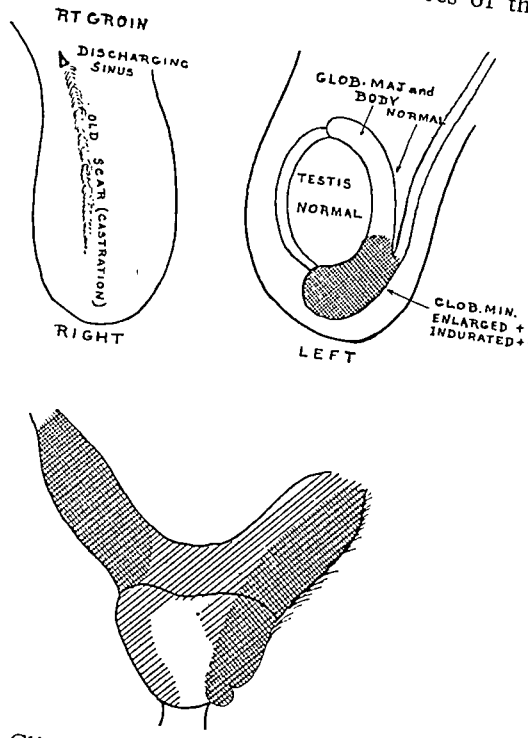

Fig. 36 (Case 9).—Clinical diagram of condition before radical operation but after castration on right side (before admission).

The urinary tract was not opened. All tissues involved in the apparently extensive tuberculous process were removed. The wound was closed with gauze drainage. Through the left groin, the left epididymis and the entire left vas deferens were removed. The wound was closed with drainage. An incision was made in the right groin to investigate the discharging sinus, which had been excised. It was impossible to find the vas deferens, and the portion of the vas deferens intervening between the ampulla and inguinal ring, therefore, remained. The wound in the right groin was packed with gauze. The patient stood the operation well.

Pathologic Report.—There was tuberculosis of both seminal vesicles, both ampullae and the right epididymis. The prostatic tissue removed was apparently tuberculous. The vas deferens was negative.

April 3: It was then three and one-half weeks after operation. The patient had had a satisfactory convalescence. There was no leakage of urine through the perineum. The perineal wound was then closed except for a small sinus. Rectal examination was negative. On the left side of the scrotum was a swollen, inflammatory reaction around the testicle and a small discharging sinus at the site of the wound. There was a discharging sinus in the right groin at the site of the previous castration. The general condition was excellent. The patient was able to retain urine three hours. Urination was normal. The urine was slightly cloudy, with leukocytes and a few bacilli. There was no tuberculosis.

Fig. 37 (Case 9, No. 8526, B. U. I.).—Specimen removed at operation.

April 9: The patient had been treated for four days with bladder irrigations, followed by instillations of 1 per cent. mercurochrome, twice daily. The urine was free from infection. The patient was discharged.

April 16: He returned for observation. There was less swelling of the left testicle. There was a small discharging sinus on the left side of the scrotum. The perineum was closed.

March 12, 1921: A letter stated: "General health good. Excellent result, no urinary fistula. One small sinus in scrotum. Urination normal. No pain. No fever. Erections normal. Urine normal."

CASE 10 (No. 8561, B. U. I.).—*History.*—H. T. Z., aged 43, married, admitted March 8, 1920, complained of frequent and difficult urination. There was no previous urinary history. He denied both gonorrhea and syphilis. The present illness began two years before with increased frequency of urination and pain. Six months later he received an injury on the left side followed by hematuria which soon disappeared. About two months before, he began to have marked pain in the perineum and rectum, and then noticed a swelling in the upper end

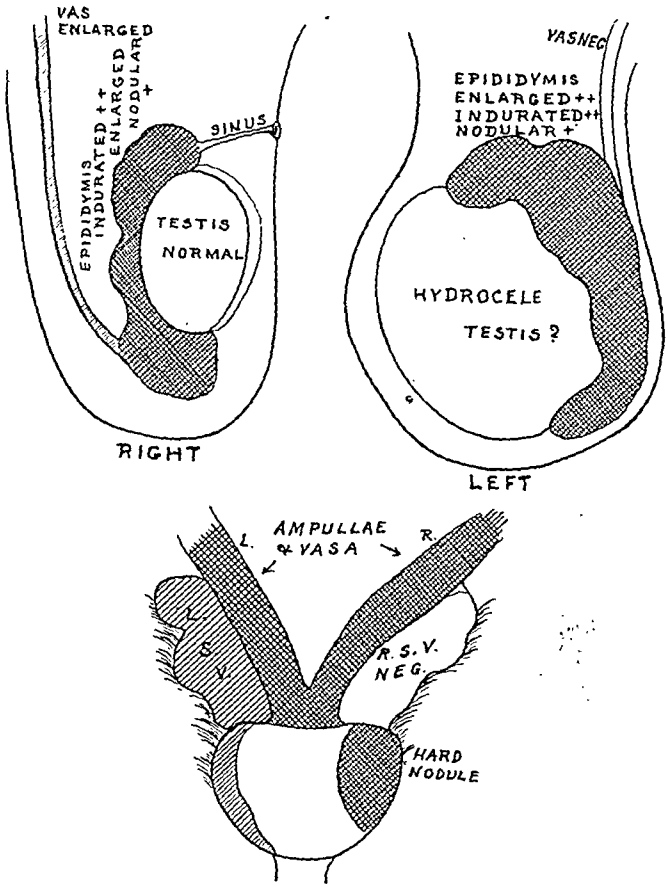

Fig. 38 (Case 10).—Clinical diagram of condition before operation.

of the right epididymis which next involved the lower end. A little later swelling appeared on the left side in the lower end of the left epididymis. After this the upper end of the left epididymis was enlarged. An abscess formed on the right side and was operated on, and has since formed a suppurating sinus. He continued to have frequency of urination and one month ago complete retention. He catheterized himself several times. Since then he has been treated by prostatic massage, irrigations and occasional passage of sounds. At the present time, he voided urine with pain, about every hour. He frequently had attacks of "renal colic" on the left side. Pain so severe that it required morphin radiated toward the groin and bladder and sometimes was felt at

the head of the penis. For the past three months he had suffered with premature and painful ejaculations. He had lost about 4 pounds (1.8 kg.) in weight. He suffered so greatly from pain and frequent urination that he was incapacitated for work.

Examination.—The patient looked healthy. He weighed 150 pounds (68.1 kg.) On percussion and auscultation, the chest was negative except for slightly increased bronchial breathing over the apexes in front and over the lower lobes behind. The heart and abdomen were negative. No tenderness nor enlargement was made out in the region of either kidney. The penis was normal; there was no urethral discharge. The right testicle was normal; the right epididymis was enlarged and nodular throughout its extent. There was a small sup-

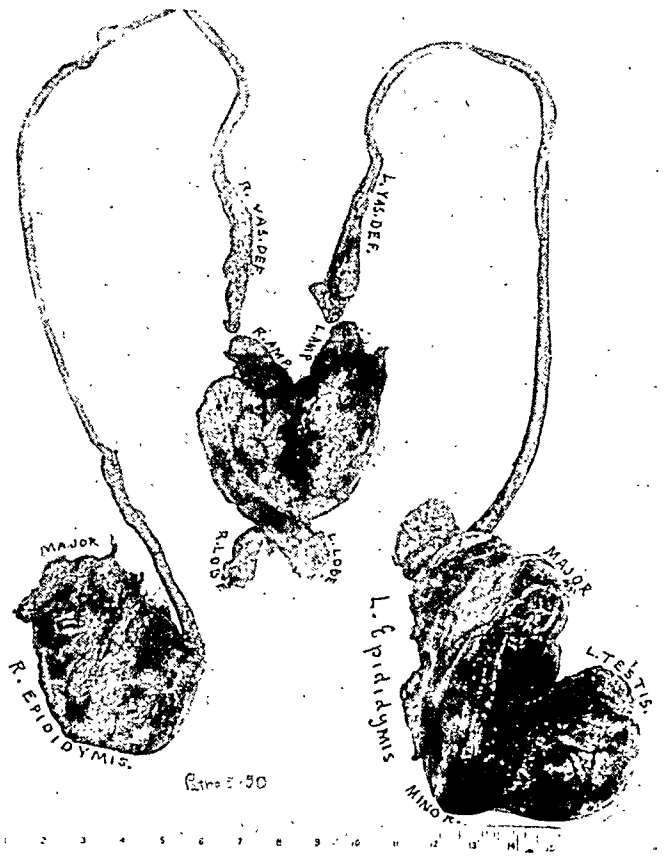

Fig. 39 (Case 10, No. 8561, B. U. I.).—Specimen removed at operation.

purative sinus in the skin, leading to the epididymis. The vas and veins were negative. The left testicle was apparently enlarged considerably but somewhat obscured by an inguinal hernia. The epididymis was enlarged and nodular. The vas and veins were negative. The prostate was negative. Both seminal vesicles were distinctly enlarged, indurated, nodular and adherent. The urine was cloudy and acid. The specific gravity was 1.010. A trace of albumin, a moderate amount of pus, no infection and no bacteria were found. March 10, 1920, cystoscopy revealed no stricture and no residual urine. The bladder capacity was 225 c.c. There was marked diffuse cystitis. The region of the right ureter was edematous and red. External to this was an area

covered with mucopurulent exudate. Around the left ureter and back of it, there was marked reddening and edema, with adherent mucopurulent exudate. Both ureters were catheterized. Urine from the right side was cloudy. A stained specimen showed tubercle bacilli from the right kidney. Urine from the left side was clear. There was no pus, and no bacteria.

March 12, cystoscopy was performed. A study of the prostatic orifice showed a small, rounded median bar. Several areas of definite ulceration were seen along the right and left lateral and posterior walls of the bladder. In other places, small, definite tubercles were seen in the mucosa. Pyelograms and ureterograms showed dilatation of both ureters and of both kidney pelves. Plain kidney and bladder plates were negative. The impression was that of marked tuberculous involvement of the epididymides, seminal vesicles and bladder; slight involvement of the right kidney. It seemed advisable to excise the tuberculous seminal tract.

Operation (Young).—March 21, under gas, oxygen and ether, a radical operation was performed. Through the perineum, both seminal vesicles and ampullae of the vasa and portions of both lateral lobes of the prostate (Fig. 30), all of which were tuberculous, were excised. Through a scrotal incision, the right epididymis was removed, the entire right vas being removed through the wound. The area around the sinus was excised. Castration was performed on the left side. The testicle was markedly involved. The entire left vas was withdrawn through the wound. The wounds were drained and partly closed. The condition was excellent.

Pathologic Report.—Both seminal vesicles, both lobes of prostate, vasa and ampullae were tuberculous. The left testicle and both epididymides were tuberculous.

Course.—March 23, the patient was unable to void. He was catheterized three times a day. A retention catheter was fastened in place that night. March 29, the urine began to drain through the perineum, for the first time. The retention catheter was subsequently removed.

Comment.—It seemed probable that a mistake was made in keeping the retention catheter in for a week. April 9, a small abscess of the left testis was aspirated. April 16, the patient was discharged. There was a sinus in both the perineum and the scrotum. The general condition was much improved, but the patient was weak.

Feb. 4, 1921, a letter stated: "Now almost a year since operation. I have no trouble with my bladder and void four or five times during the day and about four times at night. Urination is not painful and urine appears clear. Have had no trouble with either kidney and the remaining testicle is normal. There is a small sinus in the scrotum on this side. No perineal fistula. Erections and sexual powers are fairly good. Have gained in weight, have no cough and my general health is excellent."

Case 11 (No. 8681, B. U. I.).—*History.*—A. S., aged 23, single, admitted, April 13, 1920, complaining of swelling of the left testicle, gave no history of pulmonary disturbance and no history of venereal or urinary disease. There was no hematuria. Four years before, he had had soreness in the left lumbar region and a second attack six months later. There was no history of calculi. The present illness began about three and one-half months previously, with a small "lump on the left side of testicle," which gradually increased in size and was painful. Three weeks previously, it ruptured and since then a sinus had been present. There was no frequency, difficulty or hesitancy of urination. Sexual powers were normal.

Examination.—The patient was a healthy looking man, weighing 170 pounds (77.2 kg.). The tonsils were enlarged, but there was no general glandular enlargement. The lungs and heart were normal. The kidneys were not palpable nor tender. The penis, right testicle, epididymis and vas were negative (Fig. 40). The left testicle was normal. There was considerable enlargement of the epididymis, with a sinus through the skin. The vas deferens was indurated and enlarged. Rectal examination revealed prostate normal in size and consistency except in the region of the left ejaculatory duct, which was indurated. The left ampulla was indistinctly palpable, being broader than normal and moderately indurated, and could be followed for about 4 cm. above the prostate. The left seminal vesicle was indurated but not enlarged. The right seminal vesicle was soft and apparently normal.

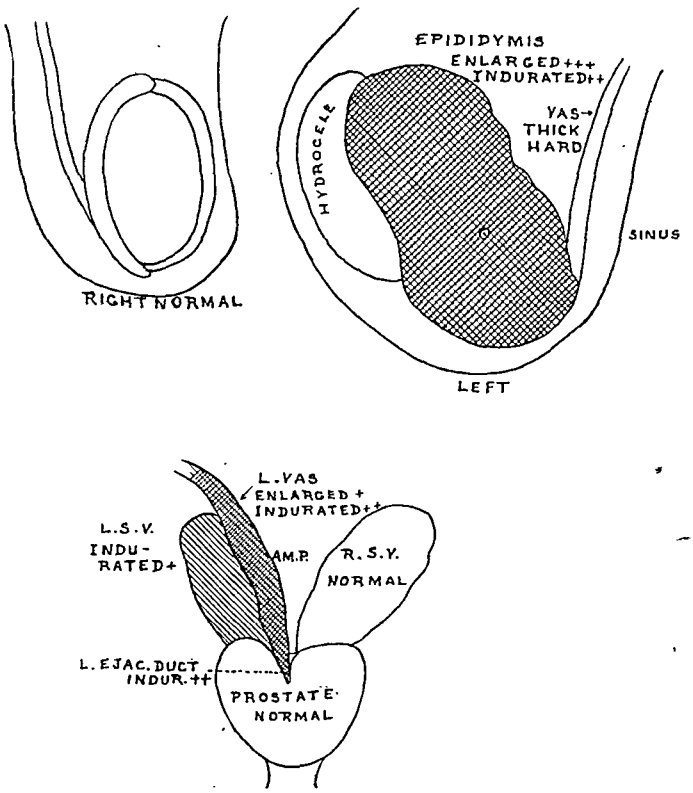

Fig. 40 (Case 11).—Clinical diagram of condition before operation; marked induration of the left vas, ampulla and left ejaculatory duct, distinctly palpable.

Operation (Young).—April 21, under nitrous oxid, oxygen and ether, a radical operation was performed, involving removal through the perineum of the left seminal vesicle and left ampulla (Fig. 41). The prostate and right seminal vesicle and ampulla appeared to be normal. The urinary tract was not disturbed. Through a scrotal incision, the left epididymis was removed, with an area of skin surrounding the discharging fistula. All of the vas was removed by traction. Both wounds were closed with drainage. The patient stood the operation well.

Pathologic Report.—The left seminal vesicle was markedly fibrous and microscopically tuberculous. The entire epididymis was enlarged and tuberculous; the vas deferens contained several tuberculous nodules in various places.

Course.—May 6, 1920: Convalescence had been very satisfactory. It was then fifteen days since operation. The patient was walking. The wound in the scrotum was healed. There had been no urinary fistula and the perineal wound was almost healed. Rectal examination was negative. The general condition was excellent.

Feb. 15, 1921: A letter stated: "Two small discharging sinuses are still present, one in the scrotum, the other in the perineum. Only a few drops of pus escape from each daily. No urinary fistula. Urination normal; no pain in the region of either kidney. No fever, no cough. Have gained in weight. Sexual powers are normal. General health excellent."

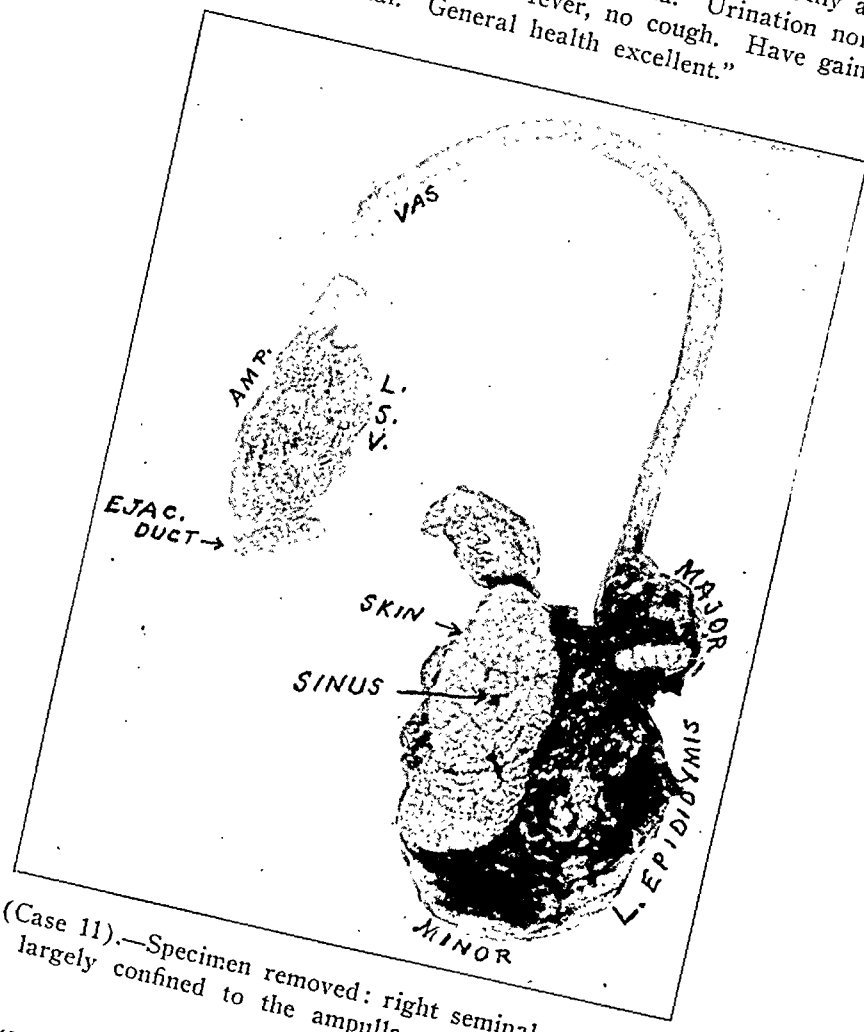

Fig. 41 (Case 11).—Specimen removed: right seminal vesicle not enlarged; tuberculosis largely confined to the ampulla and ejaculatory duct, vas and epididymis.

CASE 12 (No. 8712).—*History.*—T. C., aged 48, married, was admitted April 20, 1920, complaining of swollen testicle.

He had had gonorrhea twenty years previously and was apparently cured. Four years before, he developed pulmonary tuberculosis and was treated at the Maryland State Sanatorium. Sexual powers were normal until three years previously. He had had no sexual desire since. The present illness began six weeks before with burning in the penis before urination. Two weeks later, he noticed a swelling of the left testicle, which came on suddenly but had only

been slightly painful and tender. There had been no increased frequency or difficulty of urination; no history of hematuria or pain in the region of either kidney. The patient had not lost weight.

Physical Examination.—He was a fairly healthy looking man, height 5 feet, 11 inches (180.4 cm.), weight 158 pounds (71.8 kg.). The right side of the chest moved more than the left on respiration, and he had an increased vocal fremitus on the right side over the back. The percussion note was equal on both sides. Auscultation disclosed a few râles over the right apex. There was nothing over the apexes in the back. The heart and abdomen were negative. The left side of the scrotum had a hydrocele obscuring the testicle. The left epididymis was considerably enlarged and indurated throughout its entire extent. On the right side, there was a fairly large hernia; the testicle and epididymis appeared normal. The posterior part of the perineum to the left of the median line and in front of the anus presented an irregular, necrotic, superficial ulcer of the skin, probably tuberculous. The prostate was not enlarged or indurated. The left seminal vesicle was indurated, enlarged and adherent. The right seminal vesicle was apparently negative. The urine was slightly cloudy; the reaction acid; the specific gravity 1.024. There was no pus, and no infection, and no tubercle bacilli were found. Phenolsulphonephthalein test results were: appearance time, ten minutes; 50 per cent. first hour; 5 per cent. second hour; total 55 per cent.

The impression was that of tuberculosis of the left epididymis (possibly testicle), vas deferens and left seminal vesicle. Radical excision of the left seminal tract was advised, but owing to tuberculosis of the lungs, general anesthetic could not be given.

Operation (Young).—April 26, under infiltration anesthesia (procain 1:400), with, occasionally, small amounts of gas. Excision of the left seminal vesicle and ampulla of the vas through the perineum, left castration and removal by traction of the remainder of the vas deferens through the scrotum were accomplished (Fig. 42). Both wounds were packed.

Comment.—A tuberculous area of the skin in the perineum was excised before exposing the prostate through the perineum. Local anesthesia was very satisfactory; only occasionally was it necessary to give a very little nitrous oxid gas. The patient complained only moderately of pain. The left seminal vesicle and vas deferens were manifestly tuberculous and were completely excised. The right vesicle, vas and prostate were not attacked. On account of enlargement of the testicle and apparent involvement, castration was performed.

Pathologic Report.—The left seminal vesicle, vas deferens, epididymis and testicle all contained areas of tuberculosis. This was confirmed by the microscope. The vas was 22 cm. long.

May 10: The patient had a very satisfactory convalescence with no urinary leakage. The wound in the left side of the scrotum and the sutured portion of the perineal wound healed by first intention. There was a small perineal sinus discharging a little pus. The patient said urination was distinctly improved since operation; he was able to retain urine longer and had no pain.

July 19: The patient was readmitted to the hospital, complaining of swelling of the right testicle which began ten days after leaving the hospital and had been associated with much pain. The patient had had no dysuria, urgency, hematuria, hesitancy or incontinence, but voided about every hour. The perineal wound had remained healed, but the wound in the left groin had opened a month previously.

Examination.—The right side of the scrotum had a fairly large hernia, a hydrocele of moderate size, obscuring the testicle. There was considerable enlargement and induration of the entire epididymis. Rectal examination showed that the prostate was of about normal size. There was an indurated mass about 2 cm. above the prostate in the region between the two seminal vesicles. There was slight induration along the lateral walls of the pelvis and the region of the left seminal vesicle which had been excised was negative. The right seminal vesicle apparently was not enlarged or abnormal (Fig. 43).

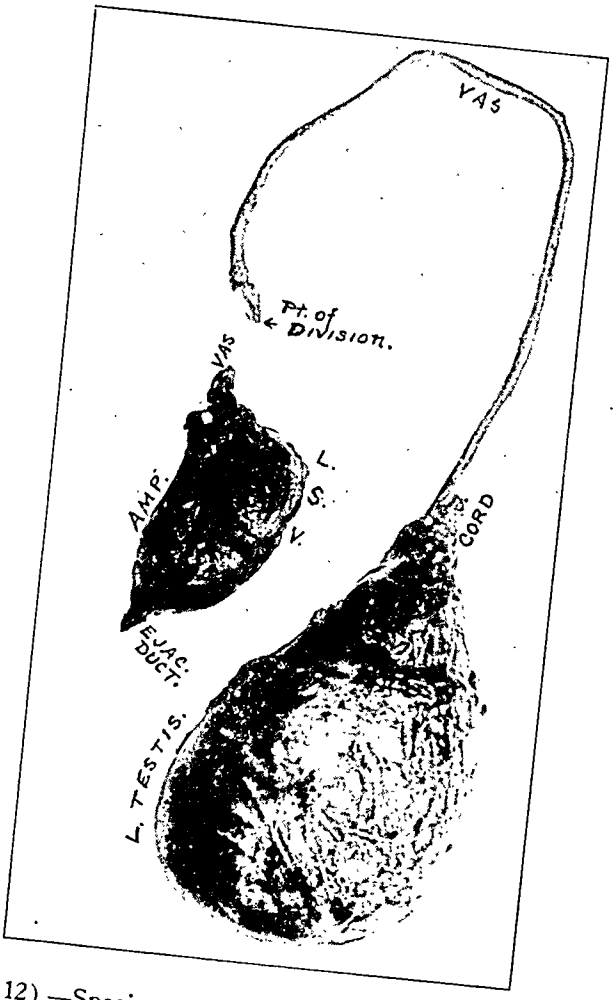

Fig. 42 (Case 12).—Specimen removed under local anesthesia. Left castration, with hydrocele, left vas, ampulla, seminal vesicle and ejaculatory duct.

Second Operation (Young).—July 21, under infiltration anesthesia (procain 1:400), castration, on the right side, was performed. Epididymectomy was not attempted on account of the evident involvement of the testicle. No effort was made to remove the entire vas or the right seminal vesicle, which was apparently negative. The scrotal wound was packed with gauze.

Pathologic Report.—Extensive tuberculosis of the epididymis, with numerous small tubercles throughout the testis, was found.

Course.—Convalescence was satisfactory, the patient being discharged fifteen days after operation with a small sinus in the scrotum on each side; the perineal wound was closed. The general condition was excellent.

September 28, the patient complained of frequency of urination. The cystoscope revealed general cystitis, no ulceration. The ureters were catheterized. Kidney urine was free from infection and both kidneys were of equal function. Bladder urine contained pus cells and numerous cocci. The patient was put on irrigations.

Jan. 21, 1921, the urine showed numerous pus cells and bacilli.

February 11, a letter stated: "Operation one year ago. I am improved but have two discharging sinuses, one on the left side of the scrotum and one in the perineum, which discharge freely. Urination is still frequent, about ten times during day and five times at night, but have no pain in bladder or on urination. Sometimes when on my feet have pain radiating to right kidney from bladder but have had no chills, fever nor sweats. Sexual powers had disappeared three years before operation, no erections. My general health is excellent."

Comment.—Here, as in Cases 2 and 3, both vesicles and ampullae should have been removed at first operation.

Case 13 (No. 8707).—*History.*—B. N. G., aged 25, married, admitted, April 20, 1920, complained of prostatic trouble. The past history was negative. He denied venereal disease. Sexual powers were normal. About three years previously, he began to have frequency of urination at intervals of about two hours, night and day. About the same time, he had a slight difficulty of urination and pain but he had never had retention or hematuria. Two weeks previously, he began to have swelling in the scrotum but with very little pain. Shortly afterward, a discharging sinus formed (the patient did not complain particularly of either testicle). Urination had continued to become more frequent and difficult. He voided now about every hour, night and day, and there was considerable pain, hesitancy and dribbling. He had not lost weight and there was no history of pain in the chest, or coughing. There was no pain in the region of either kidney.

Physical Examination.—The patient was a well-developed man and appeared to be healthy. The lungs were negative with the exception of a few coarse râles. The heart was negative. The kidneys were not palpable or tender. The penis was normal; there was no urethral discharge. Examination of the scrotum, right side, revealed: testicle, normal in size and consistency; epididymis, considerably enlarged, irregular in the globus minor and body; globus major, apparently normal (Fig. 44). Connected with the lower end of the epididymis was a sinus which discharged pus. The right vas deferens was enlarged, irregular and nodular. On the left side, the testicle was normal; the epididymis was enlarged, irregular and markedly indurated in its entire extent; there were no areas of fluctuation and no sinus. The vas deferens was apparently normal (Fig. 44).

Rectal examination showed the prostate slightly enlarged. The right lobe was prominent, slightly nodular, markedly indurated but not tender. The left lobe was also slightly irregular, moderately indurated, but not enlarged. At the upper end of the prostate on the left side, an indurated cord was felt; it extended upward and outward as far as the finger could reach. On the inner side, another cord was felt, less prominent and less indurated. The outer part of the left vesicle was very slightly indurated and adherent. On the right side, there was an irregular mass of induration, apparently involving the inner

portion of the right vesicle or vas. The outer portion of the right vesicle was apparently not enlarged or indurated (Fig. 44). A few adhesions were present along the outer side of the prostate and vesicles. The rectum was negative. There were no enlarged glands.

The impression was that of tuberculosis of the epididymis, vasa deferentia and both lobes of the prostate. Involvement of the seminal vesicles was questionable. The indication was for radical excision of the seminal tract, including partial prostatectomy.

The urine was slightly cloudy, with acid reaction and a specific gravity of 1.004. A trace of albumin, no sugar or casts, and a slight amount of pus

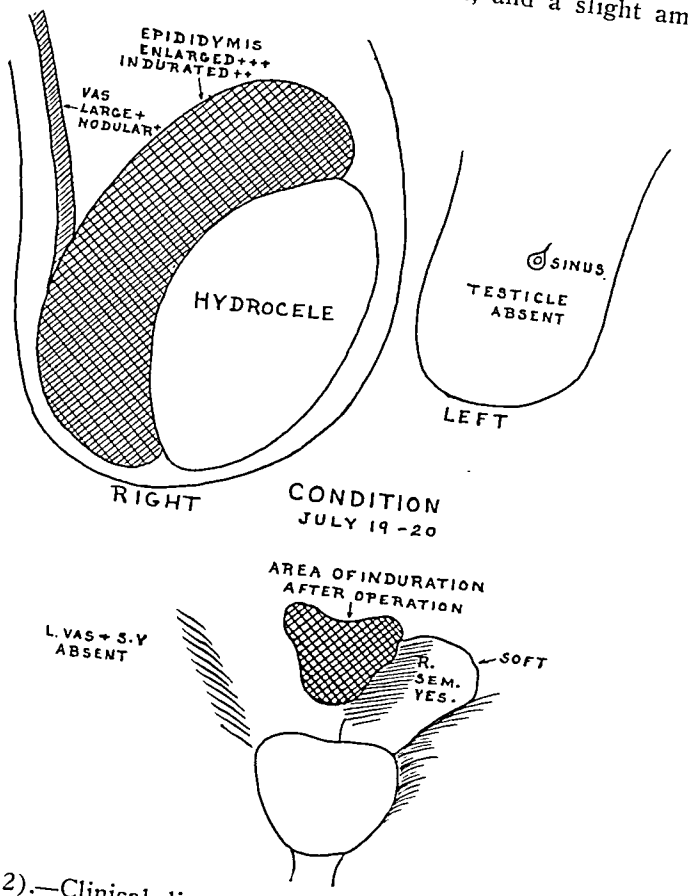

Fig. 43 (Case 12).—Clinical diagram made four months after radical operation, when patient returned with tuberculosis of right epididymis.

were found. Culture revealed colon bacilli in moderate amounts. April 26, the cystoscope entered easily; bladder capacity was 100 c.c. The bladder was irritable; the mucous membrane was diffusely red but not ulcerated. The ureteral orifices appeared normal. In the right ureter, the catheter passed easily up to the kidney. In the left ureter, it was impossible to introduce the catheter more than a short distance; apparently a stricture was present. There was no reaction around the orifice to suggest tuberculosis of the left kidney. Urine from right kidney contained short thick bacilli; no tuberculosis was found. The phenolsulphonephthalein test gave these results: 25 per cent., from

the right kidney in one hour; collection from the bladder for the same period was 3 per cent. Pyelogram of the right side was taken; apparently it was normal.

The impression was pyelitis, right side, slight; probable tuberculosis of the left kidney.

April 29: Additional studies of the bladder urine had demonstrated tubercle bacilli. A second attempt at ureteral catheterization on the right side was successful as before. On the left side, a No. 5 catheter entered for 0.5 cm. Urine flowed through this by drops continuously, clear, pale and microscopically negative. Thorium was introduced into the left ureter and a pyelogram was taken. It showed urethral dilatation beginning at the juxtavesical por-

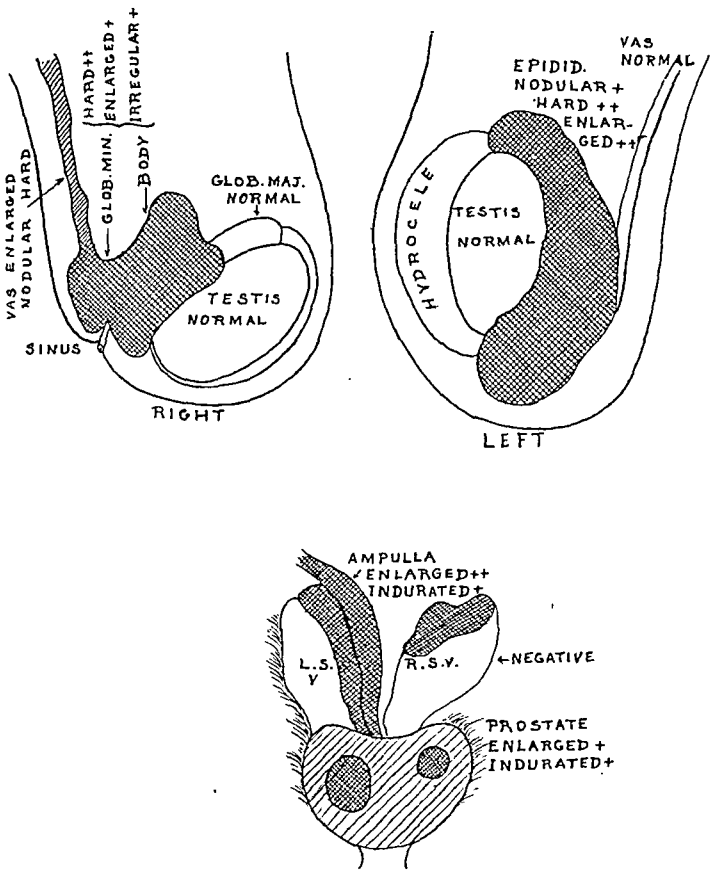

Fig. 44 (Case 13).—Clinical diagram showing interesting isolated areas of marked induration.

tion of the ureter, 1 cm. in diameter in the upper portion. The kidney was apparently normal in size; the pelvis was not well filled. Diagnosis was indefinite. A Garceau catheter was introduced into the right ureter and function was secured. The appearance time was six minutes; the output from the right kidney in a half hour was 28 per cent. At the expiration of the test, the bladder was catheterized and washed out. A transvesical phenolsulphonephthalein (left ureter) gave 18 per cent.

The impression was right pyelitis. There was a stricture of the end of the left ureter, with dilatation above. The left kidney was impaired. Tuberculosis was not proved but suspected.

Operation (Young).—April 30, under nitrous-oxid-oxygen ether, radical excision of seminal tract for tuberculosis was accomplished (Fig. 31): (1) perineal operation consisting of excision of both seminal vesicles, both ampullae and a portion of each lobe of the prostate; the ejaculatory ducts, urethra and bladder were not injured; (2) excision of right epididymis with tissue surrounding the sinus of skin of scrotum and removal of entire vas deferens by traction through scrotum; (3) removal of entire left epididymis and almost all of the left vas deferens.

Comment.—The operation was carried out without difficulty. The deeper portion of the left vas deferens back of the bladder was not removed (the vas broke at that point when traction was made). The perineal and scrotal wounds were closed partially, and small gauze packs were inserted.

Pathologic Report.—The left epididymis was markedly tuberculous. The left vas was negative. Both seminal vesicles were hard and nodular. The right vas was indurated, nodular and tuberculous. The right epididymis showed extensive tuberculosis involving the portion of the testicle which was removed.

Course.—Convalescence was uneventful. Packs were removed on the third and fourth days, and the patient was discharged on the seventeenth day. There was a small perineal sinus discharging pus, and no urinary leakage. The patient had gained in strength; urination had improved greatly; the interval was now four hours. The urine contained pus and bacilli. The general condition was excellent.

June 22: The urine was still cloudy and contained pus and bacilli. It was impossible to catheterize the left ureter. Phenolsulphonephthalein from the right side was 28 per cent., transvesical 5 per cent. in one-half hour. July 7, cystoscopy with successful catheterization of both ureters with No. 7 catheters was accomplished. Urine from the left side was cloudy and contained tubercle bacilli; urine from the right side was slightly cloudy and contained no bacteria. Phenolsulphonephthalein output was equal.

The impression was tuberculosis of the left kidney and ureter. There was a small suppurative sinus on the right side of the scrotum; the testes were normal. The epididymides and vasa deferentia were absent. Rectal examination revealed: prostate, slightly irregular, indurated and adherent, much smaller than before operation; very slight induration in the region of the seminal vesicles, which were absent; no abscess; small perineal sinus.

July 11: The patient was readmitted to the hospital for nephrectomy. The thorax and abdomen were negative. The left kidney was not palpable or tender.

Operation (Frontz).—July 12, under gas and ether, left nephrectomy was performed for tuberculosis. A curved muscle-cutting incision was made in left loin. The ureter was brought up, injected with pure phenol, divided and ligated with chromicized catgut. The kidney which was about the usual size and shape was not opened. The pedicle was ligated with chromicized catgut and the kidney was removed without difficulty. The wound was closed; two gauze packs were inserted. Chromicized catgut was used for muscle and continuous black silk for the skin. Cigaret drains were inserted at the upper angle of the wound. The condition was excellent.

Pathologic Report.—Tuberculosis involving the lower portion of the pelvis and the middle portion of the cortex and medulla was reported. Considerable normal tissue was present.

Course.—Convalescence was uneventful. The patient was discharged, August 11, one month after operation. The wound had healed except for a

small sinus at the upper angle, discharging pus. There was a small perineal sinus, with no urinary or rectal connection. The general condition was much improved.

Jan. 20, 1921: The patient stated that recently urination had become more frequent. A small sinus still persisted at the site of the kidney operation. Urine was cloudy and contained pus cells and bacilli; but no tubercle bacilli were found. The general health was excellent. He had had no fever. Cystoscopy revealed an irritable bladder; residual urine, 75 c.c. The prostatic orifice was normal. The left ureteral orifice was seen as a small depressed

Fig. 45 (Case 13, No. 8707, B. U. I.).—Specimen removed at operation.

area. There was no ulceration. The right ureteral orifice was normal. A catheter was introduced into the right kidney easily. Urine from the right side showed pus and colon bacilli but no tuberculosis. The phenolsulphonephthalein output, intramuscular, first half hour, was 40 per cent.; second half hour, 20 per cent. The patient was to have irrigations and instillations.

February 19: The patient had been under treatment by hydraulic distention and instillation of mercurochrome. His symptoms had improved greatly. The bladder capacity was 125 c.c. There was no recurrence of genital tuberculosis. The patient was discharged.

CASE 14 (No. 8729).—*History.*—B. A. R., aged 30, married, admitted, April 24, 1920, complained of swelling of the right testicle and pains in the back, hips, legs and buttocks. He had had gonorrhea two and a half years previously, which lasted four months, with no complications. Two years previously, while riding a horse, he lost his footing and badly bruised his right testicle against the saddle. For several days after this, the patient had considerable pain in the testicle and pain in the glands of the groin for two months. Later, he was kicked in the back by a horse. Since then, he had had rheumatism and arthritis, involving the left thigh and leg.

On admission, the patient complained of rheumatism which extended down the back of the left leg, along the outside, to the foot and toes. He had practically no pain in the testicle, epididymis or groin. Urination was free and painless. Intervals were slightly increased, from one to two at night, from six to seven times during the day. Sexual powers were normal. He had intercourse about five times a week. Ejaculations were normal; there was no blood. He had lost 14 pounds (6.3 kg.) in weight during the past two months. He had had no cough and examination of the chest was negative. Roentgenograms of the spine had been negative. The Wassermann reaction was negative. On account of the pain, above described, he had taken codein, ½ grain (0.03 gm.), daily for ten months. He was unable to walk.

Examination.—The lungs showed a few fine râles at the left apex, posteriorly, and slight dulness; diminished breath sounds and harsh breathing in both interscapular regions. It gave one the impression of fibrosis. The heart, abdomen and kidneys were negative (Fig. 46). The penis was negative. The left testicle, epididymis, cord and groin were negative. The right testicle was normal in size but rotated. The epididymis was considerably enlarged, very hard, irregular and nodular throughout its entire extent. There was no fluctuation and no sinuses. The right vas deferens was hard, nodular and enlarged. The prostate was broader than normal; the median furrow and notch were wide and deep; the right lobe was prominent, globular, slightly irregular and moderately indurated, particularly at the upper end and externally. Running upward and outward from the prostate were adhesions. The left lobe of the prostate was similar to the right, with adhesions running upward and outward. The right seminal vesicle was soft, indistinct, apparently not enlarged or indurated. The left seminal vesicle was also apparently not enlarged or indurated. Neither vas deferens was palpable. The urine was clear, acid in reaction; the specific gravity was 1.018; there was no albumin, no sugar, no casts. Microscopically, it showed pus in small amount; no bacteria were seen; tuberculosis was sought for. The phenolsulphonephthalein test gave these results: appearance time, ten minutes; 60 per cent. for the first hour and 20 per cent. for the second; total 80 per cent. Roentgenograms of the chest, kidneys, bladder and hips were taken. Outlines of the kidneys were plainly seen, apparently negative. The vertebrae were negative. The chest showed fibrosis of both upper lobes. The hips were negative.

The impression was tuberculosis of the right epididymis and prostate, probably of the seminal vesicles and vasa deferentia. Radical operation was advised.

Operation (Young).—May 7, under gas and ether, a radical operation (Fig. 47) was performed consisting of :(1) perineal excision of both lobes of the prostate, right seminal vesicle, ampulla of right vas deferens; the urethra and bladder were not opened; (2) epididymectomy, right side, complete removal of the vas deferens by traction, through scrotal wound. The testicle was normal. A small area was removed; the rest was left intact. Both wounds were

drained. Both lobes of the prostate were found to be very hard and considerably enlarged. The right vas and right seminal vesicle were hard and irregular, and yellowish material was seen shining through the fibrous cavity. The vas was divided about 7 cm. above the prostate. The prostate and seminal vesicles were evidently tuberculous.

Pathologic Report.—Extensive tuberculosis of the right vesicle, right vas, both lobes of prostate and right epididymis was reported.

May 22: Two weeks after operation, there were no complications; no urethral leakage. The testicular wound was healed by first intention. The perineal wound was healing by granulations. The patient was much improved in health and was now able to walk; whereas before operation he was unable to do so. He was discharged. The general condition was excellent.

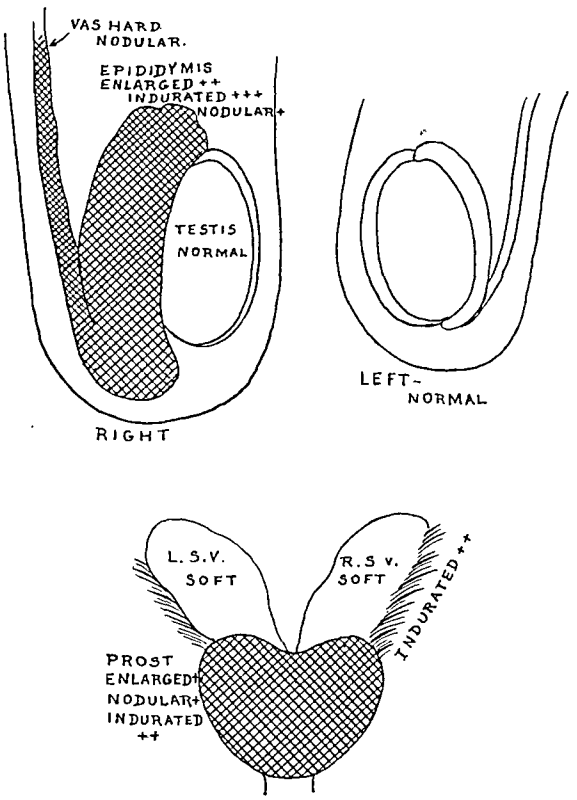

Fig. 46 (Case 14).—Clinical diagram; induration apparently confined to prostate. At operation the right vesicle was found to be tuberculous.

June 22: The patient reported that he was operated on two weeks previously for acute mastoiditis, considerable pus having been evacuated. He still suffered from rheumatism. The result of the genital operation was excellent.

March 5, 1921: A letter stated: "My condition is improved and I do not suffer so severely. My back is rigid and I can use my left leg but little without the aid of crutches. (Before operation could not walk at all.) I have three places discharging pus, viz., from my ear, from the cartilage where the ribs join on my breast and from my left foot; the breast was lanced about eight months ago and the foot about two months ago."

Case 15 (No. 5430, B. U. I.).—*History.*—N. D., aged 33, widower, admitted Dec. 2, 1920, complained of swollen, painful left testicle and pain in the groin,

and painful defecation. In 1911, at the age of 24, he had had gonorrhea, complicated by left epididymitis from which he apparently recovered. Several months later, he suddenly had swelling and pain in the right testicle. After that he suffered, off and on, with pain in both testicles. Four years previously (age 29) he began to have pain in the bladder and frequent and painful urination. He was admitted to this hospital, Oct. 7, 1916, complaining of pain in the right hypochondrium. Cystoscopy and ureteral catheterization were performed and pyelograms were made; all were negative. Careful search for tuberculosis was made but none was found. The diagnosis was pyelitis. He was discharged,

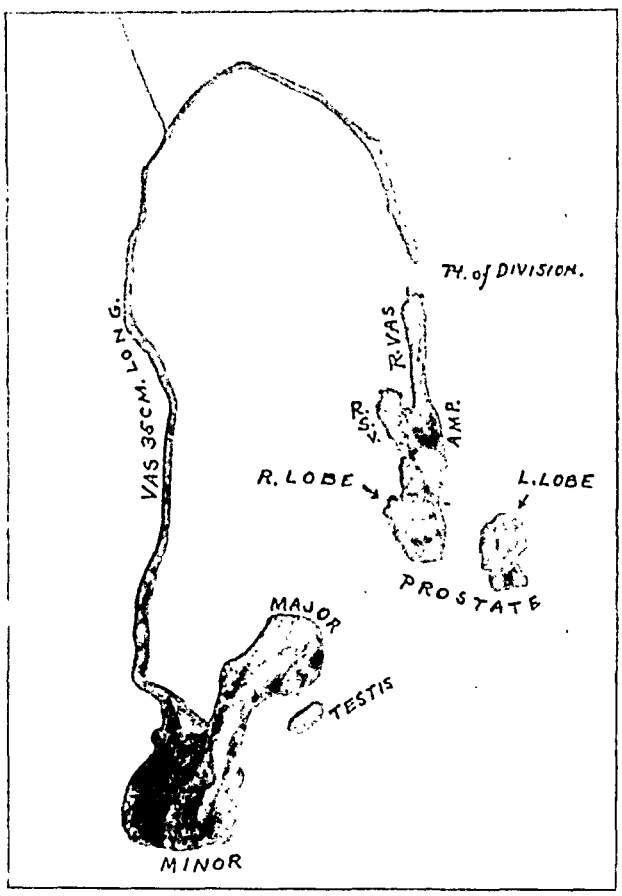

Fig. 47 (Case 14).—Specimen removed at operation.

October 26. He was readmitted, December 8, again complaining of pain in the right side. Tubercle bacilli were found in the urine from the right kidney.

Operation.—Right nephrectomy was performed, Jan. 8, 1917. Convalescence was uneventful. Pathologic examination revealed tuberculosis of the right kidney. He was discharged, February 8.

In May, after an injury to the right testicle, an abscess had formed which was opened by operation. The patient was admitted again, July 7, complaining of frequent and painful urination. Examination revealed right tuberculous epididymitis with fistula. Right epididymectomy was performed. Microscopic diagnosis was tuberculosis. He was discharged much improved, August 3.

August, 1920, he developed swelling and pain in the left testicle and epididymis, which had persisted up to the present time.

Examination (October 20).—The patient was thin. The breath sounds were harsh all over the chest, especially both apexes. No râles were elicited. The heart was negative. There was a scar on the right side of the abdomen from a previous nephrectomy. The left kidney was apparently negative (Fig. 48). The penis was negative. The right epididymis was absent. The right testicle was apparently normal. There was no sinus. The left testicle was normal; there was slight hydrocele. The left epididymis was greatly enlarged throughout and very hard with no areas of fluctuation and no sinus. The vas was nodular and indurated. The prostate was indurated on each side, soft in the middle, not enlarged. Induration also ran across the upper edge of the prostate and continued upward, involving both seminal vesicles and tissues between them. The induration was considerable and obscured the seminal vesicles and vasa deferentia, extending at least 4 cm. above the prostate. Urine was slightly cloudy, acid; specific gravity, 1.004; pus cells few. Microscopically, bacilli but no tubercles were found. Phenolsulphonephthalein test: appearance time, fifteen minutes; first hour, 45 per cent., second hour, 10 per cent.

Operation (Frontz).—October 25, under gas, oxygen and ether, a radical operation was performed (Fig. 49). Through the perineum, both seminal vesicles and ampullae and a portion of each lateral lobe of the prostate were removed, without injury to the bladder, urethra or rectum. Through the scrotal incision, the left epididymis was removed and the vas deferens was removed completely by traction through the wound. The testicle was not removed. The mediastinum testis was involved. Both wounds were closed with drainage.

Pathologic Report.—The epididymis, both seminal vesicles, the ampullae and portions of the prostate were removed. They showed extensive tuberculosis.

Course.—October 29, sudden fever (103 F.) and pain in left side developed. Diagnosis was pyelitis. Under forced "fluids," the temperature finally became normal and on discharge, December 2, the patient was in excellent condition The wound had healed. He voided urine at intervals of every two hours without pain. His general health was much improved.

Feb. 16, 1921: A letter from his physician said: "Patient voids twice at night and three times during day. Urine clear microscopically. The left side of scrotum contains a hard nodule at the seat of the operation. He now complains of some stomach trouble, but on the whole for a man who has tuberculosis of the urinary tract, he is in very good condition."

VI. ANALYSIS OF THE FIFTEEN RADICAL OPERATIONS ABOVE DESCRIBED

The fifteen radical operations described above have been studied by analytic tables, and in order that the reader may get a better comprehension of the operative results and the pathology, these tables are reproduced herewith.

The previous histories and the accompanying tables have given such a complete idea of the cases in which this radical operation has been carried out that hardly any additional comment seems necessary.

A Discussion of Pathology and Technic.—The tissues removed at operation were: right seminal vesicle 10 (alone 2); left seminal vesicle

13 (alone 5), bilateral 8, unilateral 7. Of these 7 cases of unilateral excision of the seminal vesicles and ampullae, 3 subsequently developed tuberculosis of the remaining epididymis, the other epididymis having been excised with its corresponding ampulla and vesicle at operation. This would seem to be an argument for routine double vesiculectomy.

In all cases, the seminal vesicles removed were thought to be involved, but not proved in one case.

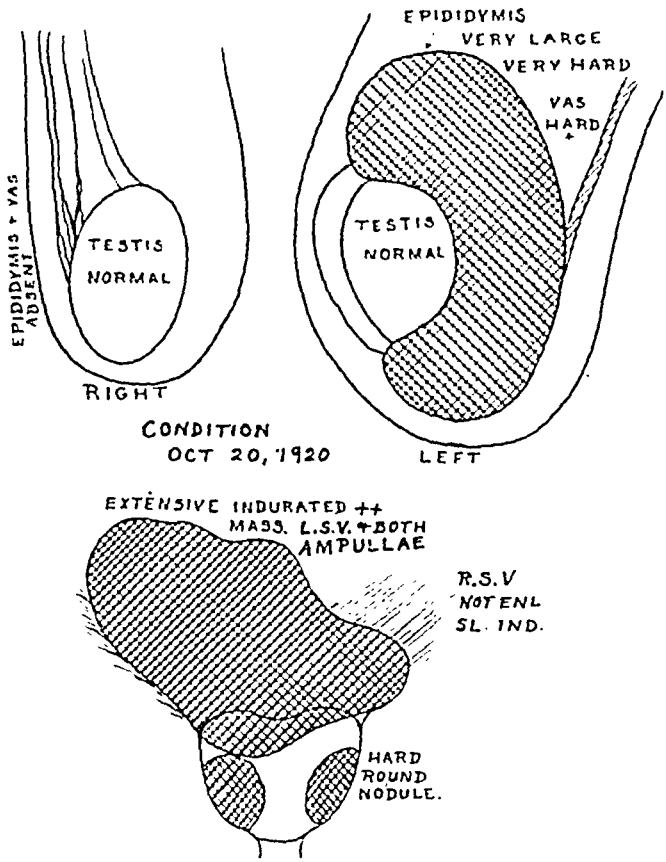

Fig. 48 (Case 15).—Clinical diagram after right epididymectomy, and before radical operation.

The ampullae removed were: right 10; left 13; both 8. (Same as with vesicles, above).

The vasa deferentia were removed as completely as possible with the epididymis and in all but about three cases the vas came away completely, often showing the teeth of the clamp on the lower end. In one case in which the vas did not come away completely, there was an extensive retrovesical tuberculosis which involved the vasa deferentia (Case 7).

Other similar, but less extensive, cases have been seen. Before clamping and dividing the vas, it is well to free it as high up as possible back of the bladder, remembering to avoid the ureter and peritoneum.

Both lateral lobes of the prostate have been removed in ten cases and the left lobe alone in three of the other five cases. In two cases the excised prostatic tissue was found to be not tuberculous on either side. The urethra was not opened in any case by the excision of the lateral lobes, and the fact that only one of the patients has a urinary

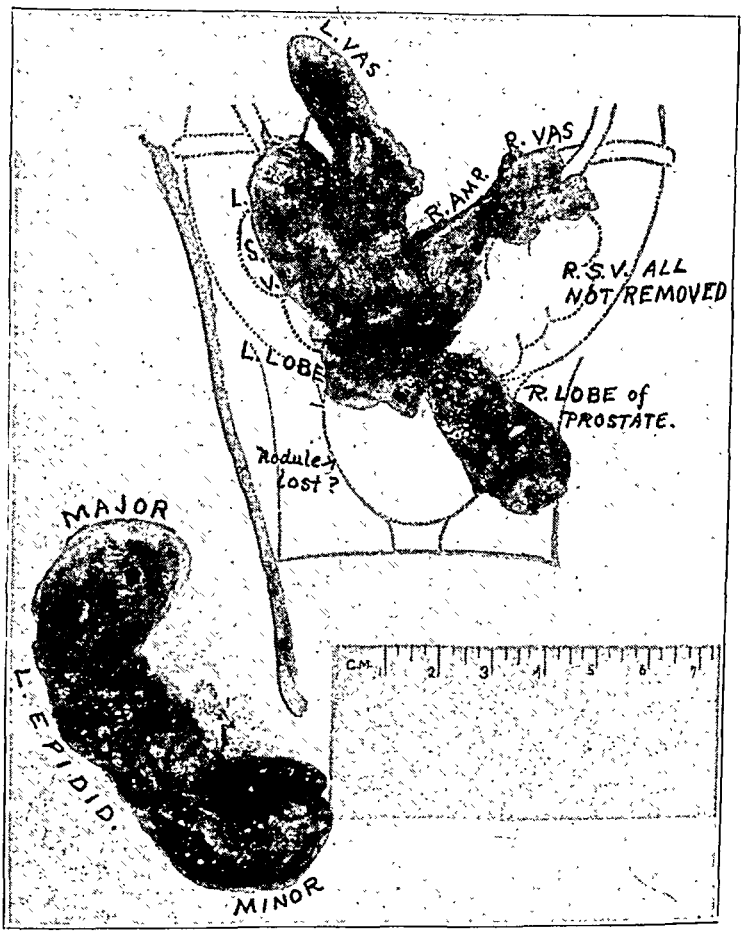

Fig. 49 (Case 15).—Specimen removed at operation.

fistula shows that it is a safe procedure. The severe tuberculous involvements which have been encountered in many cases show the advisability of prostatic resection.

The deeper portion of the vas deferens—the ampulla—was apparently involved in all specimens except one. On the right side ten ampullae were removed, eight positively tuberculous, and two probably tuberculous (sections not proved microscopically). On the left side, thirteen were removed, ten positive, two probable, only one positively

not tuberculous. In many instances, the tuberculous ampulla formed a larger mass than the adjacent vesicle.

The remainder of the vas deferens which was extracted by traction through the groin contained no definite areas or nodules of tuberculosis in six out of twenty-two vasa removed. The upper and lower ends were the portions most frequently involved, and in several cases were associated with exclusive perivasal tuberculosis of the retrovesical tissues. Our findings surely prove that forcible evulsion of the vas from the groin, without removal of the ampulla and vesicle through the perineum, is a very dangerous procedure and bad practice. As a rule, no difficulty is experienced in extracting the entire vas deferens from a wound in the upper part of the scrotum, by to-and-fro traction, with the assistance of a clamp in the perineal wound, as described in the technic of operation. It is useless and harmful to open up the inguinal canal, and especially to follow the vas into the pelvis as in the Villeneuve technic or the modification practiced by Whiteside, who has admitted, in his more recent papers the bad results obtained by Villeneuve's inguinal method.

The epididymides were removed twenty-four times, thirteen left and eleven right. All were definitely tuberculous, but in two cases on the left side the globus minor alone was involved. In the other twenty-two epididymides, the entire epididymis was tuberculous. No case of isolated globus major tuberculosis was found—an interesting fact as regards etiology.

Eight complete castrations were performed (three left, five right; only in one case were both testicles removed). In four instances, excision of the upper posterior part of the testicle next to the epididymis was carried out, and tissues excised were found to be tuberculous. None of these cases have required complete castration, although all have gone more than a year. Of the eight testes removed, all but two showed only a limited area of involvement in that portion of the testis near the globus major of the epididymis. Only one presented extensive caseation of the entire testicle. In only one case was double castration carried out; and in this case, lung tuberculosis was present and operation was performed quickly under procain (Case 12).

These cases, therefore, show that involvement of the testis is comparatively rare and that in most cases a partial excision is sufficient to remove the entire tuberculous area. This should always be attempted in bilateral involvement of the testis. In our one such case, the bad condition of the patient and our desire to avoid a long operation (epididymectomy) under local anesthesia caused us to perform a double castration (Case 12).

Nephrectomy was performed three times (kidneys removed being all markedly tuberculous, two patients having been operated on before

radical operation on the seminal tract, one after). In one case, tuberculosis was found by ureteral catheterization of the right kidney. The patient is healthy and strong. The involvement is probably small and quiescent (Case 1). Another patient (Case 10) had a tuberculous right kidney, which has remained quiescent.

The lungs were considered involved in seven cases, all but one apparently quiescent; and six patients have done well since operation. The other patient (Case 2) died of mediastinal tuberculosis one year later. Whiteside advises against operation in cases with lung involvement. This is certainly wise if the lung involvement is active and extensive. When pulmonary cases become quiescent, however, I agree with Kocher that the genital tuberculosis should be removed; and I go further than Kocher in advising excision of the seminal vesicles as well as the epididymides or testes. The radical operation can be performed under procain infiltration anesthesia (1 to 400) with only a whiff of nitrous oxid gas occasionally to quiet the patient; or it can be performed under spinal, or posterior nerve root anesthesia. In reality, nearly all patients whose cases are not hopeless should be given the chance to get well. Whiteside has shown that desperate cases may sometimes be cured by vesiculectomy.

To reiterate, the pathologic study of these fifteen cases shows conclusively the preponderant importance of the seminal vesicles as the primary seat of the disease, and the urgency to remove them if radical cures are to be uniformly expected, and the present disgraceful mortality in genital tuberculosis is to cease.

B. Immediate and Remote Results of These Radical Operations.—The operation has not been reserved entirely for patients in good general condition as shown by the fact that seven patients had fairly definite evidence of tuberculosis of the lungs previous to operation and five patients had tuberculosis of the kidney, three requiring nephrectomy. Regardless of this fact, there has been only one death so far recorded, going back as far as seven years; and all but one of the cases have been followed almost a year at least. Perineal urinary fistula, that supposedly great bugbear of operations on the tuberculous prostate and vesicles, is present in only one case; and in this, only a few drops of urine escape during urination, so that the condition is not serious. Discharging sinuses are present either in the scrotum, groin or perineal wound in six cases. Most of these are recent cases and statistics show that they usually cease spontaneously with time. At any rate, they are not really annoying and compare favorably with statistics following epididymectomy or castration in which a much higher percentage of, and more annoying, discharging sinuses are recorded in the literature. Another most interesting demonstration is the fact that the sexual powers are not usually impaired in any way

except that the amount of ejaculatory fluid is much lessened. We have no direct evidence that any case has been impaired, though ten patients have not answered this question either before or after operation. Other operators, however, have shown that the removal of both seminal vesicles and vasa does not impair the sexual appetite or act. In three cases (Cases 2, 3 and 12) in which the vas, vesicle and epididymis on one side only were removed, the opposite epididymis became involved in the course of a year and required removal; and one patient died after the second operation (epididymectomy, one year later). Bilateral vesiculectomy was carried out in eight cases and bilateral epididymectomy or castration in eight cases; in three cases above referred to the second operation being performed later. (In these cases bilateral seminal vesiculectomy should have been done.) It may be found with time that it is wise always to remove both vesicles and ampullae and, if this is not done, either to ligate and divide the supposed healthy vas, which is not removed, or to remove the ampulla on that side, or to ligate the vas through an incision in the scrotum so as to avoid involvement of the second epididymis.

There has been one death, and that one year after the radical operation. On first admission of this patient (Case 2), râles were present in the lungs; and shortly afterward, fever, night sweats and abscess of the chest wall developed. Only one seminal vesicle was removed and the remaining epididymis developed tuberculosis, which was excised one year later. Death from extensive tuberculosis of the lungs, mediastinum, chest wall and shoulder occurred several months later. Removal of both seminal vesicles when the first operation was performed would probably have prevented involvement of the remaining epididymis, and possibly have given the patient a chance to recover from the lung tuberculosis. This case (Case 2) and two others (Cases 3 and 12) furnish excellent arguments for always excising both vesicles and both ampullae at every radical operation—especially as their excision does not destroy the sexual powers.

Two patients refuse to answer letters and questionnaires, which are not returned, indicating that the patients are still alive (Cases 2 and 4). I believe the results obtained in both of these cases were good.

Of the twelve cases in which the ultimate results have been obtained up to date, the radical operation has been eminently successful in improving the general health (even in Case 14 with previous generalized tuberculous arthritis). One of these patients developed tuberculosis in the remaining epididymis and required epididymectomy. In all cases, there has been ultimately an excellent local result, with improvement in micturition even in those cases with tuberculosis of the bladder and kidney (three of which were removed).

Considered, therefore, from every standpoint, the results obtained by the radical operation in these fifteen cases have been eminently satisfactory and far better than we have obtained by mere excision of the epididymis or testicle.

VII. DISCUSSION OF RADICAL OPERATIVE TECHNIC

In my paper [15] on this same subject in 1901, the various operations for the excision of the seminal vesicles were classified thus:

1. Perineal method of Zuckerkandl by Ullmann 1889
   Perineal method of Roux 1891
   Perineal method of von Dittel by Schede 1893
   Perineal method of Guelliot 1895
   Perineal method of Baudet 1898
2. Sacral method of Kraske by Schede 1895
   Sacral method of Rydygier by Schede 1895
3. Inguinal method of Villeneuve 1891
4. Suprapubic, rectovesical, extraperitoneal method of Young (20) 1900

At that time, thirty-four cases were to be found in the literature in which radical operations for tuberculosis of the seminal vesicles, associated with testicular disease, had been performed by one of the methods above indicated. The summary of the tissues removed was:

Part Removed.—One testicle (or epididymis), twenty-three times; both testicles, five; one seminal vesicle, twenty-three; both seminal vesicles, eleven; portion of prostate, five.

Immediate Results.—Good, no fistula, thirteen; fistula but otherwise good result, fourteen; in bad condition, two; not mentioned, three.

Ultimate Results.—Twenty cases, five deaths, ten well, four recurrences. Only eight cases were followed for more than one year; of these two died of pulmonary tuberculosis and four were cured.

Writing in 1906, Baudet and Kendirdjy,[16] in a most extensive article, detail at length the cases which are to be found in the literature and discuss the methods of operation, from which I shall extract liberally: There are two methods, the upper route and the lower route. The lower route comprises median perineotomy; ischiorectal perineotomy; the sacral method and the parasacral method. The upper route comprises the inguinal; the lateral laparotomy and the median extraperitoneal laparotomy. The inguinal is suitable only for one vesicle; if you wish to operate on two vesicles, it is necessary to perform two operations. The same applies to the lateral subperitoneal laparotomy. The median extraperitoneal laparotomy, which was described by the author and carried out in three cases, has since been abandoned on account of defective drainage and resultant severe infections.

15. Young, H. H.: Ann. Surg. **30**:601, 1901.
16. Baudet and Kendirdjy: Rev. de chir. **34**:380, 1906.

The perineal method is unquestionably the method of choice and it will be interesting to examine into the various technics which have been followed.

The first operation was that of Ullmann[17] of Vienna in 1899. Ullmann's patient was operated on in two stages—unilateral castration was carried out on the right side in June, 1889, and a month later the seminal vesicles were removed by the similunar perineal incision with the assistance of the finger in the rectum. After sectioning the fascia and the levator ani muscles, the prostate was completely exposed; and then, by introducing a metal sound into the bladder, the posterior wall of the bladder was made prominent by pressure. By this maneuver, the vasa and vesicles were easily removed. The vas deferens between the ampulla and groin was not extirpated; but a portion of the prostate which was tuberculous was excised.

Roux[16] performed his first operation in March, 1890, and subsequently he had two other cases. His procedure consisted of castration with high division of the vas and then extirpation of the seminal vesicle from below, which was made to appear in the upper portion of the wound by the pressure of the finger in the rectum, with the patient lying on his side—the incision extending in a curve across the perineum backward to one side of the rectum. With the use of a traction ligature, the vesicle was drawn farther down, separated, and with the stump of the vas deferens was divided close to the neck of the bladder. The remainder of the vas deferens, i. e., up to the inguinal canal where previously divided, was then removed with the seminal vesicle.

Weir,[18] in New York, was the third to perform seminal vesiculectomy in 1892. Weir carried the scrotal incision up into the groin and opened the inguinal canal, where he freed the vas as high up as possible on the right side, making a tear into the peritoneum in so doing. Then, leaving the testicle free and suspended by the vas, he placed the patient in the lithotomy position and carried out the operation of Roux, exposing and separating the seminal vesicle and extirpating the diseased portion of the prostate. The vas deferens was divided above the ampulla and the remainder of the vasa deferentia was removed from the front with the testicles (thus differing from the operation of Roux who removed the remainder of the vasa from below with the vesicle).

Schede,[16] in 1893, successfully removed both tuberculous seminal vesicles and vasa through the incision of von Dittel in a patient who had previously been castrated on both sides.

---

17. Ullmann: Centralbl. f. chir. **8**:133, 1899.
18. Weir: Med. Rec. **44**:163, 1894.

Guelliot,[5] in 1895, published two cases in which he had removed the testicles through a scrotal incision and the seminal vesicles through an incision which began in the perineum and extended along the right border of the anus to the median line back of the anus, by means of which he was able to push the anus and rectum out of the way.

Baudet and Kendirdjy,[16] in 1898, used the following technic: A curved incision in the perineum extending farther back to the right than to the left, exposure of the prostate and seminal vesicles after division of the levator muscles; separation and division of the vasa deferentia above the ampullae after ligating the lower end; division of the vas and vesicle "in the interior of the prostate," a caseous nodule of which is removed. Right castration was then performed, the inguinal canal being opened and the vas deferens followed deeply and completely removed.

Practically all of the operators who have been referred to divided the levator ani muscles and deep lateral structures in exposing the seminal vesicles. In order to facilitate the removal of the seminal vesicles, various methods have been employed. The first is that of Ullmann who uses a sound in the bladder to make pressure on the posterior wall and thus elevate the vesicles. Others caught the prostate with toothed forceps. Roux [16] employed a finger in the rectum, which was passed up above the vesicles and by pressure brought them down into view. Subsequently, he employed, in addition, traction sutures (which have since been advocated by Squier in this country). Most operators have divided the vasa deferentia as high up as possible in the perineum, ligated and divided the upper portions of the seminal vesicles and freed them from the bladder by dissection from above downward. Legueu [16] carried out the opposite procedure, namely, division of the vesicle and vas at the upper end of the prostate and separation of these structures from the bladder by dissection from below upward. In 1913, I [3] devised an unusually long, slender prostatic tractor which could be passed through the urethra and utilized first to expose the membranous urethra and prostate in the early dissection through the perineum and subsequently to draw down the seminal vesicles and facilitate their exposure and excision, without division of the levatores ani, and without insertion of a finger in the rectum, using both traction and leverage.

In discussing the removal of the vas deferens, Baudet [16] says that it is indispensable to open the inguinal canal up to the peritoneum, to isolate the vas and liberate it well into the pelvis in order to extract it. He also thinks it is better to commence the operation from the perineum, remove the seminal vesicles and ampullae and then extricate the rest of the vas with the testicle from above. The vas can be drawn out easily without opening the inguinal canal.

A. Results Obtained by Radical Operations.—Baudet's analysis of forty-six cases, which he collected from the literature in 1906, is as follows: The inguinal method was used in six cases. Two patients died within a year after the operation—one of meningitis and the other of tuberculosis of the lungs. Two were well one year and three months after operation. In one case, two months after operation, the wound was in a bad condition being involved in the tuberculous process. One patient was well on discharge, but was not followed afterward. Three patients were operated on by the median subperitoneal laparotomy method—all bad results. The operation was condemned by the author in a subsequent publication. The sacral method was used in two cases; both patients recovered from operation and were discharged in good condition, but not followed afterward. The parasacral method was used in five cases; one with very bad wound healing, four left in good condition. None were followed after discharge from the hospital. The perineal method was used in thirty cases, with these results: well on discharge but not followed afterward, ten; deaths, four; four years, two and one-half years and five months, respectively, of lung tuberculosis, and after six months of tuberculous meningitis; well, sixteen cases, ten of which were followed for more than one year. One patient died four years later of apoplexy. With the exception of the median extraperitoneal laparotomy method, there were no immediate operative deaths during the stay of the patients in the hospital in forty-three cases. In fifteen of forty-five cases, the prostate was found to be involved.

The results found in the thirty cases in which the vesicles were removed through the perineum (the testicle, epididymis and vas through the groin or scrotal incision) are, indeed, very good; and, although this list comprises many different procedures, the results obtained are certainly better than have been secured even in more recent times by castration or epididymectomy alone without operation on the vesicles. Regardless of this fact, Baudet took a very conservative attitude—that the operation of vasovesiculectomy should be reserved for severe cases with either very marked involvement of the seminal vesicles or with tuberculous perineal fistulas. But he remarked that the presence of tuberculosis elsewhere than in the lungs (if not marked) did not contraindicate operation in these cases. Roux, on the other hand, considered that vasovesiculectomy should be performed as a prophylactic operation against involvement of the other epididymis and generalization of the tuberculosis.

At the Société de chirurgie de Paris, October 13 and Nov. 17, 1909, Baudet [19] presented two cases of vasovesiculectomy for genital

19. Tr. Soc. de chir. de Paris, Oct. 13-Nov. 17, 1908. Rev. de chir., 1909.

tuberculosis, in one of which removal was accomplished through the combined perineal and inguinal method and in the other entirely by the inguinal method of Villeneuve, with good results. In the discussion which followed, Marion presented his conclusions as to the problems as follows:

> Vesiculectomy is a legitimate operation which deserves current usage. It relieves foci of tuberculosis dangerous for the general health and menacing to the urinary and remaining genital organs. Results of the operation, when scientifically carried out, are good in the great majority of cases. Lesions elsewhere, not due to the genital lesions alone, are contraindications; but nevertheless cystitis aggravated by tuberculosis of the testicles is not a contraindication. The perineal route should be employed always when there is a double vesiculitis or vesiculitis and prostatitis and when there are data as to the lesions or the single vesicle is large. The inguinal route should be reserved for single vesiculectomies, slightly involved and clearly unilateral.

In my experience this is almost impossible to determine before operation.

Legueu agreed with these statements of Marion; but he stated that he would reserve the operation for more severe cases which were markedly aggravated.

B. Review of the Results Obtained by American Operators.—This may be divided into two stages: early operations (before 1902), Weir,[18] one case; Fenger,[20] one case; Walker,[21] one case; Bolton,[22] three cases; Young,[23] three cases; Hutchinson,[24] one case. After that there was a quiescent period in the American literature when Whiteside's[11] article appeared in 1910, in which he reported two cases with excellent results in patients who were in desperate condition. The technic followed by Whiteside is to start with the incision in the inguinal region, the vas being separated as high as possible in the inguinal canal, clamped and divided, and the testicle and outer portion of the vas being removed. The patient was then placed on his back and through a perineal incision the seminal vesicles were exposed and freed. In order to remove the remaining vas, the finger was pushed as far as possible into the depths of the retrovesical wound; then by "pushing upward on the forceps which had been previously clamped to the cut end of the vas deferens in the inguinal canal," it was possible to push this clamp through into the perineal wound, carrying the cord with it. By removing this anterior clamp and replacing it with another through

20. Fenger, cited by Senn, N.: Tuberculosis of the Genito-Urinary Organs. Male and Female, Philadelphia, 1897.
21. Walker: Maryland M. J. **1**:55, 1877.
22. Bolton: Ann. Surg. **29**:106, 1900.
23. Young, H. H.: Footnotes 14, 15 and 16.
24. Hutchinson: Ann. Surg. **29**:567, 1900.

the perineal wound, the entire spermatic cord and the seminal vesicle with the right lobe of the prostate was removed. The same technic was followed in the second case which was found to be much more difficult. Whiteside[25] follows this with a second paper in 1914, in which he was able to present twenty-two cases of vasovesiculectomy for tuberculosis. In this article he states again that the operation should be reserved for very difficult cases and that he had employed it in "only the old and apparently hopeless cases." He states he has modified the technic.

I have tried extirpation of prostate and vesicles from above (groin), but I will not try it again. The vesicles are easily exposed from above but the wound drains deeply and absolute failure followed by death within a short time from peritoneal infection or long continued sepsis in a deep, poorly drained wound is apt to be the sequel. I believe this operation offers the only hope of life to an otherwise doomed patient. In the twenty-two cases I have operated on in the past six years, I have had no immediate deaths and four eventually complete recoveries. Nine have died of pulmonary tuberculosis, three have died within a few months from local infection, six have been lost sight of—presumably they may be dead.

The fact that practically all of Whiteside's patients were in desperate condition partly accounts for the high subsequent mortality; but is it not probable that the employment of the inguinal method of Villeneuve in some of the cases, and in the others his own method of opening the inguinal canal and pushing the clamp down from it into the pelvis retrovesically with the attached vas in removing the latter, is responsible for some of his infections and death?

In his final paper,[12] in 1919, he again describes the same method of removing the vas with the assistance of the clamp through the inguinal canal into the perineal wound as above described. He then states:

I regret that this first case is the only one of which I have certain knowledge that the remote result was successful. Several others have been under observation for months, but none for more than two years. Several have died of pulmonary tuberculosis within a year, and at least one of rapid miliary tuberculosis. As a result of my experience I strongly advise that those cases showing even slight pulmonary involvement be considered inoperable. I have operated on three or four such with disappointing results. The wounds of operation do not heal and only add to the patient's discomfort. In such cases, when vesical tenesmus demands interference, a simple cystotomy for drainage is preferable.

When we contrast the result after this very radical operation and the administration of tuberculin, with the result of any equally advanced case treated with medicine or general hygienic measures, the difference in outcome is striking. On the one hand, the patients have regained health and are perhaps well; on the other, we so often see a broken down young man suffering severely and awaiting death.

25. Whiteside: Tr. Am. Assn. Genito-Urin. Surg. **9**:173, 1914.

In 1918, two articles appeared in America, the first by myself, in which I described the new radical procedure which I[3] had followed since 1914 and the second by Quinby[6] who detailed seven cases of radical excision of the seminal tract for tuberculosis according to my technic, without a single operative death and with excellent immediate results. There was no mortality in Quinby's cases, and the results obtained are indeed excellent and fully confirm my statements in regard to the effectiveness of the radical operation.

VIII. CONCLUSIONS

Statistics show conclusively that in most cases of "genital tuberculosis" the primary focus is in the seminal vesicles. Tuberculosis of the seminal tract is, therefore, the better name.

From the seminal vesicles, the globus minor of the epididymis is generally next attacked.

From the seminal vesicles, the prostate, urethra and bladder are often attacked later.

From the seminal vesicles, more rarely, the kidney may be invaded through the lymphatics along the ureter.

From the seminal vesicles by the posterior line of lymphatics, the mediastinum and the lungs may be involved.

Tuberculosis of the seminal vesicles (ampullae and prostate, if involved) ranks first in importance when a curative operation is proposed for genital tuberculosis.

Epididymectomy with injection of the vas and vesicle, as proposed by von Büngner, is preferable to simple excision, as Cunningham has shown.

Still better results may be obtained by bringing the vas permanently out of the skin in the groin for frequent injection and continuous drainage as proposed by myself in 1901, and often employed.

But with all the nonradical procedures, a high percentage of failures —ultimate infections of remote organs and death—result.

The only hope of radical cure or complete arrestation of the disease is by the radical operation—"epididymovesiculectomy," or better "excision of the tuberculous seminal tract."

This operation has already saved many otherwise hopeless cases.

By the technic described by myself, with the use of a long "urethral prostatic tractor," the urinary tract can be avoided, while the removal of vesicles, ampullae and prostatic lobes is facilitated.

The entire vas deferens can be removed by the to-and-fro traction described without opening the inguinal canal as previously done.

The incisions are comparatively small and the operation can be performed under procain infiltration anesthesia (1 to 400) if the lungs are involved.

The fifteen cases reported here (in seven of which the lungs were probably previously involved, and in five of which one kidney was tuberculous, etc.) and in which only one patient died of tuberculosis a year later, and the others are apparently completely arrested, shows the effectiveness of this radical operation.

In my opinion the only justifiable operation in tuberculosis of the seminal vesicles and epididymides is a radical excision of the seminal vesicles, ampullae (and lateral lobes of prostate if involved) through the perineal prostatectomy incision, coupled with epididymectomy and extraction of the entire vas deferens, with partial or complete castration if necessary (a rare occurrence).

The old-fashioned castration is an unnecessary mutilation and does not often cure. Radical excision of the seminal tract is the operation of choice.

RADIOHUMERAL BURSITIS, EPICONDYLITIS, EPICONDYLALGIA (TENNIS ELBOW)

A PERSONAL EXPERIENCE *

ROBERT B. OSGOOD, M.D.

BOSTON

Tennis elbow, as it has been commonly called in this country and Great Britain, or the epicondylitis of Franke, or the epicondylalgia of Féré, is a condition that is fairly common among tennis players, though by no means confined to them. The first mention of the lesion which I have been able to find was by Bernhardt, in 1896, in the *Neurologisches Centralblatt,* "On a Little Known Form of Occupational Neuralgia." He states that Remak had previously reported a case.

The most significant contributions on the subject since this article have been made by Bähr [1] in 1900, Clado [2] in 1902, Preiser [3] in 1907 and 1910, Vulliet [4] in 1909, Franke [5] in 1910, Momburg [6] in 1910, Coues [7] in 1914, and Dubs [8] in 1920. The articles by Coues,[7] in English, and Dubs,[8] in German, are the most illuminating and complete which I have seen. There has been no entirely satisfactory explanation of the exact etiology of the condition nor any convincing description of its pathology.

The onset of the typical symptoms is rarely absolutely sudden, although the symptoms are well established within a few hours after some physical exertion. The fact that the precise moment that the physical exertion which may fairly be held to have caused the trouble

* Read before the Boston Surgical Society, April, 1921.

1. Bähr: Tennisschmerzen, etc., ein kleiner Beitrag zur Pathologie des Radio-Humeralgelenkes, Deutsch. med Wchnschr. **26**:713, 1900.

2. Clado: Der Tennisarm, Progrès méd. **16**:273, 1902; abstr. Nachr. f. Unfallhlk., 1903, p. 112.

3. Preiser, G.: Der Tennis-Ellenbogen, Zentralbl. f. Chir. **34**:65, 1907; Ueber Epicondylitis humeri, Deutsch. med. Wchnschr. **36**:712, 1910; Statische Gelenkerkrankungen, Stuttgart, Enke, 1911.

4. Vulliet: L'épicondylite, Semaine méd., Paris, 1909; abstr. Ztschr. f. orthop. chir. **26**:507, 1910; Die Epicondylitis humeri, Zentralbl. f. Chir. **37**: 1311, 1910; abstr. Zentralbl. f. chir. u. mech. Orthop. **5**:81 (Feb.) 1911.

5. Franke, F.: Ueber Epicondylitis humeri, Deutsch. med. Wchnschr. **36**: 13, 420, 1910.

6. Momburg: Ueber Periostitis am Epicondylus humeri, Deutsch. med. Wchnschr. **36**:260, 1910.

7. Coues, W. P.: Epicondylitis (Franke) or Tennis Elbow, Boston M. & S. J. **170**:461 (March 26) 1914.

8. Dubs, J.: The So-Called Epicondylitis Humeri, Schweiz. med. Wchnschr. **50**:166 (Feb. 26) 1920; Ibid. **50**:187 (March 4) 1920; abstr. J. A. M. A. **74**: 1289 (May 1) 1920.

cannot often be remembered by the patient I believe to be significant, as will later appear.

The histories recount that in the course of, or following, a game of tennis, or some continuous labor, such as painting an overhead wall in an awkward position, or striking a blow with a hammer, discomfort, amounting sometimes to acute pain, is felt in the elbow region. Seeking to localize the symptoms, the patients find tenderness in the region of the external condyle of the humerus. This tenderness may be directly over the epicondyle and may seemingly be confined to this; but with careful observation, its exact location will be found to vary with different positions of the elbow: flexion, extension, pronation, and supination. In certain positions, there may be no tenderness at all directly over the epicondyle, it having shifted perhaps in right angle flexion and pronation a little mesially and distally.

The patients do not commonly seek medical advice at once. The condition is not constantly annoying; but its persistence over weeks or months and the interference which it causes with their sport or occupation lead them to seek relief.

A typical symptom, which is also annoying, occurs apart from sports and occupation. This is a sudden sensation of weakness and pain, often running down the forearm when an attempt is made to lift an object, like a glass of water or a plate or a book, with the elbow fully or partially extended and the forearm muscles, especially the extensors, set. It is hard to anticipate this inability. The water may be spilled, the plate broken, or the book dropped. It may be possible for the patient to lift momentarily a fairly heavy weight with the extended arm, without discomfort; but carrying a bag for any length of time usually produces a feeling of weakness and an ache, which may become acute.

Without treatment, the condition lasts from six months to several years, with varying degrees of severity. Even after periods of almost complete quiescence, recurrences have been common.

The physical examination of the ordinary subacute cases reveals little. Inspection at first seems to show nothing abnormal; but if the sound and the affected limbs, in a muscular patient, are placed in identical positions, for example, the hands resting on the pubes, there will be noticed a slight obscuration of the normal contours of the affected elbow, consisting of a little fulness just over the distal tip of the epicondyle and extending distally and mesially, filling up the slight normal depression over the radiohumeral joint (Fig. 1).

Palpation also at first seems to yield negative results. There is no heat and no sharply marked swelling; but over the area of tenderness, by careful examination, a feeling of increased elasticity may be appreciated. The tenderness at first seems to be sharply localized

over the epicondyle; but, in reality, it is usually slightly distal and mesial over this portion of the radiohumeral joint, and shifting slightly in different positions of flexion and extension, supination and pronation. In cetrain positions, usually extreme pronation, there may be no tenderness whatever over the epicondyle. The stereoscopic roentgenograms have been completely negative in our cases, though evidence of "periostitis" has been reported by other observers (Fig. 1, 2 and 3).

The motions are free, and when passively carried out, are painless. When a fist is made and the wrist is plantar flexed, there is pain at the seat of the lesion; but if the wrist is dorsally flexed, relaxing the exten-

Fig. 1 (Case 1).—Anteroposterior roentgenogram of affected elbow, showing shadow of soft part swelling over lateral condyle and no evidence of lime salt deposit over the epicondyle.

sors, this pain is lessened or disappears. When an attempt is made to lift an object, with the elbow fixed in full or partial extension, especially if the hand is supinated, there is pain. In a quick, sudden extension of the forearm, as in a backhand stroke in tennis, there is often, but not always, sharp pain, ceasing quickly.

THECRIES OF ETIOLOGY

Numerous theories of etiology and the essential pathology have been advanced: (1) tearing off of certain muscular attachments to the external condyle, which are never given a chance firmly to reunite

(Coues); (2) injury to the periosteum of the condyle, with a subsequent periostitis (Blecher [9]); (3) periostitis due to postinfluenzal infection (Franke [5]); (4) injury to the radiohumeral capsule (Bähr [1] and Dubs [8]); (5) arthritis (incongruence) of the radiohumeral joint (Preiser [3]). In a recent article by Louis Carp [10] one case is reported, and after an incomplete review of the literature, he states that the etiology is still uncertain. Tavernier [11] recognizes the fact that the tenderness is a little below and mesial to the epicondyle. He has suffered from the condition himself and believes it to be due to the tearing off of a few fibers of the common extensor tendon with irritation of the periosteum; but he states frankly that this theory does not

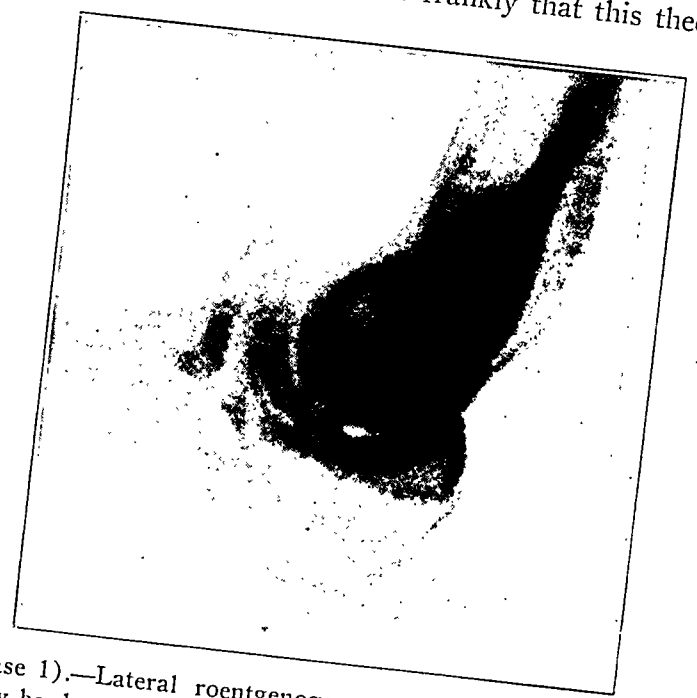

Fig. 2 (Case 1).—Lateral roentgenogram of elbow; no lesion of bone or soft parts may be detected.

account for the persistence of the symptoms. He reports one case in which resection of the epicondyle gave relief; and he advises making an incision beneath the epicondyle and scraping the bone, as a method possibly worth trying in rebellious cases.

None of these theories of the essential pathology are entirely satisfactory in a typical case, though each may have seemed to explain the lesion in an individual patient. The syndrome commonly

9. Blecher: Ueber Roentgenbefunde bei der Epicondylitis humeri, Fortschr. a. d. Geb. d. Röntgenstrahlen **20**:239, 1913.

10. Carp, Louis: Epicondylitis Humeri, Surg. Gynec. & Obst. **32**:257 (March) 1921.

11. Tavernier: Lyon chir. **18**:257, 1921.

met can hardly be explained by one, or all, of these etiologic theories. In twelve personally observed and carefully examined cases, these hypotheses failed completely to explain the symptoms or to satisfy the physical examination.

ANATOMY

The essential anatomy of the region (Fig. 4) consists superficially of the extensor group of muscles and the brachioradialis or supinator longus which spring from the external condyle of the humerus and

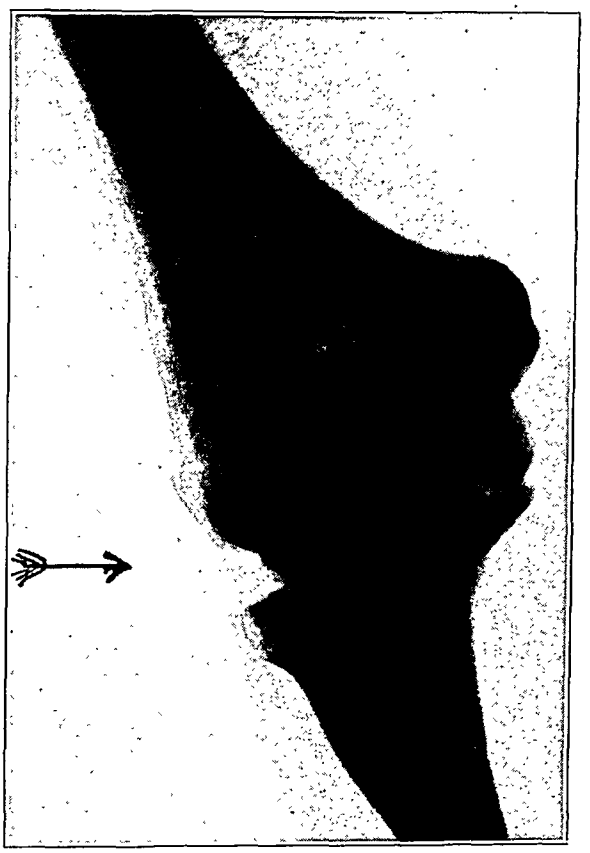

Fig. 3 (Case 1).—Anteroposterior roentgenogram of unaffected elbow; no shadow of soft part swelling over lateral condyle.

the condylar ridge above. Superficial also and most posteriorly is the considerable origin of the anconeus. Then, partially covering it, comes the extensor carpi ulnaris; next, the common extensor of the fingers and the extensor carpi radialis brevior and longior; then more anteriorly and mesially the brachioradialis or supinator longus. Beneath this conjoined tendon is the supinator radii brevis, attached to the very tip of the epicondyle with some fibers which actually blend with the radiohumeral joint. Over the supinator radii brevis and the radiohumeral joint, the conjoined tendon must have free play.

None of these muscles receive their motor nerve supply in the immediate neighborhood of the epicondyle or the radiohumeral joint. The sensory supply is from branches from the radial nerve. There are no important blood vessels directly over or beneath the conjoined tendon.

Before offering a possible explanation of the condition, a typical case will be reported. This case is a personal experience.

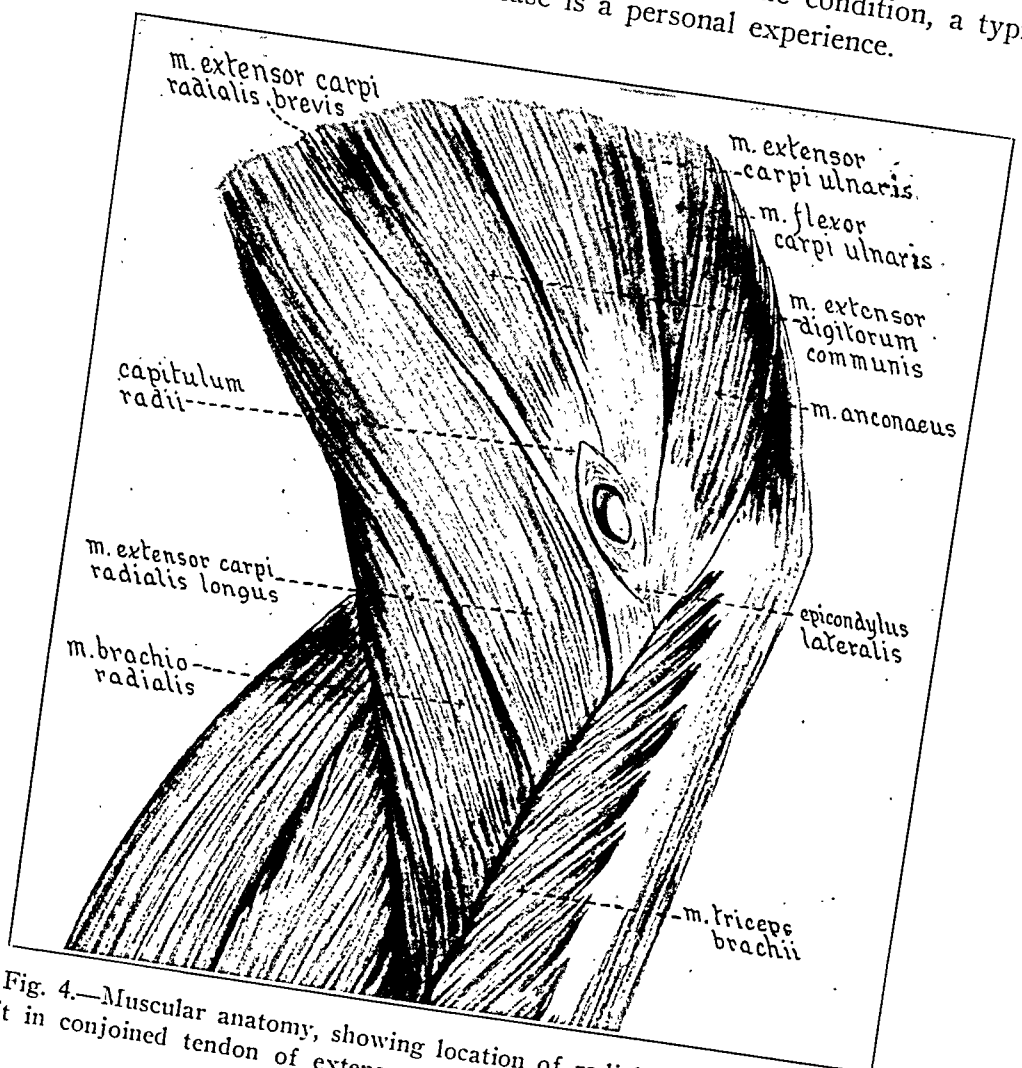

Fig. 4.—Muscular anatomy, showing location of radiohumeral bursa through split in conjoined tendon of extensor muscles.

REPORT OF CASES

CASE 1.—*History.*—A man, aged 48, who had played tennis for thirty-five years, and who was fond of the game, playing it hard, but in poor form, had never suffered any joint inconvenience from either handball, squash racket, or tennis. During the summer, from June to October, he had played for years, on an average, half a day once or twice a week. In July, 1920, while on a vacation and in good condition, he was playing a closely con-

tested singles set, in which no new strokes were being tried. He became conscious during the game of a dull pain on the outer side of the right elbow, the origin of which he did not remember. It did not seriously interfere with his playing. After the game, there was a slight smarting sensation in the region of the epicondyle and radiohumeral joint, no appreciable heat or swelling, rather acute tenderness to pressure, and a little pain running indefinitely down the forearm on certain motions. The initial discomfort passed off in a few hours. The tenderness remained; and he was only occasionally reminded of the existence of the lesion by a sharp, but not disagreeable, pain in various coordinated movements, most of which had to do with extension of the forearm and flexion of the fingers. This was more marked in supination with flexed fingers than in pronation.

For a few weeks, the arm was strapped with 10-inch (25.4 cm.) strips of adhesive plaster, applied with the arm in supination, running from the palmar surface of the forearm over the epicondylar surface of the upper arm, limiting full extension, and applied with the hope of relieving tension on the supinator radii brevis and brachioradialis (supinator longus). He continued to play tennis whenever the opportunity was offered, and found relief from the strapping, though this relief was not complete. His interest in the lesion having been aroused, he decided to do everything he could to make the condition worse. He removed the plaster and played throughout the remainder of the season without protection of any sort. The result was unexpected. He was never completely unconscious of the trouble during a game, and a sharp stab of pain occasionally interfered with the success of a hard backhand placement shot. In general, however, his game was not interfered with, if the scores of sets with players whose métier he had taken for several years can be taken as criteria. He even entered a small local doubles tournament, which, with the help of a good partner, he completed. Nor was this playing done with any gritting of the teeth. Service was not interfered with at all; and the occasional, momentary, sharp pain did not outlast the stroke. There frequently was a feeling of heaviness and lameness in the arm following a long match; but he was never kept awake by the pain, and the next morning he felt as well as ever. He could paddle, throw a ball, and swim without unpleasant sensations.

The condition, however, remained stationary. The tenderness continued; the discomfort was increased by carrying a heavy bag; distinct weakness was felt when the marmalade jar was passed at breakfast, and a blow over the external condyle caused an involuntary jump.

None of the theories of the nature of the lesion seemed fully to explain these symptoms. The anatomy of the conjoined tendon and its necessary movement over the supinator radii brevis tendon and the radiohumeral capsule suggested the possibility of the existence of a small bursa at this point. The chief books on anatomy were consulted but no description of a bursa in this region was found (Fig. 5).

Dr. Pearce Coues called my attention later to a description of the interosseous bursa, said to be involved in "tennis elbow," in Carl Toldt's "Atlas of Human Anatomy," Section on Myology, page 321. This bursa, however, was located at the lateral aspect of the biceps

tendon, between it and the tendon of the brachialis anticus, much too distal and mesial to explain the typical symptoms of tennis elbow, though it may explain those of the baseball "glass arm," in which the bicipital radial bursa may also be involved.

Dissections were made in the anatomic department of the Harvard Medical School, thanks to the kindness of Drs. John Warren and A. S. Begg, and a fairly well-defined, small bursa was found beneath the conjoined tendon over the radiohumeral joint (Fig. 6).

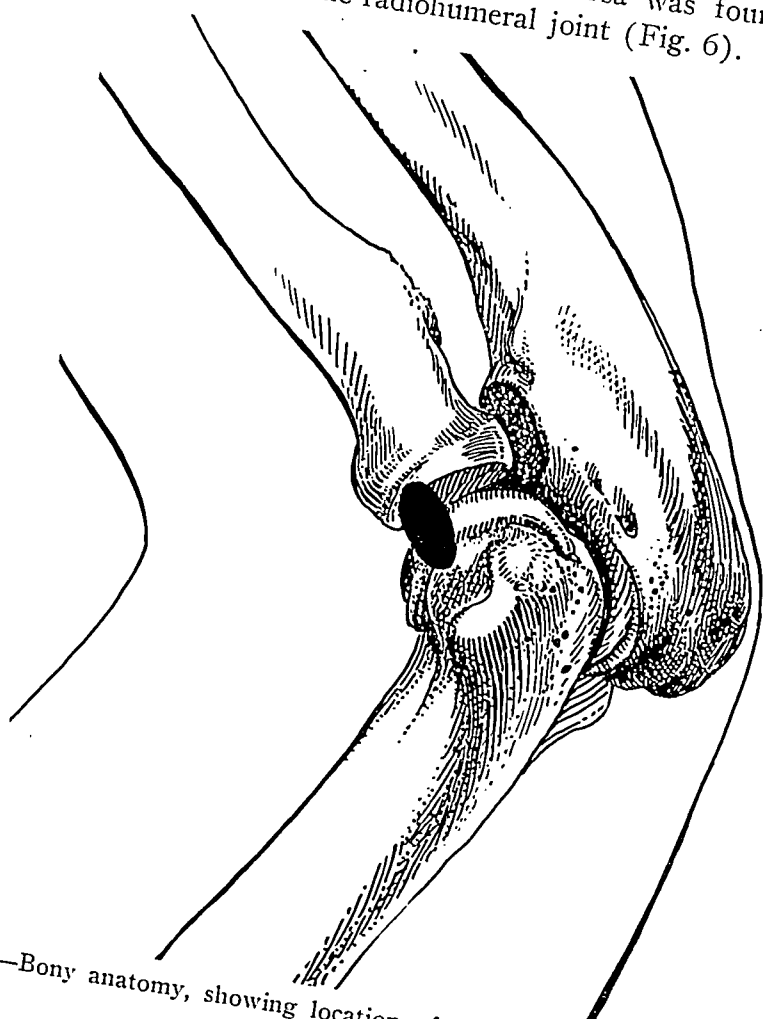

Fig. 5.—Bony anatomy, showing location of small radiohumeral bursa.

In order to discover whether this bursa was affected in my case, Dr. Lloyd T. Brown and Dr. Philip D. Wilson explored this region under local anesthesia. An extremely sensitive area was found, with outlines of a dirty, grayish-white. There was no distinct sac containing fluid. The following report of the operation was made by Dr. Pearce Coues, who was present.

Operation and Results.—Nov. 28, 1920, under infiltration anesthesia (0.5 per cent. procain) of the external aspect of the right elbow, extending from

the external condyle downward, over the head of the radius, a slightly oblique incision, 1½ inches (3.8 cm.), was made, extending from the condyle downward, in line with the radius, well over the radial head. Dissection was carried down through the fascia in this line, and the fibers of the conjoined tendon were split, after infiltration of the deeper tissues. An exquisitely tender point was located just below the condyle, on its lower surface, between it and the radial head. Incision was enlarged slightly downward, to come directly over this tender area. The radiohumeral joint was opened and exposed. It appeared normal. The radial head rotated freely. All muscle fibers seen in this region were smooth and intact. Just below the epicondyle a small

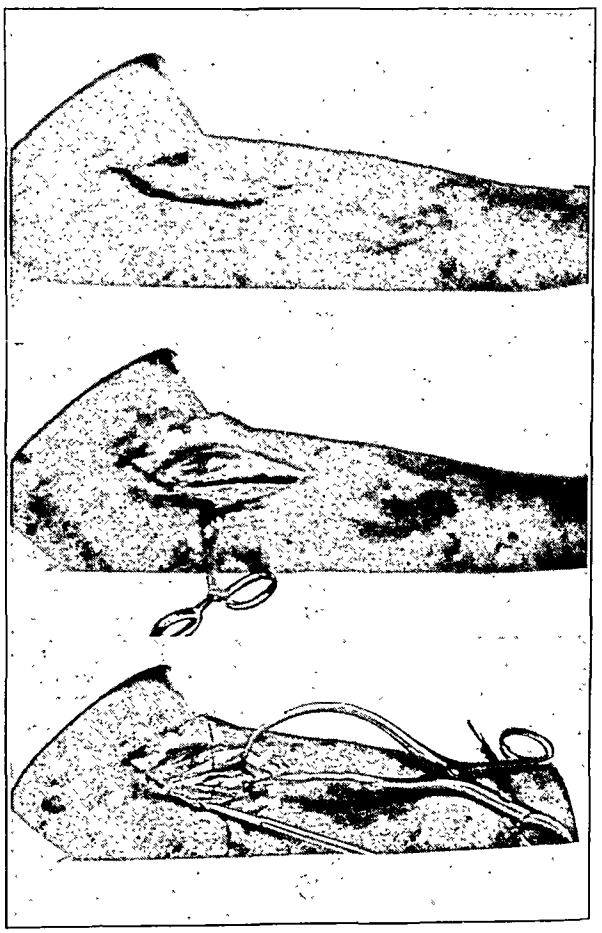

Fig. 6.—Dissection of specimen: *A,* line of skin incision; *B,* retraction of skin and subcutaneous tissue, conjoined tissue exposed, incision in line of fibers of conjoined tendon, and *C,* conjoined tendon split and retracted with opened radiohumeral bursa beneath, silk threads through walls of bursa.

amount of bluish-gray, thickened tissue was seen, which had the appearance of bursal tissue, lying directly above the anterolateral surface of the head of the radius, with fibrinous exudate on it and outside the joint. There was no free fluid found in this tissue. Two pieces of this tissue were excised for study, one from the side and one from the base of the small mass. An excellent view of the attachment fibers of the short supinator was obtained;

all muscle fibers were intact, with no fraying or thinning. Pressure over the bursalike tissue near the condyle produced the characteristic pain, sharply localized, that is complained of in these cases. The wound was closed in layers.

The pathologic report by Dr. H. S. Hartwell was chronic inflammatory tissue (Fig. 7).

The convalescence was uneventful; and within four weeks, all symptoms had practically disappeared. No tennis was played during the winter; but repeated games of handball and squash racket were played, without a return of symptoms. A heavy bag can now be carried without discomfort.

Fig. 7.—Low-power photomicrograph of portion of tissue excised from bursalike tissue found in Case 1: areolar connective tissue and fat, fibrosis and chronic inflammatory tissue.

I have refrained from publishing this paper until I had had the opportunity to play tennis through another full tennis season, so that I might determine whether a recurrence, which has been quite common in the ordinary case, would occur. There have been absolutely no symptoms of such recurrence, and I consider the condition entirely relieved.

Further dissections were subsequently carried out at the school. In one case, no bursa was found; but in seven elbows examined consecutively, bursae were present, varying in size from 1 cm. to 2.5 cm. in diameter.

CASE 2.—A typical, early case of three months' duration was encountered in the Orthopedic Clinic of the Massachusetts General Hospital in a painter, aged 41. Complete immobilization for two weeks having caused no abatement of the tenderness, the patient was persuaded to allow an exploratory operation to be performed, on the basis of the favorable outcome of the previously reported case. This case was more acute, with pain radiating down the arm and weakness of hand grip. A bursa, 2 cm. in diameter, containing a slightly cloudy, glairy fluid, resembling synovial fluid, was found (Fig. 8). The walls of this sac, which did not communicate with the joint, were curetted, and the wound was closed tight, by suturing the split in the conjoined tendon

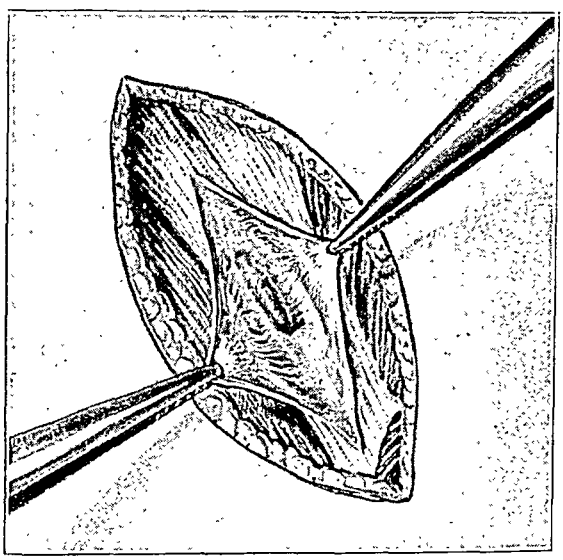

Fig. 8 (Case 2).—Operative exposure of bursa.

with catgut and the skin with silk. The arm was immobilized in plaster for one week; gentle movements were allowed during the second week, and freedom of use after fourteen days. The tenderness entirely disappeared and the patient resumed his work as a painter, without discomfort and with a full range of painless motion.

CASE 3.—*History.*—Mr. L., seen in private practice, gave a typical history of so-called tennis elbow, following a few hours after strenuous cranking of an automobile, months before. He had had no treatment other than local application; and the symptoms, though never severe, were annoying, especially in carrying a bag or lifting an object from the table. The physical signs were absolutely characteristic.

Operation and Results.—Since it was necessary for this patient to undergo a minor operation on an amputation stump of his left leg, he was advised to have the elbow explored at the same time, in the hope that the mild, but persistently annoying, symptoms might be made to subside more quickly. The

incision described in Case 1 was made, and the dissection was carried beneath the split tendon, revealing a space about 1.5 cm. in diameter, with smooth walls, but containing no free fluid. The walls of this space were curetted and a bit of the wall excised. The immediate convalescence was uneventful and the tenderness disappeared. He could lift an object without pain and could grip with the wrist in flexion without disagreeable sensation. This patient's symptoms subsequently recurred slightly. The tenderness remained absent and flexion of the fingers with an extended wrist remained painless. Carrying a heavy bag, however, again became vaguely uncomfortable. The discomfort was, however, not enough to demand further treatment.

Pathologic Report (H. F. Hartwell).—The specimen consisted of a small fragment composed of fat and connective tissue, along one surface of which was a layer of flat cells somewhat degenerate, suggesting endothelium. There was chronic inflammation (Fig. 9).

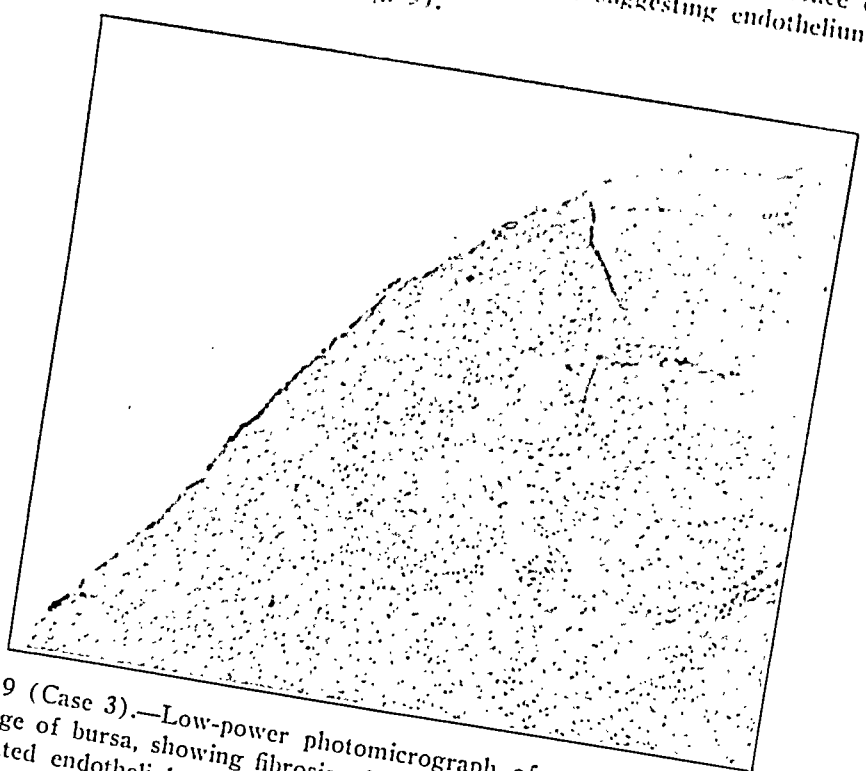

Fig. 9 (Case 3).—Low-power photomicrograph of portion of tissue excised from edge of bursa, showing fibrosis of wall and a surface strongly suggesting degenerated endothelial membrane.

COMMENT

Dr. E. A. Codman has informed me that several years ago he became interested in this condition and observed many typical cases among working men in the Outpatient Department of the Massachusetts General Hospital. He at that time suspected the presence of a bursa, but was unable to demonstrate one by dissection at the school. He discovered that he could apparently shorten convalescence by making a transverse incision over the radiohumeral joint, and he believed that he thereby relieved the tension of the fascia gliding over it, which

he supposed had set up an inflammation in the areolar tissue beneath. I believe I am right in stating that he has never published his observations, which he was kind enough to describe to me after I had told him of the bursa findings.

Another sidelight on the condition has been thrown by Dr. Wade Wright, in charge of the Clinic in Industrial Medicine at the Massachusetts General Hospital. I have considered with him about fifteen cases of pain referred to the external condyle of the humerus, occurring in connection with lead poisoning. In several of these, there had been no trauma which the patient could remember; and in several, there have been symptoms referred to the left elbow and to other joints and bursae. The association of joint pain in cases of lead poisoning has been well known for many years, the first article of which I am aware being written by Tanquerel des Planche,[12] "Lead Poisoning; A Treatise."

Dr. Wright also has been impressed with the common symptoms suggesting subacromial bursitis in cases of lead poisoning. I have examined several of these cases of pain referred to the external condyle; and the symptoms have been absolutely typical of the traumatic or occupational tennis elbow. The symptoms in several of them have disappeared along with the relief of the other symptoms of lead poisoning. This connection seems perhaps to add strength to the theory of a bursitis as the common pathologic condition.

SUMMARY

1. Tennis elbow, epicondylitis, or epicondylalgia presents a fairly typical syndrome, occurring in connection with certain sports, most commonly with tennis, and in various occupations and in lead poisoning. The right arm is more commonly affected than the left. This condition occurs more often in men than in women, but it is typical in both sexes. One case is reported in a boy of 14.

2. It seems to be most frequently caused by strenuous or repeated extension of the arm in a flexed position, meeting a sudden opposition to further extension, as in a backhand stroke in tennis, fencing or in boxing (Vulliet[4]), or by striking blows with a hammer with the arm in a cramped position, by the punching and lasting of a shoemaker, by the slinging of mortar by the mason. It is possible that an infection or toxin may be the etiologic factor in certain cases.

3. The essential pathology is believed to be an inflammatory reaction in a commonly existing bursa, varying in size, and located beneath the conjoined tendon of the extensor muscles between this tendon and

12. Tanquerel des Planche: Lead Poisoning: A Treatise, Boston, Tappan, Whittemore & Mason, 1850.

the tip of the epicondyle, the origin of the supinator radii brevis muscle, and the radiohumeral joint. Somewhat similar symptoms occasionally referred to the mesial condylar region may be explained by similar areolar tissue reactions beneath the common tendon of the flexor muscles. No constant bursa has been found in this region but adventitious ones may well occur.

4. Heretofore, the only method of treatment which has been generally successful has been complete immobilization for six weeks. Untreated, the discomfort may persist indefinitely; but it is usually self-limited, in from three months to a year. The operation of splitting the conjoined tendon, opening the bursa, evacuating the contents, and curetting its walls is not likely to do harm; and in two cases it has been followed by a rapid subsidence of symptoms and free use of the arm.

5. It is possible that the so-called epicondylitis may be due to a lesion of more than one structure, as in the operative findings of Franke[5] and Goeldel;[13] but if in the typical lesion, the bursa described above is commonly found, and if its affection, as in our cases, should be found to be fairly constant, the name radiohumeral bursitis may be considered more descriptive than the term epicondylitis or tennis elbow.

---

13. Goeldel: The Causation and Treatment of Epicondylitis, München. med. Wchnschr. **67**:1147, 1920.

STUDIES IN TRAUMATIC FRACTURES OF THE CRANIAL BONES

I. EDEMA OF THE BRAIN; II. BRUISES OF THE BRAIN *

CARL WESLEY APFELBACH, S.B.

CHICAGO

I. EDEMA OF THE BRAIN

The basis for the well recognized variability of the clinical manifestations accompanying fracture of the cranial bones is readily understood when the many possible alterations in the head resulting from this form of injury are considered. There is no single anatomic change in any instance responsible for the character and severity of the symptoms. The fracture is often simple, but is produced by a force which may tear blood vessels, compress the brain, injure the content of cranial foramina or open a path for infection from the outside. The bruises of the brain that are so commonly present may be absent, and still death may follow. Similarly, extradural, intra-arachnoid (subdural) and subarachnoid hemorrhages are inconstant. Death occurring shortly after injury is probably due in some instances to shock.

Edema has long been recognized as one of the changes which may, in the brain, follow trauma severe enough to fracture the cranial bones; but the interpretation of this change, its origin and its importance as a cause of the symptoms have not received the attention given almost all other sequelae.

Some writers [1] believe that edema of the brain occurs when intracranial tension is increased by a foreign body (such as large intracranial blood clots, depressed fractures, etc.) sufficiently to interfere with the cerebral circulation. Then the capillaries and veins are compressed and stasis of blood in the arteries and veins follows, with transudation of fluid into the brain tissue. Transudation, however, does not always immediately follow such embarrassment of the circulation; frequently a period of a day or two intervenes between the injury and its appearance. The importance of edema is that it may increase intracranial pressure and aid in producing the fatal anemia of cerebral compression.

---

* From the Department of Pathology, Rush Medical College.

* Aided by a grant from the American Medical Association.

1. Kocher, Theodor: Hirnerschutterung, Hirndruck und chirurgische Eingriffe bei Hirnkrankheiten, in Nothnagel: Specielle Pathologie und Therapie **5**:134, 1901. Von Bergmann and von Bruns: Von Bergmann in Handbuch der praktischen Chirurgie, Ed. 3, **1**:169-185, 1907.

Cannon[2] does not believe that fluid will pass from blood vessels into the brain tissue merely because blood pressure is increased; and he has emphasized that high blood pressure may be caused by increased tension in the brain tissue. He attributes the occurrence of edema to changes in osmotic pressure in the brain tissue, caused by contusion, the latter characterized by "diffuse formation of thrombi, punctate extravasations and thin patches of hemorrhage in the meninges"; and especially because the arteries are terminal vessels. He produced great swelling of the brain by passing physiologic sodium chlorid solution through the cerebral arteries of a cat, and concludes that edema of the brain substance is the result of alterations in the brain tissue, associated at times with a pressure many times greater than the blood pressure. He believes that the edema amply explains all the signs of intracranial tension often manifested by patients suffering from cerebral trauma.

Courtney[3] does not regard traumatic cerebral edema as a pathologic entity, but as part of a general condition that he terms "contusion," characterized by hyperemia, thrombosis and transudation. Relying on Obersteiner's demonstration of vasomotor nerves for the cerebral arteries, Courtney postulates that cerebral vascular paralysis may follow trauma as does splanchnic paralysis. Therefore, when the brain is injured and "contusion" occurs, the transudate, unabsorbed because of vasomotor paralysis, compresses contiguous regions progressively until cerebral and bulbar anemia results.

"Hirnschwellung," a condition in which the ratio that has been established between brain weight and cranial volume under normal conditions is disturbed, so that the weight of the brain exceeds the normal figure for a given cranial volume, is present in some instances of fracture of the cranial bones. Reichardt[4] believes that the pressure symptoms frequently noted after cerebral injury are due to such an alteration of that ratio. Although Reichardt, who first described "Hirnschwellung," could not find microscopic changes to explain the phenomenon, others[5] have described degenerative changes ("ameboid

---

2. Cannon, W. B.: Intracranial Pressure After Head Injuries, Boston M. & S. J. **145**:158, 1901.

3. Courtney, J. W.: Traumatic Cerebral Edema: Its Pathology and Surgical Treatment: A Critical Study, Boston M. & S. J. **140**:345, 373, 393, 1899.

4. Reichardt, M.: Bericht über Folgen der Hirnverletzungen, Deutsch. Ver. f. Psychiat., April, 1918; Deutsch. Ztschr. f. Nervenh. **28**: 1905; Berl. klin. Wchnschr. **55**:822, 1918.

5. Perusini: L'anatomia pathologica in Psichiatria, Riv. sper. di freniat. **35**: 1909. Alzheimer: Beitr. z. Kenntn. d. path. Neuroglia usw., Nissl-Alzheimer hist. u. histopath. Arbeiten **3**: 1911.

glia cells and cells with fibrinoid granules"). Reichardt [6] has expressed the belief that the underlying process is absorption of water by protoplasm and not a transudate outside the cells. Attempts to reproduce this condition in animals have so far failed.[7]

Some writers [8] explain edema of the brain by changes in the rate of secretion or absorption of cerebrospinal fluid. Rawling states:

> If as a result of some head injury, the intracranial venous pressure is considerably raised, so as to be well above the tension of the cerebrospinal fluid, the normal rate of absorption of cerebrospinal fluid will be impeded and it will collect in excess.

"Reactionary swelling" of the brain to trauma is another term applied to edema of the brain by some,[9] to explain the frequent presence of excess fluid in the cranial cavity and the clinical manifestations of cerebral compression in fracture of the cranial bones.

Encephalitis and edema of the brain, following cerebral trauma, are factors which may produce a vicious circle leading to venous hyperemia, and then more edema, until anemia of the brain results, according to Garrow.[10]

Rogers [11] believes that extradural or subdural hemorrhage is never alone adequate to explain death, but that the small hemorrhages accompanied by edema (produced by "irritation") cause intracranial pressure sufficient to destroy life.

The only common factor in the above mentioned opinions is that there is an increase of fluid in the cranial cavity in some instances after fracture of the cranial bones. There still remain questions regarding edema in general which are not answered, and until they are, any discussion of the factors involved in edema of the brain must of necessity be largely theoretical.

The production of cerebral edema in vivo, simulating closely the edema found after cerebral trauma, was accomplished by Weed and

---

6. Reichardt, M.: Ueber Hirnschwellung, quoted by Barbieri and Carbone: Biochem. Ztschr. **49**:293, 1913.

7. Barbieri and Carbone: Biochemische Studien über die Gehirnschwellung: (*a*) Die akute Schwellung des Gehirns und die kolloidale Lehre vom Odem, Biochem. Ztschr. **49**:293, 1913. Liesegang and Mahr: Hirnschwellung. Die Physik und Chemie der Hirnschwellung, Ergebn. d. Neurolog. u. Psychiat. **2**:157, 1912.

8. Rawling, L. B.: Cerebral Edema (Excess Cerebrospinal Fluid, Brit. M. J. **1**:499 (May 4) 1918. Hamilton, W. F.: Intracranial Pressure, Canad. M. A. J. **8**:873 (Oct.) 1918.

9. Trotter: Brit. J. S. **2**:520, 1915, quoted by Lobingier: Cerebral Edema in Intracranial Trauma, Calif. State M. J. **16**:303 (June) 1918.

10. Garrow, A. E.: The Surgical Relief of Increased Intracranial Pressure, Canad. M. A. J. **8**:882 (Oct.) 1918.

11. Rogers, C. C.: Intracranial Pressure, Surg., Gynec. & Obst. **30**:291 (March) 1920.

McKibben[12] and Renauld,[13] by intravenous injections of hypotonic solutions (water and 0.6 per cent. sodium chlorid solution, respectively).

The expression "edema of the brain" as used here represents a general edema of the brain substance and not the local edema about bruises, or edema ex vacuo, or serous meningitis, or pia-arachnoid edema or internal hydrocephalus. When edema is marked, at the postmortem examination, the drumlike tenseness of the dura after removal of the calvarium is conspicuous and commensurate with the degree of intracranial tension. After the dura is reflected from the top of the brain, the convolutions are found to be flattened; the peripheral ends of the sulci closed tightly; the small cerebral veins empty, and the larger branches near the superior longitudinal sinus sometimes filled and wedged tightly in the sulci. The minute pial arteries are almost, or quite, invisible; the surface of the visceral arachnoid layer is dry and by reflected light, scattered, almost microscopic droplets are seen that form when the viscid serous surfaces are separated. If there is no subarachnoid hemorrhage, the surface of the brain is light grayish-brown or the color of putty. When the brain is removed from the cranial cavity, it is found to be soft, and easily loses its form if laid on a flat surface. After the brain is hardened in liquor formaldehydi for several days, the following changes are noted: an increased difficulty in cutting, closure of the lateral ventricles, and the absence of the stippling of the brain substance by the small intracerebral blood vessels—a condition also usually present with anemia from whatsoever cause. Microscopically, the perivascular lymph sheaths are distended; and there are empty spaces between fibers and cells, the latter farther apart than normally. Changes in the cells are sometimes absent. In many brains, there are also the various types of bruises of the brain, leptomeningeal hemorrhage and compressed regions from large extradural or intra-arachnoid blood clots. When Weed and McKibben,[12] as mentioned, produced these changes, they also found them absent if the skulls were first trephined so the brain might expand.

Believing that information as to the water content would aid in explaining the rôle of the edema accompanying cerebral injury, determinations of the percentage of water were made of the brains from the bodies of twenty-six persons who died of linear fractures of the cranial bones and associated brain injuries.[14] (See Tables 4 and 5.)

The head of the body was opened before the trunk so as to prevent drainage of fluid from the head to the trunk and thus maintain pressure relations

12. Weed, L. H., and McKibben, P. S.: Experimental Alteration of Brain Bulk, Am. J. Physiol. **48**:531 (May) 1919.

13. Renauld, quoted by Liesegang and Mahr: Footnote 7, second reference.

14. Necropsies, medicolegal, by Dr. E. R. LeCount.

in the cranial cavity more nearly like those existing during life. The brain was removed from the cranial cavity and placed in a dry calvarium and weighed. The thin meninges were then removed from the tops of the parietal lobes; brain tissue was cut out and placed in weighed glass-stoppered weighing bottles, and weighed immediately; the material was then removed quantitatively to a beaker and kept in redistilled 95 per cent. alcohol until used.

The method employed to determine the water content is essentially that devised by Waldemar Koch,[15] modified by Mathilde L. Koch,[16] and followed by McKenzie and LeCount[17] in the study of edema of the brain following heat stroke.

The brain tissue is cut into small pieces, transferred to a dried, weighed extraction thimble and extracted in a Soxhlet apparatus for from six to twelve hours with redistilled 95 per cent. alcohol, and from six to eight hours with redistilled ether. After the ether evaporates, the dry white porous tissue is ground to powder in a glass mortar, transferred to a beaker, and digested with hot distilled water on an electric plate for fifteen minutes. The water is decanted into another beaker, and similar water digestions repeated three times. The water extracts are evaporated to about 25 c.c.; redistilled 95 per cent. alcohol is added to precipitate the water soluble proteins, and the solids are again transferred to the extraction thimble to be extracted in the Soxhlet apparatus for from twelve to eighteen hours with redistilled 95 per cent. alcohol. The alcohol, ether and water extracts and filtrates are evaporated together and dried to constant weight in a vacuum desiccator. The residue and the extraction cup are dried in an oven at 105 C. to constant weight. The sum of the weights of the dried extracts, filtrates and residue gives the weight of the solids, and subtraction of this sum from the weight of the fresh tissue gives the weight of the moisture.

Even this method does not furnish an exact measure of the water content of brains from bodies in which increased intracranial tension existed before death, for these reasons:

1. The fall of blood pressure and the passage of blood from the head to the trunk after death decrease the intracranial tension and may permit some fluid to escape from the brain tissue into the leptomeningeal spaces and even into the spinal canal.

2. When the skull-cap and dura are removed, intracranial tension is reduced; the tension on the fluid in the brain is reduced, and frequently fluid drips from the brain while the latter is being removed from the cranial cavity.

---

15. Koch, Waldemar: J. Am. Chem. Soc. **31**:1340, 1909.

16. Koch, M. L., and Voegtlin, C.: Chemical Changes in the Central Nervous System in Pellagra, Bull. 103, Hyg. Lab., U. S. Public Health Service, Washington, D. C., 1916, p. 67.

17. McKenzie, P., and LeCount, E. R.: Heat Stroke with a Second Study of Cerebral Edema, J. A. M. A. **71**:260 (July 27) 1918.

3. When the leptomeninges are removed before cutting out brain tissue for weighing, fluid wells up into the sulci and frequently half fills them in the few seconds required to excise sufficient tissue.

The increase of water found by this method, therefore, represents simply some part of the actual increase of moisture in the brain that existed before death. When intracranial tension is not increased, the chance for loss of water is not so great and the determinations are more nearly correct. The smaller amount of increase found in the analyses when gray matter predominated (Table 5) may be due to the proximity of this tissue to the surface of the brain where the fluid may more easily escape.

There are several other factors entering into the analyses that may interfere with the use of the results obtained in arriving at definite conclusions as to the actual increase of fluid in the brain substance:

1. The normal water content of the whole cerebrum and of some of its components has been computed by several investigators; and it is readily understood that similar parts of the brain must be used in each analysis, and that the normal water content of such pieces must be determined for control purposes (Table 1).

TABLE 1.—NORMAL WATER CONTENT OF THE WHOLE CEREBRUM AND OF SOME OF ITS COMPONENTS

Investigator	Cerebrum, Per Cent.	White Matter, Per Cent.	Gray Matter, Per Cent.
Baumstark (Arch. f. d. ges. Physiol, Vol. 7)	.....	69.53	76.99
Bernardt (quoted by Halliburton)	.....	70.00	85.00
Petrowsky (quoted by Halliburton)	.....	68.00	81.00
DeRegibus (quoted by Halliburton)	.....	70.00	86.00
Charles (quoted by Halliburton)	81.00	.....	.....
Koch and Voegtlin [16]	76.90	.....	.....
Thudichum [7] (Die chemische Constitution des Gehirns, Tübingen, 1901)	.....	70.20	85.20
Halliburton (Chemical Physiology and Pathology, London, 1891, p. 517)	.....	70.00	83.50
Hammarsten (quoted by McKenzie and Lecount [17])	76.3	.....	.....

2. The water content of the brain decreases from infancy to old age. Rosenheim [18] found the water content, in percentage, to be 78.86 for man, 85.8 for a child of 3 months, 89.99 for a child of 5 days, and 90.29 for a fetus of 36 weeks.

3. In albino rats it has been found that the water content of the brain increases after death.[19] When death was due to pneumonia, there was from 0.7 to 0.8 per cent. more water in the brains of animals

18. Rosenheim: Purification of Kerasin and Phrenosin, Biochem. J. **8**:110, 1914, quoted by Mathews, A. P.: Physiological Chemistry, Ed. 1, 1915, p. 579.

19. King, H. D.: The Effects of Pneumonia and of Postmortem Changes on the Percentage of Water in the Brain of the Albino Rat, J. Comp. Neurol. **21**:147-154, 1911.

dead for eight or nine hours than there was in other animals examined immediately after death, other conditions being quite similar as regards age and breed.

4. After adult life is reached, the water content of brains of individuals of the same age is not the same, because atrophy is more marked in some (because of arterioscleriosis, alcoholism, etc.). Therefore, edema of some degree may be present in such a brain with atrophy and still the brain may not show by actual measurement any more water than normally present, or at the most a slight increase.

5. Murachi [20] found in experiments on swelling of the brain substance that the gray and white matters swell differently.

To decrease the errors that might result because of these factors, the water content of control brains was determined. In the first series, a piece of brain was removed from the upper surface of each cerebral hemisphere close to the motor region, cone shaped, the base being from 4 to 5 cm. in diameter and from 5 to 6 cm. deep. In such pieces, the white matter predominates. Four brains were examined with the results given in Table 2.

TABLE 2.—WATER CONTENT OF CONTROL BRAINS FOR SERIES 1

Case No.	Percentage of Water	Weight of Brain Tissue Used in Grams	Patient in Hospital	Time Elapsed Between Injury and Entrance	Time Elapsed Between Death and Necropsy	Age in Years	Cause of Death
21	75.83	95.6258	4 hours 25 min.	2 to 3 hrs.	10 hours	27	Bullet wounds; hemothorax, 1,795 gm. of blood*
28	75.23	97.6866	7 hours 45 min.	2 hours	14 hours	35	Bullet wounds; hemothorax
29	74.36	79.8297	Found dead	.....	Unknown	20	Bullet wounds; hemopericardium
30	75.44	129.9406	20 min.	Unknown	21 hours	45	Bullet wounds; hemothorax

* Difficulty was encountered in finding brains which could be used as controls because the water content of brains is disturbed by many causes of death. With general acute anemia, edema of the brain is present; but as the analyses show, the edema is minimal.

The normal water content for the pieces of brain used in Series 1 is near 75.5 per cent. Allowing for changes due to absorption of water after death and the variation due to age and preexisting diseases, an actual increase of water is considered to be present when the analysis indicates that the percentage of water is above 76 per cent.

In the second series, a thin piece was removed from the upper surface of each hemisphere, the thickest portion measuring not more than 1 cm. Gray matter predominates in these pieces. The material used by MacKenzie and LeCount [17] was of similar parts of the brain;

20. Murachi, N.: Ueber die titrierbare Azidität und die Quellungsfähigkeit des urämischen Gehirns, Arb. a. d. neurol. Inst. a. d. Wien. Univ. **10**:327, 1912.

and the two analyses of control brains which I made agree with their results for the normal brain. In this series, 80 per cent. of water is used as the highest limit for normal brains.

These figures for normal brains take into account absorption of water that may occur after death, since the bodies of both the control and skull fracture groups were kept in approximately the same conditions, and both contain instances in which the bodies were examined as long as twenty-four hours after death.

TABLE 3.—WATER CONTENT OF CONTROL BRAINS FOR SERIES 2

Case No.	Percentage of Water	Weight of Brain Tissue Used in Grams	Patient in Hospital	Time Elapsed Between Injury and Entrance	Time Elapsed Between Death and Necropsy	Age in Years	Cause of Death
31	79.80	95.5795	Found dead	.....	Unknown	21	Bullet wounds
32	79.35	75.9051	25 min.	2 hours	24 hours	40	Bullet wounds

TABLE 4.—RESULTS AND CONDITIONS CONNECTED WITH EXAMINATIONS OF BRAINS IN SERIES 1 (SKULL FRACTURES)

No.	Percentage of Water	Estimated Increase of Water in Percentage	Weight of Brain	Estimated Increase of Water in Whole Brain	Patient in Hospital	Hours Elapsed Between Injury and Entrance	Hours Elapsed Between Death and Necropsy	Age
5	75.01	0	1,136	0	8 days	Few hours	3 hours	39
6	79.35	3.35	1,345	45.05	8 hours	4 hours	19.5 hours	30
7	78.04	2.04	1,326	27.05	37 hours	5 hours	9 hours	50
8	75.40	0	1,375	0	1.5 hours	Few hours	24 hours	53
9	78.30	2.30	1,266	29.12	11 days	Few hours	7 hours	40
10	75.16	0	1,339	0	29 hours	7 days	24 hours	44
11	75.85	0	1,255	0	33 hours	1 hour	12 hours	28
12	77.77	1.77	1,455	25.75	1 hour	5 to 7 hours	12 hours	55
13	75.22	0	1,289	0	1 hour	Unknown	22 hours	42
14	76.90	0.90	1,368	12 31	2 days	1 hour	6 hours	33
15	76.97	0.90	1,280	11.52	8 hours	Unknown	6 hours	30
16	79.70	3.70	1,102	40.77	50 hours	1 day	4 hours	2
19	77.50	1.50	1,733	25.99	50.5 hours	Unknown	16.5 hours	35
					36 hours			
					17 hours			

In Table 4, the results and some of the conditions connected with the examinations of the brains in Series 1 are listed, and in Table 5 those of Series 2.

COMMENT

The actual increase of water for the entire brain when edema is present varies between 3 and 45 gm. Many attempts have been made to determine the volume of a foreign body that will produce symptoms or death when in the cranial cavity. Deucher[21] injected masses of paraffin into the cranial cavity of animals and found that when 6 per

21. Deucher: Ueber Hirndruck, Deutsch. Ztschr. f. Chir. **36**:145, 1893.

cent. of the brain volume was introduced no changes occurred; but with 10.1 per cent., there was slowing of the pulse and respiration. Schulten[22] believes that in man there may be from 40 to 90 c.c. decrease of intracranial space by extradural hemorrhages and no symptoms necessarily follow. Sixty-eight c.c. of free blood between the dura and the cranial bones have produced moderate stupor and slowing of the pulse; and 116 c.c. have produced marked symptoms of intracranial pressure with coma. Schulten also states that 130 c.c. of free blood in the subdural space may produce no symptoms, while 250 c.c. soon produces death. Cushing[23] states that unless some specialized centers are compromised by a compressing force, the cranial cavity may harbor a foreign body from one-eighth to one-tenth the size of the

TABLE 5.—Results and Conditions Connected with Examinations of Brains in Series 2 (Skull Fractures)

No.	Percentage of Water	Estimated Increase of Water in Percentage	Weight of Brain	Estimated Increase of Water in Whole Brain	Patient in Hospital	Hours Elapsed Between Injury and Entrance	Hours Elapsed Between Death and Necropsy	Age
1	78.74	0	1,562	0	8 hours	Unknown	12	45
2	80.9	0.9	1,327	11.94	30 hours	Unknown	20	60
3	79.0	0	1,348	0	1.40 hours	3 or 4	16	33
4	82.20	2.20	1,350	29.70	3.30 hours	10 ?	13	14
17	78.29	0	1,509	0	48 hours	Unknown	8.30	30
18	81.48	1.48	1,319	19.52	26 hours	3 or 4	20	67
20	79.39	0	1,579	0	10 hours	Few hours	5	35
22	79.30	0	1,377	0	20 hours	Unknown	9	45
23	80.71	0.71	1,295	9.19	2 hours	Unknown	14	65
24	81.86	1.86	1,333	24.79	21 hours	Unknown	4	60
25	81.01	1.01	1,391	14.04	52 hours	3 or 4	10	7
26	81.62	1.62	1,341	21.72	9 hours	2 hours	5	40
27	80.22	0.22	1,336	2.93	5 days	3 hours	16	70

brain, without the major symptoms of compression appearing. Pagenstecher[24] did not find general symptoms of compression when 6.5 per cent. of the cranial cavity was occupied by a foreign body; but with 8.1 per cent., coma and sudden death occurred.

The variance in the figures quoted is dependent on the unequal vulnerability of the various parts of the brain to pressure. Breslauer[25] produced unconsciousness in dogs by the injection of 2 c.c. of physiologic sodium chlorid solution in the subarachnoid space at the base of

22. Schulten: Arch. f. klin. Chir. **32**:433, 455, 947, 1885, quoted by Kocher: Footnote 1.

23. Cushing: Some Experimental and Clinical Observations Concerning States of Increased Intracranial Tension, Am. J. M. Sc. **124**:375-400, 1902.

24. Pagenstecher, quoted by Kocher: Footnote 1.

25. Breslauer: Zur Frage des Hirndrucks, I. Ueber akuten Hirndruck, Arch. f. Clin. Chir. **103**:478-496, 1914.

the brain, while Duret [26] was able to inject 18 c.c. of a similar solution before symptoms appeared.

Even though the actual increase of water in some of the brains examined would appear to be insufficient to produce symptoms when compared to the figures quoted above, the tenseness of the dura, after the removal of the calvarium and the absence of other foreign bodies (such as clots, etc.), suggest that edema is the cause of the increased intracranial tension. The experiments of Weed and McKibben [12] indicate that edema alone causes swelling of the brain sufficient to produce protrusion of the brain through trephine holes and cerebral hernia. Positive proof that edema plays a rôle in the production of symptoms of intracranial pressure in fractures of the cranial bones may be obtained by surgeons from clinical observations. If edema does cause symptoms of intracranial pressure, then they should usually appear several hours after the injury and increase up to the end of the second or third day, and then diminish unless death ensues. If other causes for increased intracranial tension (such as extradural and subdural clots) are absent or of minimal extent, it may well be concluded that edema may produce the symptoms of intracranial tension. Reichardt [6] and others have suggested that the increase of the volume of the brain may be due to a colloid-chemical phenomenon, based on the work of Fischer [27] and others,[28] and this may explain the marked swelling in the presence of a relatively small increase of the water content of traumatized brains.

CONCLUSIONS

1. Edema of the brain occurs frequently with fractures of the cranial bones.

2. Edema was most frequently found in the brains of persons who died between several hours after the accident and the second or third day; it was usually absent when death occurred during the first few hours or three or more days after the injury.

3. It is not yet known whether edema of the brain plays an important part in producing symptoms and death in fractures of the cranial bones, or whether it is merely a terminal pathologic condition dependent on changes in the brain tissue, physical or chemical, that are the essential lesions of traumatized brains.

---

26. Duret: Etudes experimentales et cliniques sur les traumatismes cerebraux, Paris, 1878.

27. Fischer, M. H.: Oedema and Nephritis, New York, John Wiley & Sons, Ed. 3, 1921, p. 731.

28. Barbieri and Carbone; Liesegang and Mahr: Footnote 7.

II. BRUISES OF THE BRAIN

The examination of the hardened brains used in the analysis for water content revealed some characteristics of bruises of the brain and traumatic leptomeningeal hemorrhage that have not been given careful consideration in the literature that I have reviewed.

In a previous report [29] in which were described the bruises in the brains of 504 persons who died with fracture of the cranial bones, a classification of bruises was made to bring out the *extent* of the cerebral destruction. In about 10 per cent. of the 504 brains, there were deep lacerations, the leptomeninges were torn widely open, and the brain was destroyed for from 2 to 4 cm. deep, and in areas of from 4 to 6 cm. The remainder of the bruises varied from wedge-shaped regions from 2 to 4 cm. deep, the leptomeninges covering them being torn sometimes, and the brain tissue being infiltrated with blood and superficially destroyed, to smaller bruises frequently consisting merely of petechial hemorrhages of the cortex. After careful consideration of the bruises in the twenty-six brains studied in this series, still another classification of bruises presented itself. In the first class are those which result from laceration of the brain tissue at the time that the cranial bones are fractured, and in the second, a much larger group, bruises which are caused by hemorrhage from torn pial arteries at, or near, the junction of the white and gray matter. It is with the second class that this discussion is chiefly concerned.

When a hardened brain from the body of a person dying with fracture of the cranial bones is examined, the first thing usually noticed is free blood in the leptomeninges, sometimes thick enough to hide the convolutions of the brain and sometimes only enough to make the sulci brown. But common to all is the patchy distribution of the blood and the presence of the blood chiefly in the leptomeninges of the front half of the top of the brain, while at the base the surface and the margins of the bruises are covered with blood. Traumatic intraleptomeningeal hemorrhage does occur without grossly visible bruises of the brain; but much more commonly it results from cerebral injury. In view of the fact that the base of the brain is frequently injured, while the upper surface is injured infrequently, there must be distinct anatomic or physiologic conditions to explain this phenomenon. A fact that does not agree with the explanation that the leptomeningeal hemorrhage is the result of trauma to the thin meninges of the top of the brain is that the blood can usually be traced to bruises of the under surface or sides of the brain, being thickest near the bruises and gradually thinning

29. LeCount, E. R., and Apfelbach, C. W.: Pathologic Anatomy of Traumatic Fractures of Cranial Bones and Concomitant Brain Injuries, J. A. M. A. **74**:501-511 (Feb. 21) 1920.

out toward the top of the brain. Still another explanation may rest in the flow of the cerebrospinal fluid from the base toward the pacchionian bodies, which would carry the blood with it to the top of the brain. During the removal of the leptomeninges of the brain in order to determine the exact amount of bruising of the outside of the brain, it was found that the leptomeninges of the top and sides of the front of the brain are easily stripped from the surface and out of the sulci; whereas at the base, only small pieces can be removed because of the tightness with which the membranes hug the surface of the brain. Inasmuch as bleeding follows the lines of least resistance, I believe that it is the latter factor that determines the spread of the

Fig. 1.—Posterior surface of a coronal segment of the cerebrum at the level of the anterior horns of the lateral ventricles: *a* and c indicate two bruises, the centers near the junction of the gray and white matter; the outside of the brain at *c* grossly is unchanged, while at *a* it is unchanged except for grayish-black discoloration. At *b* is a large bruise entirely inside the brain since there is a thin strip of gray matter at the surface. At *d* is a bruise, all in the gray matter and extending to the surface, for here there is shallow excavation, the surface honeycombed and mottled brown and gray.

blood to the top of the brain instead of into the tightly adherent leptomeninges of the base.

When the surface of the brain is examined after the leptomeninges are removed, many signs of injury are found that cannot be seen with the membranes still in place. Often when the leptomeninges are not torn and only leptomeningeal hemorrhage is seen, multiple small bruises

can be found. Aside from the larger lacerations already excluded from this description, the surface appearance of the injuries is as follows:

The minimal changes consist of gray-black discolorations of the surface, from 1 to 10 mm. in their greatest dimension. They are located a variable distance centrifugally from the largest bruises. A little more extensive, and the most frequent, type of injury is defects (Fig. 3, *c* and *b*) of the most prominent parts of the convolutions, from 1 to 4 or 5 mm. deep and from 1 to 10 mm. in the greatest surface dimension, round, oval or irregular in outline, the base being granular,

Fig. 2.—Anterior surface of a coronal segment from the left cerebral hemisphere about 5 cm. posterior to the frontal pole. At *b* and *c* are two bruises, 1 cm. from the under surface of the brain, with intact brain tissue intervening. They are both at the central end of a sulcus and near the junction of the gray and white matter. At *a* is a defect in the under surface filled by a blood clot, and there was a sulcus in the center of the clot; the defect probably resulted from bleeding which occurred from a lesion similar to those at *b* and *c*. At *d* is a laceration of the brain with additional destruction by bleeding from torn blood vessels in the surrounding brain tissue. The accumulation of blood in the leptomeninges and tearing from distention are illustrated at *e*.

discolored a light brown to gray-black, and made up of numerous, small, semispherical depressions at the bottoms of which there are frequently minute hemorrhages. The margins are slightly scalloped,

sharply demarcated, the surrounding tissue for from 1 to 3 or 4 mm. discolored a light brown to gray. Still more extensive injuries, resulting from hemorrhage, are defects (Figs. 2 *a* and 4 *a*) filled with clotted blood, from 5 to 15 mm. in diameter, the surrounding tissue intact or discolored a light brown to gray, or superficially absent, as in the second type described.

In surfaces made by sectioning the brain in the usual way, at the regions of discoloration of the outside of the brain, hemorrhages are present, from 1 to 20 mm. in diameter, separated from the surface of the brain by a layer of gray matter from 1 to 2 or 3 mm. thick. Fre-

Fig. 3.—Posterior surface of a coronal segment of the left cerebral hemisphere, 4 cm. posterior to the frontal pole. Multiple hemorrhages are present in the under surface at, or near, the junction of the gray and white matter. At *a* beginning extension of bleeding from a hemorrhage is seen. At *b* the blood has already reached the surface and produced here a round, black, slightly honeycombed depression. At *c*, there is a saucer-shaped excavation, the surface honeycombed, mottled black and gray, the black spots representing the hemorrhages present in the gray matter. Smaller hemorrhages are seen with extension toward the surface in thin streaks, probably along perivascular sheaths.

quently, hemorrhages are found at the junction of the gray and white matter without any gross changes of the surface of the brain opposite them (Figs. 1 *c* and 3 *a*).

Surfaces through the bruises of the second type show small or large hemorrhages at, or near, the junction of the white and gray matter, immediately above the base of the defects. Occasionally, no hemor-

rhages are present here, and it may be assumed that the bleeding had carried with it all the brain tissue immediately peripheral to the innermost level of the hemorrhage (Figs. 3 *c* and 4 *a*).

Surfaces through the larger bruises show defects from 1 to 2 cm. deep, filled with clotted blood, the margins of which are discolored, and in the surrounding brain tissue are multiple petechial hemorrhages or simply discoloration. In the latter instance, if the clotted blood is removed, nothing more is seen than in the superficial contusions, as if

Fig. 4.—Posterior surface of a coronal segment from the left cerebral hemisphere near the anterior horn of the lateral ventricle. At *a*, in the surface, there is a round, black blood clot, 5 mm. in diameter, and about it for from 5 to 7 mm. multiple smaller black regions. A sulcus extended into the brain here. There are also multiple small hemorrhages at, or near, the junction of the gray and white matter, many of which extend into the excavation, but not shown here, because they are seen on the external surface. At *b* is a small hemorrhage beginning at the junction of the gray and white matter and extending to the surface. Other smaller, round and linear hemorrhages in the gray matter are also present.

a hemorrhage had occurred as indicated in Figure 1 *a* and *b*, and then broken through to the outside, leaving merely a cavity. In Figure 2, *a* and *d* indicate two typical bruises of this type.

I believe that these three types of bruise are merely stages of one process. In many instances of fracture of the cranial bones, the force is not sufficient to lacerate the brain, but only sufficient to tear the small arteries in the cortex, chiefly at the junction of the gray and white matter. Bleeding then occurs, and, depending on the size of the vessel torn and of the rent, a small hemorrhage results, or bleeding continues and the blood infiltrates the gray matter, reaches the surface of the brain and breaks through into the leptomeninges. The explanation for the predilection of the region of the junction of the gray and white matter for the greatest injury may rest on anatomic features. Perhaps the thin meninges with the thin layer of fluid in them serve as a cushion for the surface of the brain sufficient to prevent injury to the outside, while the force as it is transmitted through the brain from a medium of lesser density (gray matter) to one of greater density (white matter) or vice versa, produces the greatest commotion at, or near, the junction.

Lacerations of the leptomeninges are another type of lesion which may depend on hemorrhage instead of on injury at the time of fracture of the cranial bones. In some instances, when these are present, the injury to the brain is only moderate as in Figure 2 *e;* but usually, there is a thick layer of blood in the leptomeninges. These lacerations of the leptomeninges are usually of the base. Perhaps the tensile strength of the thin meninges is less than the strength of the fibrous bands holding the membranes to the surface of the brain, so that when bleeding occurs from bruises of the brain, the blood, instead of spreading in the leptomeninges, ruptures them and runs into the intra-arachnoid space (subdural). This receives some support from the frequency of lacerations of the base and of the sides near the base where the leptomeninges are tightly adherent to the surface, and their infrequency at the top of the brain where they are less adherent and spread of blood in them occurs more readily.

The question may be asked why the bleeding from torn vessels at, or near, the junction of the gray and white matter is toward the outside of the brain instead of into the white matter. Again it may be stated, that bleeding follows the lines of least resistance. The cortex is softer than the white matter, owing to the preponderance of cellular tissue, so that the blood more easily spreads through this layer than through the white matter.

Another characteristic of brain bruises worthy of mention is that frequently in brains of people who die shortly after injury the bruises are superficial; whereas if life continues for one or two days, or more, larger bruises are found. This may be due to bleeding persisting for one or two days after the injury before it ceases, in this way giving the bruises a chance to enlarge.

CONCLUSIONS

1. Aside from the severe lacerations of the brain that occur at the time of injury, most bruises of the brain result from bleeding due to rupture of the pial arteries at, or near, the junction of the white and gray matter.

2. The leptomeninges with the cerebrospinal fluid in them protect the surface of the brain from injury in many instances, and the force is expended at, or near, the junction of the white and gray matter because of difference in density of these tissues.

3. Traumatic leptomeningeal hemorrhage is most frequent at the top of the brain because the thin meninges are less firmly adherent to the brain, and the spaces between the visceral layer of the arachnoid and pia are larger than at the base of the brain.

4. Lacerations of the leptomeninges of the base of the brain are caused both by trauma at the time of fracture of the cranial bones and by subsequent bleeding into them from cerebral injuries.

TECHNIC OF THE TREATMENT OF CARCINOMA OF THE BLADDER AND PROSTATE BY A COMBINATION OF SURGERY, ELECTROCOAGULATION, RADIUM IMPLANTATION AND ROENTGEN RAY*

B. A. THOMAS, A.M., M.D.
Professor of Urology, Graduate School of Medicine of the University of Pennsylvania; Genito-Urinary Surgeon to the Presbyterian Hospital

AND

G. E. PFAHLER, M.D.
Professor of Radiology, Graduate School of Medicine of the University of Pennsylvania

PHILADELPHIA

Although one [1] of us (G. E. P.), in 1914, recommended, after an experience of two years, the treatment of malignant disease, particularly of the mouth, by the combination of surgery, electrothermic coagulation, roentgen rays and radium, it is true that a similar, though perhaps less efficient procedure, comprising cystotomy, electrocautery removal, application of radium *en bloc* and roentgen-ray cross-fire was actually employed by the other [2] (B. A. T.) in the same year in a patient with carcinoma of the bladder, who today is without symptoms and has never experienced any evidence of recurrence. Since the advent of the practice of using multiple small doses of radium in needle form (emanations or element), an important stride has been taken, better results achieved, and the popularity of radiotherapy greatly extended. This practice, together with the superiority of electrocoagulation over the electrocautery for the removal of the tumor mass, prompted us last year, in a paper before this section, to emphasize the empiric value of this combination of therapeutic measures in certain definite types of bladder carcinoma. It is our intention now to give in detail the precise technic employed in the management of these unfortunate cases of bladder and prostatic carcinoma.

It is of the utmost importance to appreciate fully that the treatment about to be described should be reserved for, and only applied to, certain types of carcinoma of the bladder or prostate, as defined in a

---

* Read before the Section on Urology at the Seventy-Second Annual Session of the American Medical Association, Boston, June, 1921.

1. Pfahler, G. E.: Electrothermic Coagulation and Roentgen Therapy in the Treatment of Malignant Disease, Surg., Gynec. & Obst. **19**:783 (Dec.) 1914.

2. Thomas, B. A.: Technic of Operative Treatment of Bladder Tumors, Surg., Gynec. & Obst. **21**:133-150 (Aug.) 1915.

previous paper, namely, those commonly regarded as inoperable, in which the growth is so extensive as to preclude the advisability of resection of the bladder, with or without transplantation of the ureter, or in which the vesical orifice has become involved to the extent that nothing short of total cystectomy, a procedure seldom applicable, would suffice to remove all the obviously diseased tissue, or in which the general condition of the patient will not warrant too radical or prolonged surgical intervention. Under no circumstances should this method of treatment be applied to those cases of carcinoma of such a nature and so situated that resection is possible, with or without ureteral reimplantation or transplantation, either extraperitoneally or transperitoneally; nor should it be employed on those surgical derelicts, who through personal neglect or ignorance and unscrupulous advice or procrastination, have reached the stage in the progress of disease when any aid, other than possible cystostomy for urinary deviation, avails naught. Relative to malignant disease of the prostate, the same general thought pertains; namely, radical surgical extracapsular perineal prostatectomy, if possible; otherwise, if the disease is not too extensive and no metastases have occurred, the therapeutic procedures here detailed and applied suprapubically, by cystotomy, after an interval of from two to four weeks, or after perineal exposure of the gland. The methods promise results far better than have been obtained in the past by other lines of treatment.

Realizing, first, the number of cases of vesical carcinoma not amenable to the formidable operation of partial cystectomy; secondly, the high hospital death-rate following total cystectomy associated with bilateral nephrotomy or ureteral transplantation, thirdly, the miserable existence accorded patients by a mere cystostomy for drainage; fourthly, the unsatisfactory results following either electrocoagulation or radium or roentgen ray separately, and, fifthly, the hopelessness of doing nothing at all, surgically, we have been prompted to combine four of the most effective therapeutic measures to combat malignant disease of this type.

TECHNIC

Attention to the preliminary preparation of the patient and his credentials for qualification for these operative procedures, so far as organic disease, especially kidney damage, is concerned, is just as obligatory as in cystotomy for any indication, notably prostatectomy. However, neither the operative shock nor mortality seems to be so great as in resection of the bladder or prostatectomy. Therefore, in view of the unpardonable sin of procrastination in malignancy, cystotomy, even under local anesthesia, to effect better drainage and more speedy decompression of the kidneys than can be obtained by the catheter

à demeure, may be required as a preliminary step, although it is eminently desirable, if at all possible, to complete the entire procedure, electrocoagulation and radium implantation, at one time under general, or, rarely, spinal anesthesia.

The patient is placed in the recumbent position prepared for the Trendelenburg, if desired later, with thighs abducted, knees partially flexed, feet together and strapped in position (Fig. 1). The bladder is irrigated and filled by means of a catheter with from 10 to 12 ounces of a solution of silver nitrate 1 : 6,000. A clamp is applied to the catheter distal to the glans penis, and a tourniquet is placed around the body of

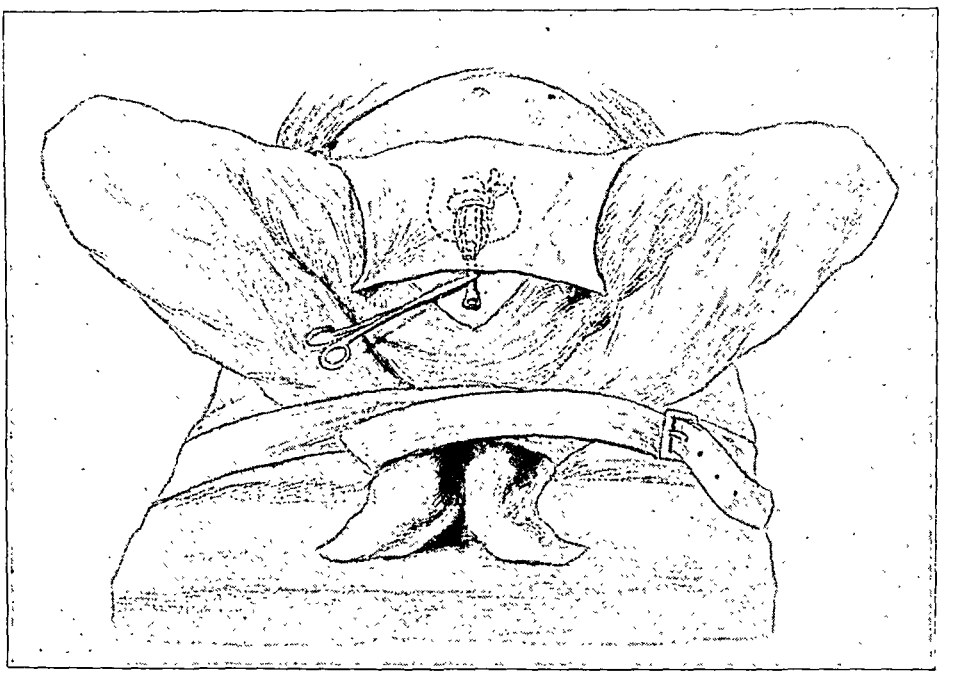

Fig. 1.—Position of patient for suprapubic cystotomy, with a sterile towel covering the genitalia, and at the same time permitting easy access to, and release of the catheter clamp, tourniquet to penis and removal of catheter after bladder is exposed and grasped.

the penis to prevent escape of the solution from the bladder. This position of the lower extremities, described by Peterkin, with the external genitalia draped with a sterile towel, readily permits the release of the catheter clamp, the escape of the solution in the bladder and the removal of the catheter, without the slightest disturbance of the patient's position, after the bladder has been exposed and fixed, just prior to incision. Also the position is desirable in the event of the introduction of a finger into the rectum to elevate the trigon or prostate.

After the usual iodin preparation of the skin, a vertical median incision is made and the bladder opened well up on the anterior wall (Fig. 2), after permitting the escape through the catheter of the silver nitrate solution from the bladder. The freshly cut edges of the wound are protected by sterile towels, and the carcinomatous mass in the bladder is exposed, using special retractors (individual are superior to

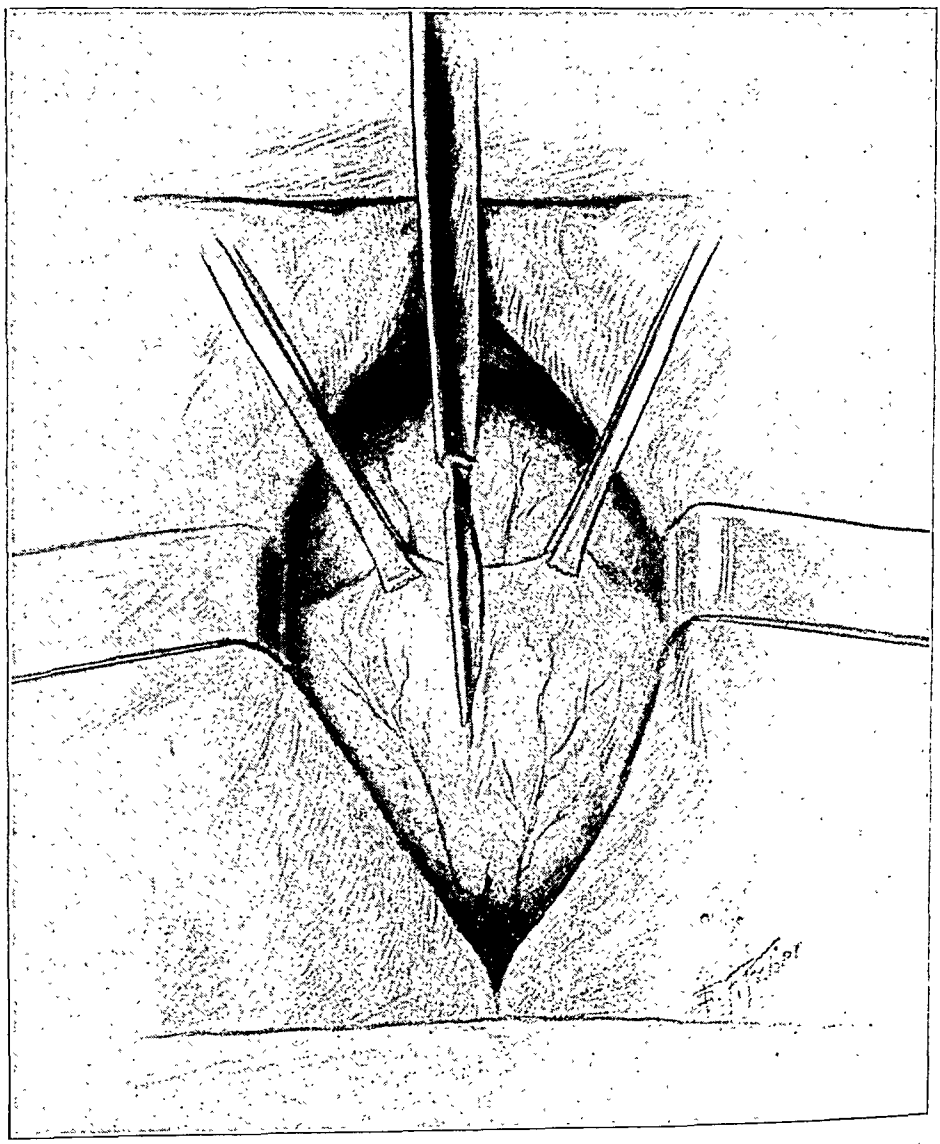

Fig. 2.—Edges of incision through skin, fat, fascia and muscle protected by sterile pads; bladder grasped by Allis' forceps and incised as high up on fundus as possible.

self retaining) (Fig. 3), and the process of electrocoagulation begun. A large pad electrode (Fig. 4, *A*), measuring 6 by 8 inches is placed under the buttocks of the patient, and in direct contact with the skin.

The wire connected with this electrode must be firmly attached so that it cannot separate and make a ground with the operating table. Otherwise the current is likely to leak out to the table at some point of contact and produce a burn of the tissues in some healthy part of the body. The wire connecting this electrode should further be covered by rubber tubing (Fig. 4, *C*), so that there is no opportunity during the

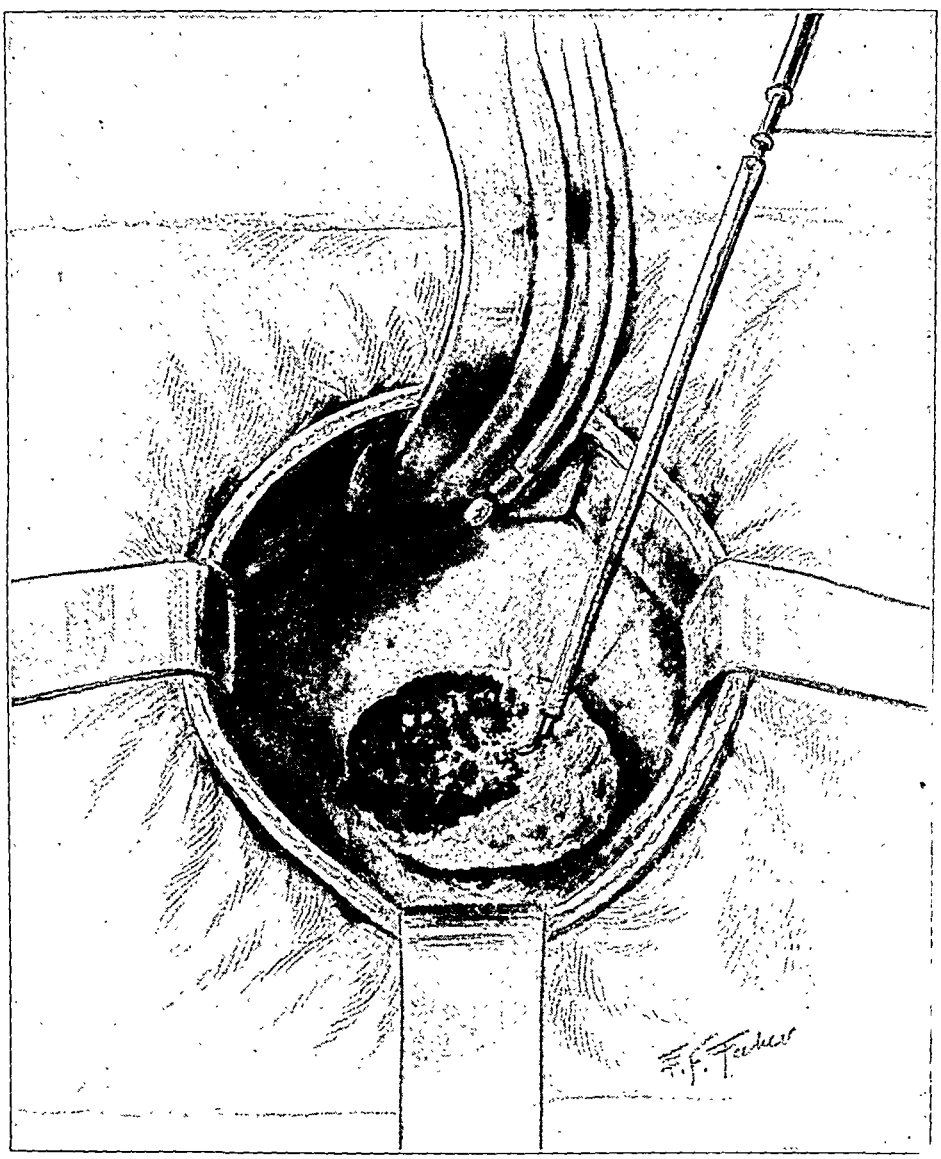

Fig. 3.—Bladder retracted, displaying carcinoma in process of destruction by electrocoagulation. The degree of heat generated in the bed of the tumor is very great and persists after treatment for a few minutes; it cannot be tolerated by the gloved palpating finger even for a few seconds, and doubtless is much more penetrating and effective than the electrocautery.

operation for the current to leap from the wire to the table. This wire, attached to the indifferent electrode or pad, is then attached to one side of the d'Arsonval instrument. The other pole of the d'Arsonval is attached to the active electrode (Fig. 4, *B*). It must be borne in mind that the d'Arsonval current is an oscillating current, and, therefore, when we speak of the poles, it must not be thought that either one of these is positive or negative, for they are alternately positive and negative, and the alternations or oscillations occur from 100,000 to a million

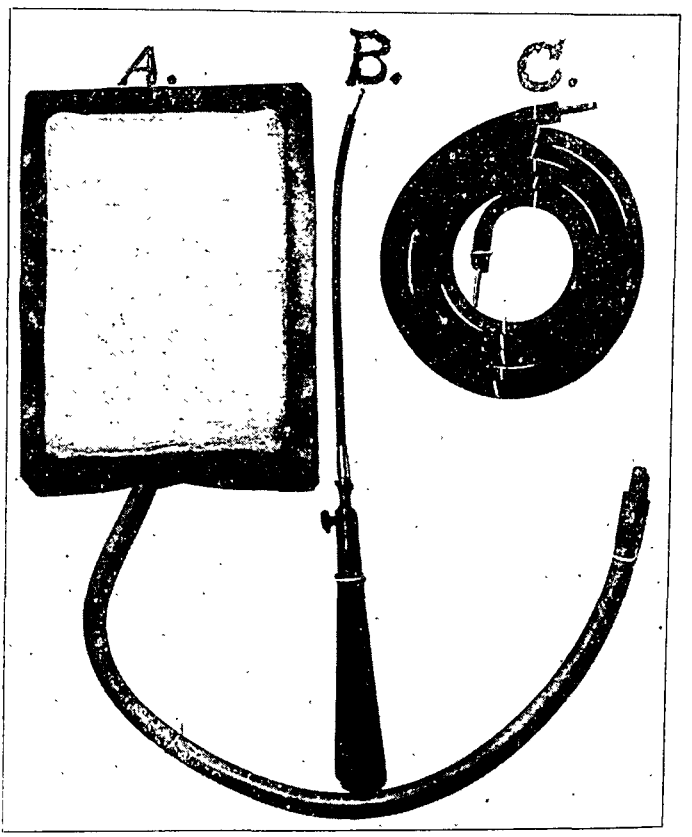

Fig. 4.—*A*, the pad which is placed under the buttocks of the patient, and the permanently attached rubber covered wire; *B*, active electrode used for destruction of the growth; *C*, type of Pfahler's rubber covered wires for carrying the d'Arsonval current. Two such wires are used.

times per second. One wire being attached to the large pad under the patient gives no local effect on the tissues in that region; but because of the great concentration of the current at the pointed or bulbous electrode which is introduced into the bladder, there is rapid destruction or coagulation of the tissues to which it is applied. Because of the danger of a sharply pointed electrode penetrating the tumor mass and starting bleeding, one of us (G. E. P.) has developed a bulbous electrode (Fig.

4, *B*) which is 9 inches long and 1/16 inch in thickness, and the bulb is less than 1/8 inch in thickness. This whole electrode is then covered with rubber tubing, so that when it touches the side of the abdominal wall or wound there is no local destruction, but the destructive effect occurs only at the tip of the electrode. This electrode is attached to a wooden handle, and the wooden handle in turn is attached to the wire connected with the d'Arsonval pole, or more commonly to the Oudin current pole, which is in turn connected directly to the opposite pole of the d'Arsonval instrument. All of these electrodes, needles and wires are sterilized by boiling. The spark gap and rheostat being adjusted so that a current of from 500 to 1,500 milliamperes can be used, the growth in the bladder is carefully destroyed, and each portion of the tumor is coagulated with sufficient rapidity to prevent hemorrhage, and yet slowly enough so that the steam from the cooking tissues does

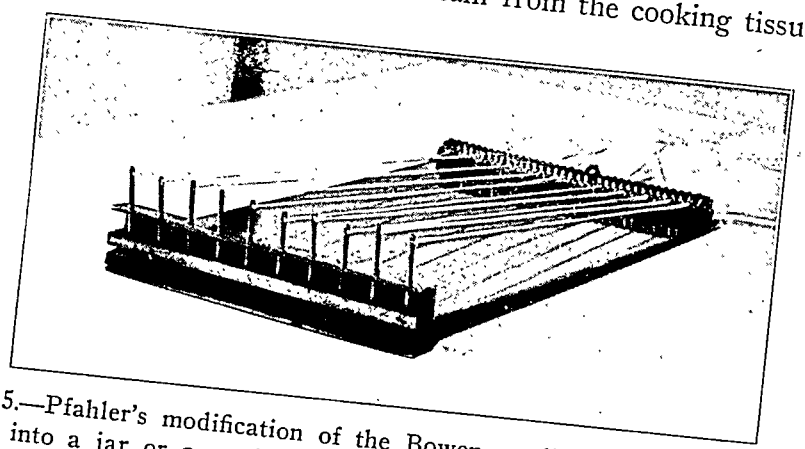

Fig. 5.—Pfahler's modification of the Bowen needle holder prepared to be dropped into a jar or pan of antiseptic solution; needles ready for insertion into the bladder. The points of the needles rest against rubber; the threads are held by a spring clamp.

not scald or macerate the wall of the bladder. The steam can be blown away by a current of cool air, but ordinarily it is practical just to work slowly enough so as to avoid this complication. The tumor tissue is destroyed until all parts are soft, and until all bleeding points have been brought under control. There will, of course, be left in the region of destruction an area of charred tissue; but there should be none of that induration which we recognize as characteristic of malignant disease. The tumor tissue after it has been destroyed may be curretted away, clipped away with curved scissors, or more generally simply wiped away with a sponge.

After all visible and palpable evidence of the tumor mass has been destroyed and removed, the bladder is irrigated with a warm solution of silver nitrate 1:4,000 to 1,000 and the incised edges of the bladder opening painted with a solution of resorcin, 5 per cent. The interior

of the bladder is then sponged as dry as possible, and the radium needles are implanted. The needles which we now use contain 10 milligrams of radium element each (Fig. 5). They are 27.5 mm. in length, 1.73 mm. in external diameter, the wall thickness of the metal being 0.4 mm. Each needle is attached to a waxed silk thread, and for this purpose we now make use of the dental floss prepared by Dunham-Reifel Company (as originally suggested to one of us [G. E. P.] by Dr. Russell H. Boggs). This is sterilized as it is prepared. It is again sterilized in chemical solutions before being used. The radium needles and the threads can be sterilized either by means of pure phenol fol-

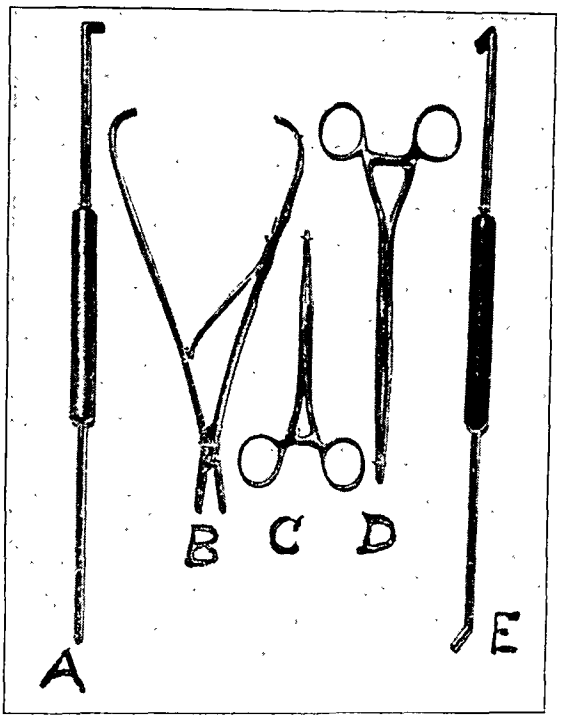

Fig. 6.—*A*, radium needle holder with arrangement for straight insertion at one end and insertion at right angles at the other; *B*, leaded jaw forceps for grasping and inserting radium needles; *C*, special grooved hemostatic forceps for forcing the needles to a deeper point; *D*, longer forceps for the same purpose, and *E*, needle holder for inserting needles at an angle of 45 degrees.

lowed by an immersion in alcohol, or in 10 per cent. liquor formaldehydi or in 95 per cent. alcohol. These needles are introduced by carriers (Fig. 6) into the base of the tumor, approximately from 1 to 2 cm. apart, and left in place from eight to eighteen hours, depending on the probable degree of malignancy and the extent of the disease (Fig. 7). The smaller the area of disease and the closer the needles, the shorter the period of time the needles are allowed to remain. From six to fifteen needles are used depending upon the size of the base of the

tumor. Up to the present time we have observed no vesicorectal fistula, and we have not observed any necrosis of normal tissue as a result of the introduction of the needles. Electrocoagulation is, of course, followed by sloughing of the destroyed tissue and this process will require approximately three or four weeks. The sloughing tissues are macer-

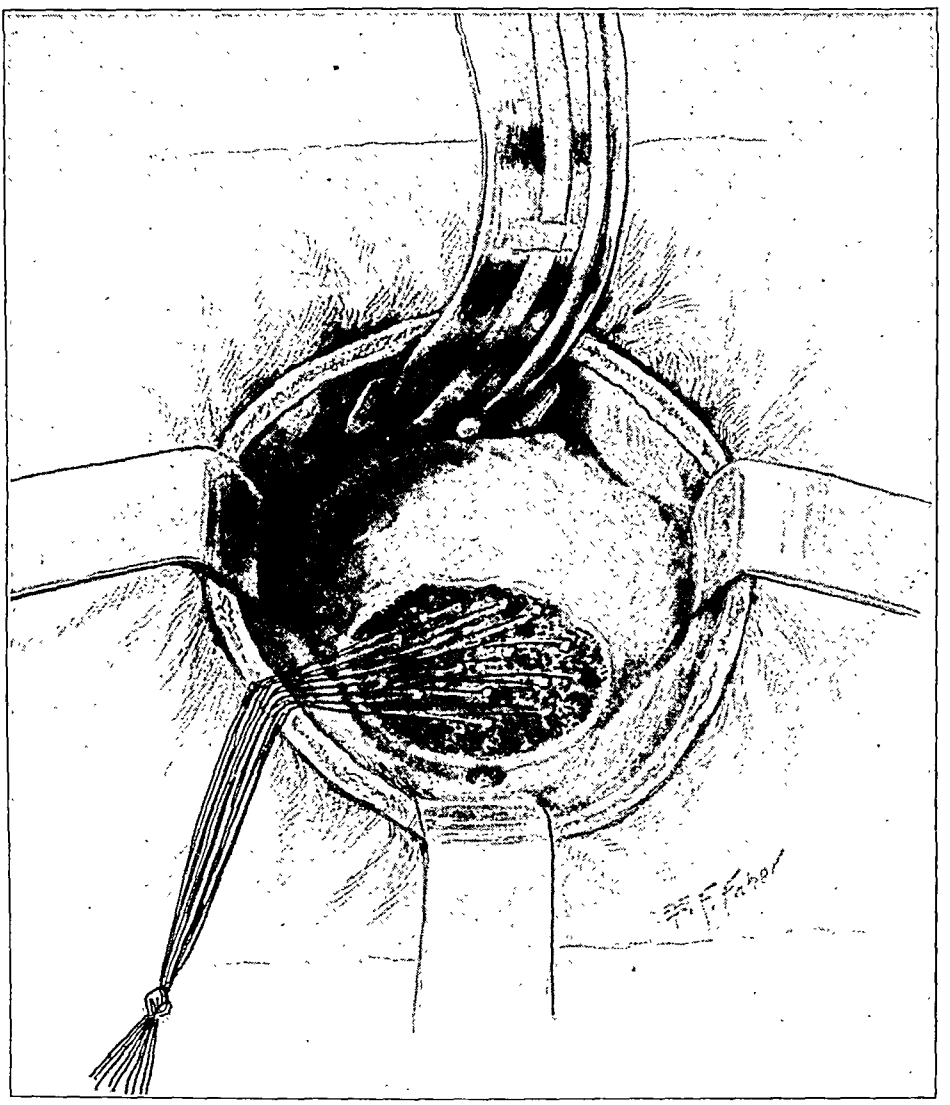

Fig. 7.—Disposition and arrangement of radium needles in the bed of the electrocoagulated area, following destruction and removal of the tumor.

ated by and carried out with the urine, either through suprapubic drainage or through the urethra.

A large sized, properly fenestrated rubber drainage tube, 2 to 2½ cm. in diameter, is introduced into the bladder, care being exercised not

to allow the end to impinge on the vesical trigon (Fig. 8), and retained at the upper angle of the bladder incision by closure of the wound below with continuous chromic gut suture (Fig. 9). The strand of threads attached to the radium needles is either passed out through the drainage tube or along the inferior aspect of the tube externally. A small fenestrated rubber tube passing into Retzius' space, for perivesical drainage, in case of bladder leakage, is secured to the lower angle of the skin incision. The large tube is then rotated downward and

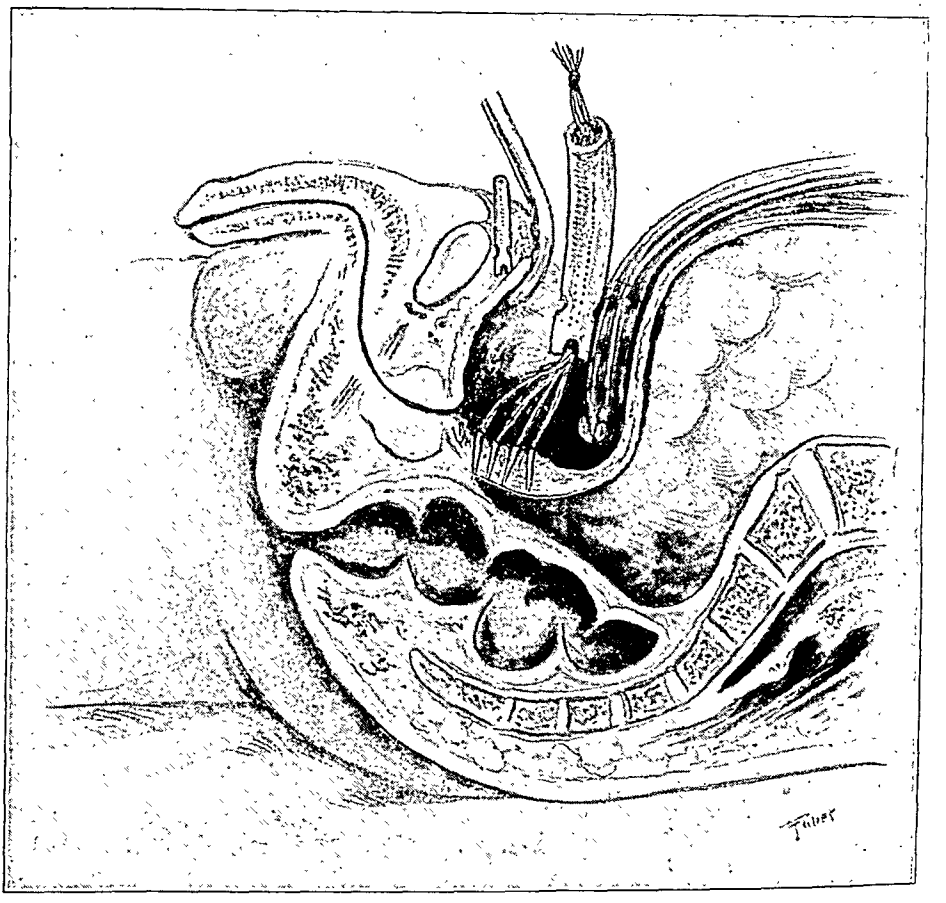

Fig. 8.—Sagittal section showing position of radium needles and conduction of their silk thread guides through properly placed drainage tube.

secured by suture of silkworm gut to the skin on either side of the incision just above the small prevesical drain (Fig. 10). The recti muscles are drawn together by one or two sutures of plain gut, and the fascia closed to the level of the tubes by a continuous suture of chromic gut. The skin is closed by interrupted sutures of silkworm gut and the radium needle threads secured for the time desired, if passed through the lumen of the drainage tube, by an L-shaped glass drain connector (Fig. 11). At the end of the first week after operation,

the drainage tube and all sutures are removed, and a special suprapubic drainage ambulatory apparatus is fitted to the patient (Fig. 12). This device, as a rule, suffices to keep him dry, either in bed or out, and thereby saves much gauze and cotton otherwise necessary for the absorption of urinary leakage.

Should the carcinoma be one involving the prostate gland, treatment, as a rule, should be applied both suprapubically and perineally. The

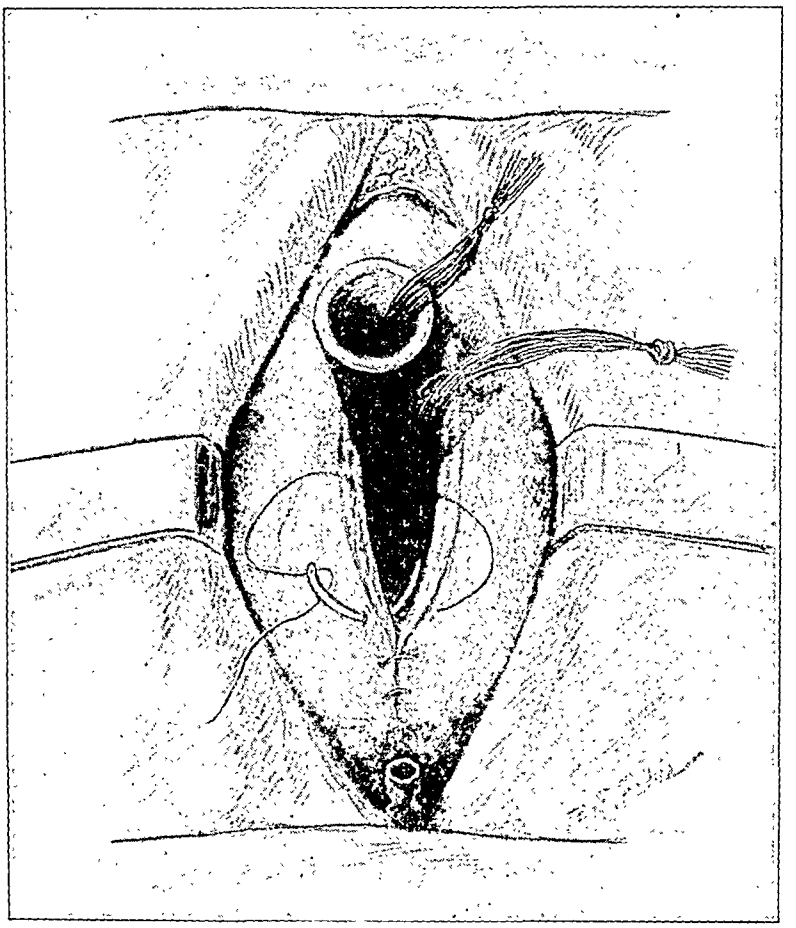

Fig. 9.—Closure of bladder showing proper placement of vesical and perineal drainage tubes. The radium needle threads may be conducted from the bladder either through the large vesical drainage tube or beside it above the continuous suture.

character of the carcinomatous growth, tending either to infiltrate or project into the bladder, or to be confined mainly to the posterior and lateral lobes of the prostate, will determine whether the primary attack should be made above or below. This decision will be aided materially by the findings of rectal palpation and cystoscopy.

The suprapubic technic differs in no essential from that employed when the carcinoma is confined to the bladder, excepting that when there is little protrusion of the growth into the bladder, destruction of the mass by electrocoagulation will not be necessary and the radium needles can be inserted immediately into the growth about a centimeter equidistant, as pointed out by Herbst[3] (Figs. 13 and 14), or as described above.

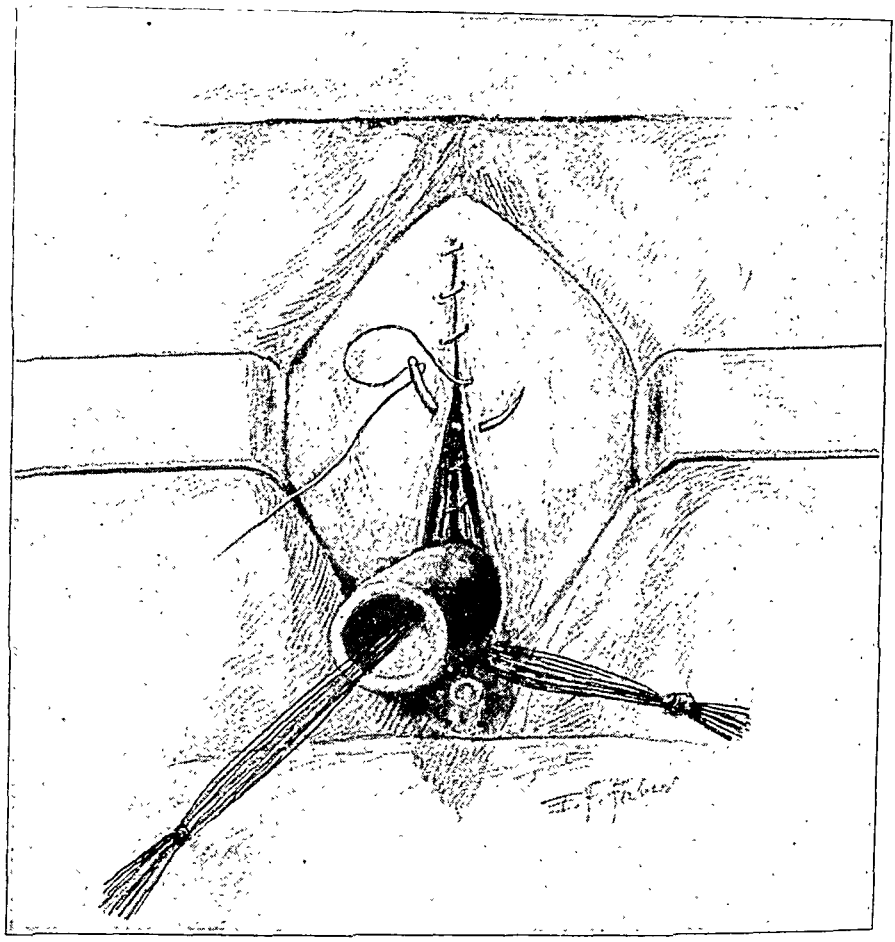

Fig. 10.—Bladder has been rotated downward by drainage tube, subsequently to be fixed by suture at lower angle through both sides of skin incision. Apposition of recti muscles by one or more interrupted sutures, also closure of fascia above tube, may be noted.

The perineal exposure of the prostate is best effected in the manner employed for prostatectomy, with the patient placed on the Halstead perineal board attached to any operating table (Fig. 15). The car-

3. Herbst, R. H.: Cancer of the Prostate; Combined Surgical and Radium Method of Treatment, J. A. M. A. **72**:1610 (May 3) 1919.

cinomatous gland is approached by the usual dissection and when exposed may be presented advantageously by two heavy traction sutures introduced in the tissues of the basal angles (Fig. 16), or by the insertion of the prostatic tractor (Fig. 17). In many cases, no traction will be required for sufficient exposure of the gland for the introduction of the radium needles. Just as in the case of the bladder, these

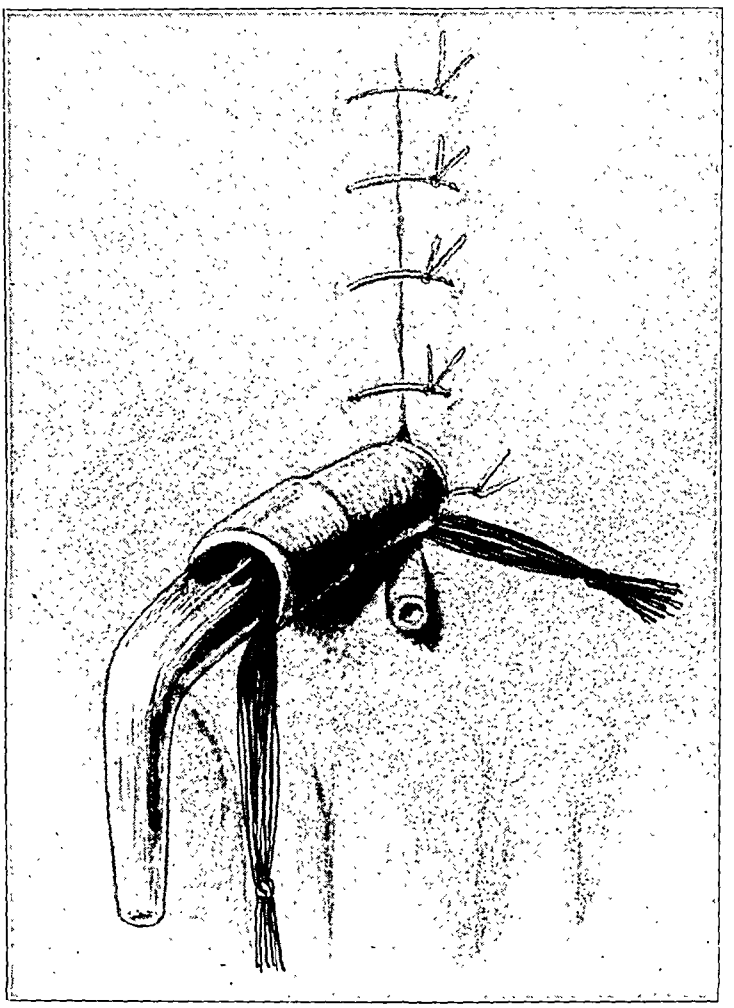

Fig. 11.—Suture of skin showing proper position of drainage tubes and disposition of threads attached to radium needles; showing manner in which threads are secured by glass drain connector if brought out through rubber tube.

needles are inserted about a centimeter apart, care being taken to avoid the urethra, at the same time assuring complete radiation of the posterior lobe, that part of the gland most commonly primarily involved and lying directly posterior to the urethra. The strand of threads attached to the needles is brought out one of the angles of the skin

incision, either alone or in conjunction with a drainage tube passed through the prostatic urethra into the bladder, in case the urethra has been opened (Fig. 18). The perineal drainage of the bladder, or by catheter through the urethra, may be necessary for a few days to obviate urinary obstruction in the prostatic urethra due to swelling of the prostate, incident to the action and reaction of radium.

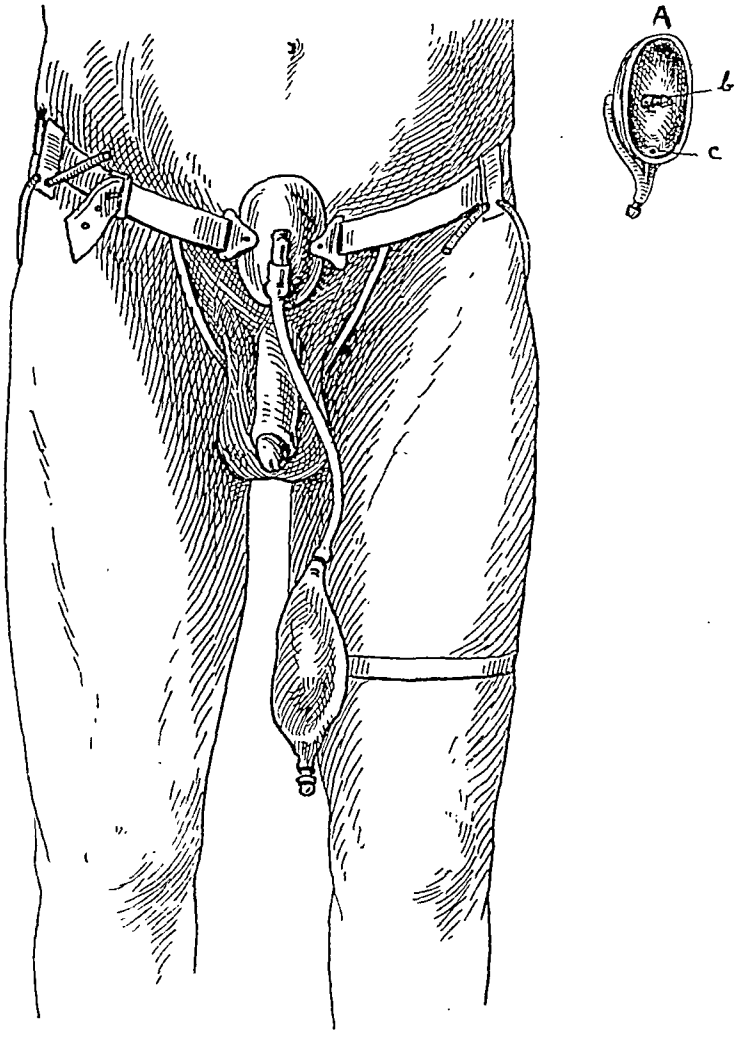

Fig. 12.—Suprapubic drainage apparatus fitted to patient on removal of intravesical rubber tube drain; *b*, detachable metal tip removed in a day or two, for the temporary attachment of decreasing sizes of rubber drainage tubes; *c*, opening for escape of urinary overflow into cup.

Intensive roentgen-ray cross-fire may be of advantage and should precede operative intervention, thereby destroying outlying carcinomatous foci in the lymphatics, limiting the spread of the disease temporarily and probably preventing certain metastases that might otherwise occur. In any event, whether employed before operation or not,

as soon after surgical intervention as the condition of the patient will permit, electrocoagulation, radium implantation and roentgen-ray treatment as here described should be instituted.

Anteoperative roentgen-ray treatment in all forms of malignant diseases is probably more important than postoperative treatment. It has been recommended for a considerable time by one of us (G. E. P.). (It

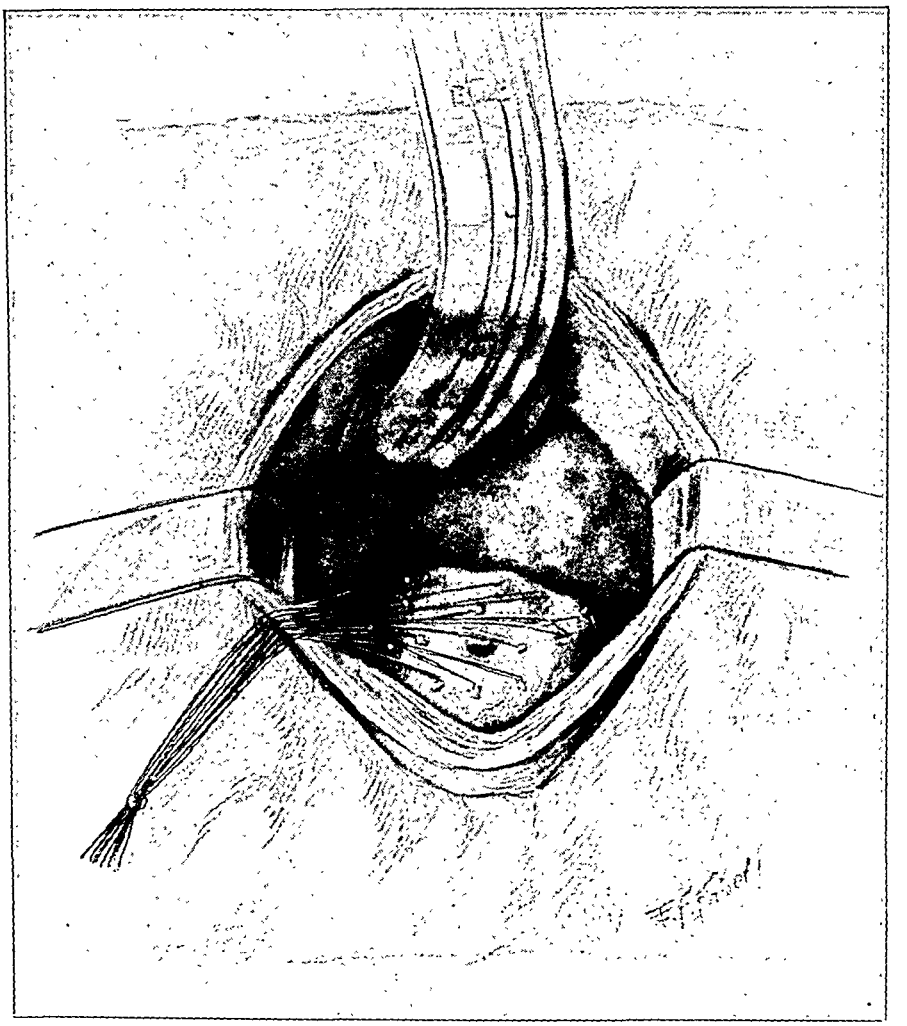

Fig. 13.—Arrangement of radium needles in vesical projection of carcinomatous prostate.

is especially important in treatment of malignant disease of the bladder because of the great likelihood of metastases having developed before the patient comes under active treatment.) This anteoperative roentgen-ray treatment will consume a period of about two weeks. It is not intended that it should be used with the idea of circumventing operation,

Fig. 14.—Sagittal section showing disposition of needles in prostate.

Fig. 15.—Position of patient on Halstead board and incision employed for perineal exposure of prostate.

or with the idea of waiting to see results, but entirely with the object of devitalizing carcinomatous tissue so that there is less likelihood of transplantation or recurrence following operation. This roentgen-ray treatment should cover the entire pelvic area and extend as far up along the line of lymphatics as is probable that the disease has traveled. The plan of treatment will be modified somewhat according to the amount of disease and its duration in each individual case; but in a general way, the anteoperative treatment in the average case will consist in dividing the area between the umbilicus and symphysis pubis into two areas by a

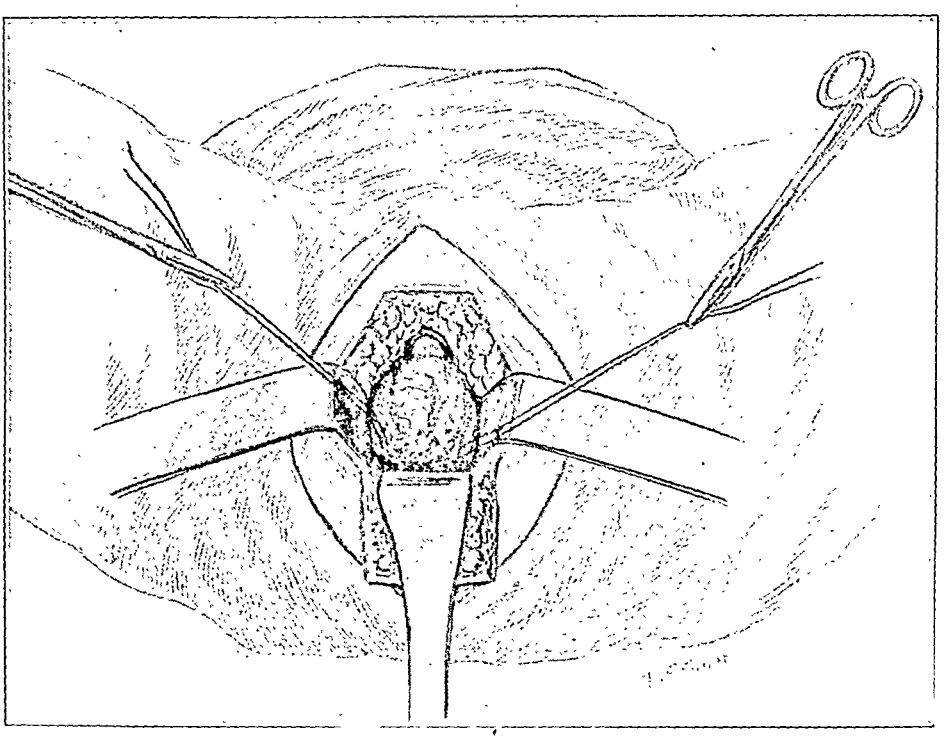

Fig. 16.—Exposure of carcinomatous prostate gland facilitated by traction sutures of heavy silk.

vertical line. The outer border of each area is marked by a line extending vertically through the anterior superior iliac spine. Posteriorly, it is best to divide the pelvic area into two regions by a line extending through the middle of the sacrum. The rays are then directed through the anterior fields so that in their distribution they will cover the proximal and the opposite side of the deep portion of the pelvis. Posteriorly, the rays are directed through the great sacrosciatic notch so that they will cross at about the center of the pelvis. Through each of these areas all the rays that the skin will tolerate must be given. In other

words, a full skin dose, which is just short of an erythema dose, should be given through each of these areas. For this purpose, one must use the technic and the amount of treatment which has been found to produce a skin dose with the particular instrument in use. For this purpose, we use with our instruments 6 mm. of filter, at a focal skin distance of 30 cm., from 25 to 30 minutes exposure with a 9 inch parallel spark gap, and 5 milliamperes of current. As postoperative treatment, at least two such full doses should be given through each area, beginning about two weeks after the radium application, and repeated again about three or four weeks later.

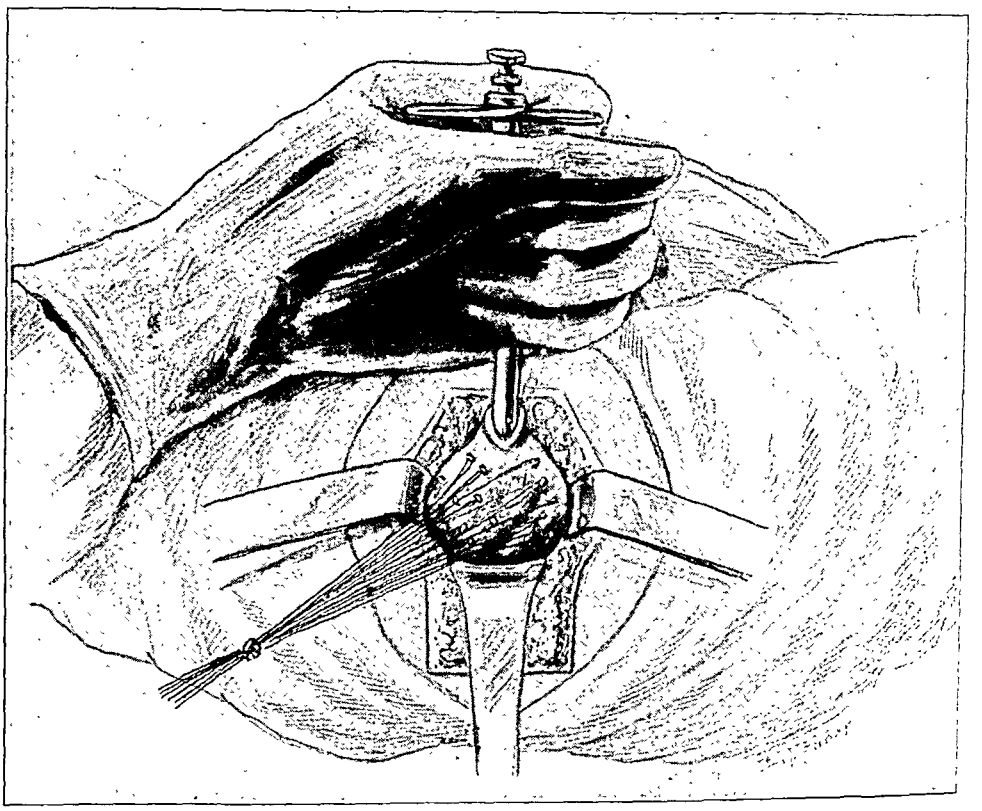

Fig. 17.—Display of gland, aided by prostatic tractor; radium needles inserted into carcinomatous tissue, avoiding urethra.

RESULTS OF TREATMENT

Employing this combination, or quartet, of therapeutic measures, twenty-six patients have been treated. It is true that originally, in a few cases, our methods, with the present technic, were comparatively crude in some respects. Until three years ago, when the small needles came into use, we were obliged to plant the radium *en masse* into the growth or its bed; also, the electrocoagulation of the growth was not

so intensively and thoroughly done; indeed, in some instances, the tumor was destroyed or removed by the electrocautery, prior to the implantation of radium. Nevertheless, it is a remarkable fact that in our series of cases, although some patients have not been relieved of their symptoms, or their symptoms have returned after a period of improvement or actual freedom, only two are known to be dead, and one has been untraceable, a result we dare say that could not have been paralleled by any other form of treatment. The majority of these patients have been treated and observed only during the last three years, therefore, we are not justified in drawing conclusions, nor is it

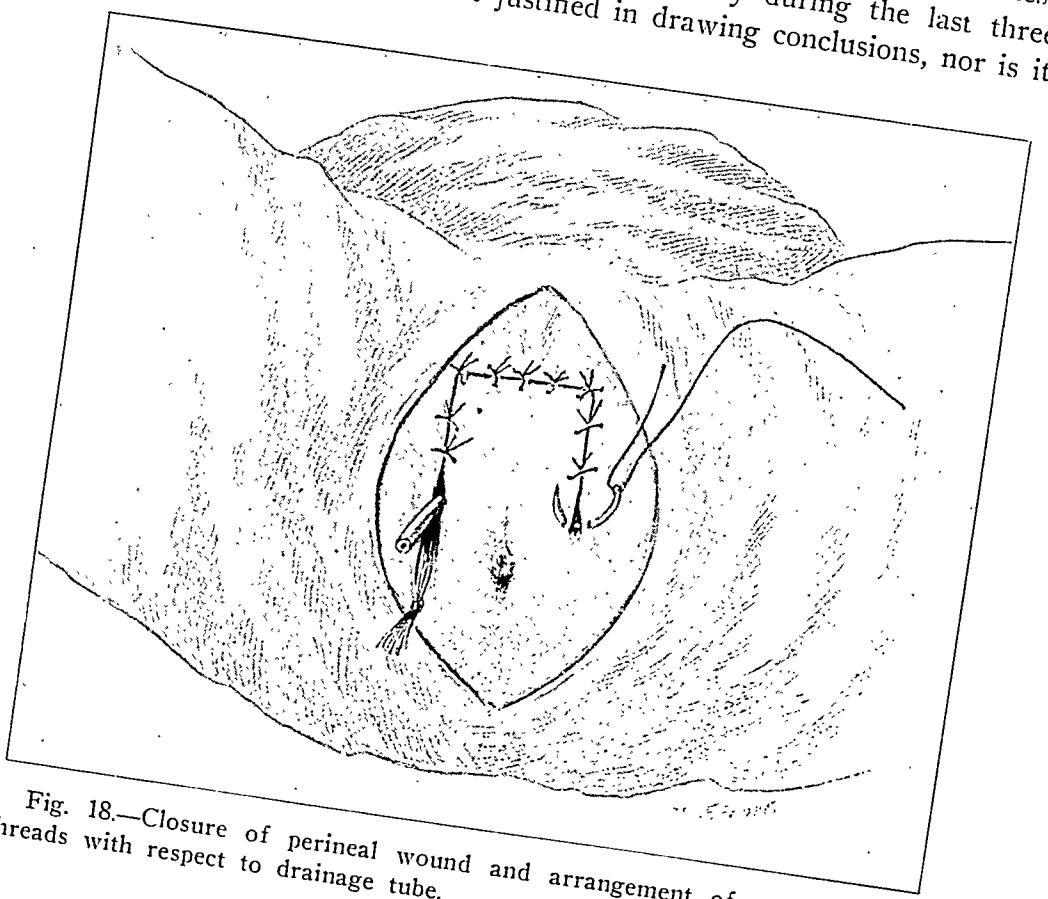

Fig. 18.—Closure of perineal wound and arrangement of radium needle threads with respect to drainage tube.

our intention to make any particular claims as to end-results. We desire simply to describe the technic evolved from experience and at present employed in this surgically unwelcome and disheartening type of formerly inoperable bladder and prostatic carcinoma, and to say that it is our conviction that the treatment here described and practiced offers more in the way of prolongation of life, if not cure in a few rare instances, than any other method of treatment heretofore employed in this particular deplorable type of malignant disease.

A DETAILED BACTERIOLOGIC STUDY OF A CASE OF GAS GANGRENE FOLLOWING A COMPOUND FRACTURE

STUDIES ON PATHOGENIC ANAEROBES III *

CLINICAL OBSERVATIONS BY
EDNA L. BARNEY, M.D.

BACTERIOLOGIC STUDIES BY
HILDA HEMPL HELLER, PH.D.
SAN FRANCISCO

CLINICAL OBSERVATIONS

A summary of prewar cases of gas gangrene has shown that this type of infection occurs far more often with compound fractures than with any other type or condition of wound, and that the occurrence of gas gangrene in civil life is extremely uncommon, only 175 cases having been reported up to 1915. Data on this subject since the war show that the percentage of gas gangrene cases in war wounds was moderate, ranging in different localities from 1 to 3.5 per cent.

In the 175 cases collected from the literature up to 1915 by Simonds,[1] the relative number of several types of wounds was as follows: compound fractures, 61; lacerated wounds, 28; operation wounds, 11; gunshot wounds, 10, and hypodermic needle puncture, 9. Thus nearly as many cases of gas gangrene developed in hypodermic needle punctures and slightly more in operation wounds than in gunshot wounds. Gas gangrene was twice as frequent in lacerated wounds and six times more frequent in compound fracture cases than in gunshot wounds. This refutes the impression gained from war reports that gas gangrene was peculiarly incidental to gunshot wounds. Furthermore, the relatively high frequency of gas gangrene in compound fracture wounds as compared to some other types of wounds, which are equally liable to contamination by foreign substances, argues for a different accessory agent to the growth of gas gangrene organisms than is supplied by the nidus theory.

---

* From the Department of Surgery and the George Williams Hooper Foundation for Medical Research, University of California Medical School.

1. Simonds, J. P.: Studies in B. Welchii with Special Reference to Classification and Its Relation to Diarrhoea, Rockefeller Institute for Medical Research, Monograph 5, 1915.

In the experiments of Bullock and Cramer,[2] particles of wood, cloth, paper and other foreign substances, after being soaked in a suspension of *B. welchii,* were introduced beneath the skin of mice with negative results. *B. welchii* was also introduced into hematomas with negative results. Bullock and Cramer found, however, that the presence of certain calcium salts aids in the production of gas gangrene. Doses of 2½ mg. of calcium chlorid injected with a suspension of *B. welchii* or of *Vibrion septique* never failed to produce gas gangrene in the experimental animals. Calcium nitrate and calcium acetate have the same effect. The conclusion of Bullock and Cramer was that calcium salts produce at the site of injection a local change in the tissues which lessens their defensive mechanism. Therefore, does it not seem probable that calcium salts, liberated by the disintegration of devitalized bone substance in compound fractures, may supply, to a large extent, the factor that lessens the resistance of the tissues to gas gangrene anaerobes?

Whether a fracture is compounded from within outward by a bone fragment or from without inward by a foreign body, there is in either case ample opportunity for bacterial invasion. But in compound fractures, not only the severe traumatization of the bone substance itself, but the usual traumatizing effect of the bone fragments on soft tissue cause far greater devitalization than would result in a corresponding injury to soft tissue without fracture. The increased devitalization burdens both the injured and adjacent tissues with a greater metabolism complex and no doubt a lowered cell resistance. This increased devitalization, which includes both bone and soft tissue, is probably an important accessory cause for the increased susceptibility of compound fracture over other wounds for the development of gas gangrene.

REPORT OF CASE

History.—M. R., aged 8 years, schoolgirl, American, entered the surgical clinic of the University of California Medical School, Oct. 2, 1919. On the evening of October 1, the patient fell from a bench, 4 feet above the ground, injuring her arm. The ground was covered with dry grass and showed nothing to suggest any particular contamination. The child's home was close by, and next to a barnyard. There were several goats in the vicinity.

Immediately after the accident, the child, with the injured arm wrapped in a towel, was taken to an emergency hospital, where at 8 p. m., the fracture was reduced and the arm was splinted.

Examination.—When the patient entered the surgical clinic the next morning, the entire forearm was moderately swollen, but not more so than would be expected from a fracture of both the ulna and the radius. Over the middle third of the ulna on the volar surface was an open wound, 1.5 cm. in length.

---

2. Bullock, W. E., and Cramer, W.: On a New Factor in the Mechanism of Bacterial Infection, Proc. Royal Soc., Series B **90**:513, 1919.

Inquiry elicited the fact that before reduction at the emergency hospital, the lower fragment of the ulna was protruding through the wound. At the time of examination at the surgical clinic, fourteen hours after injury, no symptoms nor signs of gas gangrene were noted. But the following morning, October 3, when the child returned to the clinic, the forearm was gangrenous, with circulation stopped just below the elbow. The entire arm was greatly distended, and edema had extended into the shoulder muscles. From gangrenous blebs on the wrist, when punctured, oozed a bloody serum and bubbles of gas. Gas bubbles also issued from the wound.

Operation and Result.—The arm was amputated, guillotine method, just below the level of the insertion of the deltoid muscle. The amputation was well above the lowest line of the circulation. Smears made at this time from the wound in the forearm showed the presence of *B. welchii.* No tetanus organisms were found; but 1,500 units of tetanus antitoxin was administered subcutaneously.

On the morning following the operation, 20 c.c. of *B. welchii* antitoxin, which was the only available antiserum related to gas gangrene, was given intravenously. We were able, fortunately, to obtain *B. welchii* antitoxin through the courtesy of Dr. K. F. Meyer of the Hooper Foundation. On the second day following the operation, 15 c.c. of this antitoxin was given subcutaneously, about 50 antitoxin units in all. The child was apparently very toxic. A marked tachycardia developed, together with restlessness, delirium, stupor and cyanosis. The wound was treated with surgical solution of chlorinated soda (Carrel-Dakin solution). It was dark in color, with patches of crusts covering sloughs. The patient remained in restless delirium until the eighth day after operation; the pulse rate increased to 160, and the temperature to 39.2 C., rectally. There was a blowing systolic murmur heard over the precordium; the liver edge was 3 cm. below the costal margin; but the splenic margin was not palpable. There were also, on the eighth day, definite signs of serum sickness with edema of the eyelids and lips and herpes on the lips. There was also vomiting and diarrhea. The wound had not begun to granulate but was still the color of old meat. The Carrel-Dakin solution was discontinued, and a mild solution consisting of salt solution and hydrogen peroxid was substituted.

On the following day, the ninth day after operation, the pulse rate began to drop; the child became rational; the sloughs began to disappear, and the child advanced steadily to complete recovery. She was dismissed from the hospital on the twentieth day after operation.

PATHOLOGIC ANATOMIC NOTES

The examination of the arm amputated was undertaken three hours after the operation. The odor of the arm was strong, rank and penetrating, but not putrid. It resembled that of butyric acid; but there was also a rank, peculiar odor similar to that of blackleg muscle in cattle. The arm was rigid as it had been before amputation. The tissues were about as resistant to pressure as a very hard rubber ball, the moist skin of the forearm showing considerable stretching and tension. On the wrist and on the palm of the hand were several long bullae filled with a serous colorless liquid. The hand and fingers were very edematous and had a white transparent appearance. Crepitus was present in the hand, wrist and forearm. On the flexor surface,

midway between the wrist and elbow, was a small wound about ¾ by ¼ inch in area. This had probably been caused by perforation by the fractured ulna. The forearm showed blue marks and abundant indications of contusions. There was no bronzing of the skin unless a certain dark discoloration of that on the wrist may be so designated. The elbow was greatly swollen as was the upper arm, but above the elbow crepitus was absent.

The cut end of the arm showed a bubbling of gas at the site of the principal blood vessels. A large amount of blood escaped from the arm before it was examined, probably on account of the gas pressure.

An incision made along the flexor surface revealed a varying amount of gas in the different portions of the arm. Most striking was a gradual spreading of the skin of the wrist, till it lay open for a space of more than an inch. Gas was released from solution where it had been confined by the pressure exerted by the integument, and large bubbles appeared in the connective tissue and among the muscles, distending the tissue greatly. The muscles in this region were slightly dry and somewhat hemorrhagic. They were not brick colored or yellowish nor had they in any great measure lost their elasticity. Section of the palm allowed considerable bubbling to take place; but it was apparent that most of the swelling of the hand was due to a white edema that retained its gelatinous consistency on section. The muscles of this region were normal or slightly pale in color; all the tissues were moist and elastic, and there was no turbid exudate except a little fluid that contained a few red cells. The large muscles of the upper portion of the forearm were moist, edematous and contained a considerable amount of gas. This bubbled forth for some time after section without the application of any pressure. Its odor was rather rank and sweetish, the butyric acid element not being marked, and a true proteolytic odor not being noticeable. All the muscles were hemorrhagic, most of them uniformly so. The fracture of the ulna had occurred in the middle of the shaft; that of the radius was comminuted and in the upper third of the shaft. Examination of the broken ends showed that the arm had been shortened a quarter of an inch, perhaps partly by the pressure of the gas. On the muscle next to the fractured end of the ulna was a yellowish discoloration thought to be due to bacterial action. Bacteria were, however, not found to be especially abundant in this region. The muscles of the forearm surrounding the fracture were somewhat darker, and the region immediately about the fracture of the radius was marked by the presence of much gas and areas of black hemorrhagic infiltration of the muscles. Extending toward the elbow, several of the muscles showed irregular, small and large black hemorrhages. On the flexor surface of the elbow was a small lacerated blood vessel

Form No. 59.—10m-5,'19

UNIVERSITY OF CALIFORNIA HOSPITALS GRAPHIC CHART

UNIVERSITY OF CALIFORNIA HOSPITAL

October 1919

HAHNEMANN HOSPITAL

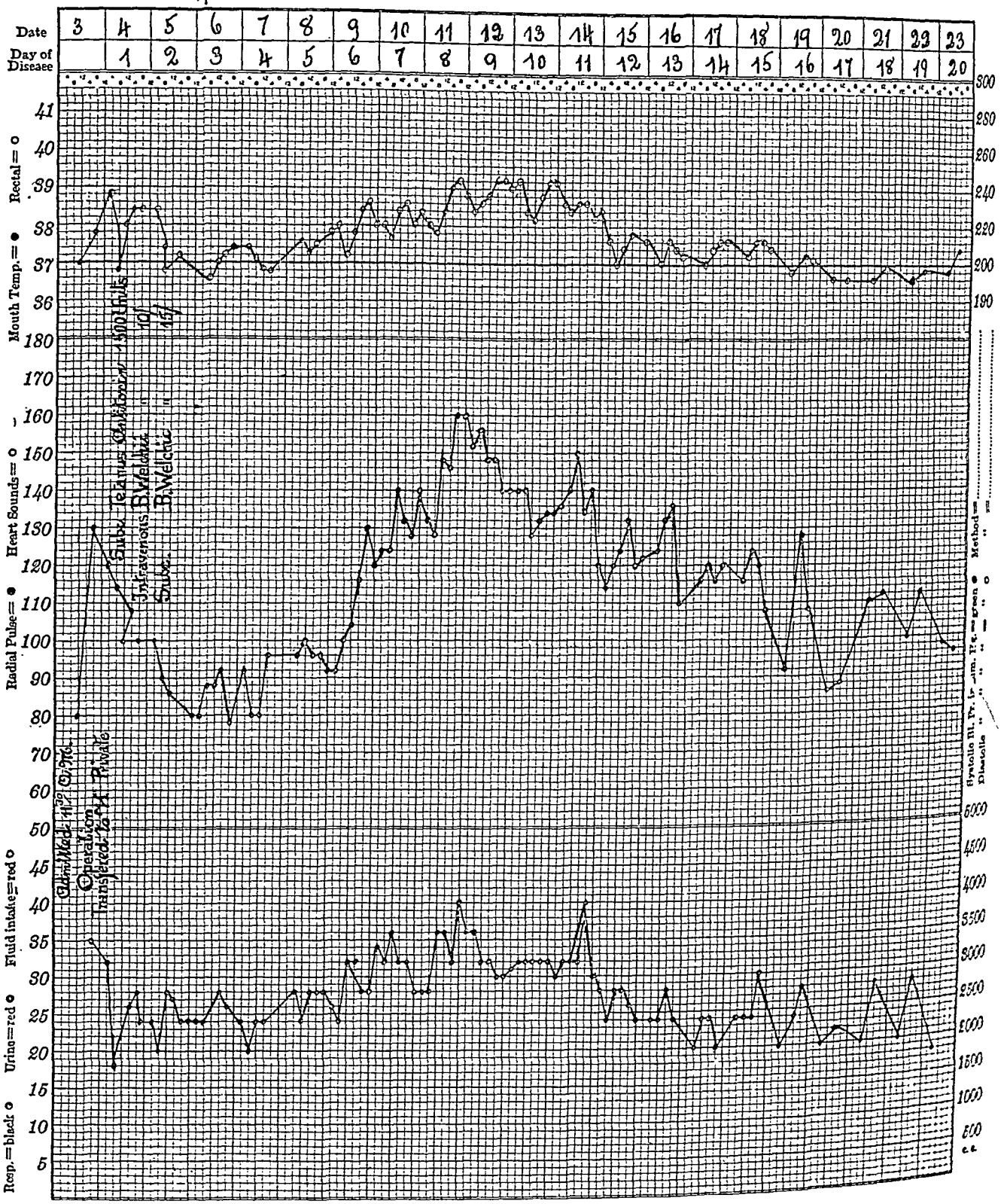

Chart of remarkable tachycardia in a case of gas gangrene.

containing a clot. The fascia of this area and the muscles below it were blackish red and contained gas. Aside from the gas and color changes, the muscles appeared normal. Nowhere in the forearm was there any pus or exudate. The muscles of the upper arm were but little affected. The fat-containing fascia of this region was, however, markedly gelatinous and contained no gas. The edematous fascia retained its consistency long after section, only a little blood-stained exudate leaking forth.

Twenty-four hours later the arm had lost its rigidity almost entirely, though it had been kept on the ice in the meantime. It is not unlikely that this rapid loss of rigidity was partly due to the escape of the gas and partly to the effect of the bacterial action on the tissues. The muscles were distinctly flabby but not putrid. The connective tissue of the upper arm had lost its gelatinous consistency. A week later, it was found that the area of blackish discoloration was spreading toward the line of amputation, especially near the bone. The arm kept for some time in the refrigerator developed no signs of normal decomposition and the odor remained as before.

MICROSCOPIC AND CULTURAL FINDINGS

At the site of the small perforating wound over the fracture of the ulna were found thick, short, gram-positive, square-ended rods, and in a minority somewhat longer and more slender round-ended rods, not to be easily distinguished from the shorter ones when stained with a thick gentian violet gram stain. A meat medium culture from this region gave an extremely vigorous growth of typical *B. welchii.* In this culture, contaminations were noticeable only after the elimination of *B. welchii* by heat.

A smear from the muscles of the wrist, the region where there was most gas, showed both types of organisms, the heavy rod and the slender rod. A culture gave predominantly *B. welchii.* When this organism was killed, various others were found to be present.

Smears from the palm of the hand showed a clear staining gram-negative rod with rounded ends, and occasional terminal oval spore-bearers. (The thin methyl violet gram stain [3] of the home laboratory was used for this and all the following stains.) A culture on meat medium gave, in twenty hours, gas and a gram-negative rod. This organism produced only a faint pink coloration of the meat particles. The culture seemed to die on exposure to the air, as subcultures showed only a small saprophyte that produced no gas. There was no hint of the presence of *B. welchii.*

---

3. Heller, H. H.: The Etiology of Acute Gangrenous Infections of Animals, J. Infec. Dis. **27**:385 (Nov.) 1920.

Smears from the site of the fracture of the ulna and the muscles above it gave little or no indication of the presence of *B. welchii.* They showed everywhere gram-negative rods, single and in pairs. These were most abundant at the site of the fracture and in the deep red hemorrhagic muscle. The organisms in the muscles in general were vegetative only; those at the site of the fracture were sporulating. The spores were large, oval, usually terminal, with thin walls. They are best described as racket shaped. No bilaterally asymmetrically placed spores were seen. Some bacilli from this region were irregular in their staining, reminding one of the granulose forms of *Vibrion septique.* The edematous fascia of the upper arm contained a very few organisms, some of them sporulating. These were found close to the line of amputation. Cultures taken above the fracture of the ulna gave no Welch bacilli whatever. They contained an organism making a large woolly colony of loose structure with a halo of hairlike radiations. This organism was, so far as it is possible to state, the sporulating one seen on the smears. It proved to be a variety of *Vibrion septique.* A remarkable feature was its greater size in human tissue than in guinea-pig tissue. The eye trained to seeing anaerobes in guinea-pig tissue would find the large racket shaped rods in human tissue more like those of *B. oedematiens* than like *Vibrion septique.* A guinea-pig inoculated in the thigh with 0.5 c.c. of a twenty-four hour culture died in sixteen hours and showed moderate hemorrhagic infiltration of the muscles, little edema, a little gas in the inguinal region, marked injection of the peritoneum, injection of the intestines and of the suprarenals, enlargement of the suprarenals and an invasion of the lungs as shown by congestion and hyperemia. Such lung invasion is rather unusual in the case of *Vibrion septique* strains and is apparently constant in the case of this strain in the guinea-pig body. The lung and liver and peritoneum showed long gram-positive filaments, which are very reluctant to form spores even after forty-eight hours at room temperature; the muscle at the site of inoculation showed forms in all stages of development from purely vegetative, through granulose, swollen forms to sporulating forms. This organism was found also in the wrist and was apparently present in the hand, though cultures failed to show its presence.[4]

4. The technic used in the isolation of these strains was simple. Dilution shakes were made in deep peptone liver agar of samples from various portions of the arm. Peptone liver agar is an excellent medium because an exceedingly wide range of anaerobes will grow on it. These shakes were searched carefully and persistently for unusual colony types, and such, when found, were isolated on liver agar and then planted into meat. From the meat, all different types were inoculated into the thigh muscles of guinea-pigs. Details as to the operation of my isolation technic will be found under the title "Principles Concerning the Isolation of Anaerobes," J. Bacteriol. **5**:445 (Sept.) 1921.

There was also, wherever *Vibrion septique* was encountered, an unidentified gram-negative rod that made small dense colonies with short radiations and that belonged to the nonproteolytic group of anaerobic bacteria This organism appeared to be wholly nonpathogenic for the guinea-pig. We shall call it *Bacillus S.*

From the elbow was isolated a third invader that is of interest. It produces lesions much like those caused by certain oedematiens group strains, but culturally it cannot be included in such a group. It possesses distinct though mild proteolytic powers, and in many minor ways differs in its habits from oedematiens group of organisms. This bacillus has marked toxic properties for the guinea-pig and only moderate invasive ones. It usually becomes septicemic in that animal, a fact of interest, because of its invasion in the human case. Considering the number of bacilli present in the animal body at the time of death, this bacillus is far more toxic than the observed strains of other tissue invading groups. Proteolytic action and tissue destruction were not detected in the guinea-pig body probably on account of the sparse proliferation of the bacilli, though a faint proteolytic odor may sometimes be noted. Edema production in connective tissue and muscles is marked; the edema is water-clear. No gas formation has been noted in the animal. Hemolytic action may be entirely absent or may be confined to a spot or two. Injection of the serous surfaces and of the suprarenals is intense. In accordance with a new system of nomenclature,[5] we propose for this bacillus the name *Reglillus progrediens.*

From the region of the wrist, a second new tissue-invading pathogen was isolated. It is a nonproteolytic anaerobe of high saccharolytic powers, and resembles *B. welchii* in its action on tissues. No organism of our acquaintance possesses sufficient characteristics in common with it to warrant its association in the same genus. For it we propose the name *Meyerillus sadowa.* It is an actively invading organism of the muscle-feeding type. It causes considerable muscle and connective tissue destruction in the guinea-pig, and but little gas and edema formations. The intestines are injected and bile-stained, the suprarenals injected and enlarged. The striking lesion is a multitude of hemorrhagic erosions on the stomach lining, resembling leopard spots. The bacilli are densely gram-positive heavy rods with square ends; in the animal body they vary in size and form no chains or spores.

These two species will be described in detail in a future paper.

A strain of sporogenes affinities was isolated from the muscles distal to the fracture; but this type of organism was not present in sufficient numbers to cause any gross evidences of proteolysis.

---

5. Heller, H. H.: Suggestions Concerning a Rational Basis for the Classification of the Anaerobic Bacteria, J. Bacteriol. **5**:521 (Nov.) 1921: Certain Genera of the Clostridiaceae, J. Bacteriol. **7**:1 (Jan.) 1922.

No aerobes were found in the material at any point.

On the ninth day after the fracture occurred, exudate from the stump contained leukocytes and was microscopically sterile; but smears from the necrotic areas showed gram-positive sporulating rods resembling *Vibrion septique,* a gram-negative rod, and a few large cocci. Culture showed the presence of *Vibrion septique* and a proteolytic organism.

Much emphasis was laid during the war on the part played by the heavily fertilized soil of France in the causation of gas gangrene. As we here had to do with a much less severe wound than many of those encountered during the war, one containing no earth or other foreign material, and as we found so many species of anaerobes in the wound, an effort was made to investigate the conditions surrounding the accident.

The child had fallen from a high bench, near a street in a suburb of San Francisco, onto dry sandy earth covered with dry grass. Goats were pastured in the neighborhood and had perhaps often crossed the place where the accident occurred; but no manure was demonstrable in the close vicinity. The ground had probably not been cultivated for years. One would not think of it as a particularly dirty spot. Two samples of grass and two of earth were taken to the laboratory and were inoculated into meat medium. All gave a mixture of anaerobes on cultivation. These included heavy gram-positive, short, square-ended rods. All four cultures when inoculated onto milk gave prompt and decided stormy fermentation, which was caused by the short, gram-positive rods, establishing the identity of *B. welchii.* This organism in the meat cultures was killed out by heat, and the resulting meat cultures when twenty hours old were inoculated in 0.5 c.c. doses into the thighs of guinea-pigs. Two of these animals developed a very marked edema, and one of them which had been injected with a culture from grass died in twenty-four hours, and on section, its tissues showed evidence of great proteolytic action. The other was killed after twenty-four hours. The thigh inoculated contained gas and was partially digested. The whole ventral surface to the axillae was covered with a plaque of white serogelatinous edema, a half inch in thickness. This edema was not putrid and contained no gas. These infections were both evidently mixed proteolytic and nonproteolytic ones. *Vibrion septique* may be regarded as having been absent as it almost always causes death in the guinea-pig before the lapse of eighteen hours. Various unidentified anaerobes were cultivated from these guinea-pigs.

It must be remembered that the physician who received the case stated that the arm was wrapped in a towel that was "rather dirty," and that the family of the child lived near a barnyard. Nevertheless, we think that because of the findings in the grass and earth it may be

stated that abundant anaerobes may exist on the surface of uncultivated poor sandy soil, and that numbers of these are capable of surviving and multiplying in lacerated muscle, and that some of them may penetrate healthy tissue in proximity to such muscle, even when foreign matter such as soil is not present in the wound.

COMMENT

We have here to do with a mixed anaerobic infection which had as a focus lacerated muscle in the forearm. The organisms found are divisible into groups, as in the accompanying table:

GROUPS OF ORGANISMS

Flora Observed	Proteolytic	Nonproteolytic
Invasive in man in tissue proximal to wound	Reglillus progrediens	Vibrion septique Bacillus S
Invasive in guinea-pig, but not in man		B. welchii Meyerillus sadowa
Not invasive in guinea-pig or properties unknown	Sporogenes type	Small rod producing no gas Gram-negative rod producing little acid Bacillus S

Although the opinion most widely held early in the period of the war was that gas gangrene was a monospecific invasion, caused usually by *B. welchii,* workers who have since made careful bacteriologic studies of their material have emphasized that gangrenous invasions following war wounds are usually polyspecific. The interested reader will find the fullest account of such investigations in Weinberg and Séquin's [6] book and in the report of the Medical Research Committee [7] on anaerobic bacteria and infections. The cases of Weinberg and Séguin are the most carefully worked out and discussed. These authors describe more numerous and more highly polyspecific infections than do other workers This must, in all probability, be attributed to their technic. They use for isolation deep glucose agar shakes, wherein the flora is spread out like a map, and wherein relatively accurate estimates of the number of organisms of different sorts may be made. The British workers have employed surface methods almost entirely. These suffice admirably for *B. welchii* and for *Vibrion septique,* but sometimes fail to show the presence of other types.

6. Weinberg, M., and Séquin, P.: La Gangrène gazeuse. Paris, 1918.

7. Report No. 39 of the Committee on Bacteria and Infections, Medical Research Committee, London, 1919.

The ecology of bacterial organisms entering a sterile territory of rich food supply which has partially but not entirely lost its defensive powers against them is a most interesting study; and it is to be regretted that the exact distribution of these organisms was not more carefully mapped out in this case than it was. For purposes of an ecologic study, the arm investigated may be divided into various zones.

Zone 1. *The Immediate Foyer of the Wound.*—Into this, both aerobes and anaerobes were without doubt introduced. The condition of the tissue was anaerobic; the strict aerobes never developed; the facultatively anaerobic ones were probably all types to which the body had some resistance, and the defensive powers in the damaged tissue were sufficient to destroy them even in the presence of the rapidly developing toxins of the anaerobes. But several types of anaerobic organisms were apparently able to multiply unhindered in this damaged tissue, probably because they were types to which the body was unaccustomed, some of them, types which would probably not have been able to multiply in tissue so little damaged as was the muscle about the fractured bones, if they had not been defended by the toxins of their fellows.

Zone 2. *The Hand.*—The portion distal to the fracture was probably afforded a meager circulation for a considerable period of time after the accident occurred. Invaders capable of traveling along the blood vessels and lymph channels did so and reached the hand. They were the organisms that died after their first cultivation, and the minute rod that produced no gas, perhaps also *Vibrion septique.* These organisms caused the formation of a thick edema in the connective tissue and of a little gas in the region of the small muscles.

Zone 3. *The Wrist.*—As swelling in the region of the fracture increased, the circulation in the distal segment decreased, and some of the active muscle feeders (*B. welchii, Meyerillus sadowa* and the sporogenes-like organism) traveled downward in the muscle, some of which was contused, multiplying extensively and attacking it so severely as to produce gas but no gross tissue destruction, and effectually shutting off the circulation from the entire distal portion of the arm. Organisms found within this region cannot be considered as strongly invasive in their nature, merely because of this invasion of damaged muscle.

Zone 4. *The Section Between the Fracture and the Elbow.*—Here the contest between the tissues and the organisms was acute The blood supply was somewhat subnormal; the tissues were somewhat contused. A reservoir of necrotic, toxin-breeding muscle lay distal to this section. Apparently, only three organisms succeeded in invading this zone, *Vibrion septique,* the mysterious *Bacillus S,* that in the presence of the toxin of *Vibrion septique* was able to avail itself of the same means of distribution as that organism, and a toxic edema-former with slight proteolytic powers (*Reglillus progrediens*). That *B. welchii* was not represented in this zone may surprise some workers. Strains of this type of organism vary in pathogenicity. This was one of moderate pathogenicity for the guinea-pig. The strain *Meyerillus sadowa* was fully as pathogenic for the guinea-pigs as the Welch strain.

Zone 5. *The Upper Arm.*—Here *Vibrion septique* and *Bacillus S* multiplied with a fulminating rapidity and availed themselves of the blood and lymph channels for distribution. At the level of amputation, the blood vessels contained numerous bacilli, and *Vibrion septique,* at least, had invaded the

blood stream at the time of the operation. The tissue invasion at this point was slight. After amputation, the bacilli continued to multiply in the tissues of the stump; but the defensive forces were sufficient to prevent extensive necrosis of the tissue and gas formation.

Zone 6. *The Body.*—It is much to be regretted that blood cultures were not made of this case. There must have been a continuous pouring of organisms into the blood stream before the amputation; but it is a question how efficiently the blood defense disposed of them. Klose [8] found that in 60 per cent. of eighty cases of anaerobic wound infection anaerobic organisms were to be cultivated from the blood stream at various stages of the disease, and 51 per cent. of these patients recovered. Therefore, the defense of the body against the persistence of anaerobic bacilli in the blood stream is less than that against anthrax bacilli. On the other hand, the presence of anaerobic bacilli in the blood stream does not indicate so grave a prognosis as does than of anthrax bacilli.

An item of interest lies in the anatomic lesions in the arm. The gelatinous edema of the connective tissue and the black hemorrhages of the muscles were so typical of the lesions produced in the guinea-pig by the oedematiens strain "Joly" that even a very cautious worker would be tempted, especially after finding a large terminal oval spore-bearer and large rods with curved ends, to affirm the presence of that organism. But as far as is ascertainable, a bacillus of the oedematiens group was not present. This type of organism is easily isolated on account of its large colonies. None of the organisms isolated produced in the guinea-pig a black hemorrhagic discoloration like that noted in some of the muscles of the arm. *Vibrion septique* strains produce a less intense coloration in the guinea-pig. The discoloration in the arm muscles must be attributed to the more prolonged action and greater proliferation of *Vibrion septique* organisms in the muscle of a larger and more resistant animal than the guinea-pig. The edema noted in the connective tissue is readily referable to the combined action of the highly toxic edema-producing Reglillus strain and *Vibrion septique.*

The question of the incidence of gas infection in civil life is of interest. Von Hibler [9] lists fifteen strains of *B. welchii* that he isolated from human material. Of these, only two could be called the direct cause of the death of the patient. Both of them were infections after injury. He lists four strains of *Vibrion septique* type isolated by himself; and in three of these cases the organism was demonstrated to be the probable cause of death. He found Novy's bacillus once in a human case, and it was probably the cause of death.

8. Klose, F.: Ein Beitrag zur Kenntnis der durch die Gruppe der gas-oedem Bazillen erzeugten anaeroben Wundinfektion, Münch. med. Wchnschr. **64**:295, 1917.

9. Von Hibler, E.: Untersuchungen über pathogenen Anaeroben, Jena, 1908.

Ghon and Sachs [10] have investigated anaerobic infections occurring in civil life and report various anaerobic invaders.

Cases of anaerobic invasion exclusive of tetanus coming to necropsy in civil life may be classified into two groups. One group is that of patients weakened by sickness or operations who are invaded by their own intestinal bacteria. Such invasions, though they may be, and frequently are, polyspecific, usually have for their chief invader the Welch bacillus. This organism is a common human intestinal saprophyte. Occasionally, Welch bacillus infection follows the injection of drugs into the legs or buttocks. But systemic or local invasions following wound infections, under which head come puerperal infections, especially such invasions as have small foci, are frequently not caused by *B. welchii,* even though the latter organism may be found in the wound. The severity of the tissue destruction and the presence of foreign matter has much to do with the type of invader capable of multiplying in the first hours. The serious wounds caused by high explosives afford far more chance for the growth of *B. welchii* and other muscle feeders than do such cases as the one herewith reported. Welch bacillus infection among animals (except, perhaps, among young sheep) is apparently exceedingly rare, while *Vibrion septique* infection is common. Blackleg infection is found with some frequency among cattle and sheep and oedematiens group infection is noted occasionally among horses. The Medical Research Committee [11] and Sacquépée [12] have miminized the importance of the rôle of the Welch bacillus in war wounds.

The preferred habitat of the anaerobic invaders is of interest. The notable muscle feeders are *B. welchii* and *B. chauvoei.* They may proliferate metastatically, the latter more frequently than the former. *B. welchii* infections may frequently be controlled by excision of infected muscle, while blackleg infections may not. Organisms of the *Vibrion septique* group may feed on muscle, and they frequently do so; but they show a preference for connective tissue and for serous linings, and they also show a remarkable facility for spreading along the lymph and blood channels. Their invasions are, therefore, not to bé controlled by excision of individual muscles as are Welch infections. Many of the organisms of the oedematiens group fail to spread rapidly from the site of inoculation and act by means of toxins that advance far before them. Some strains of *B. novyi* may kill

10. Ghon, A., and Sachs, M.: Beitrag zur Kenntnis der anaeroben Bakterien des Menchen zur Aetiologie des Gasbrandes, Centralbl. f. Bakteriol. **34**:288, 609; **35**:665; **36**:1,178, 1903.

11. Medical Research Committee, quoted by Caulfeild, A. H. W.: B. Perfringens: Toxin and Antitoxin Production, J. Inf. Dis. **27**:151 (Aug.) 1920.

12. Sacquépée, quoted by Caulfeild: Footnote 11, second reference.

guinea-pigs without any invasion at all. Other types, such as the bacillus of Ghon and Mucha and the oedematiens strain "Joly" possess very active invasive powers.

Therefore, it is evident that the prognosis of a gangrenous infection in man or animal depends very much on the specific anaerobes that are present in that process.

The value of persistence and careful observation should be emphasized in the investigation of mixed floras. The careful and scientific investigation of a gas gangrene case takes weeks, not hours. The bacteriologist who amiably complies with the clinician's impetuous demand for a diagnosis will usually have to reverse the diagnosis or change it several times. The bacteriologist who contents himself with finding in an invaded tissue Welch bacillus or *Vibrion septique* and who makes no effort to look farther adds nothing to the sum of human knowledge. There are plenty of pathogenic anaerobes still undiscovered. True, it is rare that unusual types invade alone; but unusual pathogens are worth isolating, studying and describing.

For the bacteriologist who is besieged by the clinician, anxious for the life of his patient, the following suggestions may be made. The generous administration to the patient of mixed Welch-vibrion septique-oedematiens serum should be suggested. Smears should be made and cultures taken from affected tissue remote from the wound. Guinea-pigs should be inoculated with fluid drawn aseptically from such tissue. If specific anaerobe antiserums of the three important types are available, three guinea-pigs should be protected, each with two serums in different groupings and all three of them should be inoculated in the thigh with tissue fluid, not with wound exudate, from the patient. In from twelve to eighteen hours, an answer of some value concerning the presence or absence of some one or two of the three important types may be formulated. This procedure is recommended by the British Medical Research Committee.

SUMMARY

The case herewith reported emphasizes the importance of bacteriologic examination early in compound fractures, even in civil life, by one especially skilled in anaerobic work. It shows also that all cases of compound fracture should be under observation in a hospital for at least the first two days after injury.

This case of gas gangrene, which was due to an infected compound fracture of the forearm, was diagnosed before amputation as a Welch bacillus infection.

Four anaerobic bacilli capable of rapid invasion in the guinea-pig body were isolated from the amputated arm. *B. welchii* had not invaded such tissue as was supplied with circulation. The principal invader

was *Vibrion septique,* which nearly caused the death of the patient after the amputation. There were two anaerobic bacilli that are guinea-pig invaders which are apparently new. No cocci or aerobic rods were present in the wound or surrounding tissue.

The area about the fracture had not been exposed to very dirty conditions, nor was a visible amount of foreign material introduced into the small wound made by the broken bone. There was, however, comminution of bone which may have had not only a mechanical but a chemical influence on the multiplication of the bacteria that were introduced into the neighborhood of the fracture.

A careful study of the process of invasion by anaerobic organisms in gas gangrene cases, a labor well nigh impossible in most war laboratories, is advisable when time and facilities for the study of anaerobes are available.

ARCHIVES OF SURGERY

VOL. 4 MAY, 1922 No. 3

A REVIEW AND CLASSIFICATION OF BONE SARCOMAS

JAMES EWING, M.D.
NEW YORK

The knowledge of tumors of bone and bone marrow is still in the descriptive stage. To reach a correct histologic diagnosis of the case and to provide some conception of the probable clinical course are all that can be expected at the present time, and often more than is accomplished. The separation of the numerous tumors of this group into well-defined clinical and pathologic entities is far from complete, while knowledge of the exact origins of these tumors and of their various exciting and contributing causative factors is extremely fragmentary, or, indeed, wholly lacking. Moreover, with the present trend of medical research, the prospects are not favorable to important progress in this field. Serology, immunology, chemistry, studies in nutrition, and the use of modern instruments of precision have contributed little and promise little in the study of bone tumors. Abundant clinical material, wide clinical experience, and knowledge of the embryology, physiology and pathology of bone, are the more essential qualifications for successful investigation in this field.

Such studies call for clinical observation by the surgeon, and morphologic research by the pathologist, by each of whom the work must be carried out on a broad and systematic plan. The surgeon must provide complete clinical pictures of the different neoplastic diseases of bone; and the pathologist must discover the origin, the predisposing anatomic conditions, the mode of growth, and the general etiologic factors, if an effective knowledge of these diseases is to be attained. When this knowledge has been secured, it will still be necessary to devise means for its dissemination so that it may become effective in controlling the mortality and possibly the incidence of these diseases.

For this purpose a uniform nomenclature is highly desirable or essential; and the main clinical and morphologic features of the different bone tumors must be clearly presented in accessible form. The present article is intended as a contribution toward this end.

CLASSIFICATION OF TUMORS OF BONE AND BONE MARROW

In the legitimate classification of tumors of bone only those neoplastic diseases which clinical experience shows to actually occur must be

recognized. To divide the tissues into their constituent cells and to classify tumors blindly according to the possible cells of origin is unsound and unserviceable. Most tumors are not simple structures composed of a single cell, but are complex and become simple growths only in anaplastic metastases. Moreover, the tumors do not develop at random. They arise under quite definite conditions, which usually determine their course, and these conditions must be considered in a classification. The classification must be both clinical and anatomic. If a central chondrosarcoma arises from an aberrant superfluous island of cartilage misplaced by a rachitic process, then this disease may be recognized as a specific entity. If an osteogenic sarcoma arises at an epiphyseal line from traumatic partial separation of the epiphysis, or because of some structural defect, it also becomes a specific entity which deserves to appear in classification. On the other hand, if in the foregoing examples, considerable variations in structure of the tumors are observed in different cases which run much the same clinical course, it is unwarranted to subdivide such tumors because of minor structural variations, since they remain essentially the same diseases in origin, course, and general significance. The practice of designating bone tumors simply as round, spindle, or giant cell is quite inadequate to define the disease properly. Nearly all malignant tumors show all these types of cells at different periods or in different portions. When, however, the disease has been identified, for example, as osteogenic sarcoma, the further designation of cell type (spindle, etc.), is useful to indicate the degree of anaplasia or potential malignancy of the tumor. To a considerable extent, it is possible to classify bone tumors according to the foregoing plan, while increasing knowledge will serve to correct errors as they come to light. Only such a classification will be of service to both clinician and pathologist. Accordingly, one may recognize the forms of neoplastic diseases originating in bone and bone marrow given in the accompanying classification.

Classification of Bone Tumors

Osteoma	Spongy Ivory	
Chondroma	Pure chondroma Chrondromyxoma Myxoma	Capsular Periosteal Central
Angioma: Cavernous		
Endothelioma	Angio-endothelioma Diffuse	Solitary Multiple
Benign Central Giant Cell Tumor and Its Variants	1. Bone cyst 2. Giant cell tumor 3. Xanthosarcoma 4. Myxosarcoma (benign)	

Osteogenic Sarcoma
- Periosteal (extraperiosteal)
- Solid medullary and subperiosteal
- Telangiectatic
- Sclerosing

Myeloma
- Plasma cell
- Lymphocytic
- Myelocytic
- Erythroblastic

The inclusion of pure myxoma under the heading chondroma appears to be indicated because of the great probability that all pure myxomas of bone are derived originally from cartilage. The myxomas may be more difficult to eradicate surgically than chondromas but they do not exhibit any greater potential malignancy. Under the benign giant cell tumors, which must usually be regarded as sequelae of osteitis fibrosa cystica, are included for convenience sake, simple bone cysts. These lesions are not tumors; but Martland has shown that the simple cyst may result from the spontaneous degeneration and softening of a giant cell tumor.

The existence of telangiectatic osteogenic sarcoma as a distinct disease has not yet gained general acceptance. However, I am convinced that this lesion is one of the most specific of bone tumors, both in its gross anatomy and in its clinical course. One type of malignant bone aneurysm is a vascular osteogenic sarcoma. Its possible relation to cavernous angioma must be considered. In spite of recent contributions to the contrary I believe that the existence of four specific types of myeloma is firmly established. Wallgren,[1] however, concludes that all myelomas arise from a single primitive marrow cell. Of the groups of tumors mentioned above, I shall discuss only the cellular forms in the present paper.

Outline of the Clinical, Anatomic and Structural Features of Some Common Bone Tumors

Endothelioma

The knowledge of endothelioma of bone has reached a stage which calls for definite recognition of this disease. The condition is generally submerged under the general diagnosis of round cell sarcoma or myeloma, since both are composed of small diffusely growing cells with round nuclei. Having seen ten cases within the past year, I cannot regard it as a rare disease. Three anatomic forms may be recognized: (1) multiple endothelioma; (2) solitary angio-endothelioma, and (3) diffuse endothelioma.

1. Multiple endothelioma, in which nearly every bone in the body was the seat of small medullary tumors, occurred in a remarkable

1. Wallgren: Virchows Arch. f. path. Anat. **232**:331, 1921.

case described by Marckwald. It is the only recorded case of its kind. Symmers and Vance [2] have described a somewhat similar case, and multiple tumors in much smaller numbers have often been observed. In several of the cases collected by Howard and Crile, there were

Fig. 1.—Angio-endothelioma of bone.

multiple tumors. Whether the several tumors were primary or secondary and metastatic from one original growth cannot be determined; but multiple primary tumors undoubtedly occur. They appear in adults

2. Symmers, D., and Vance, M.: Am. J. M. Sc. **152**:28 (July) 1916.

and nearly all have been fatal. Metastases in lungs and lymph nodes occur. It does not appear that any have been treated by modern roentgen-ray technic. The diagnosis rests on the roentgenogram, which shows multiple central tumors with diffuse absorption of bone. Multiple myelomas are much more numerous and sharply perforate the bone. The structure consists of endothelial-like cells in small groups or sheets, often forming alveoli and sometimes cysts containing serous or mucinous fluid.

Wells has recently described a multiple endothelioma in which isolated small groups of cells, similar to those described by Marckwald, appeared, which seemed to be derived from the blood vessels of atrophic and mucinous bone marrow.

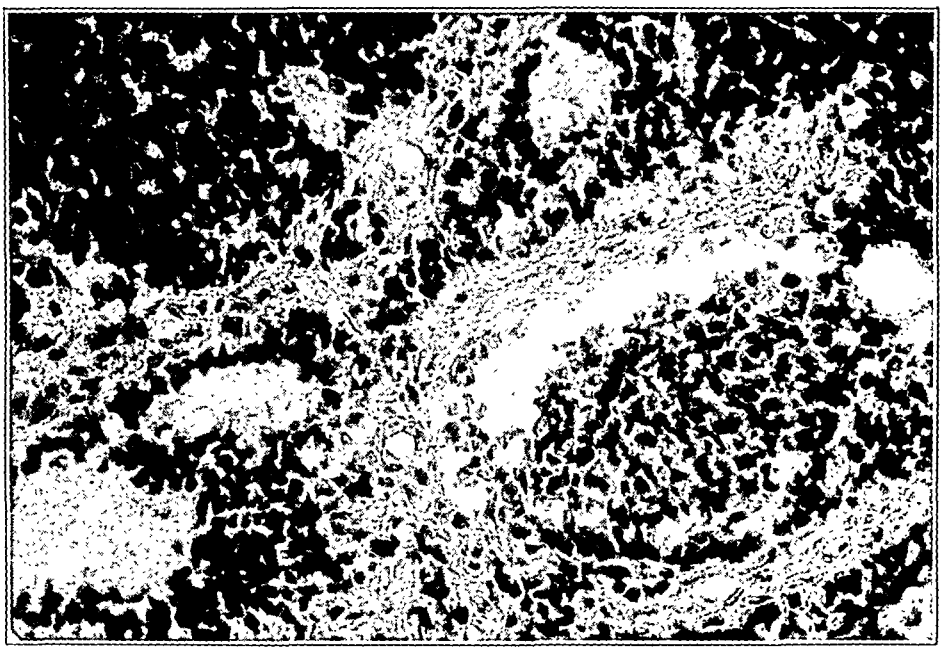

Fig. 2.—Structure of angio-endothelioma of bone.

2. Angio-endothelioma usually appears as a single tumor which sharply and completely destroys the bone and often reaches large dimensions (Fig. 1). Its expansile pulsation places it among the malignant bone aneurysms. The roentgen ray shows a clean cut destruction of bone by a central tumor which displaces and eventually invades the soft parts. There is no bony capsule and the periosteum is free. This disease returns after amputation and produces metastases. It grows much more rapidly than the benign central giant cell tumor, but can hardly be distinguished from telangiectatic sarcoma on clinical and roentgen-ray evidence. From the ordinary osteogenic sarcoma it differs in that it fails to show a wide zone of involved periosteum extending beyond the main tumor mass. These differences are rendered obvious by a comparison of the photographs of gross specimens with roentgen-

ograms. The structure is highly characteristic, consisting of large clear endothelial cells in cords and columns inclosing circulating blood (Fig. 2). The subjects are chiefly adults.

3. Solitary diffuse endothelioma occurs in young subjects, all of my patients being under 21 years of age, five of them being 14 years old. The bones involved were: ulna, twice; radius, once; tibia, twice; scapula, once; skull, once; pubes, twice, and femur, once. It begins slowly, with pain and gradually developing disability. After several months, spontaneous fracture may occur. Transient variations in size of the tumor have been noted and may prove very deceptive both to the patient and to the physician. One patient died from metastases after amputation. Another developed multiple tumors of the skull. Bence-Jones protein was found in one case only. The tumors develop in the marrow or in the bone or in both. The shaft is widened and slowly absorbed without a trace of bone production. The soft tissues are gradually invaded. The most striking feature, best revealed by the roentgen ray, is the involvement of a large segment or the whole of the shaft, which distinguishes the process from osteogenic sarcoma and the giant cell tumor. This location, together with the smooth fading of a slightly widened shaft, generally permits a diagnosis from the roentgenogram alone (Fig. 3). The differential diagnosis from the benign giant cell tumor and from osteogenic sarcoma is assured if the tumor recedes rapidly under roentgen-ray or radium treatment. True myelomas, however, may respond in the same manner. The structure presents diffuse sheets of small polyhedral cells with clear cytoplasm, without intervening stroma, often undergoing mucoid or hydropic degeneration (Fig. 4). Zenker's solution best preserves the cell form. After poor fixation, the tissue resembles that of a myeloma or "round cell sarcoma." That the cells are endothelial is shown by the appearance in some cases of many spaces lined by tumor cells and filled with intact blood. The structure may approach that of angio-endothelioma or it may verge on myeloma. Plasma cells are absent or scanty and uncertain; but the possible relation of this tumor to plasma cell myeloma remains to be determined.

The importance of recognizing this tumor lies in the fact that amputation is probably unnecessary, because the tissue is remarkably susceptible to the roentgen ray and radium. The prognosis is, however, complicated by the occurrence of multiple tumors and metastases. One of my patients died with multiple tumors of the skull which were believed to be primary, and another is said to have died with pulmonary metastases after amputation of the arm.

The comparative frequency of this disease renders it one of the most important of bone tumors. Since the structure is quite different

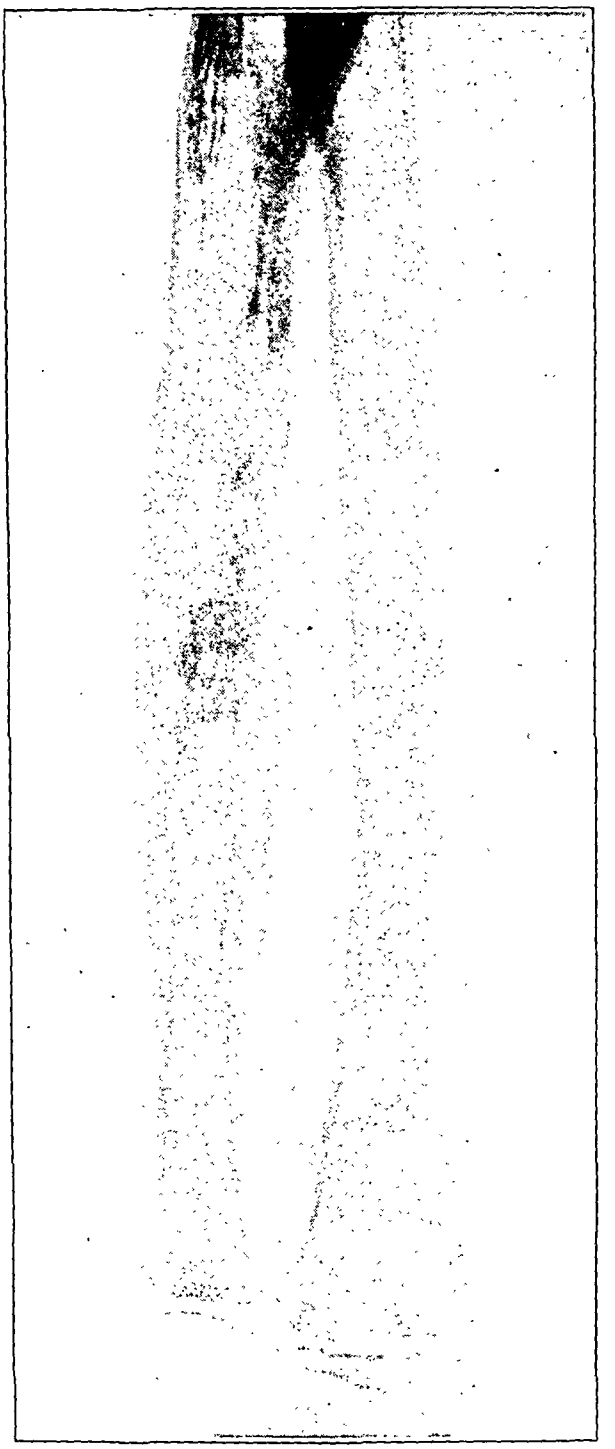

Fig. 3.—Diffuse endothelioma of ulna.

from that of the easily recognized endotheliomas with blood channels, alveoli and cystic spaces, it appears clear that the cases are not recognized as endothelioma, but are classed as round cell sarcoma or myeloma. Since solitary myeloma is not a frequent diagnosis, most of the cases probably pass as round cell sarcoma. Unless the pathologist is familiar with the structural details of diffuse endothelioma, he will invariably render a diagnosis of round, or possibly small, spindle cell sarcoma, or myeloma, in these cases. I have been making this error myself for many years, although I was long aware that the tumors did not correspond to any known form of bone cell or bone marrow cell neoplasm. That the tumors are not osteogenic sarcoma became apparent when their prompt recession under radium was

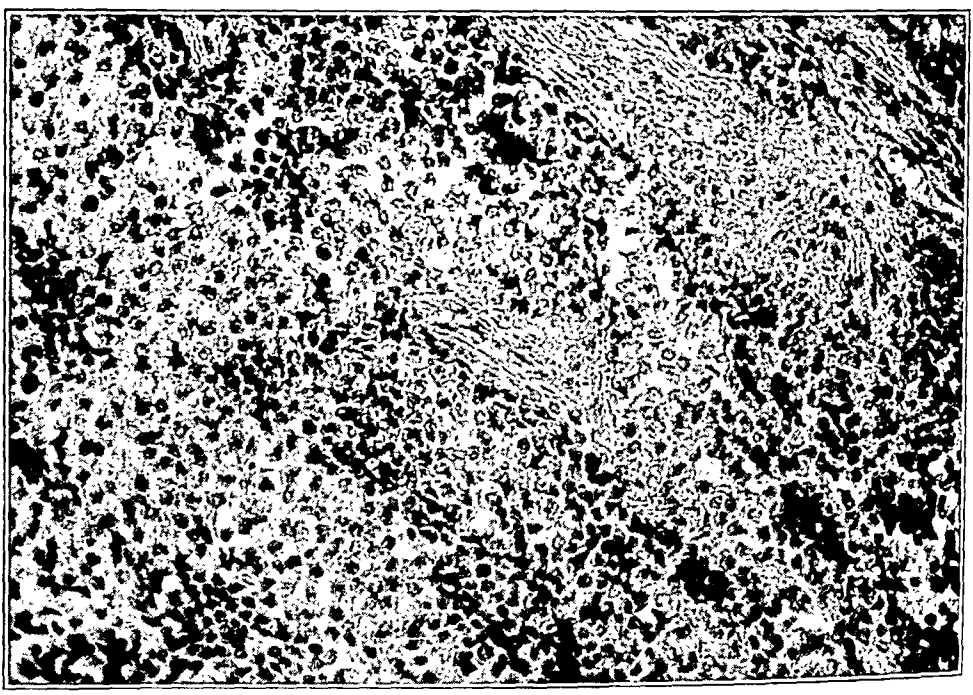

Fig. 4.—Diffuse endothelioma of bone; showing compact structure of large polyhedral cells.

observed, for oseogenic sarcoma reacts slowly to radium. That the growths are of endothelial nature was strongly suggested by the appearance of broad sheets of clear polyhedral cells without a trace of intercellular stroma. This origin was finally demonstrated by the observation of a case in which the usual diffuse structure was present in much of the material removed at exploratory operation, while in other portions the growth was composed exclusively of blood spaces filled with intact blood and lined by large clear endothelial cells.

The apparent limitation of the disease to young patients is one of its most interesting and suggestive features. Of the twenty cases of

endothelioma collected by Howard and Crile,[3] three occurred in patients under 20 years of age. One of these in the femur of a girl of 9 years, with other tumors in the skull, approached in structure the diffuse type, the blood spaces being lined by from five to ten rows of cells. In Kolaczek's patient, 18 years of age, a very large tumor of the tibia was in part composed of spindle cells, and in part of alveolar endothelioma. Crile's patient, at 11 years, showed alveoli and well defined lymph spaces. As Crile points out, the angio-endotheliomas occur with few exceptions after the period (40 years) when osteogenic sarcoma is most frequent. They often develop in patients of quite advanced years, 50 to 75, when osteogenic sarcoma is practically unknown.

These observations regarding age incidence throw no light on the nature of the underlying conditions in the bone and marrow which lead to endothelioma; but they show that endothelioma yields somewhat different results at different periods of life.

Much further exploration of the dark territory of the general pathology of bone and bone marrow is needed before one can formulate any hypothesis regarding the conditions of origin of these tumors. Most of the young subjects show a secondary anemia, without specific characters. Usually the skeleton is delicately built. A history of rickets or scurvy or other notable disorders of childhood has not been elicited. Six of my ten patients were Jews. One was very fat, as were also his two brothers. Signs of status lymphaticus were not definitely present.

Regarding the choice of treatment of this disease, I wish to emphasize the caution, that, while the diffuse endotheliomas of young subjects have proved uniformly susceptible to heavy radium packs and to repeated applications of roentgen ray, sufficient time has not elapsed to determine the final outcome of this treatment. The tumors tend to recur unless treatment is continued over a long period. The danger of metastases during treatment must be considered. On the other hand, the tendency to produce metastases appears to be less prominent than in the case of osteogenic sarcoma. Many of the multiple tumors are probably primary, so that amputation is often futile. Hence it seems justifiable or even strongly indicated to immobilize the member and attempt to save the limb or life by physical therapy. If this plan is adopted, it is highly important to avoid incision into the tumor. The diagnosis can generally be made on the clinical history, the peculiar roentgenogram, and the early response to radium. It may be of interest to note that competent observers firmly maintained that some of my cases were osteomyelitis, while one patient was persistently treated with arsphenamin.

3. Howard and Crile: Ann. Surg. **42**:358, 1905.

BENIGN GIANT CELL TUMOR AND ITS VARIANTS

In 1852, Nelaton and Robin, in a well illustrated monograph, clearly pointed out the gross, microscopic and clinical features of this benign *tumeur à myeloplacques,* contrasted it with the malignant osteogenic sarcoma, and urged conservative treatment. Gross, also, in 1868, clearly described the disease and recognized its benign nature. These contributions seem not to have been widely read; but several later writers, especially in America, have described the disease and discussed it as an important novelty. It is quite apparent also that many surgeons and pathologists are still unfamiliar with the important differences that separate this disease from osteogenic sarcoma, so that many limbs have been unnecessarily sacrificed and many supposed bone sarcomas have been erroneously assumed to be operative cures.

The knowledge of the clinical and morphologic characters of the common benign central giant cell tumor we owe chiefly to Nelaton and Robin; but it has long been felt that the scope of these tumors is inadequately defined. Some of them do not behave like benign neoplasms. Gross believed that he observed violations of the rule that they never produce metastases. Many of them recur after operation and infiltrate the soft tissue or even break into the joints. Also the microscopic diagnosis occasionally presents serious difficulties, even for the experienced observer. It is the variants of the disease which give rise to difficulty.

The typical forms of the disease seem to find their origin mainly in the changes produced by osteitis fibrosa cystica; and the simple bone cyst is usually found as a part of localized osteitis fibrosa. Osteitis fibrosa affects one or many bones and produces a change in the marrow marked by diffuse overgrowth of spindle cells, loss of hematoblastic and fat cells, absorption of cancellous tissue and often thinning of the shafts. About the dissolving bone trabeculae and along the inner surface of the shaft, numerous giant cells are often found. Cysts form in the new tissue, and these may be lined by giant cells and filled with serous fluid. Hemorrhages readily occur in the cysts and the inflammatory reaction about these blood masses leads to the growth of granulation tissue in which are often many giant cells and disintegrating bone. In some such manner the ordinary giant cell tumor probably develops; but it must be admitted that the exact mode of origin of the simple tumors has never been certainly traced. Martland[4] has shown that simple cysts may result from the liquefaction of previous giant cell tumors. I have evidence that some giant cell tumors result from the absorption of aberrant islands of cartilage with neoplastic proliferation of the released cartilage cells, and others. It appears

4. Martland, H. S.: Proc. New York Path. Soc. **21**:102, 1921.

Fig. 5.—Benign central giant cell sarcoma, epulis type; showing limiting shell of bone and multicystic appearance.

also that any simple hematoma of bone marrow may lead to the production of granulation tissue with many giant cells. Barrie's designation "hemorrhagic osteomyelitis" would not be inept for some of these processes if it did not suggest an intense inflammatory reaction. This array of possible initiatives of the peculiar tumor tissue is not inconsistent with the variety of clinical conditions under which the disease is observed. The benign giant cell tumor is of wide occurrence as respects age, location, multiplicity, and previous history of the patient, and it is unlikely that it always arises under identical conditions.

1. *Typical Benign Central Giant Cell Tumor.*—This is a characteristic condition. It occurs usually as a single tumor in one end of the tibia, fibula, humerus, femur, lower jaw, or lower end of the radius, or in the flat bones. It progresses slowly, with pain, swelling and disability. Spontaneous fracture may result. The soft parts are displaced. It usually begins near the epiphyseal line, where the cancellous tissue is absorbed and the shaft widened by a globular mass. A thin, sometimes crackling, shell of bone is regularly laid down about the advancing tumor.

The roentgenogram shows a multicystic appearance, with destruction of the shaft, an irregular deposit of outlying shell of bone and sharp limitation from the soft tissues. Occurring in the middle of a long bone, there may be a sharp irregular fracture with comparatively little widening. Beyond the tumor the periosteum is unaffected (Figs. 5 and 6).

On gross examination such tumors are nearly always found to be cystic; or the central portion is diffluent and filled with blood detritus, chocolate colored fluid, or clear serum. The texture of the growth is that of soft, reddish, vascular granulation tissue, becoming more and more dense toward the periphery.

The structure shows an abundance of giant cells with many small separate nuclei. They appear in masses or they surround capillaries or blood spaces. They are derived from the vascular endothelium but participate in the tumor process, sometimes extensively. The stroma is composed of many capillaries supported by a moderate number of spindle fibroblasts with nuclei showing normal or slightly increased chromatin (Fig. 7). Tumors of this type are always strictly benign, in the oncologic sense, although they may lead to serious clinical disturbances. They may be cured by curettage, by roentgen ray and radium, and some of them disappear spontaneously. They may become transformed into simple cysts. They are prone to become infected from curettage or exploratory incision, and a progressive cellulitis and osteomyelitis may develop. The wide cavities left after curettage may offer some surgical problems.

Fig. 6.—Benign giant cell tumor of upper end of tibia; collapse of joint surface without invasion of joint cavity; infection through line of diagnostic incision.

2. *Xanthosarcoma.*—Some of the central giant cell tumors of bone are solid throughout, firm, dry, and yellow. The yellow color is due to the presence of many large polyhedral cells distended with lipoid granules. This is a structure commonly designated as xanthoma (Fig. 8). These tumors have greater growth capacity than the ordinary giant cell tumor. They often reach considerable size, breaking down the bony capsule and forcing their way between muscle and fasciae, but definite infiltrative growth is rare. They may destroy the epiphysis and lead to collapse of the joint surface. The roentgenogram reveals an incomplete bony capsule, or none.

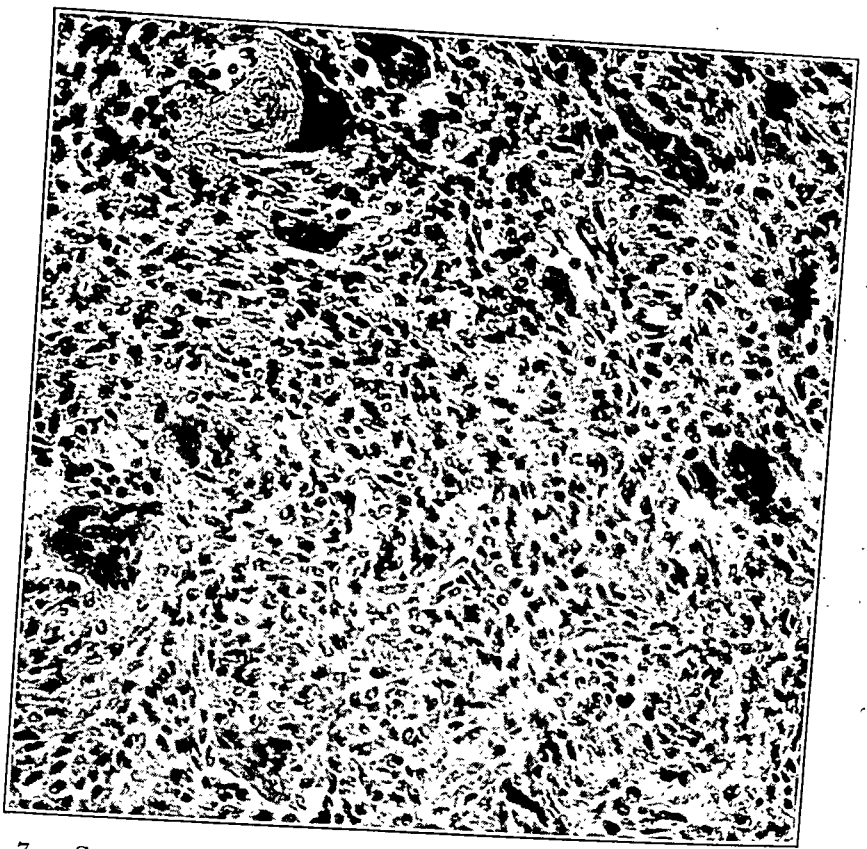

Fig. 7.—Structure of benign giant cell tumor; polynuclear giant cells lying among spindle and polyhedral cells; slight hyperchromatism of nuclei.

The structure presents a diffuse growth of medium sized spindle cells with very little hyperchromatism. Varying proportions of the tissue are composed of the lipoid cells. Giant cells are missing over large portions of the growth; but usually they appear abundantly in some portions, generally about blood spaces or blood extravasations. If the histologist encounters only the spindle cells, an erroneous impression of a malignant tumor is liable to be gained.

These tumors are prone to recur after curettage, especially when large, owing to the difficulty of reaching all portions of the growth.

Infection is also a frequent complication which results in the loss of many limbs and of some lives. They slowly respond to roentgen-ray and radium treatment; but one who chooses this method of treatment must plan to restrict the motion of the part and devote some months to the treatment. Immobilization reduces blood supply, avoids the danger of fracture, and permits weakened joint surfaces to remain intact.

I have never known these tumors to produce metastases, and I have been unable to find authentic records of such complication; but it seems quite possible that by curettage groups of viable cells could be dislodged from the tumor and pass into the blood vessels. However,

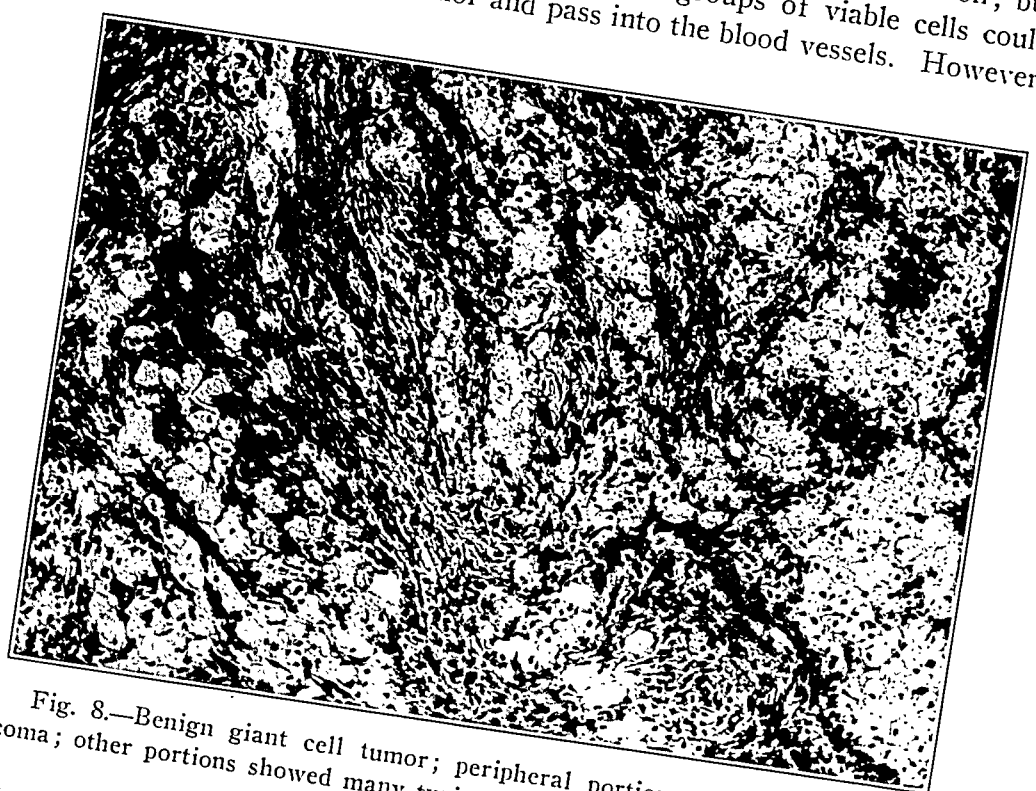

Fig. 8.—Benign giant cell tumor; peripheral portions showing xanthosarcoma; other portions showed many typical giant cells of epulis type.

the blood vessels are usually small and scanty, and the danger of metastases can probably be ignored.

That the central xanthosarcoma of bone is a variant of the giant cell tumor is clearly indicated by the clinical history, central location, general structure, the course of the growth as revealed by the roentgen ray, and by the not infrequent occurrence of xanthoma cells in typical giant cell tumors. In the benign tumors of tendon sheaths xanthoma cells are generally prominent.

3. *Myxosarcoma.*—The peripheral portions of many giant cell tumors are often composed of solid elastic opaque tumor tissue of myxoma-

like structure, while the central area alone is soft and vascular and contains the characteristic giant cells. Even this central area may be reduced to a minimum, and nearly the whole tumor may be composed of solid opaque tumor tissue in which there are many spindle cells lying in a mucinous matrix (Fig. 9). Although the central location and rather sharp limitation of the growth strongly indicate a benign character, the histologic structure with many spindle cells suggests malignancy, and this impression may be strengthened by reliance on frozen sections. However, these central tumors are benign and their



Fig. 9.—Benign giant cell tumor; peripheral portions composed of large spindle cells with clear cytoplasm; other portions showed giant cells of epulis type.

virtual identity with the ordinary giant cell tumor is shown by the gross transitional forms which connect the two types and by the presence of typical giant cells which may be seen in some parts of the tumor. They are quite different in structure from the fascial myxosarcomas and from any myxomatous areas of osteogenic sarcoma.

In some cases the main tumor cell is large and spindle or polyhedral in form with vesicular nucleus, while giant cells are scanty. These spindle cells lack the hyperchromatism of the malignant osteogenic tumors. Numerous small lymphocytes may also appear diffusely or in clusters, which are probably derived from the lymphoid marrow and which are almost never seen in malignant sarcomas (Fig. 10).

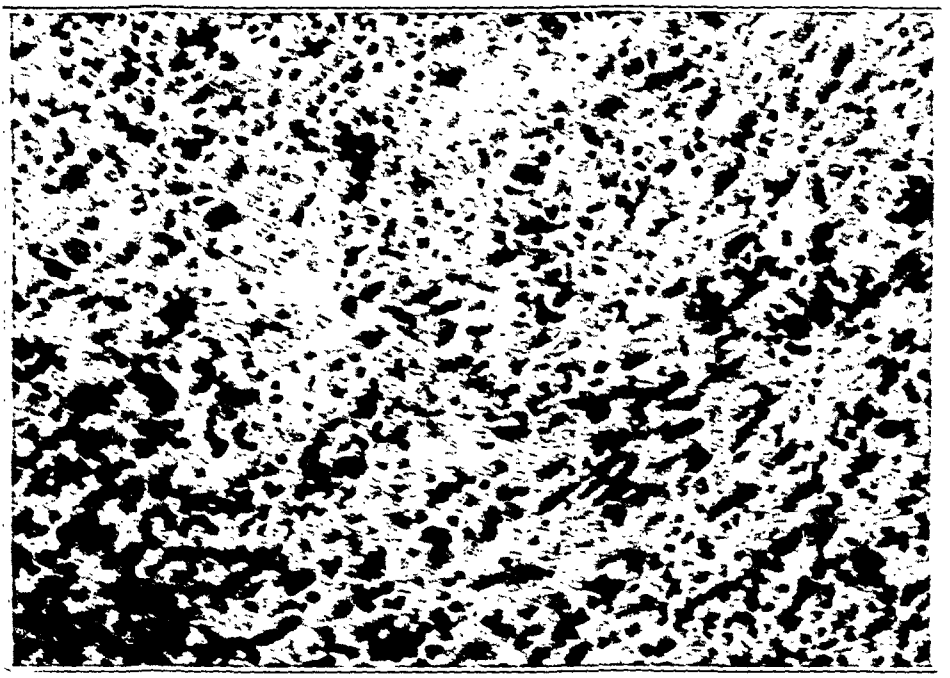

It seems probable that these growths represent a vigorous proliferation of tissue cells about degenerating cartilage. Probably the cartilage cells participate in this process as well as the endothelial and possibly other marrow cells. That the absorption of cartilage may be connected with other giant cell tumors in which no traces of cartilage or their peculiar derivatives are present, deserves, perhaps, further consideration. From their cellular character, one gains the impression that these tumors must be more malignant than the others; but several patients whom I have followed recovered after curettage. Being cellular they should be susceptible to radium and roentgen ray.



Fig. 11.—Benign central giant cell tumor with island of dissolving and partly calcified cartilage.

5. *Telangiectatic Giant Cell Tumors.*—In 1894 a portion of a central giant cell tumor was submitted to Dr. T. M. Prudden at Columbia for diagnosis and prognosis. It came from a growth which occupied a large lower segment of the shaft of the tibia in a girl, aged 14 years. The tumor was described as extremely vascular. After much discussion, on account of the presence of numerous typical giant cells, the tumor was pronounced benign. Curettage was recommended and performed. Several years later we were informed that the patient recovered, and that her leg was sound.

The structure showed very wide blood spaces separated by thin strands of spindle cell tissue lined by many giant cells. The spindle cells resembled those of the ordinary giant cell tumor.

That the course of central telangiectatic tumors with giant cells is not always favorable is shown by a case illustrated by Figures 12 and 13. The subject was a child of 10 years, in whom the head of the humerus was completely excavated by a bloody mass in which no tumor tissue could be detected on gross examination. Section revealed thin strands of tumor tissue composed of spindle cells with hyperchromatic nuclei. These inclosed wide blood spaces lined by numerous giant cells with multiple small nuclei which again were relatively hyperchromatic. Interscapular-thoracic disarticulation was performed; but the patient

Fig. 12.—Telangiectatic osteogenic sarcoma of head of humerus; malignant bone aneurysm, in a child of 10 years; pulmonary metastases.

is said to have died of pulmonary metastases four months later. This was not confirmed by necropsy. This case may well be classed as a malignant bone aneurysm. On account of this observation it seems proper to urge that more attention should be paid to the main tumor tissue than to the giant cells in the diagnosis of doubtful cases of this type.

6. *Borderline Cases of Giant Cell Tumors.*—Some bone tumors, mainly central in location, are found to have involved much of the neighboring bone shaft which is eroded or perforated, while the tumor tissue early penetrates the soft tissue and fails to throw out a uniform

limiting shell of bone. This anatomic condition is not easily distinguished in the roentgenogram from some osteogenic sarcomas; but careful palpation, roentgenograms taken from several angles, and surgical exploration reveal an absence of the extensive involvement of periosteum which is nearly constant in osteogenic sarcoma. The periosteum in these cases is generally quite intact beyond the main tumor mass.

The structure consists of numerous rather large spindle cells with vesicular nuclei which exhibit some, but not pronounced, hyperchromatism. Intercellular strands are scanty or absent. By hydropic imbibition the cells may appear polyhedral. Giant cells are scanty or absent in many areas but appear in groups, often in the clefts or

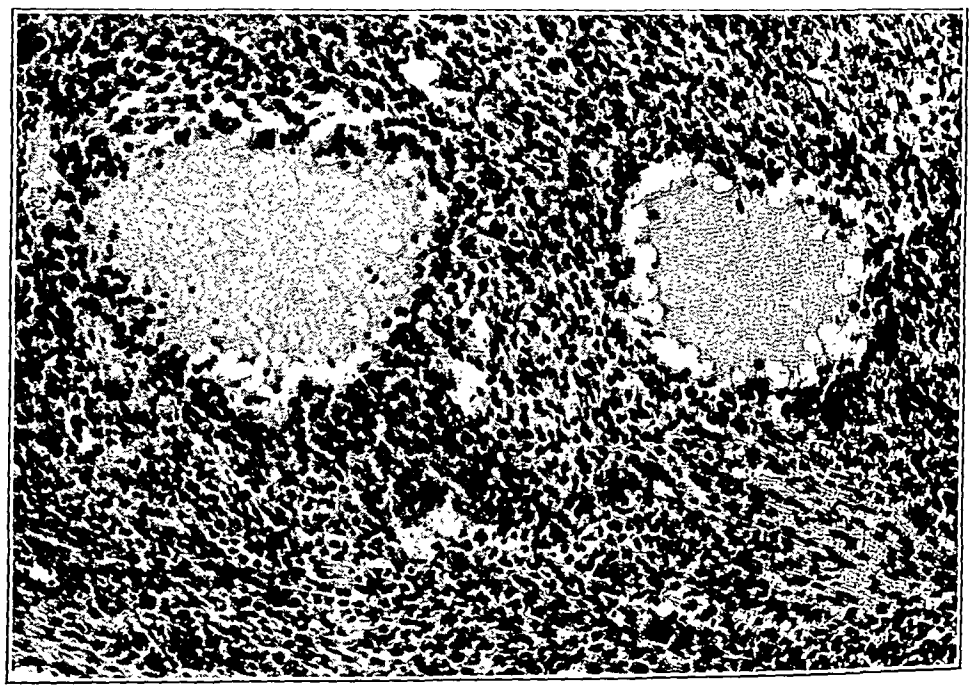

Fig. 13.—Structure of a telangiectatic osteogenic sarcoma; tissue from the outer shell of a highly vascular tumor; round and spindle cells with hyperchromatic nuclei enclosing blood sinuses; same case as Figure 12.

sinuses of tumor tissue. They are not so large as the giant cells of the ordinary giant cell tumor, and the nuclei, while multiple, are larger and more hyperchromatic. The diagnostic difficulties are increased when only curetted fragments of the tumor are available. Such tumors offer a difficult problem for the pathologist and for the surgeon. My colleagues and I have adopted the policy of designating these tumors as borderline tumors of the giant cell type and of giving a guarded prognosis. They are prone to recur after curettage; but I have not known them to produce metastases even after repeated insults.

While they probably belong with the benign giant cell tumor and are connected with the absorption of bone or cartilage, it seems possible that osteoblasts may participate in the proliferation and endow the process with more aggressive qualities than belong to the strictly benign tumors (Fig. 14).

7. *Secondary Giant Cell Structure in Malignant Osteogenic Sarcoma.*—Since the peculiar giant cells of the benign tumor occur whenever bone is being absorbed and since these structures signify in general a type of foreign body giant cell, one should be prepared to find them in malignant osteogenic tumors surrounding blood extravasations, or following infection, or surgical trauma. Under such

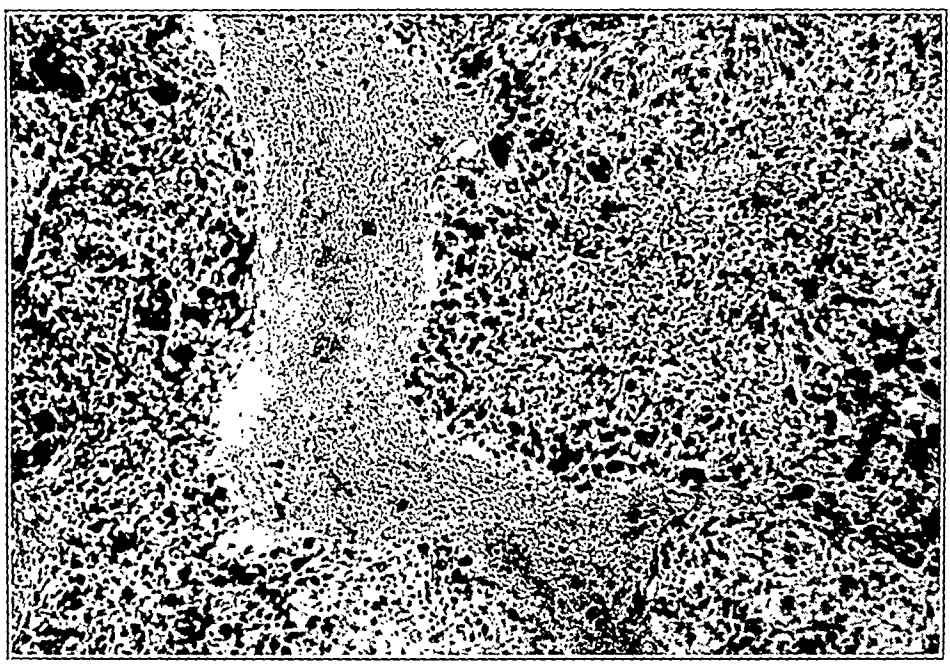

Fig. 14.—Benign giant cell tumor, low magnification; giant cell with many compact nuclei; polyhedral and spindle cells; many small lymphocytes.

conditions they not infrequently appear in malignant tumors and may lead to an erroneous diagnosis by the pathologist when only small portions of tissue are available. These and other considerations have led me to take the position that cutting into bone tumors and removing a small piece for diagnosis is generally hazardous. The diagnosis of bone tumors can safely be attempted only when all of the clinical history and roentgenograms are available. With such data carefully analyzed, the probatory incision is usually found to be unnecessary; and it is not too much to say that the gross anatomy of the lesion is often a safer guide to a correct clinical conception of the disease than the variable and uncertain structure of a small piece of tissue. Doubt-

less there are cases in which both classes of evidence are needed; but they constitute a minority of the group and the microscopic evidence is often indecisive.

The foregoing review of the conditions under which giant cells of the epulis type may be found in bone tumors reveals the difficulties which surround microscopic diagnosis in this field. When the giant cells form the major portion of the tumor, the process is almost invariably lacking in aggressive growth and clinical malignancy; but when they become scanty and are associated with many spindle cells and compact polyhedral cells, the tumors as a rule are more aggressive, while in some cases in which the giant cells are associated with other, more numerous, tumor cells of malignant histologic character the tumors, as in the malignant bone aneurysm cited, are quite malignant. In addition, there is the occasional occurrence of epulis giant cells in inflamed and degenerating osteogenic sarcoma. Under these circumstances, it seems desirable to restrict the importance of the presence of giant cells in the diagnosis of bone tumors, and to emphasize more strongly the importance of the main tumor cells. Furthermore, it seems probable that further study of the origin of these benign central tumors will lead to the definite subdivision of the group based on exact histogenesis and general etiology. The demonstration of a group of these tumors as probably derived from the absorption of cartilage is perhaps a step in this direction. The xanthomatous tumors also are peculiar in many respects and suggest that they too enjoy some peculiar conditions of origin. Osteitis fibrosa seems to be associated only with the benign vascular cystic tumors composed chiefly of giant cells of large size.

A more satisfactory term should be found to designate this group of tumors, and one which lays less emphasis on the giant cells. Central osteogenic sarcoma or benign central sarcoma may be suggested as worthy of consideration.

OSTEOGENIC SARCOMA

Of this, the main malignant tumor of bone, four distinct groups should be recognized, because of their peculiar gross anatomy, microscopic structure and clinical course. These are: (1) periosteal sarcoma; (2) subperiosteal and medullary sarcoma; (3) telangiectatic sarcoma, and (4) sclerosing osteogenic sarcoma.

I have previously urged the recognition of only three groups of osteogenic sarcoma, merging the first two groups of the present list for the sake of simplicity; but the facts demand the sacrifice of simplicity in the interest of more accurate knowledge. A large number of bone tumors are *extra*periosteal, while many others are *sub*periosteal and invade or originate in the marrow cavity. On dissection these tumors are found to be quite different in gross anatomy; in structure,

Fig. 15.—Malignant ossifying extraperiosteal sarcoma, which produced pulmonary metastases.

they are quite divergent, and the clinical courses are far from parallel. These contrasts suggest essential differences in the conditions of origin of the tumors.

1. *Periosteal Sarcoma.*—The extracortical position of these tumors is quite characteristic. In fact, the true periosteal sarcoma appears to originate from the periosteum itself or from the outer layers, leaving

Fig. 16.—Extraperiosteal osteogenic sarcoma; same case as that shown in Figure 15.

the bone shaft intact or slightly eroded, whereas other osteogenic sarcomas are subperiosteal and grow beneath the periosteum, separating it from the shaft over a wide area by a fusiform mass of cellular tumor tissue. These relations are indicated in the accompanying sketch (Fig. 20), and they become quite apparent in Figures 15, 16, 17 and 19.

Fig. 17.—Malignant spindle cell extraperiosteal and capsular sarcoma, fungating through the skin at line of diagnostic incision; infection with rapid enlargement from inflammatory edema.

The roentgenogram shows an intact or slightly eroded shaft running through a solid tumor mass which lies at one side and which is attached to a segment, often narrow, of the periosteum. Some of these tumors arise mainly from the capsule of the joint, but a pure capsular sarcoma is rare.

The small area of periosteum involved and the firm encapsulation frequently observed suggest that in such cases an effort may be made at local excision. Some periosteal sarcomas are dense fibrosarcomas which recur locally but which have only a moderate tendency to produce metastases. They also suggest conservative treatment.



Fig. 18.—Structure of extraperiosteal and capsular osteogenic sarcoma; same case as Figure 17.

Most periosteal sarcomas produce bulky rounded solid growths which long remain encapsulated, pushing the soft parts before them. When forming cartilage, they may reach enormous dimensions.

The texture of periosteal sarcomas varies. Some are cellular, soft, crumbly, rapidly growing and extremely malignant. A tumor of the humerus gave myriads of metastases in nearly every portion of the body from calvarium to heel, while the pancreas was completely replaced by tumor tissue, composed of small spindle cells. A cellular tumor of the patella proved fatal six weeks after the originating injury was received.

Most of the tumors are firm because of the presence of much intercellular stroma, which appears in the form of stalactite strands of

hyaline, osteoid or osseous tissue, or masses of cartilage. The metastases may produce bone.

The structure of the periosteal sarcoma is usually specific and easily recognized. It presents spindle cells, small or of moderate size,

Fig. 19.—Solid central and subperiosteal osteogenic sarcoma; the sharp limitation at epiphyseal line may be noted.

but usually presenting hyperchromatic nuclei. Cell bodies are not always easily demonstrable, so that some of these tumors may pass as round cell sarcoma. In other cases the spindle cells are quite large,

and with increasing stroma they tend to become large and sometimes polyhedral.

Differing markedly from these malignant cellular growths is a series of cellular fibrosarcomas in which hyaline and fibrous stroma exceeds the bulk of the cells. Such tumors are not, as a rule, malignant. They recur locally after excision, but are slow to produce metastases. They probably form the majority of cures of osteogenic sarcoma by amputation (Figs. 21 and 22).

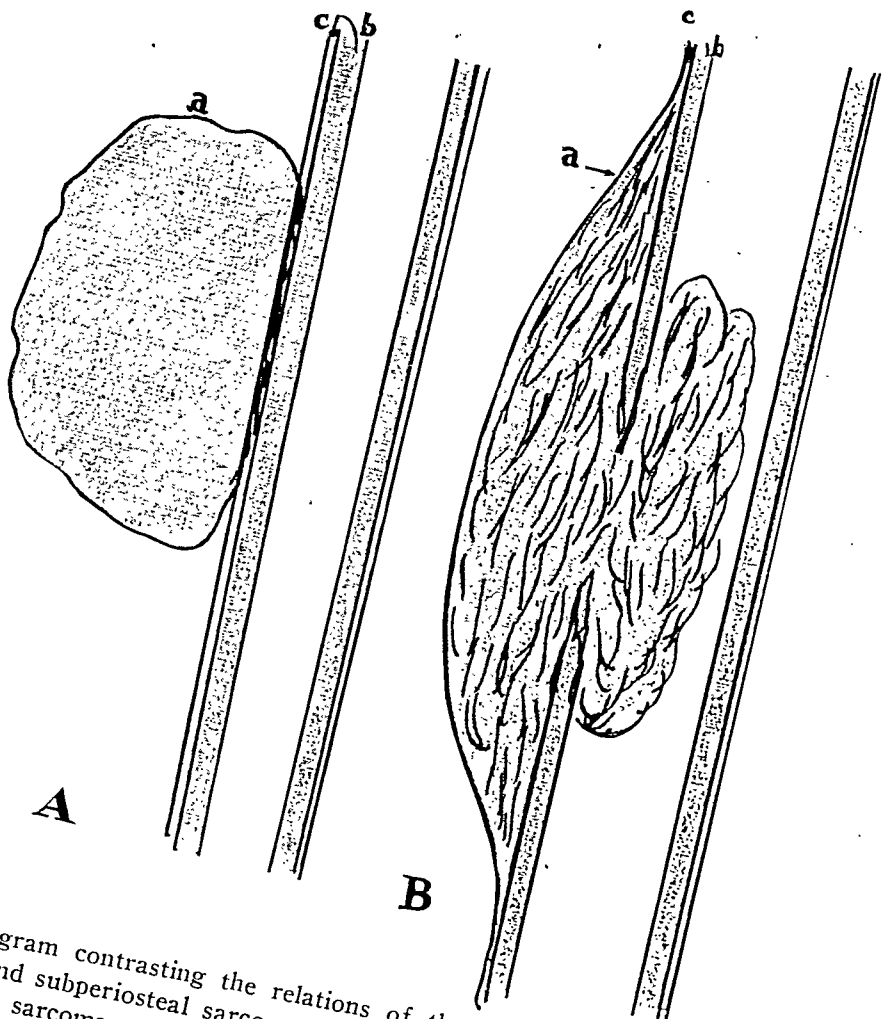

Fig. 20.—Diagram contrasting the relations of the extraperiosteal sarcoma and medullary and subperiosteal sarcoma: *A*, periosteal sarcoma; *B*, medullary and subperiosteal sarcoma; *a*, tumor; *b*, shaft and *c*, periosteum.

The diagnosis between hyperplastic callus and productive periostitis is not always easy, and must be based on general familiarity with both processes. Mistaking exuberant callus and productive periostitis for sarcoma is a very common error which may be avoided if the microscopist will insist on having unmistakable neoplastic characters

before concluding that a malignant process exists. Malignant bone-producing tumors very rarely develop within three weeks after a trauma. Periostitis usually covers a wide area, while tumors are localized.

2. *Solid Subperiosteal and Medullary Sarcoma.*—The most frequent form of osteogenic sarcoma involves marrow, shaft and subperiosteal tissue. The cancellous tissue toward the end of the diaphysis is converted into a solid tumor mass which extends up the marrow cavity, and after considerable delay may cross the epiphyseal line into the epiphysis. At the same time the shaft is destroyed and the tumor spreads beneath the periosteum, producing a fusiform swelling which gradually encases the bone. In the earliest cases which I have

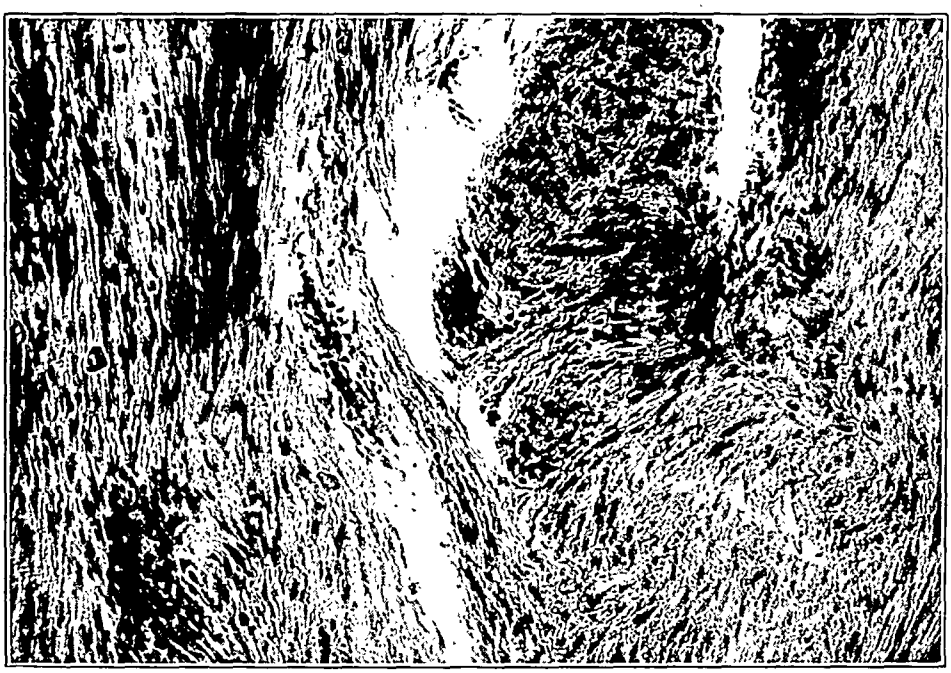

Fig. 21.—Large spindle cell, highly fibrous periosteal sarcoma.

dissected the lesion was about equally developed in both locations, medullary and subperiosteal. The separated periosteum long remains as a resisting capsule; but eventually it is perforated, after which the tumor process rapidly invades the soft parts (Fig. 19).

Occasionally, these tumors spread widely over large segments of bone. I have seen most of the ilium, pubes, ischium, and upper half of the femur covered and infiltrated by cellular subperiosteal and medullary sarcoma.

The tumor tissue is solid, opaque and cellular. Usually there is considerable stroma, of osteoid character, which renders the growth firm and resistant. Bone formation is not prominent; but irregular

islands may appear throughout the medullary portions, and radiating striae beneath the periosteum. Hemorrhage and necrosis belong to the rapidly advancing cases. Combinations with the sclerosing type of osteogenic sarcoma are not infrequent.

The structure exhibits considerable variations. Most of the tumors consist of spindle, rounded, and polyhedral cells, while mononuclear giant cells are common. In some cases, probably concerned with cartilage, the cells are large and polyhedral. The stroma is usually abundant, and of hyaline, cartilaginous, osteoid, or osseous type. Bone production and absorption go hand in hand in the same territory. The blood vessels consist of capillaries and clefts between tumor cells,



Fig. 22.—Spindle cell fibrosarcoma of periosteum.

and of larger vessels lined by tumor tissue and through which cell emboli readily pass (Figs. 24 and 25).

In the roentgenogram the most striking feature is the elevation of the periosteum by a fusiform subperiosteal tumor. A bony capsule such as is seen about benign central tumors is missing; but irregular extracortical deposits of bone may be seen. The medullary region is usually opaque and in sclerosing types it may be quite dense. The cortex is generally obscured or destroyed (Fig. 23).

3. *Telangiectatic Bone Sarcoma.*—This is a characteristic gross anatomic picture (Fig. 26). Its exact point of origin is not narrowly defined, but it early destroys the shaft and grows expansively in all directions, obliterating the marrow cavity and perforating the distended

periosteum and its shell of bone. Vascular tumors may pulsate. In several rapidly progressing cases, I have found the lower 2 inches (5 cm.) of the femur sequestrated beneath the periosteum and lying in blood clot. Combinations with cellular solid central and periosteal tumor masses are common.



Fig. 23.—Osteogenic sarcoma.

At the other extreme are cases in which there is comparatively little tumor tissue, but widely dilated blood spaces separated by strands and walled off externally by narrow layers of malignant tumor tissue.

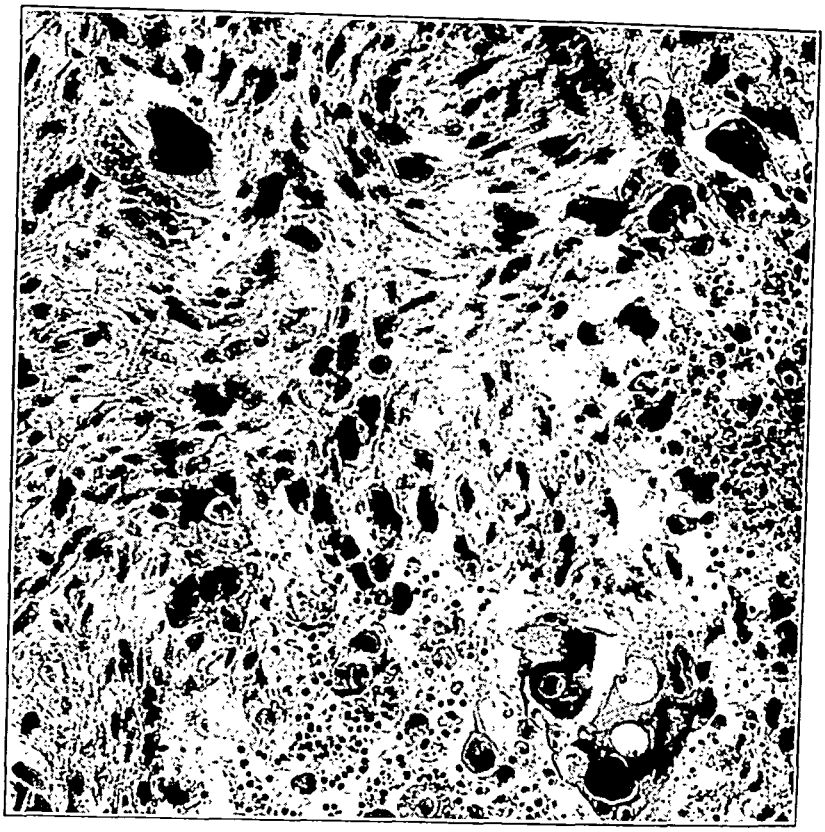

Fig. 24.—Malignant osteogenic sarcoma with giant cells.

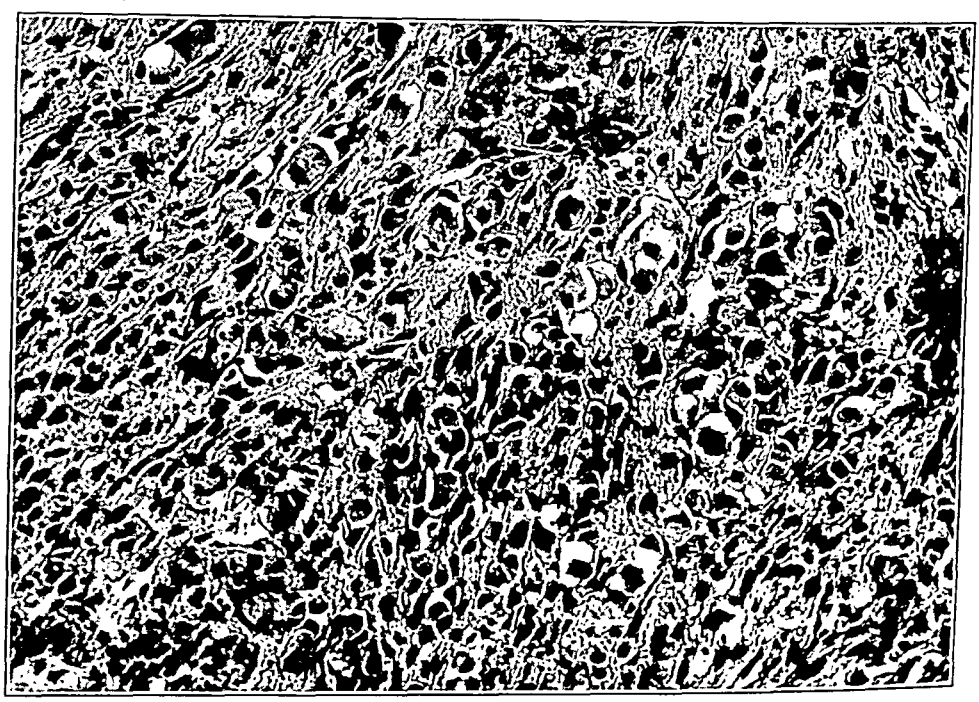

Fig. 25.—Structure of osteogenic sarcoma; large polyhedral and spindle cells in fibrillar and osteoid stroma.

These are the true malignant bone aneurysms (Figs. 12 and 13). This type of tumor is practically limited to young subjects. Few patients survive more than a year, and no cures by any method appear to have been recorded.

Fig. 26.—Telangiectatic osteogenic sarcoma.

All of these variations and combinations indicate that the disease is essentially one and the same process, which originates from osteoblasts and destroys periosteum, bone shaft and marrow.

4. *Sclerosing Osteogenic Sarcoma.*—This term was employed by Virchow to designate certain bone-producing sarcomas, mainly central

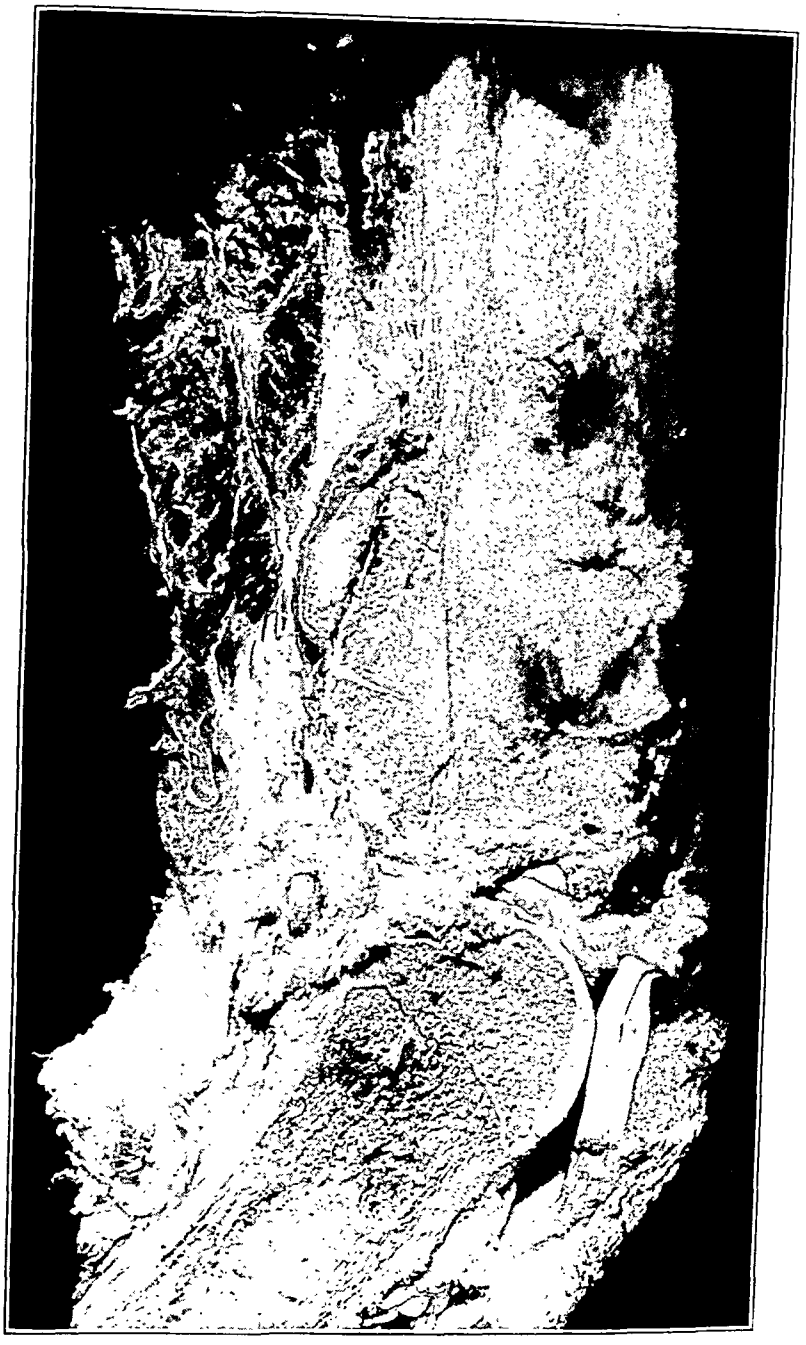

Fig. 27.—Sclerosing osteogenic sarcoma of femur; fusion of thickened cortex with central mass of ossifying tumor; extension up marrow cavity and into periosteum.

in location, but involving periosteum, shaft and marrow cavity, and transforming the end of the bone into a bulky solid mass of hard, occasionally ivory-like, bone.

Minor variations in this process are not uncommon. The periosteum usually remains unbroken; but it may be perforated early, releasing a portion of the tumor which grows in more cellular form, invading the soft tissues. The roentgen ray shows the club shaped central mass of dense bone with widening and obliteration of shaft. The picture is unlike that of any other process in bone (Fig. 27).

Fig. 28.—Structure of sclerosing osteogenic sarcoma; large spindle and polyhedral cells lying in osteoid and osseous tissue; nuclei large and hyperchromatic.

The dominating histologic feature is the production of much intercellular material in the form of hyaline osteoid tissue or dense bone. This material is at first cellular but eventually becomes very compact, hard, and acellular (Fig. 28). In the advancing peripheral portions are blood vessels lined by tumor cells, through which metastases readily occur.

The progress of the disease is slow, from one to two years elapsing before marked swelling of the bone appears, and from five to twenty-five years passing before the usual fatal termination is reached. Yet the prognosis is poor, since metastases seem to occur early, although some years may elapse before pulmonary signs are detected.

ETIOLOGY OF OSTEOGENIC SARCOMA

It is difficult to find any adequate hypothesis regarding the causation of osteogenic sarcoma. Trauma rather frequently precedes the outbreak of the disease but has been noted only in a minority of cases, and is of itself an inadequate explanation. It is possible to conceive that traumatic hemorrhage and separation of minute fragments of bone may tend to release the vigorous regenerative capacity of osteoblasts; but the atypical and lawless form of the regeneration always evades our grasp. Definite fractures are seldom followed by sarcoma although exuberant callus closely approaches in structure osteogenic sarcoma. Some element of tissue predisposition must be involved and it seems probable that this factor may consist in an abnormal blood supply in the affected part, providing excessive nutrition. If such a factor actually exists it works more often alone than with trauma. Typical osteogenic sarcoma almost invariably begins *in the end of the diaphysis* and long fails to cross the epiphyseal line. This relation suggests that a vascular and nutritional disturbance may reside in the branches of the main nutrient artery but not in the capsular vessels which supply the epiphysis. Multiple osteogenic sarcoma, affecting the ends of several long bones, of which I have seen one case so interpreted, favors the idea that the disease is dependent on some congenital disturbance in the structure of the bones.

UNIDENTIFIED TYPES OF BONE SARCOMA

In the group of osteogenic sarcoma one must include certain malignant cellular tumors, the origin and nature of which are still quite undetermined. One not infrequently encounters cellular medullary and subperiosteal tumors in which the hyperchromatic cells grow diffusely without producing bone or any stroma.

The nature of these tumors remains an unsolved problem in which several possibilities may be considered: (1) It is possible that osteoblasts may proliferate so rapidly as to produce a tumor tissue composed of rounded or polyhedral or short spindle cells, entirely free from intercellular material. (2) An endothelial origin of some of the cellular tumors is also to be considered; but the necessary proof is difficult to secure, and unless the evidence is quite convincing the diagnosis of endothelioma should not be entertained. (3) It is always a safe resort to assign undifferentiated round and polyhedral cell tumors to the group of myelomas; but this plan does not assist in unraveling that miscellaneous class of neoplasms. (4) The perithelial cells of blood vessels are a source of somewhat specific tumors in many situations; but there is no definite evidence that angioblastic cells produce the cellular tumors of bone. (5) The increasing recognition of neuroblastoma, especially in young subjects, raises the suspicion that some

of the cellular tumors of bone may be derived from the neuroblast; but the characteristic rosets on which alone the diagnosis of neuroblastoma may safely rest, have not been demonstrated in bone sarcoma. (6) One may draw into the possible sources of tumors aberrant organ and tissue rests, the existence of which in bone or bone marrow is mainly hypothetic. (7) A metastatic origin of atypical cellular bone tumors is always to be kept in mind; but this explanation will not apply to most of the tumors in question.

These speculations seem permissible mainly to emphasize the fact that the territory of cellular bone tumors still requires much further exploration. Yet there is a practical value in knowing that such unidentified tumors exist, so that peculiarities in age incidence, location, structure, and clinical course, and paradoxic cures by surgery, roentgen ray, and radium, may not be attributed to the well known malignant bone tumors.

MYELOMA

Only a brief outline of the main features of this extensive, but comparatively rare, group of tumors can be undertaken at this time.

Myelomas are tumors derived from the specific bone marrow cells. Granular myelocytes, lymphocytes, and nucleated red blood cells are the three specific cells of bone marrow, and tumors of each of these cells are observed. The commonest form of myeloma is, however, composed of plasma cells, the origin of which is still somewhat uncertain. The weight of opinion favors an origin from lymphocytes or from endothelial cells. There are thus four histologic varieties of myeloma: (1) plasma cell tumors; (2) lymphocytoma; (3) myelocytoma, and (4) erythroblastoma.

These tumors have certain common features which separate them sharply from osteogenic sarcoma. While often single they are usually multiple. Eventually, they may become widely diffused or systemic. They readily destroy bone by diffuse absorption or sharp perforation, but never produce bone. Visceral metastases develop slowly or not at all, so that many cases come to necropsy without metastases. The regional lymph nodes are not infrequently involved. The presence of involved regional nodes is almost certain evidence against osteogenic sarcoma, although in a few cases of this disease the nodes appear to have sifted out cells which ordinarily travel through large blood channels.

The location of myelomas is peculiar. They choose by preference the midportions instead of the ends of the bones, often involving considerable segments or later the whole of the marrow cavity. They also affect the vertebrae, ribs and skull, which are seldom the sites of osteogenic sarcoma. Passing through the bone, myelomas infiltrate the soft tissues, without, as a rule, producing the bulky tumors and destruc-

tive effects of other sarcomas. Rapidly destroying bone, they early lead to spontaneous fractures, or collapse of joints, or crushing of vertebral bodies with paraplegia (Fig. 29).

A peculiar cachexia and anemia usually accompany myeloma, due to the destruction of blood-forming marrow. Bence-Jones proteinuria is occasionally present. The prognosis of all forms of myeloma is unfavorable, owing to the multiple and systemic nature of the lesions. Yet solitary myeloma is probably curable by excision or amputation. Of the recurrences and extensions it is difficult to determine whether they are metastases or multiple primary new growths.



Fig. 29.—Plasma cell myeloma of vertebral body, causing collapse of vertebra and paraplegia.

Like other lymphoid tissues, myeloma recedes rapidly under roentgen-ray and radium treatment and the bone is partially restored; but the ultimate prognosis remains unfavorable because of extensions and metastases.

The diagnosis of myeloma can usually be made on the general clinical features and on the roentgenograms. The medullary location, the preference for the midportions rather than the ends, the sharp perforation or diffuse absorption of bone are rather specific roentgenologic features; yet diffuse endothelioma produces much the same effects

as solitary myeloma. Tissue excised for diagnosis shows a diffuse growth of round cells of the various types occurring in marrow. Myeloma is the only true round cell tumor occurring in bone. Hence the term "round cell sarcoma" should be eliminated from the discussion of bone tumors and the more exact histogenetic designations employed. The various cell types in myelomas can usually be recognized in sections, since plasma cells, lymphocytes, granular myelocytes, and hemoglobin-holding cells are peculiar. Yet owing to neoplastic variations in cell structure and degenerative processes, there has been extensive debate regarding the exact nature of many cases, and the exact identification of every case is impossible.

The several varieties of myeloma differ somewhat in their general behavior.

1. *Plasma Cell Myeloma.*—This is usually multiple and often occurs in the form described as Kahler's disease, with extremely numerous painful perforating tumors affecting many bones throughout the body, without notable visceral metastases, with early cachexia and with proteinuria. Yet I have observed solitary plasma cell myeloma of the sternum, tibia, and femur, and Greenough, Simmons, and Harmer report solitary myeloma of the ilium and humerus.

Large mononuclear nongranular cells occur in rapidly progressive cases which involve several bones and produce extensive metastases. In a young patient, observed by Norris, very large round cells with hyperchromatic nuclei occurred in widely distributed bone tumors and in very bulky metastases in all the organs. In these cases it is impossible to determine the cell of origin.

2. *Diffuse Lymphocytoma.*—This occurred in a case that I followed for several years. The disease first appeared in the humerus, the entire shaft and the epiphysis being widened and the bone distorted and largely absorbed. The progress was relatively slow. Under roentgen-ray treatment the greatly swollen arm was reduced to normal dimensions and the shaft was largely restored. The patient, a young man, resumed his work for a period of two years, and passed out of control; but it was learned that the disease reappeared in other locations, with a fatal result, about five years after the inception. The structure of the humerus tumor showed a diffuse growth of typical small lymphocytes.[5]

3. *Large Mononuclear Cells.*—These cells with prominent granules of variable staining characters I have observed in three cases.

5. Ewing, James: Neoplastic Diseases, Ed. 2, Philadelphia, W. B. Saunders Company, 1922, pp. 294-295.

One of them involved the whole marrow cavity of the humerus of an adult male, destroyed the shaft over the upper half and produced a bulky infiltrating extensively necrotic tumor of the muscles and fasciae. Shoulder-joint amputation was soon followed by recurrence and generalization of the disease. Considerable infiltration by lymphocytes and extensive necrosis suggested a syphilitic process; but the wide areas of large hyperchromatic granular cells and the later course demonstrated the myelomatous nature of the disease.

This form of myeloma appears to have escaped definite attention in the literature of bone sarcoma, although several authors have described scanty neutrophil granules in the cells of myeloma.

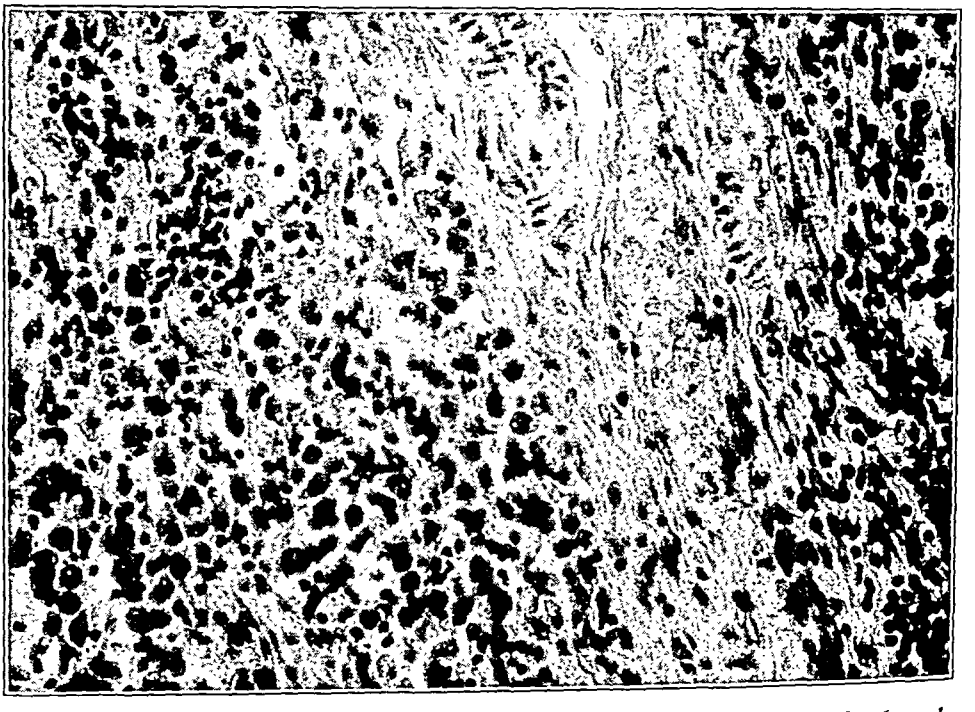

Fig. 30.—Myeloma of femur involving a large portion of the shaft; loosely packed large round cells.

4. *Hemoglobin-Holding Cells.*—These have been found in myeloma by Ribbert [6] and by Norris. In Ribbert's case the largest tumors were in the ribs and smaller growths were found in the vertebrae and skull. The tumors presented a striking brownish-red appearance; and hemoglobin in abundance was found in the tumor cells. In a similar case observed by Norris [7] in Bellevue Hospital the cells were rich in hemoglobin.

6. Ribbert: Centralbl. f. Path. **15**:337, 1904.
7. Norris: Proc. New York Path. Soc. N. S. **6**:128, 1906.

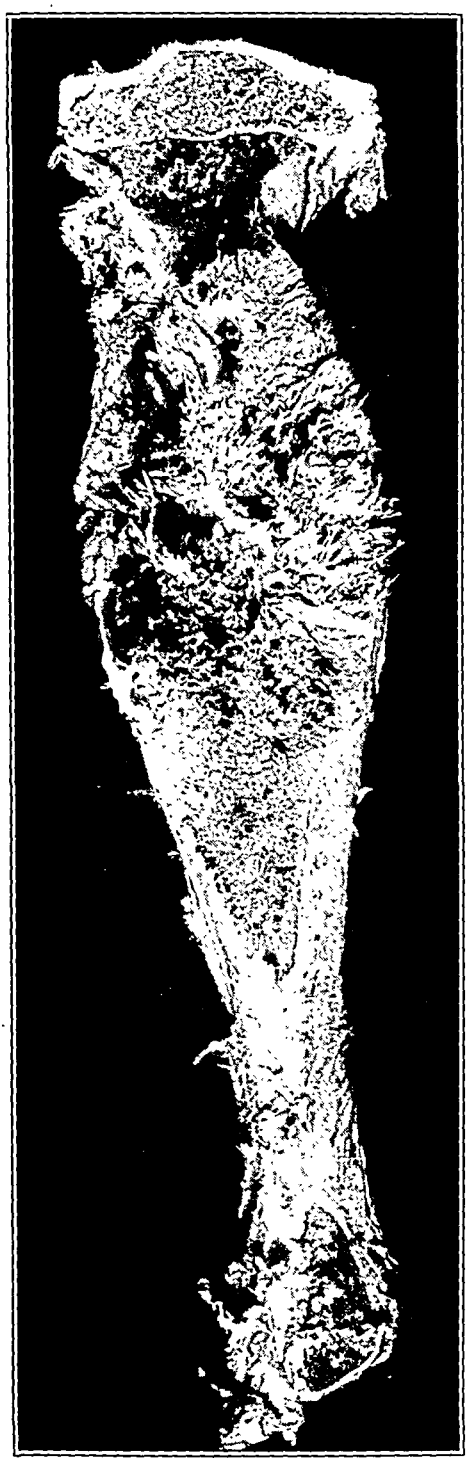

Fig. 31.—Myeloma of tibia, composed of small round cells with hyperchromatic nuclei.

The Prognosis and Treatment of Sarcomas of Bone

The increasing knowledge of the natural history of bone tumors furnishes a basis for reconsidering the treatment of these diseases. I believe that the present state of our knowledge and the additional resources of roentgen ray and radium demand that the whole subject of the prognosis and treatment of bone sarcoma should be reopened and readjusted to meet the present situation and bring the control of these diseases more nearly in line with present possibilities. It does not require an extensive experience with surgical literature, to say nothing of actual surgical practice, to force the conclusion that the results now generally obtained with this group of diseases are far below a reasonable standard.

Generally speaking, the diagnosis of malignant bone tumors is accomplished in the late stages of the disease, after long delay has been incurred by considering every other possibility, and not a few impossibilities. Experience with many of these cases at the Memorial Hospital shows that in the presence of definite signs of bone sarcoma, persistent pain and loss of function, these patients are generally treated for inflammatory conditions and the last possibility to be considered is sarcoma. Often until the terminal stages, treatment has been directed toward the alleviation of rheumatism, neuralgia, syphilis, osteomyelitis, sprain, endocrine disturbance, etc. All the modern laboratory methods for the quantitative study of the secondary phenomena of disease have been freely employed; but the diagnosis of a lethal disease has not been made in time to be of service. Even in the face of indubitable signs and pathognomonic symptoms of well established bone sarcoma I have known experienced surgeons to refuse to accept the diagnosis of malignant tumor.

The main reason for this costly conservatism must be found in the fact that the diagnosis of bone sarcoma is generally accepted as a signal for an immediate surgical operation, either amputation, or excision, or diagnostic incision. As long as this view and this aggressive standard practice prevail so long will the surgeon delay in accepting a grave prognosis for his patient. On the other hand, if the diagnosis were approached more radically, treatment might be much less radical.

I believe that with present resources, the suspicion of bone sarcoma should not be taken as a signal for operation. The diagnosis in the great majority of cases of bone sarcoma can be accomplished on clinical history, roentgen-ray findings, and the results of therapeutic tests with roentgen ray or radium. The therapeutic test is at the same time the best treatment for a large proportion of bone sarcomas. In short, the nonoperative treatment of these diseases is a goal to be aimed at. The main exceptions to this proposal, of which there are many, are found among the early osteogenic sarcomas with which prompt ampu-

tation has effected some cures. There are also complicated cases of other types which demand operation.

Considering first the omission of diagnostic incisions, one finds that the vast majority of cases of bone sarcoma of every type give highly



Fig. 32.—Myeloma of tibia; bony portions of the tumor are dissolving bone apparently displaced from the shaft.

characteristic roentgenograms, which, interpreted in the light of exact and simple clinical data, permit a reasonably accurate diagnosis. The roentgenologic details will not here be repeated; but emphasis may

be placed on the facts that: osteogenic sarcoma almost never affects the middle half of the shaft, but is a disease of diaphyseal ends; erosion or destruction of a segment of shaft is nearly constant in osteogenic sarcoma; the benign central tumors regularly widen the shaft and displace the periosteum with its thin shell of bone, long before more aggressive forms of this disease invade the soft tissue; and myelomas and diffuse endotheliomas involve wide segments of the bone, often the midportions, and cause smooth gradual fading of the shaft. Syphilis, tuberculosis, chronic osteomyelitis and periostitis, and Paget's disease, each presents its own peculiar morphology and

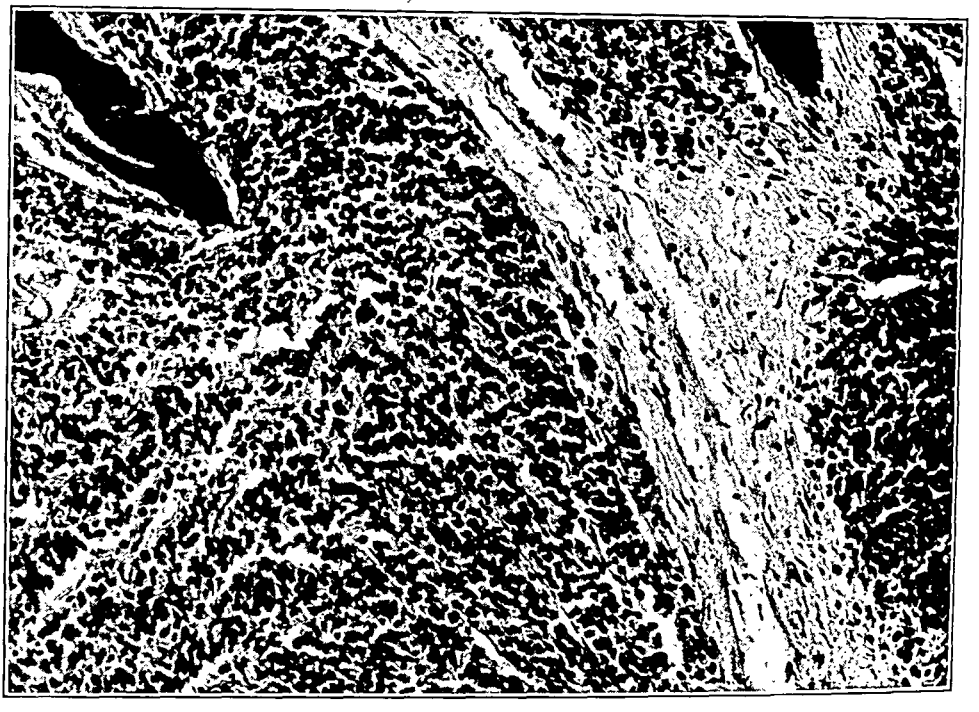

Fig. 33.—Structure of a diffuse myeloma; cells small, round, and polyhedral; type undetermined; same case as Figure 31.

clinical setting, and, with rare exceptions, lacks the specific features of bone tumors. It must be admitted that these interpretations require experience; but no inexperienced person should undertake to deal with bone tumors. When the experienced observer is unable to reach a conclusion, then resort must be made to the diagnostic incision, before amputation is advised.

The therapeutic test is decisive evidence as between certain classes of bone tumors. Myelomas and diffuse endotheliomas melt down rapidly under roentgen ray and radium. These physical agents control the growth of the benign central tumors and cause the gradual restoration of the shaft, while the relief of pain and disability is usually

prompt. With osteogenic sarcoma, roentgen ray and radium have little or no immediate effect on the size or form of the tumor. Chondrosarcomas seem to be wholly unaffected by external radiation.

When the clinical data, roentgen-ray findings, and therapeutic tests have been carefully weighed by an experienced observer, I believe there will be very few cases remaining for diagnostic incision.

When tissue has been removed for diagnosis, the microscope in competent hands will provide an accurate idea of the clinical nature of the disease in the great majority of cases, but not always. Failure to secure a characteristic portion of the tumor, encountering tissues greatly altered by inflammatory or degenerative processes, and inexperience of the pathologist with the very wide scope and confusing variety of histologic features occurring in diseased bone are some of the common sources of error which the surgeon must face who trusts his diagnosis to the microscope. It would be a mistake to overemphasize these hazards; but the more experienced the pathologist, the more he learns to rely on clinical data for clinical diagnoses and the more he urges the surgeon to make his diagnosis on clinical observation, and not to expect too much from the study of small pieces of tissue. As a rule, the microscope reveals the general class of a bone sarcoma; but it often fails to reveal those special features which are so important in forming a clinical estimate of the disease.

The diagnosis having been reached, the plan of treatment may then be determined with adequate reference to the natural course of the disease. In this decision, I would emphasize the necessity of distinguishing not only between the different groups of bone sarcoma but between different cases in the same group. Blanket rules are inadmissible in dealing with cases which differ so widely in their natural tendencies as do bone sarcomas. The slowly growing, encapsulated fibrosarcoma attached to the periosteum presents a very different therapeutic problem from the highly malignant telangiectatic sarcoma, and there is much variation among the cases of benign giant cell tumor.

TREATMENT OF THE GIANT CELL TUMOR

The standard treatment of this disease is by curettage, followed, as a rule, by application to the cavity of some escharotic. A plastic bone operation is sometimes required. The results are generally good. Yet there are several limitations to the success of this radical surgical method. Infection not infrequently follows the curettage, and leads to persistent suppuration, osteomyelitis, or septicemia, since it is difficult to eradicate infection of tumor tissue in the marrow cavity of a long bone. Or the tumor recurs and requires repeated curettages, with advancing destruction of bone, or opening into joints, so that eventually amputation is required. I have observed many cases of this benign

tumor in which all of these unfortunate terminations have resulted in the hands of competent operators. Nor is it unreasonable to assume that the trauma of repeated curettages may transform an originally benign process into one clinically malignant. Even the mechanical forcing of viable cells through open blood vessels and the production of metastases seem quite within the range of possible results of surgical trauma, especially in cellular tumors.[8]

All of these hazards may be avoided by treating these patients by roentgen ray or radium. Both of these physical agents control the growth, soon relieve pain and disability, and permit the gradual restoration of the shaft. The experience at the Memorial Hospital with a considerable series of cases during the past few years has demonstrated, in my opinion, that treatment by roentgen ray or radium should be adopted as the method of choice in uncomplicated forms of this disease. Recently, Jungling[9] has reported the cure by roentgen-ray treatment of a large medullary sarcoma of the upper end of the femur, and at the same time he records the spontaneous regression of two other cases located in the humerus and fibula. This plan, however, calls for a period of several months of observation, for while pain and disability are usually relieved promptly, the restoration of the shaft is slow. If this method fails after adequate trial, then it is time enough to consider curettage, or, if there is great destruction of tissue, amputation.

For a successful result, it is highly important that the skin and tumor capsule should not be incised for diagnosis, since the scar may break down under repeated radiation, and infected cases as a rule do badly. The insertion of radium tubes into the cavity after curettage is not a very satisfactory method, since such radiation renders the tissue more susceptible to infection, and adequate dosage may cause chronic osteitis or bone necrosis. The best method is external radiation through the intact skin. The capacity of the physical agents to deal successfully with the various forms of the benign giant cell tumor is clearly dependent on the cellular structure and delicate blood vessels of the tumor tissue.

Myeloma.—Owing to the multiple or systemic distribution of most cases of myeloma the prognosis of the disease remains unfavorable under any form of treatment. Since these cellular lymphoid tumors are very susceptible to roentgen ray and radium, these agents would seem to deserve first choice in treatment. Yet since little is known

8. Since this article was written, I have obtained all the data in a case demonstrating the transformation of a benign giant cell tumor of the tibia into a malignant large spindle cell sarcoma as a result of repeated curettage, infection and radium treatment, and terminating, after amputation, in death from pulmonary metastases. This case will be fully reported later.

9. Jungling: Strahlentherapie **12**:178, 1921.

regarding the mode of extension of myeloma, one may assume that a prompt amputation may at times forestall metastases. The available reports in the literature, as well as my experience with a few of these rare cases, does not encourage the belief that amputation accomplishes much in this disease. For multiple cases affecting the bones of the skull or trunk, roentgen ray and radium constitute the sole resource, and so far as the local tumor is concerned they are effective.

Endothelioma.—So far I have been able to learn there are no reports of surgical cure of angio-endothelioma, and no record of treatment by physical agents. Owing to early metastases and multiple origin, the prognosis of this disease must remain unfavorable. On account of the vascular and cellular structure of the tumors, it is to be hoped that the effects of the physical agents on this process will be submitted to an early test.

Diffuse endothelioma as already stated, regresses so rapidly under roentgen ray or radium as to call for this plan of treatment in every case. Yet I would again emphasize that sufficient time has not elapsed to determine the final outcome of cases that have responded well to radiation. At the present writing, four of ten patients are dead: three from multiple tumors, one from "acute mania"; two are without signs of disease; one has progressed favorably for a year, and three have not been traced. Until more is known regarding the nature of this disease, it can only be said that the physical agents seem to control the local process, and that amputation should be withheld until its indications are more clearly defined.

Osteogenic Sarcoma.—While the highly lethal character of this disease is perhaps its most impressive feature it is probable that isolated surgical cures have been obtained for nearly every bone of the extremities. Near the shoulder or hip joint there are probably none, except possibly Berger's case, at the upper end of the humerus, reported by Jeanbreau and Riche.[10]

I have examined in some detail the statistical reports of Kocher, Coley, Reinhardt, Butlin, Nasse, and others, and have been unable to draw any definite conclusions from them, because of the uncertainty in diagnosis. Greenough, Simmons, and Harmer, however, carefully classify fifty-six cases of true osteogenic sarcoma occurring at the Massachusetts General and the Huntington hospitals, and report three cures of three years' standing by radical operation. These tumors were located in the femur, tibia, and inferior maxilla, and all were of highly fibrous or ossifying structure. On the other hand, barring one operative death in a very extensive case, all of the fourteen patients with giant cell tumors were cured by operation.

---

10. Jeanbreau and Riche: Rev. de chir. **32**:153, 1905.

More significant than combined statistics is the analysis of the types of cases for which amputation may reasonably be expected to yield success. All the cellular and vascular sarcomas treated surgically seem to have been fatal within a few months. Likewise the established small spindle cell periosteal sarcomas are extremely malignant.

More favorable conditions are furnished in the very early stages of sclerosing central and subperiosteal tumors which have not ruptured the periosteum. For such tumors prompt amputation may well be endorsed as offering a reasonable hope of success, although the attested records of such success are extremely rare. More favorable still are the encapsulated fibrosarcomas attached to the periosteum. Many of these growths are comparatively acellular and are at first capable only of local recurrence. They form a considerable proportion of the reported surgical cures.

With the use of physical agents as adjuvants to surgery, they form a favorable field for conservative surgery, aiming at local extirpation followed by treatment by roentgen ray or radium. As long ago as 1908, Goebel [11] reported the cure (fifteen months' observation) of a malignant infiltrating periosteal sarcoma of the femur in an infant in whom he twice extirpated portions of the tumor and followed the operations with exposure to the roentgen ray to the limit of skin tolerance.

In order to secure more accurate data regarding the prognosis of osteogenic sarcoma, the following scheme may be offered as indicating the different grades of malignancy in the disease; and it is suggested that the use of some such scheme replace the custom of merging all types of osteogenic sarcoma in statistical reports.

1. Encapsulated extraperiosteal fibrosarcoma; fibrous, cartilaginous or osteoid stroma in excess of cells; prognosis fair.

2. Sclerosing medullary and periosteal sarcoma; course slow; metastases appear very late.

3. Cellular spindle cell periosteal sarcoma; stroma scanty or absent; some cures by surgery and other methods.

4. Solid cellular central and subperiosteal sarcoma; some surgical cures of early cases.

5. Very vascular cellular telangiectatic sarcoma; no reported cures.

For the past seven years, I have been interested in efforts to control osteogenic sarcoma by physical agents at the Memorial Hospital. The results have been unsatisfactory but encouraging. They involve many clinical and technical considerations that belong to my clinical and radiologic colleagues. My own services have been directed toward securing accurate anatomic and histologic diagnoses, and to the study

11. Goebel: Arch. f. klin. chir. **87**:191, 1908.

of the effects of the physical agents on the tissues. From these sources of information the following conclusions have been drawn.

1. It has been shown by physical computation, histologic changes in the tumor tissues, and clinical results, that it is possible to deliver an effective dosage of roentgen ray or radium to all parts of many osteogenic sarcomas where the tumors are accessible from all sides.

2. The histologic changes demonstrate a slowing of the rate of growth of the tumor cells, by which they are induced to lay down calcific material, or dense hyaline stroma, or bone. With vascular and cellular tumors, hemorrhage and necrosis may be produced.

3. Cellular tumors without much intercellular stroma may undergo complete resolution and disappear.

In evidence of this statement I would refer to the following case:

In 1915, Dr. C. H. Peck referred to the hospital a boy, aged 8 years, with a recurrent periosteal sarcoma of the metacarpal bone of the thumb. The tumor had recurred promptly after excision, presenting a globular swelling, 2 by 3 cm. Section of the original tumor showed a small spindle cell sarcoma without demonstrable stroma. Roentgen-ray treatment (Müller tube), given by Dr. Arthur Holding for three months, produced, for the first month, no definite effect; during the second month, the tumor ceased to grow; after the fourth month, there was steady recession, which became complete in six months. The boy was followed for four years without recurrence.

4. Tumors producing much intercellular material can probably not be made to disappear by present technic with physical agents. The most that can be hoped for such tumors is the sclerosis or ossification of the tumor tissue with cessation of growth.

5. The majority of true osteogenic sarcomas under radiation, while suffering retardation of growth, prove fatal from the usual metastases. It may be said that they would do so under any circumstances; but the possibility that prompt amputation might save some patients may be considered by many as a bar to conservative treatment. On the other hand, the long survival of certain cases heavily radiated and later coming to amputation strongly suggests that effective radiation distinctly postpones metastases.

6. The technic of employing roentgen ray and radium in osteogenic sarcoma can be made much more efficient by the proper selection of cases, by more careful study of the exact anatomic condition to be dealt with, adapting the agents to the conditions as found, and by a judicious combination with surgery.

It is obvious that the problems here involved are of a major character and demand the most intelligent cooperation of surgeon, radiologist and pathologist. From results already obtained I am convinced that large rewards await the resourceful worker, by using all the means now at his disposal, in reducing the mortality from this lethal disease.

THE GENERALIZED TYPE OF OSTEITIS FIBROSA CYSTICA

VON RECKLINGHAUSEN'S DISEASE *

JOHN J. MORTON, M.D.
Assistant Professor of Surgery, Yale University School of Medicine
NEW HAVEN, CONN.

INTRODUCTION

The localized form of osteitis fibrosa, especially in its relation to the formation of bone cysts, has been very commonly recognized and commented upon during the last twenty years. Bloodgood,[1] in numerous publications, and also Barrie,[2] Silver,[3] and Meyerding,[4] have furnished valuable contributions to the American literature; and Elmslie[5] has given a good summary of the English cases. The Germans have written at length on the subject.

The generalized type, however, has received scant attention, possibly because it is not recognized; and, aside from the article by Lötsch,[6] no extensive publication has been devoted entirely to this form of the disease, although both Meyerding and Elmslie discuss the generalized cases in their papers.

It seemed worth while, therefore, to report the subjoined case: first, because of the rarity of the condition, especially in the United States, and secondly, because of the possibility of correcting some of the deformities arising in this disease. At the same time, it was considered advisable to collect the reports of general types of the disease in order to find what might be learned from them.

REPORT OF CASE

History.—A man, aged 23, a lathe operator, was referred, Nov. 14, 1919, by Dr. Stanley Cox of Holyoke, Mass., complaining of bowing of the thigh bones. Except for the usual children's diseases, the history was essentially negative. He had never had a serious illness, although he had had a sore

---

* I am indebted to Dr. Robert W. Lovett of Boston for permission to use his records of the case reported in this article.

1. Bloodgood, J. C.: Bone Cysts, J. A. M. A. **43**:1124-1129 (Oct. 15) 1904; Prog. Med. **5**:188-192, 200-204 (Dec.) 1903; ibid. **6**:181-194 (Dec.) 1904; ibid. **7**:273-280 (Dec.) 1905; Ann. Surg. **12**:145-189, 1910.
2. Barrie, G.: Ann. Surg. **61**:128-142, 1915; ibid. **67**:354-363 (March) 1918.
3. Silver, D.: Am. J. Orthop. Surg. **9**:563-588, 1911-1912.
4. Meyerding, H. W.: Am. J. Orthop. Surg. **16**:253-276 (Sept.) 1918; ibid. **16**:367-382 (Oct.) 1918.
5. Elmslie, R. C.: Brit. J. Surg. **2**:17-67, 1914.
6. Lötsch, F.: Arch. f. klin. Chir. **107**:1-137, 1915.

throat occasionally and frequent colds but no cough. His appetite was good; the bowel movements regular, and he denied venereal infection. Three years previously, he had an attack of facial erysipelas, lasting about three weeks. At 3 years, he fell and fractured the right femur. Union was good under ordinary treatment. At 4 years, the right arm was hit by a swing and broken

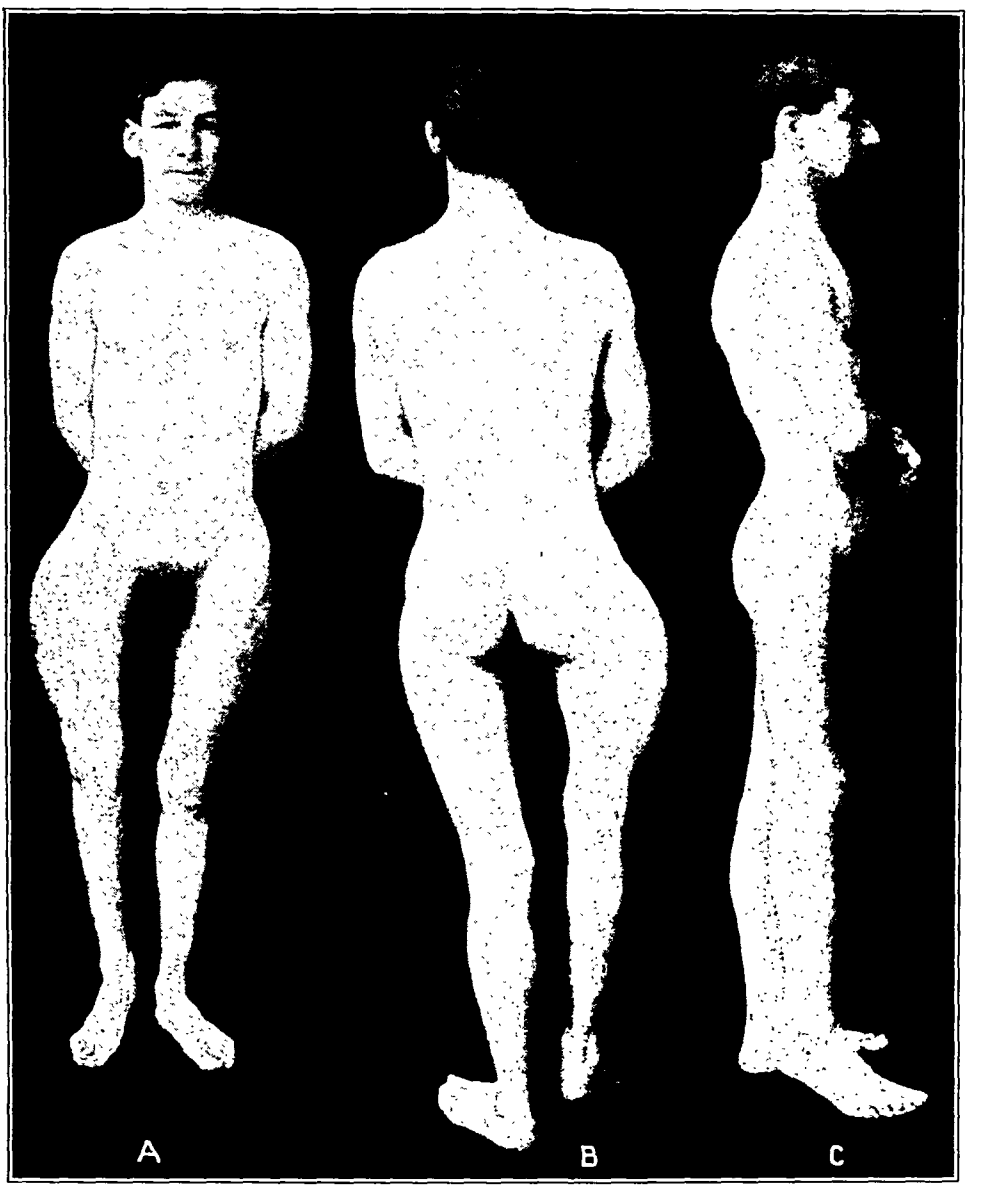

Fig. 1.—Three views of patient showing marked bowing of the femurs with shortening of the right leg and equinus position of the right foot.

just above the wrist. He had no further trouble in any way until he was 12 years old. At that time he fell, after which he could not walk for two or three days. It was six or seven weeks before the pain and limp disappeared. At 16, he fell over a railroad track and again broke the right femur. He was

in the hospital six weeks; and the fracture united without complication. He had no trouble during the subsequent five years, until March, 1919, when he began to have pain just above the right knee, which gradually became more severe. Some days he could not get up from his chair because of inability to extend the leg at the knee. This continued until July, 1919. At that time he suffered with pain in the left knee, which extended up the thigh into the hip, and the pain in the right thigh disappeared. The upper portion of the left thigh became bent and a roentgenogram showed a pathologic lesion of the bone. July 21, 1919, while walking, his left foot hit against a clump of grass, tripping him. He fractured the left femur by this fall and was in the hospital eleven weeks. The bowing of the femur was considerably reduced by the

Fig. 2.—Defects in the frontal and occipital regions.

treatment of this fracture. In October, 1919, there was a return of pain in the right thigh and knee, which had persisted to the time of examination. The pain was not severe, did not keep him awake, but was annoying and "rheumatic-like." He walked with a limp on the right side and with the aid of a cane.

Examination.—The patient was well developed and well nourished. There was no apparent pain at the time of examination. No abnormalities were noted in the head. The sinuses were not tender on pressure. The pupils were equal; reacted to light and on accommodation. There was no nystagmus. The von Graefe sign was not elicited. There was no exophthalmos. The extra-ocular movements and the eye grounds were normal. There was no mastoid tenderness; no

discharge from the ears and no defect in hearing. Breathing was partially obstructed on both sides of the nose. The mucous membranes of the mouth were of normal color; the tongue protruded in the midline and was clean. The teeth were in bad shape; many were missing, and there were a number of old snags in the molar region of the upper and lower jaws. The tonsils were embedded and somewhat scarred. There was no general glandular enlargement. The epitrochlears were not palpable. The thyroid was not enlarged. There was no tremor and no tachycardia.

Fig. 3.—Defects in left frontal region.

The chest was not quite symmetrical, being somewhat depressed below the precordial region and the ribs flared slightly laterally. The percussion note and vocal fremitus were normal. There were no râles. The heart was normal in position and size. The sounds were regular and clear. No murmurs were heard. The heart rate was 70. The pulses were equal and of good volume and tension. No tenderness and no masses were detected in the abdomen on palpation. No organs were palpable. Rectal examination was negative. The genitalia were normal. The spine showed no scoliosis. Movements of flexion, extension, side bending and rotation were normal. There was no disturbance

in the range of motion of any of the joints, except the hip and knee. The reflexes were present and equal in the arms and legs on both sides. Sensation was normal throughout.

Both thighs showed a very marked outward bowing, especially the right (Fig. 1 *A*). This deformity had shortened the distance between the gluteal fold and the knee joint on the right side to such an extent that the patient could not get his right heel to the floor (Fig. 1 *B* and *C*). The deformity was mainly of the thigh bones, which palpation demonstrated to be considerably thickened. The trochanters were high above Nélaton's line and were also

Fig. 4.—Beginning changes in the upper humerus and at the junction of the upper and middle thirds.

thickened. There was practically no abduction in either hip; adduction was normal; flexion to a right angle was possible on both sides; there was no rotation of either hip. The knee joints flexed to about 75 degrees; extension was complete.

Measurements were: the anterior superior spine to the malleolus (left) 35 inches (89 cm.); the anterior superior spine to the malleolus (right) 33 inches (83.8 cm.); the umbilicus to the malleolus (left) 38 inches (96.5 cm.); the umbilicus to the malleolus (right) 36 inches (91.5 cm.).

Tibia measurements were: malleolus to tibia tubercle (left) 14 inches (35.5 cm.); malleolus to tibia tubercle (right) 15 inches (38 cm.).

Femur measurements were: anterior superior spine to tibia tubercle (left) 21 inches (53.3 cm.); anterior superior spine to tibia tubercle (right) 18 inches (45.7 cm.).

Circumference measurements were: thigh (left) 18 inches (45.7 cm.); thigh (right) 18½ inches (47 cm.); calf (left) 13½ inches (34.3 cm.); calf (right) 11¾ inches (31.3 cm.).



Figure 5

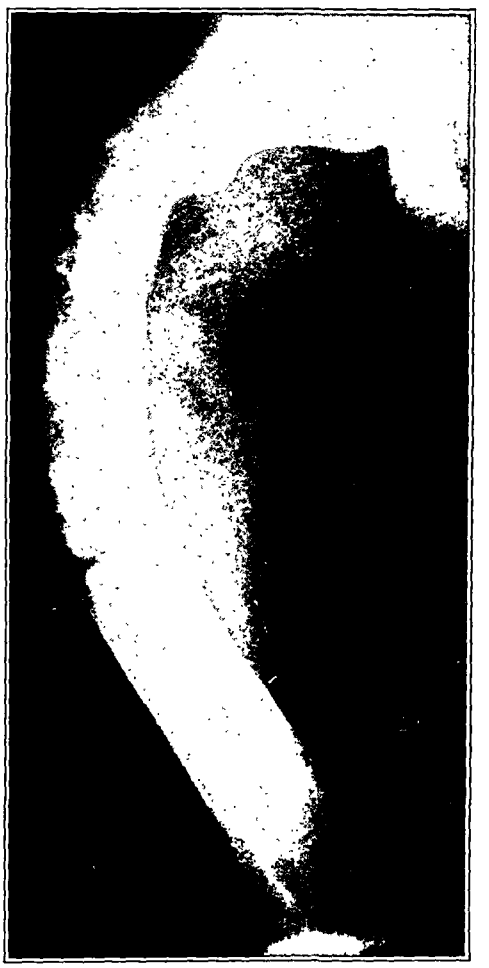

Figure 6

Fig. 5.—Changes in the upper end of the right radius and ulna showing areas of rarefaction and thinned cortical bone.

Fig. 6.—Right femur showing marked bowing and coxa vara, foamy cystic appearance of bone, no differentiation between cortical and medullary bone and a fracture of the midshaft. Compare with Figure 14, one of von Recklinghausen's original cases.

Special Examinations.—Urine: The color was high; the specific gravity was 1.026. The slightest possible trace of albumin was demonstrated by heat test.

No positive result was obtained with nitric acid; no sugar was present. No Bence-Jones bodies were found on three examinations. There were many calcium oxalate crystals.

Stool: There was no abnormal gas formation and no abnormal odor. The reaction was neutral and smears were microscopically negative.

Blood: One c.c. of venous blood in a tube of 9 mm. diameter clotted in five minutes. This may be looked upon as the lowest limit of normal clotting time. The clot retracted normally and the blood serum contained no abnormal pigments. Hemoglobin was 80 per cent. plus. The red cells showed no abnormal variation in size. They were perhaps slightly achromic. No polychromatophilia was present, nor were any other abnormalities noted. Platelets occurred in normal numbers and appeared of normal character. White cells, as estimated from blood smears, numbered about 6,000. The differential count was: poly-



Fig. 7.—Both femurs involved, the right more than the left, the process differing only in degree.

morphonuclear neutrophils, 64 per cent.; lymphocytes, 30 per cent., and large mononuclears, 6 per cent. The white cells were of normal character. No eosinophils or basophils were seen. The blood was entirely normal except for a trifling secondary anemia. There was no evidence of any disturbed bone marrow or hematopoietic function. The Wassermann reaction was negative.

Roentgen-Ray Examination.—Roentgenograms were taken of practically all the bones in the body and the following condition was noted: The periosteum of the cranial bones was of normal appearance; the cortical bone was not thickened; but scattered through its substance were clear spaces, especially marked in the frontal and occipital regions. These spaces were from pinhead to pea size and were surrounded by a slightly denser shadow. The sinuses

were unchanged and the bones of the face showed nothing abnormal (Figs. 2 and 3). The vertebral column showed nothing worthy of note. The clavicles, scapulae, ribs and iliac bones were normal. The right humerus showed at the junction of the upper and middle thirds unmistakable early evidence of the disease process. Here the cortical bone presented a thinning and spongy cystic formation, with slight reaction about the clear spaces. The periosteum was unchanged, and there was no deformity of the bone (Fig. 4). The right forearm showed beginning changes in the upper third of the radius and ulna, very

Fig. 8.—Thinning of cortical bone in the fibula; also large cystic patch in the upper end of the tibia and scattered small areas of rarefaction.

similar in appearance to those observed in the humerus (Fig. 5). The bones of the right wrist and right hand were practically without change. Small areas of rarefaction occurred in the basal phalanx of the thumb, and in the middle phalanx of the index finger.

The left arm was not examined roentgenographically. The right femur was the bone most involved in the disease process. It resembled the shepherd's crook referred to by von Recklinghausen. The whole bone was markedly bowed

outward, especially in its upper and middle portions. It was considerably expanded in width throughout its entire length. The head seemed to be of normal appearance, smooth in the joint cavity, with no signs of trouble. The great trochanter impinged upon the iliac bone above the rim of the acetabulum. The neck showed a very marked coxa vara. The periosteum of the bone was apparently unchanged. The cortical bone was riddled throughout the entire shaft with areas of honey-combed, foamy looking spaces, in places sharply

Fig. 9.—Right foot with occasional small calcium poor areas, showing distinctly the cysts of the tibia and thinning of the cortical bone of the fibula.

outlined, in others merging in long streaky lines. There was no medullary cavity apparent, the whole area being filled with the spongy substance mentioned above. There was a thickening of the cortical bone on the concavity of the curve. At about midshaft on the convexity was a beginning fracture with considerable separation of the outer portions (Fig. 6). The left femur resembled

the right in practically every detail of structure. It differed only in the lessened degree of the bowing and the coxa vara, and in the less marked evidence of the disease. There was a healed fracture in the midshaft which showed a heaping up of periosteal callus and very little deposit of lime. Both femurs showed considerable diminution in the lime content (Fig. 7). The knee joint on the right showed no involvement. The right tibia showed considerable evidence of disease throughout its entire shaft. Areas of thinning of



Fig. 10.—Left foot and leg bones showing diffuse mottled shadows and in places very thin corticalis.

the cortex occurred, in places only a thin shell of periosteum remaining. The medullary cavity was indistinct and merged with the cortical mottled shadow. The right fibula was much less involved but showed the beginning disease in spots. The cortex and medulla remained indistinct throughout most of its length (Fig. 8). The right foot was relatively free, though an occasional

rarefaction was visible on close study of the bones (Fig. 9). The left tibia and fibula were similar in appearance to the right leg bones, and the bones of the left foot were not extensively involved (Fig. 10).

Treatment.—A plaster spica was applied to the right femur, and an attempt was made to wedge the bone over. This was considered worthy of trial, because there was a separated fracture line at the midshaft, and it was thought that the bone was plastic. This line of attack was not very successful, however,

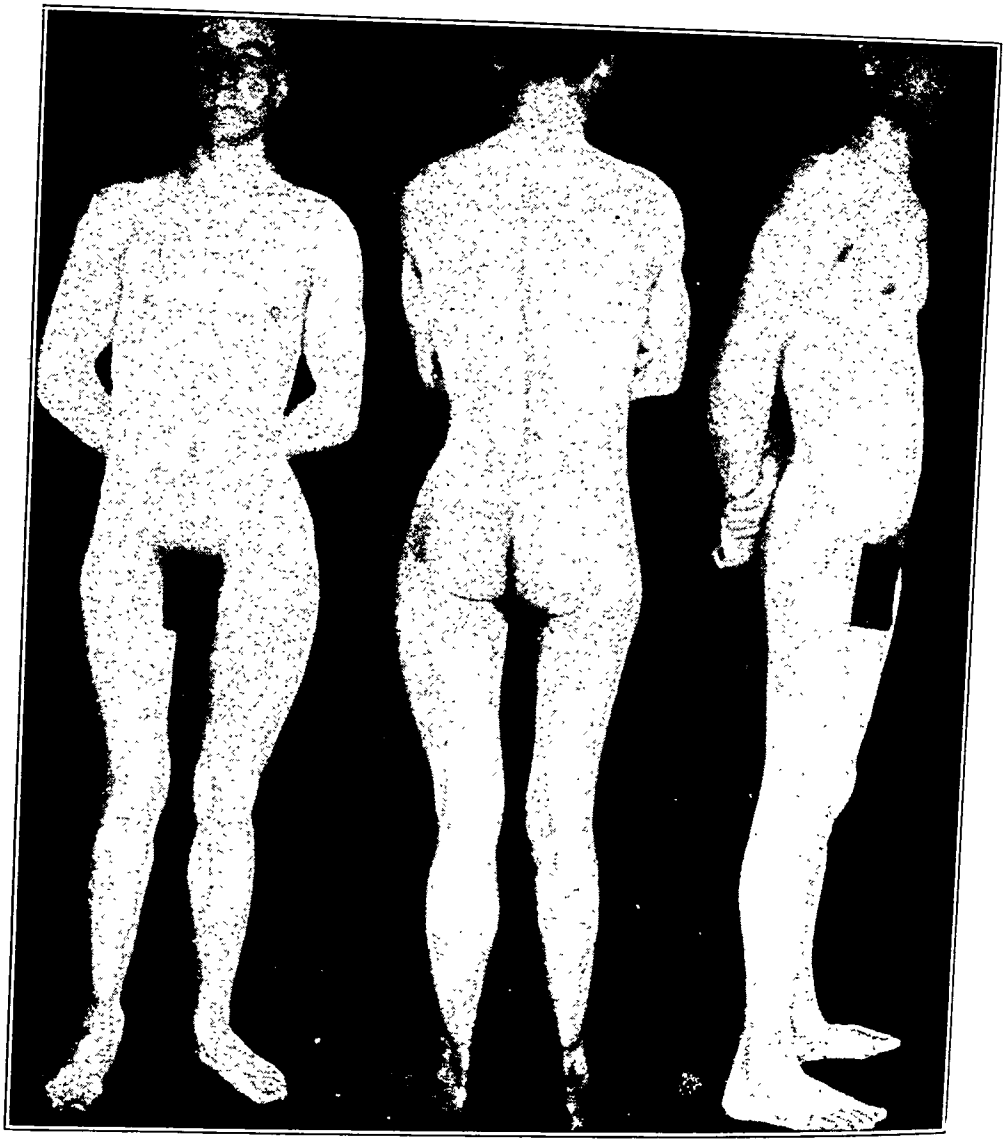

Fig. 11.—Patient after operation; the right femur is much straighter and he can put his heel on the ground easily.

so, Jan. 5, 1920, an open wedge-shaped osteotomy was performed in the upper third of the shaft. The periosteum appeared normal and stripped back easily. The cortical bone was vascular and relatively soft in consistency on the convexity of the curve; but it was necessary to use a mallet to drive the osteotome through it. No definite medullary cavity was made out. The concavity of the curve

was decidedly harder and quite difficult to cut through with the osteotome. The incision was sutured with fine silk and the leg was put up in extension in a Thomas splint. The postoperative course was uneventful. The femur was considerably straightened in its upper portion by this operation. Healing was solid in four weeks. The patient was discharged in a plaster hip spica which he wore for about three months.

He reported in October, 1920, for a second osteotomy to be performed on the lower part of the curved femur. This operation was performed under ether, Oct. 19, 1920. The periosteum was not thickened in the lower third of

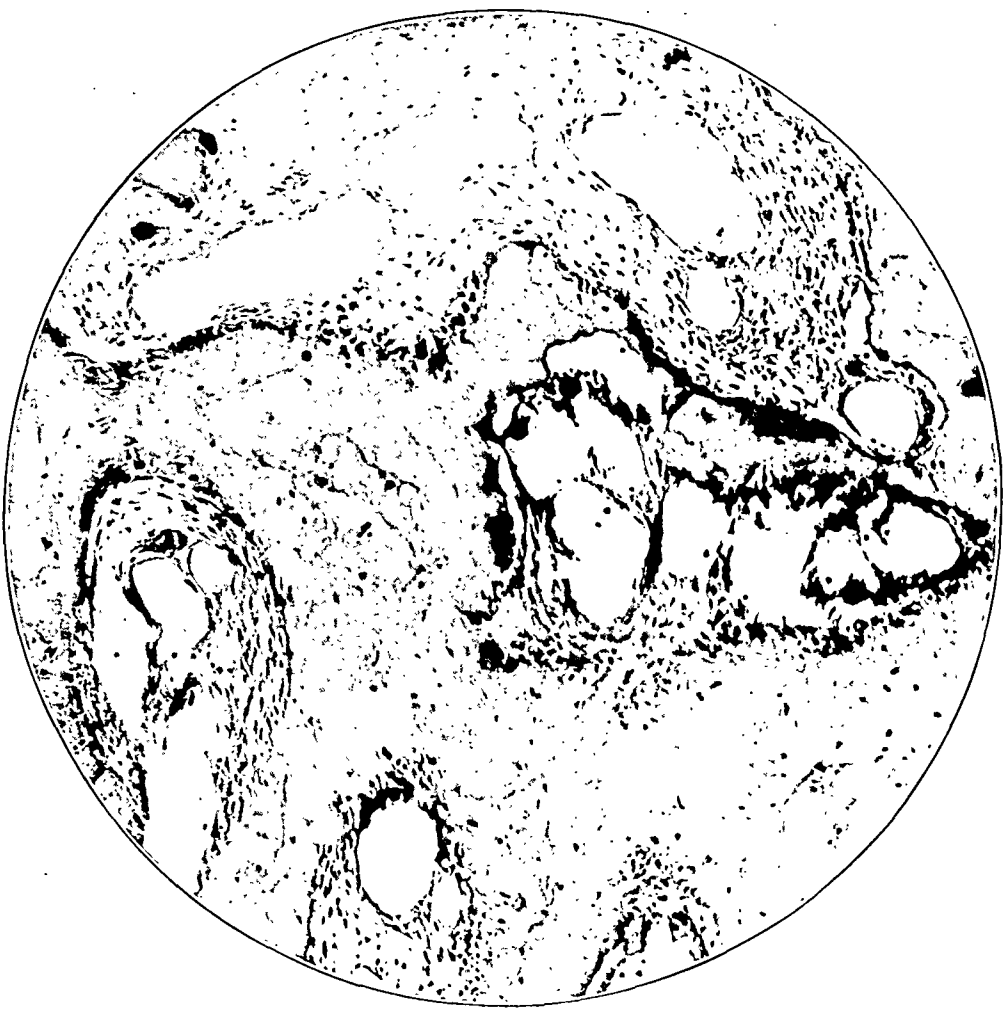

Fig. 12.—Low power photomicrograph of specimen removed at operation, showing infiltration of connective tissue, replacing the bony trabeculae, the formation of small cystic spaces in the connective tissue and the scattered osteoclast giant cells.

the shaft; the cortical bone was fairly soft and vascular. There was a more apparent medullary cavity in this portion of the bone. The wound was closed with fine silk and the leg was put in a plaster cast. Convalescence was uneventful. He was discharged in a cast, Oct. 30, 1920. A roentgenogram was taken the day of discharge showing the bone alinement to be good.

A roentgenogram, taken Nov. 18, 1920, showed the bones in good position with considerable callus formation. The cast was removed Feb. 23, 1921, and baking and massage of the knee joint were started. Measurements on this date were: right, anterior superior spine to malleolus, 35½ inches (90 cm.); left, anterior superior spine to malleolus, 35 inches (89 cm.); right, umbilicus to malleolus, 37 inches (94 cm.); left, umbilicus to malleolus, 37 inches (94 cm.). He put the whole foot on the floor easily and walked without difficulty (Fig. 11). He wrote in May, 1921, that he was getting about perfectly on his leg and that

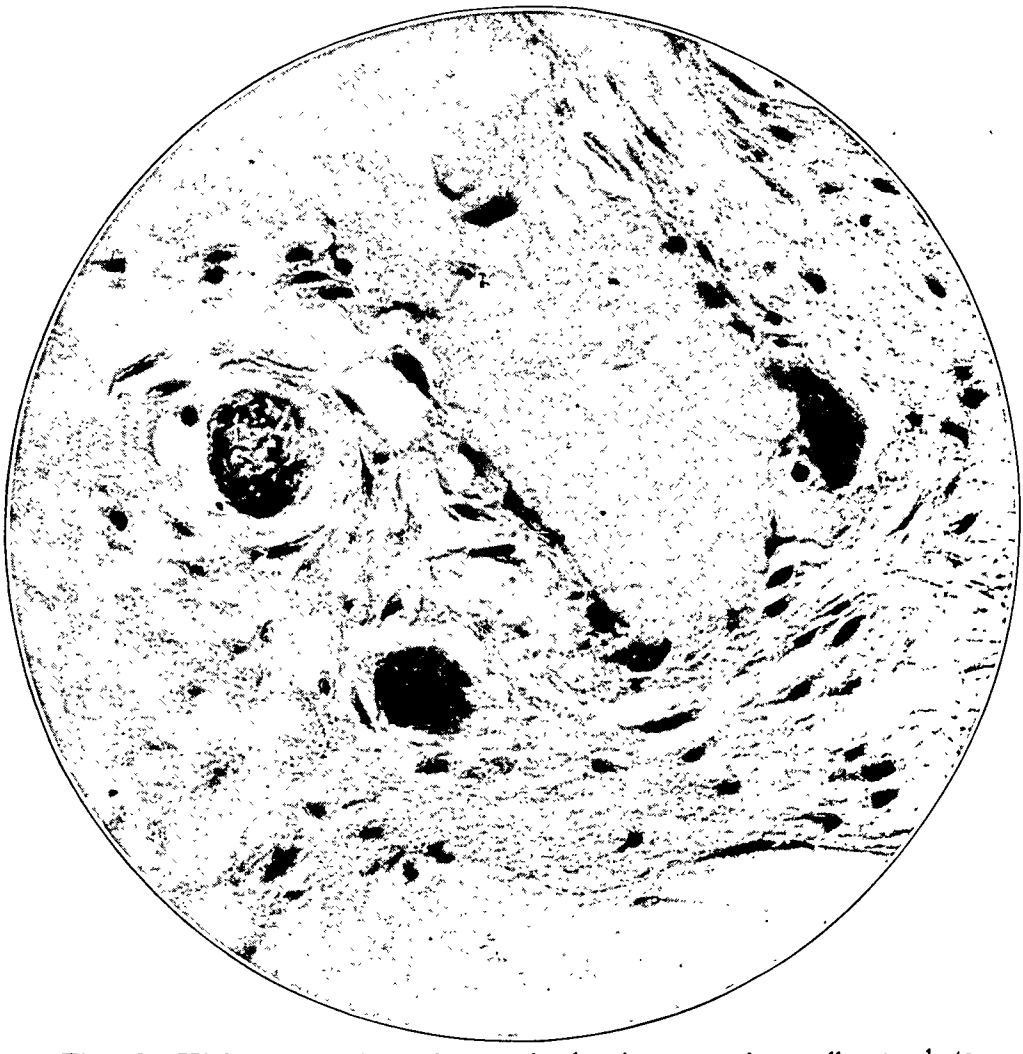

Fig. 13.—High power photomicrograph showing two giant cell osteoclasts, fibroblasts of the connective tissue and a blood vessel in the left center.

it was as good as new. The knee joint was entirely free in its motion and he had returned to his occupation.

Pathologic Report.—The specimen removed at the first operation was examined by Dr. V. C. Jacobson of the Peter Bent Brigham Hospital, Pathological Department, to whom my thanks are due for the photomicrographs and for the following report: "There are three sections showing the same picture. The tissue is composed of narrow anastomosing trabeculae of bone, much in the nature of cancellous bone, separated by large spaces, irregular in shape,

some rather cystic, usually quite filled with a loose reticulum in which lie more or less spindle-shaped cells, resembling fibroblasts. These cells form a large part of the nonbony part of the tissue and are closely packed along the bone trabeculae, where osteoblasts are also present in moderate numbers. Fat is still present in these areas, but in small amount and it appears to be replaced by the spindle cell growth. A few small capillaries ramify in these spaces and hemorrhage is seen to have occurred often. The bone is all of periosteal origin and the condition is fairly typical of osteitis fibrosa" (Figs. 12 and 13).

Diagnosis: "Osteitis fibrosa."

Cultures: "Cultures of the specimens taken at each operation failed to show any growth on aerobic or anaerobic culture media."

HISTORICAL REVIEW

Hirschberg,[7] in 1886, is usually credited with having given the first description of the generalized type of the condition under discussion, although he did not recognize it as a separate entity but thought that it was a form of osteomalacia. Von Recklinghausen[8] followed him five years later (1891) with the report of three cases which he considered as differing from the commonly recognized types of bone lesions and proposed the name "osteitis fibrosa cystica," this describing what he believed at that time to be the pathologic process. In 1910 the same author in an extensive work, "Untersuchungen über Rachitis und Osteomalacia," reviewed the literature and classified as this disease a few cases which were described as osteomalacia with tumors and cysts a number of years previous to the appearance of Hirschberg's article. Thus the reports of Froriep,[9] 1840, and of Engel,[10] in 1864, and of Langendorff and Mommsen,[11] 1875, were all included in von Recklinghausen's latest classification under the term "metaplastic malacia." Sporadic reports have appeared in the thirty years following von Recklinghausen's original description and the total of the recorded cases of the general type, excluding the few transitional cases in which only two bones have been involved (Bockenheimer,[12] Tietze,[13] Röpke,[14] Pfeiffer,[15] Körte,[16] R. Johnson,[17] etc.) is still very small. Ringel,[18] in

7. Hirschberg, K.: Beitr. z. path. Anat. u. z. allg. Path. **6**:513-524, 1889.

8. Von Recklinghausen, F.: Festschr. Rudolf Virchow, 1891; Untersuchungen über Rachitis und Osteomalacia, 1910.

9. Froriep: Chir. Kupfertafeln, Weimar, **9**: 1838-1842.

10. Engel: Inaug. Dissert., Giessen, 1864.

11. Langendorff, O., and Mommsen, J.: Arch. f. path. Anat. **69**:452-486, 1877.

12. Bockenheimer, P.: Arch. f. klin. Chir. **81**:236-274, 1906.

13. Tietze, A.: Beitr. z. klin. Chir. **52**:495-559, 1906; Verhandl. d. deutsch. Gesellsch. f. Chir. **35**:167-171, 1906.

14. Röpke, W.: Arch. f. klin. Chir. **92**:126-154, 1910.

15. Pfeiffer, C.: Beitr. z. klin. Chir. **53**:473-495, 1907.

16. Körte, W.: Verhandl. d. deutsch. Gesellsch. f. Chir. **35**:194, 1906; Deutsch. Ztschr. f. Chir. **13**:42-50, 1880.

17. Johnson, R., Cited by Elmslie: Reference 5, p. 44.

18. Ringel: Deutsch. med. Wchnschr. **44**:367, 1918.

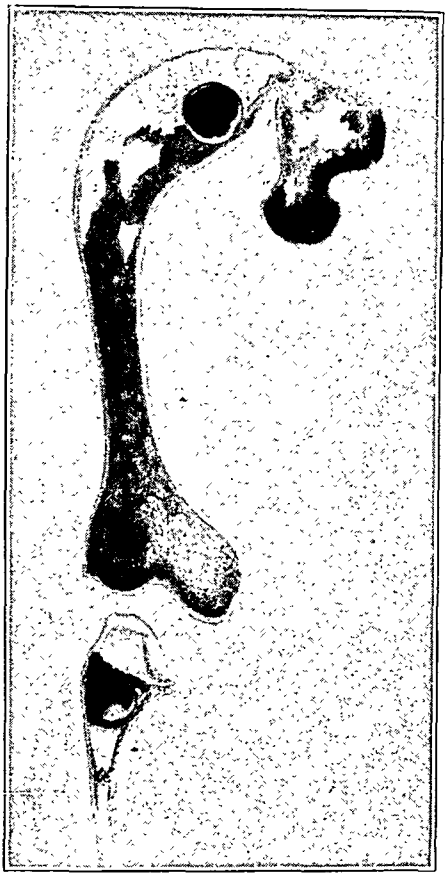

Fig. 14.—Femur and ulna from Case 5 in von Recklinghausen's original paper, 1891. The femur shows the characteristic bowing and the "shepherd's crooking" of the neck and head; a large cyst in the shaft and white connective tissue replace the bone; the ulna shows three cysts and fibrosis.

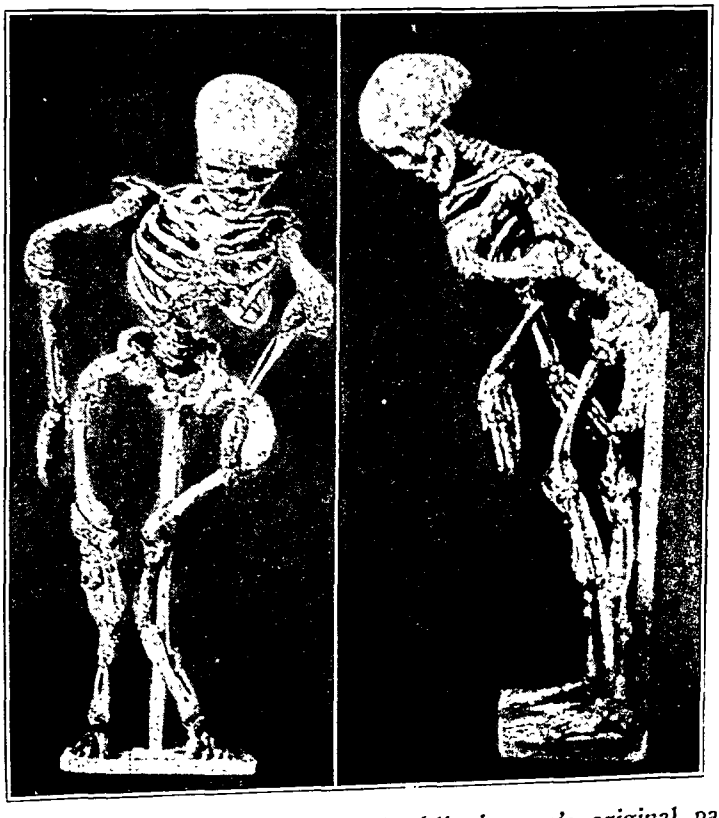

Fig. 15.—Skeleton of Case 6 in von Recklinghausen's original paper, 1891, showing characteristic skeletal deformities.

1918, asserted that there are about thirty cases known, and Roth,[19] in 1920, that there are only forty. Barrie,[20] writing in the *Annals of Surgery,* in 1920, asserted that there have been but four cases of patients with multiple giant cell sarcoma reported in the American literature, although cases without giant cell tumors are more numerous.

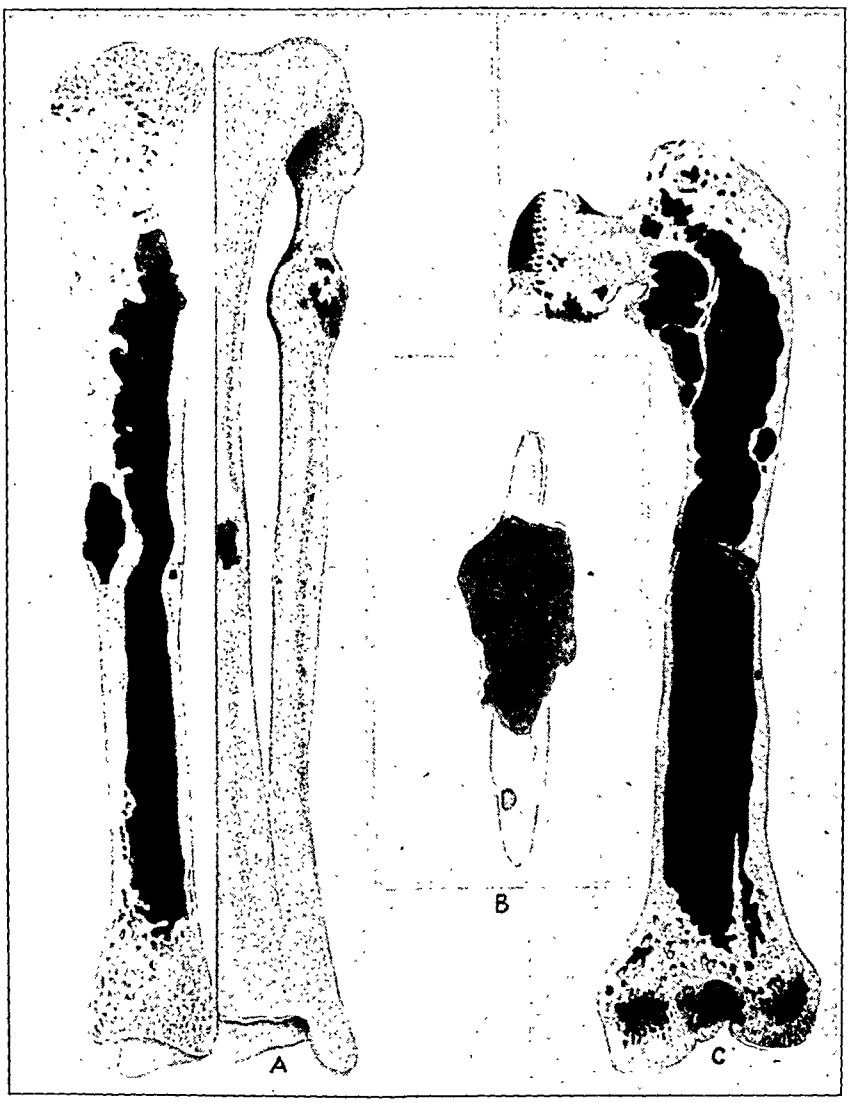

Fig. 16 (Case 7 in von Recklinghausen's article, 1891).—A, tibia and fibula with giant cell tumors; B, cyst in giant cell tumor of a rib, and C, femur showing giant cell tumors near lesser trochanter and smaller ones in shaft, also a fracture line through the midshaft.

19. Roth, M., and Volkmann, J.: Mitt. a. d. Grenzgeb. d. Med. u. Chir. **32**:427-453, 1920.

20. Barrie, G.: Ann. Surg. **71**:581-593 (May) 1920.

CLASSIFICATION OF TYPES

On reviewing the literature it becomes at once apparent that there are several different types or stages of the disease which have been described by various authors. There are certainly two outspoken groups, namely the cases with so-called giant cell sarcoma (myeloid sarcoma, giant cell tumor, hemorrhagic osteomyelitis, etc.); and those in which giant cell sarcomatous masses are not present. Fibrosis is a factor common to both groups and cyst formation is almost always present; but further subdivision is possible if cases are considered with regard to the occurrence of general malacia of the skeleton or hyperostosis of a portion of it. It is difficult to make a rigid classification as there is so much individual variation and overlapping from one variety to the other; but in general it is possible to group the cases according to the following scheme:

Group 1.—Without giant cell sarcoma:

A. With multiple cysts, fibrosis and malacia confined to a few bones.

B 1. With multiple cysts, fibrosis and predominant general malacia.

B 2. With multiple cysts, fibrosis, general malacia and hyperostosis.

Group 2.—With giant cell sarcoma:

A. With cysts, fibrosis and tumors, but no marked malacia.

B 1. With cysts, fibrosis and tumors, and marked malacia.

B 2. With cysts, fibrosis, tumors, malacia and hyperostosis.

The majority of the cases fall into Group 1; and it has been possible to find 37 in the literature. Of these, 22 fall into subdivision A; and 8 and 7 fall into subdivisions B 1 and B 2, respectively. In Group 2 there are 26 cases, the greatest number of which fall into subdivision B 1, 16; the other 10 cases being about equally divided between A and B 2.

Group 1 (A) is characterized by the fact that the disease occurs most often in young people, sixteen of the patients being under 30 years of age. If the first evidence of the process is taken into account, it is apparent that the onset is frequently in early childhood. In the accompanying table showing the subdivision, the earliest symptom which could be considered as referring to the disease has been taken as the onset of the process. In this way the origin of many of the cases can be traced back to the first 10 years of life. Burchard [21] has roentgen-ray proofs of cyst formation in his case at 18 months, and Bradfield [22] at 6 years. The oldest patients reported in this subdivision are 59 and 51 years of age; and there is evidence that the process in

21. Burchard, A.: Fortschr. a. d. Geb. d. Röntgenstr. **19**:113, 1912.
22. Bradfield, Cited by Elmslie: Reference 5, pp. 56-57.

TABLE 1.—CASES IN GROUP 1 (A) *

Case	Age	Sex	Cysts	Malacia	Duration	Symptoms	Treatment	Result	Pathologic Report
Barrie (Case 1915)	12	♂	Left femur; left pelvic bone; left fibula	Left femur	Since 5 years of age	Fracture	Osteotomy for deformity	Good	None
Barrie (Case 1918)	32	♂	Femurs; tibias; fibulas (small)	Not marked	Since 10 years of age	Pain	Medical	Good	None
Bradfield	6	♂	Humeri; femurs; left tibia	Both femurs bowed	Since 6 years of age	Fracture	Splinting	Good	None
Burchard	4	♂	Right femur; right tibia; right fibula	Femurs bowed	Since 1½ years of age	Limp	None	Good	No examination
Hamann[23]	23	♂	Both zygomatic bones; tibias	.....	Since 22 years of age	Swelling; pain	Hypophysis feeding	Good	No examination
Harting[24]	34	♂	Right ulna; right femur; tibias; humeri; clavicles, etc.	Not marked	Since 33 years of age	Fracture; pain	Cyst tapped	Good	None
Heineke[25]	24	♀	Femurs; left tibia; iliacs; right humerus, left great toe	Local only	Since 4 years of age	Fracture; pain	Osteotomy; exploration of cyst	Good	Fibrous marrow; cysts
Martin[26]	17	♂	Skull; dorsal vertebrae; humeri; femurs; leg bones	Right femur	Since early childhood	Fracture; pain; limp	Osteotomy	Good	Fibrous marrow, osteoid; malacia
Meyerding (Case 13)	17	♂	Right femur; right tibia; right fibula	Femur markedly bowed	Since 12 years of age	Fractures; malunion	Excision; bone graft	Good	Osteitis fibrosa cystica
Meyerding (Case 14)	21	♀	Right frontal; right radius; right humerus; right tibia; right fibula; right femur	Local only	Since 6 years of age	Fracture; tumor	Resection radius head, curetting and crushing in of tibia	Good	Osteitis fibrosa cystica
Meyerding (Case 15)	29	♂	Right humerus; both femurs; both tibias; both fibulas	Local only	Since 10 years of age	Fracture; nonunion	Excision; extension; bone graft	Good	Osteitis fibrosa cystica
Meyerding (Case 16)	26	♂	Left femur; left tibia; left fibula; left humerus	Local only	Since 12 years of age	Fracture; malunion	Excision; extension; bone graft	Good	Osteitis fibrosa cystica
Meyerding (Case 17)	30	♀	Both humeri; upper end of radius	Local only	?	Fracture	None	Good	No examination
Meyerding (Case 18)	19	♂	Fifth metacarpal of fourth and fifth fingers	Local only	Since 6 years of age	Swelling of right hand	Crushing of cyst walls	Good	No examination
Meyerding (Case 19)	41	♀	All the long bones	Local only	Possibly since 26 yrs. of age	Pain; swelling	Operation advised	Good	Section nonmalignant
Von Mickulicz[27]	?	?	Both femurs; radius; tibia	No	No details given				
Moll[28] (Case 1)	59	♀	Humeri; radii; ulnas; pelvic bones	Spine?	Since 41 years of age	Pain; limp; fracture	Extension	Good	None
Moll[28] (Case 2)	29	♀	Skull; right humerus; two left ribs; right femur; right tibia, etc.	Spine?, both tibias	Since 24 years of age	Pain; fracture	Operation; left tibia; cyst eradicated	Good	Fibrous marrow, osteoid
Morton	22	♂	General	Both femurs bowed	Since 3 years of age	Pain; fracture	Osteotomy for deformity	Good	Fibrous marrow, cysts
Ringel	20	♂	All the pipe bones and ribs	Local only	?	Fracture	Splinting	Good	No examination
Roth and Volkmann	51	♀	Tibias; left fibula; right radius; right femur; ribs; hands	Not marked	Since 41 years of age	Swelling; pain; fracture	Exploratory operation tibia	Good	Fibrosis osteoid
Wehner[29]	21	♀	Left radius; right scapula; left pelvis; calcanei cuboid, etc.	Both femurs	Since 3½ years of age	Pain; fracture	Not stated	Good	None

* In this and the following tables, ♂ indicates male and ♀, female.

23. Hamann, O.: Med. Klin. **16**: 63-64 (Jan.) 1920.
24. Harting, A.: Am. J. Roentgenol. **1**: 203-208 (March) 1914.
25. Heineke, H.: Beitr. z. klin. Chir. **40**: 481-498, 1903.
26. Martin, B.: Berl. klin. Wchnschr. **56**: 355-356 (April) 1919.
27. Von Mickulicz: Centralbl. f. Chir. **31**: 1323, 1904 (Discussed by Von Haberer).
28. Moll, K.: Beitr. z. klin. Chir. **118**: 433-445, 1920.
29. Wehner, E.: Fortschr. a. d. Geb. d. Röntgenstr. **27**: 140-144, 1919-1920.

each of these is ten years, or more, old. In general, the course is chronic and runs for years without change in its character. The most common manifestation of the disease is fracture, this leading to its discovery in most instances; other signs are bowing of the bones and tumor. Pain is sometimes a complaint and is usually of a rheumatic nature. The bones most frequently attacked are the pipe bones of the lower extremities, although the upper extremity is by no means spared. Cysts of the skull and ribs occur but not commonly. The bowing of the femurs is practically the only sign of malacia in these cases. The prognosis is good as to life; no fatalities being recorded for this group. The fractures heal well if properly treated; the patients stand operation well and the bone reacts to operation much the same as normal bone. Deformity is amenable to correction. The diagnosis is made from the roentgen-ray appearances, and microscopic section shows marrow fibrosis and numerous cysts with here and there a giant cell. Many of this group have not had a pathologic examination but have been classified here because they most nearly conform to the type.

In contradistinction to subdivision A, the cases recorded under B 1 seem to offer a very poor prognosis, ending in almost every instance in death. There are but few cases recorded from which to draw any definite conclusions; but of these all but one occurred in the female. Most of them are reported at a later age; and there is nothing to indicate a long chronicity from early years. Two cases reported by Joachimsthal [30] and Meslay [31] are exceptions to the last statement. The predominant character of the process is a genereal softening of the whole osseous system, a true osteomalacia, indistinguishable clinically from the puerperal form of that disease; in fact, all of these cases were reported by the various authors as the nonpuerperal type of osteomalacia. Von Recklinghausen has picked them out and classified them purely from the pathologic picture presented at necropsy. The symptoms given by this form are marked pain, numerous fractures, rapidly increasing deformity and helplessness, so that the patients all become bedridden in a short time and remain in a pitiful condition to the end. The course is downhill within a few years, with anemia and emaciation as accompanying evidence of the severity of the process. No treatment known appears to affect the progress of the malady. Diagnosis is made from the pathologic finding of a metaplastic picture in the diseased bones, a marrow fibrosis and cystic formation in addition to the halisteresis or calcium withdrawal.

Subdivision B 2 is practically identical with the preceding in every respect, except for the occurrence of hyperostoses of certain bones, notably the skull, making it difficult to differentiate the condition from

30. Joachimsthal: Verhandl. d. Gesellsch. d. charité Aertze **17:** 1911.
31. Meslay: Thèse de Paris, 1896; Rev. mens. d. mal. d. l'enf. **15:** 1897.

TABLE 2.—CASES IN GROUP 1 (B 1)

Case	Age	Sex	Cysts	Malacia	Duration	Symptoms	Treatment	Result	Pathologic Report
Albertin[32]	35	♀	Right humerus; both femurs; both iliac bones	Whole skeleton	Not observed clinically	.....	.....	Death	Fibrous marrow; cyst formation; malacia
Bramann[33]	34	♀	Both femurs; both tibia; left radius	Ribs; vertebrae; pelvis; both tibias, etc.	Since 30 years of age	Pain; deformity; fracture	Bed	Death; stomach catarrh; jaundice	Fibrous marrow; cysts- osteoid; numerous giant cells
Engel	55	♀	Pelvic bones; both humeri; both femurs; all vertebrae; both scapulas; both clavicles; sternum; ribs; right radius; jaw; few bones of hands and feet	General	Since 42 years of age	Pain; deformity; fractures	Bed	Death; pneumonia; pleurisy; anasarca	Fibrous marrow; cysts; malacia
Joachimsthal	13	♀	Both humeri; both ulnas; both radii; both scapulas; both clavicles; metacarpals; phalanges; most of ribs; pelvis; left fibula; left femur; tibia	Bones of extremities; left ribs	Since 6 years of age	Fracture; deformity	.....	Not stated	No examination
Koehl-Hanau[34]	18	♀	?	Femur; lumbar vertebrae	Since 46 years of age	Fracture; swelling of legs; pain	Bed	Death; ileus	Fibrous marrow; osteoid; a few giant cells; malacia
Langendorff and Mommsen	33	♂	Left humerus; left tibia; left fibula	General	Since 32 years of age; rickets as a boy	Pain; fracture; deformity	None	Death; asphyxia	Fibrous marrow; cysts; malacia; giant cells
Meslay	15	♀	?	Pipe bones; thorax; vertebrae	Since 13 years of age	Pain; fracture; deformity	Early osteotomy	Death; cause ?	Fibrous marrow; osteoid; malacia
Saxinger[35]	36	♀	Right tibia; left tibia; right femur; right forearm; left humerus	Vertebrae; ribs; pipe bones	Since 33 years of age	Fracture; tumor	Operation; bed	Death; heat	Fibrous marrow; osteoid; malacia

32. Albertin: Province méd., Lyon **4**: 541. 1890.
33. Bramann: Verhandl. d. deutsch. Gesellsch. f. Chir. **1**: 31-36, 1887.
34. Koehl-Hanau: Cor.-Bl. f. schweizer Aertze **22**: 1892.
35. Saxinger: Beitr. z. klin. Chir. **79**: 219-232, 1912.

TABLE 3.—CASES IN GROUP 1 (B 2)

Case	Age	Sex	Cysts	Malacia	Hyperostosis	Duration	Symptoms	Treatment	Outcome	Pathologic Report
Fujii[36]	36	♂	Vertebrae (2); left femur; right humerus	Sternum; right tibia; right fibula; ribs	Skull; left femur	Long time	Rheumatic pains	.....	Death; cause unknown	Fibrosis; bone building and withdrawal; few giant cells; cysts
Gottstein[37]	11	♀	Whole system	.....	Skull; hands	Since 4 years of age	Fractures	Not stated	Not stated	No examination
Katholicky[38]	30	♀	General	General	Skull; collar-bone; jaws; leg bones	Since 23 years of age	Pain; weakness; anemia	.....	Death; asthma; edema of lungs	Osteoid; sparse bone building
Klestadt[39]	35	♂	Left tibia; left femur; parietal bone	General	Skull	Since 14 years of age	Pain; fracture; deformity	.....	.....	No examination
Von Recklinghausen (1891) Case 5	66	♀	Right tibia; right femur; right calcaneus; right first metatarsal; right ulna; skull	Femurs; sternum; ribs; pelvis; spine	Skull; femurs	.....	.....	.....	Death; pneumonia	Osteitis; fibrosa; cysts; few giant cells
Von Recklinghausen (1891) Case 6	40	♀	?	Pelvis; pipe bones; spine	Skull; pipe bones	.....	.....	.....	Death	Skeleton only
Virchow[40]	?	♂	Fourth and fifth vertebrae; left tibia; right humerus; cranium; jaw?	Femurs; ribs; pelvis; spine; tibia	Skull; femurs; right humerus	.....	.....	.....	Death	Fibrosis; cysts; nests of giant cells

36. Fujii: Ztschr. f. Chir. **114**: 25-74, 1912.
37. Gottstein: Demonstration, Schleswig Gesellschaft für vaterländische Kultur in Breslau, July, 1907.
38. Katholicky: Wien. klin. Wchnschr. **19**: 1428-1429, 1906.
39. Klestadt, W.: Beitr. z. klin. Chir. **75**: 681-706, 1911.
40. Virchow: Tageblatt der Neun und Fünfzigen Versammlung Deutscher Naturforscher und Aertze, Berlin, 1886.

Paget's disease in some instances. Two of von Recklinghausen's original cases fall into this class. Von Recklinghausen concluded that the changes in his cases were all old and secondary to the active disease long ceased and that the hyperostosis and hardness of the new bone were secondary protective changes. This certainly does not hold for all the cases in this group as the active processes of calcium withdrawal and bone deposit are going on simultaneously, apparently representing two forms of reaction taking place much the same as in normal bone growth.

Both Groups B 1 and B 2 present deformities that are typical of this condition and advanced osteomalacia. The head is bowed down and forward, the chin resting on the sternum in the severest cases; the thorax is compressed laterally and bulges forward in a pigeon's breast deformity; the vertebrae are crushed together under the body weight, biconcave, "fish-like" vertebrae resulting; and the normal spinal contours are accentuated causing kyphosis in the dorsal, and lordosis in the lumbar region. Varying degrees of scoliosis occur. The whole result of the spinal change is to allow the patient to "sink together" and to make the arms seem disproportionately long for the body. Add to this the outward and forward bowing of the femurs and the forward bowing of the tibias and the attitude is that which has been aptly termed "anthropoid-ape like." The pelvis shows the most remarkable changes, being compressed at the sides, bulging forward at the symphysis in the "duck-bill" appearance, and the sacrum protruding into the pelvic cavity, giving the pelvic inlet the so-called "heart-shaped deformity."

Group 2 (A) is not represented by many reported cases, and Barrie was able to find but four in the American literature. One of these has been classed under Group 1 (A) because of inadequate pathologic examination. The only evidence we have that there were giant cell tumors in this case (Harting [24]) is a report of Kanavel [41] which came out a year later and states that in both cysts operated on "a granulomatous type of tissue was found." Barrie's case is remarkable in that there were no cysts present but numerous solid tumors, which he considered hemorrhagic osteomyelitis and which Ewing called giant cell sarcoma of the epulis type. In Crile and Hill's [42] case there is no mention made of cysts in the original report; but Dr. I. S. Hirsch of New York saw the same patient ten years later and said that "the roentgen ray showed multiple multilocular cystic tumors which had the typical appearance of what we now recognize as giant cell tumor." Haussling and Martland's [43] patient had a cyst in the right humerus. The foreign reports which seem best to fit into this class are those of

41. Kanavel, A.: Surg. Gynec. & Obst. **20**:745, 1915.

42. Crile, G. W., and Hill, W. C.: Surg. Gynec. & Obst. **3**:57-61, 1906.

43. Haussling, F. R., and Martland, H. S.: Ann. Surg. **63**:454-464 (April) 1916.

TABLE 4.—CASES IN GROUP 2 (A)

Case	Age	Sex	Cysts	Malacia	Tumors	Duration	Symptoms	Treatment	Outcome	Pathologic Report
Barrie..... Case 1920	50	♂	None.....	Not marked	Skull; ribs of right side; long bones of lower extremity	Since 42 years of age	Weakness; pain in the legs	Exploration in left tibia for examination	Good	Giant cell sarcoma
Crile and Hill..	22	♀	Not mentioned.....	Not marked	Right ulna; right os magnum; right metacarpals and general	Since 21 years of age	Pain; swelling	Exploratory operation	Good	Multiple giant cell sarcoma
von Haberer..	10	♂	Right parietal; right femur; left femur; pelvis; ribs, etc.	Femurs; right humerus; left tibia	Parietal; right femur; left femur; lower jaw	Since 5 years of age	Swelling; deformity; fracture	Excision of tumors for examination	Good	Osteoid; cysts; giant cell sarcoma; fibrous marrow
Haussling and Martland	25	♀	Right humerus.....	Not marked	Right orbit; right femur; right humerus; clavicles; fibula, etc.	Since 24 years of age	Weakness; pain; tumor	Curettage of tumors	Good	Giant cell sarcoma
Werndorff.....	9	♂	Right pelvis; right femur; right tibia; right fibula	Right femur; right tibia	Right femur; right tibia	From earliest childhood	Deformity right leg	Resection of tumor; right femur	Good	Giant cell sarcoma; cysts; fibrous marrow
Wrede.....	40	♀	Almost all the bones; cranium	?	Upper and lower jaws	Since 30 years of age	Swelling	Operation: removal of tumors	Not stated	Giant cell sarcoma

von Haberer,[44] Werndorff[45] and Wrede.[46] There is no definite age of onset, the age in the reports varying from 9 years to 50 years; but the tumors may run a course of several years without injuring the health. The distribution is quite general and it does not seem satisfactory to attempt to classify by regions as Elmslie[5] has attempted. For instance, tumors of the jaw may arise in young or old and may run a rapid or chronic course.

The symptoms most often given are swelling, deformity, pain and fracture. The tumors do not seem to affect the course one way or another; there is no tendency to malignant change or to metastasis; but local recurrence is common unless operative removal is thorough. Bloodgood[1] has demonstrated, however, that a local operation is all that is necessary, even in recurrent growths. The bone reacts well to operation and tends to fill in the defect with solid tissue. Large tumors can be excised and bone grafts substituted with satisfactory results. The prognosis is good in all cases in this class.

There is some factor present in divisions B 1 and B 2 which causes a widespread malacia and a very severe general reaction. The resemblance to the corresponding divisions of Group 1 is striking. One of von Recklinghausen's[8] original cases and both of his 1910 cases fall into division B 1, as well as Hirschberg's[7] case, which is often referred to as the first description of the disease. Apparently, the occurrence of giant cell tumors in osteomalacia is sufficient to classify the case as osteitis fibrosa and many of the sixteen cases which have been put in B 1 were originally described as osteomalacia with cysts and tumors. The disease originates later in life, as a rule, being noticed after 30 years of age in almost all of the reports. The symptoms are pain, fracture and deformity, and the course is downhill. The patients become weak, anemic, emaciated and bedridden. Death follows in practically every instance after a period of suffering. On section the tumors may be few or numerous—quite a number of cases have but a single small tumor, whereas in others the skeleton is peppered with growths. The tumors seem to bear no definite relation to the severity of the disease.

Division B 2 differs from B 1 only in the occurrence of hyperostoses and thickening of the skull, which make it necessary to differentiate this condition from Paget's osteitis deformans. There are but four of these cases. Perhaps a better classification would place in one group all cases with marked malacia, irrespective of the presence or absence of tumor growth, for Groups 1 (B) and 2 (B) are similar;

---

44. Von Haberer, H.: Ztschr. f. Chir. **31**:1323, 1904.

45. Werndorff, R.: Ztschr. f. orthop. Chir. **32**:122-133, 1908.

46. Wrede: Verhandl. d. deutsch. f. Chir. **51**:73-74, 1912; Zentralbl. f. Chir. **35**:1400, 1908.

TABLE 5.—CASES IN GROUP 2 (B 1)

Case	Age	Sex	Cysts	Malacia	Tumors	Duration	Symptoms	Treatment	Result	Pathologic Report
Butlin[47].....	50	♂	Left femur; right femur; right humerus	Femurs; calvarium; humerus; other bones	Jaw (2); sixth rib right	Since 43 years of age	Swelling; fractures	.....	Death; cause ?	Giant cell sarcoma; cysts; fibrous marrow
Davidsohn[48]...	58	♀	Both femurs.....	General	Tibia; patella; femurs	Since 56 years of age	Pain; fracture; edema	Medical	Death	Giant cell sarcoma; osteoid; fibrous marrow
Feldmann[49]....	28	♂	No roentgen rays....	General	Right lower jaw; left humerus; femurs ?	Since 17 years of age	Deformity; fracture; pain; swellings	Osteot.; medical	In poor condition when reported	No examination
Froriep.....	?	♀	Entire bone system; jaw	General	Pelvis; skull	Many years	Pain; fracture	.....	Death; cause ?	Fibrous marrow; giant cell sarcoma
Gaugele[50].....	36	♀	Sternum; ribs; vertebrae; humeri; right femur	General	Tibia; humerus; ulna	Since 28 years of age	Fractures; swellings; deformity; anemia; emaciation	Medical	Death; uremia	Fibrous marrow; giant cell sarcoma
Grashey[51].....	54	♂	One radius; one ulna; one metacarpal	Entire skeleton	Fifth metacarpal	Since 50 years of age	Weakness; fracture	.....	Not stated	No examination
Hart[52].....	74	♀	General.....	General	General	Since 69 years of age	Bedridden; fracture; deformity	.....	Death; bronchitis and pneumonia	Giant cell sarcoma; cysts; fibroid marrow; osteoid
Hirschberg.....	35	♀	Left humerus; left femur; left tibia	General	Left tibia; left humerus; left femur	Since 31 years of age	Swelling; pain; emaciation	.....	Death; marasmus	Giant cell sarcoma; fibrous marrow; cysts; malacia
Lissauer[53].....	36	♂	Numerous.....	?	Right forefinger; Middle phalange	Since 8 years of age	Pain; swelling; fracture	.....	Death	Fibrous marrow; giant cell sarcoma; bone atrophy
Meyer[54]..... Case 1	43	♀	Left femur; left tibia; left calcaneus; lumbar vertebrae	Vertebrae especially	Right femur	Indefinite, 10-14 years	Pain; fracture	Operation	Death; cause ?	Giant cell sarcoma; cysts; fibrous marrow
Meyer..... Case 2	36	♂	Right femur; pelvic bones; skull	General	Multiple	Several years	Pain; fracture	Splint	Death; pneumonia	?
Von Recklinghausen (1891) Case 7	40	♂	Ribs, also in the tumors	General	Left ilium; upper and lower jaws; radius; tibia; ribs; fibula; femur	No data	Pain; fracture; deformity	.....	Death; marasmus	Giant cell sarcoma; cysts; fibrous marrow
Von Recklinghausen (1910) Case 1	33	♀	Left femur; right fibula; right tibia; cranium; metatarsals; metacarpals; phalanges	General	Lower end; left femur	Since 31 years of age	Fracture	Bed	Death	Cysts; fibrous marrow; one giant cell tumor
Von Recklinghausen (1910) Case 2	50	♀	General.....	General	Right pubis; horizontal ramus	Since 48 years of age	Unsteadiness; emaciation; pain; pallor	Bed	Death	Giant cell sarcoma; cysts; fibrous marrow; malacia
Rehn[55].....	23	♀	Pelvic bone; right	General	Right ulna; right numerous in both femurs; ribs	Since 14 years of age	Anemia; pain; swellings	Excision of tumors	Death; heart failure	Giant cell sarcoma; osteoid; fibrous marrow
Schönenberger[56]	33	♀	Left tibia..... fibula	General	Pelvis; right humerus; both tibias; pelvis; left pelvis; both femurs	?	Pain in back and legs	Medical	Death; bronchitis	Giant cell sarcoma; fibrous marrow

47. Butlin, H. T.: Tr. Path. Soc., London, 31: 277-279, 1880.
48. Davidsohn, C.: Charité-Ann. 28: 741-753, 1904.
49. Feldmann, G.: München. med. Wchnschr. 48: 1840-1842, 1901.
50. Gaugele, K: Arch. f. klin. Chir. 83: 953-975, 1907.
51. Grashey: Atlas Chirurgisch Pathologischer Röntgenbilder; Lehmann's Medizinscher Atlas, 1908, vol. 6.
52. Hart, C.: Beitr. z. path. Anat. 36: 353-374, 1904.
53. Lissauer: Monatschr. f. Unfallheilk. 12: 51-56, 1905.
54. Meyer, O.: Frankfurt. Ztschr. f. Path. 20: 115-159, 1917.
55. Rehn, L.: Verhandl. d. deutsch. Gesellsch. f. Chir. 33: 424-431, 1904.
56. Schönenberger, W.: Arch. f. path. Anat. 165: 189-226, 1901.

TABLE 6.—CASES IN GROUP 2 (B 2)

Case	Age	Sex	Cysts	Malacia	Tumors	Hyperostosis	Duration	Symptoms	Treatment	Result	Pathologic Report
Hartmann[57]...	28	♀	Left iliac; right femur	Left femur; right femur	Left iliac	Skull	Since 15 years of age	Pain; deformity; swelling	Operation for tumor; operation for correction; opration for drainage	Death; operative collapse	Cysts; giant cell sarcoma; fibrous marrow
Kolisko[58].....	30	♂	Numerous.....	General	Numerous	Skull	.....	.....	.....	.....	Giant cell sarcoma; cysts
Lötsch.....	57	♀	Skull; ribs; hands; iliac bones; vertebrae; humeri; clavicle; wrists; right ulna; right radius; left tibia	General	Left tibia; right tibia	Skull	Since 47-50 years of age	Pain; emaciation; swellings; fracture	Exploratory operation, tibia	In fair condition at report	Giant cell sarcoma; cysts; fibrous marrow
Monckeberg[59]..	55	♀	Right humerus; right clavicle; right pelvic bone; right femur; jaw	General	Jaw; ninth rib	Skull	Since 39 years of age	Fractures; swelling of jaw	Extirpation of jaw tumor three times	Death	Giant cell sarcoma; cysts; osteoid; fibrous marrow

57. Hartmann, K.: Beitr. z. klin. Chir. **73**: 627-650, 1911.
58. Kolisko, A., Discussed by Katholicky: Wien. klin. Wchnschr. **19**: 1428, 1906.
59. Monckeberg: Verhandl. d. deutsch. path Gesellsch. **7**: 232-237, 1904.

and in a like way all cases with local softening only, because Groups 1 (A) and 2 (A) are also much alike. But in working through the numerous and confusing reports, the different factors were separated and cases assorted as nearly as possible by the presence or absence of these conditions.

PATHOLOGY

In his earliest description von Recklinghausen [8] regarded the disease as an inflammatory process, a chronic productive inflammation whereby fibrous tissue was substituted for bone structure, resembling in this way fibrous myocarditis or liver cirrhosis. In his later work he changed his belief and thought that he was dealing with a metaplasia of existing tissue and a calcium withdrawal. Whichever view is correct the pathologic picture is fairly constant. It is characterized by the building of a fibrous marrow which extends through the spongiosa strands and works its way into the cortical bone. This young fibrous marrow consists of finely fibrillar thready connective tissue with few nuclei, and is usually not vascular. In places it becomes infiltrated with round cells and appears as an obvious granulation tissue. The process of resorption goes on hand in hand with the new formation of tissue, differing from the normal in the persistence of the osteoclast giant cells, which gather together in small clumps. There is also some barrier to the deposition of calcium salts so that the bone formation remains in the osteoid tissue stage instead of going on to completion. The result of this resorption is that the bone is left weakened and softer than normal so that a true malacia occurs. A further step is the formation of cystic spaces in the poorly vascularized connective tissue. This is explained by von Recklinghausen [8] and Fujii [36] as simple atrophy and rarefaction through softening. The cysts always lie in the middle of the fibrous marrow at first and their walls are formed of thick fibrillae of this tissue, having a concentric arrangement and bound together by short strands. True epithelial or endothelial linings are lacking; but in spite of this the cavity walls are fairly smooth. The contents are usually fluid—thin or gelatinous, water clear, yellow or reddish according to the amount of blood extravasation. The changes noted occur in the beginning in circumscribed patches in individual bones. The whole bone becomes involved later by broadening out and confluence of the pathologically changed places. The epiphysis and periosteum, as a rule, remain unchanged. The metaphysis in young bone and the diaphysis in formed bone seem to be the places of predilection.

The formation of the giant cell tumors may or may not be extensive. In all cases, giant cells are present, but in one group in not sufficient numbers to form the masses of brown red tissue which has received so many names and caused so much controversy as to its nature.

There have been several quite divergent views as to the origin of these cells. Adami [60] believes that they are myeloplaxes and that they differ from foreign body giant cells in the even distribution of their nuclei throughout the cell body and in the absence of central degeneration of the cell, and that they differ from parenchymatous (true tumor) giant cells in that their nuclei are well formed, of uniform size, and lack mitotic figures. Mallory,[61] on the other hand, considers them to be foreign body giant cells due to fusion of endothelial leukocytes and attracted into the tumor by the presence of lime salts which they dissolve and remove. Both observers agree that they are similar to the osteoclasts normally present in Howship's lacunae. Barrie [62] has reproduced the medullary giant cell sarcoma experimentally by embedding a piece of sterile gauze in the bone marrow, and he agrees with Mallory as to the origin of these cells. He believes that they will be found wherever a suitable irritative agent is present and he regards them as evidence of a chronic nonsuppurating form of osteomyelitis. Haussling and Martland [43] are inclined to support Barrie's contention. Lubarsch [63] attempts to differentiate the giant cells in epulis, giant cell sarcoma of the long bones and giant cell building in osteitis fibrosa. He argues that in the first two conditions abundant pigment is present but never inside the giant cells; that in epulis the giant cells are uniformly packed together, and that in giant cell sarcoma of the femur and tibia one finds considerable polymorphism of the cells—hyperchromatic and irregular nuclei—mitoses, etc., are never wanting. In osteitis fibrosa, on the contrary, the giant cells are more or less full of pigment; they are irregularly distributed, clumped in one place and lacking in other places; mitoses are always wanting, also polymorphism, and there is seen a distinct transition of fibrous tissue to giant cell formation. Von Recklinghausen [8] disagrees entirely with this view and considers both epulis and giant cell sarcoma of the long bones to be the products of osteitis fibrosa.

There is abundant pathologic and clinical evidence at hand now, however, firmly to establish the benign nature of these giant cell growths. They grow locally only, do not metastasize, recur only on incomplete removal, and may be removed by local operation several times if necessary. The growth is expansive, leading to absorption of the surrounding bone and only very seldom breaking through the periosteum. Hemorrhage and tissue infarctions are common findings

60. Adami, J. G.: The Principles of Pathology, Ed. 2, Philadelphia, Lea & Febiger, 1910, vol. I.

61. Mallory, F. B.: Principles of Pathologic Histology, Philadelphia, W. B. Saunders Company, 1914.

62. Barrie, G.: Ann. Surg. **65**:151-158 (Feb.) 1917.

63. Lubarsch, cited by Gaugele: Reference 49, pp. 968-971.

in and around the giant cell collections and there is probably some relationship between the two. Barrie [62] believes that hemorrhage is an essential part of the production of the giant cell growths. The extravasated blood may well act as an irritant and attract these cells to its neighborhood, where they certainly appear to function as scavengers loading their cytoplasm with blood pigment. Blood pigment occurs also free in clumps in the tissues and is a sure evidence of old hemorrhage.

Where large collections of these cells have a poor central blood supply, softening occurs and cyst formation takes place. Thus in the second large group—fibrosis with tumors, two varieties of cyst may be found. Mönckeberg [59] has called attention to these:

1. Fibroma cyst—smooth softening with slight growing tendency, very little or no pigment, and marked proliferation in the surrounding bone.

2. Giant cell sarcoma cysts, arising through softening and extravasation of blood, rich in pigment, which showed great growth tendency, marked absorption of surrounding bone.

In the very extensive involvement of the skeleton the calcium withdrawal leads to marked changes. The bone loses its hardness, is liable to fracture and becomes bowed and deformed in many places. The softness is so marked that it is often possible to cut the bone with a knife at necropsy. The cortex and marrow melt into each other and cannot be differentiated. The characteristic deformities have been discussed under classification.

The pathologic fractures which are so common heal well and within normal time limits in spite of the changes in the bone. This is explained by the integrity of the periosteum which seems to be remarkably spared in this disease. Osteotomies heal well and Hartmann [57] has noted oftentimes an exuberant callous formation with long persistence.

The pathology of the internal organs shows practically nothing of moment. There is a decided contrast between the extensive pathologic condition of the bone and the relatively normal general findings.

Fujii [36] asserts that he is able to differentiate pathologically between osteitis fibrosa and osteomalacia, and offers the following criteria:

Osteomalacia.—This is marked by typical broad smooth osteoid seams without giant cells; bone corpuscles in general sparse and distributed irregularly, in the peripheral part of the bone framework, oftentimes wanting; bone framework, short, plump and scanty; bone marrow shows no connective tissue change.

Osteitis Fibrosa.—This is identified by small osteoid margins with formation of numerous lacunae which are filled with more or less numerous osteoblasts; bone corpuscles numerous and distributed regu-

larly, reaching to the free edges of the bony framework and communicating with one another by numerous long bony canals; bone marrow characterized by connective tissue change.

Axhausen [64] takes exception to this view and it does not coincide with Pommer's [65] ideas of the pathology.

ETIOLOGY

The etiology of the condition is obscure at present, and we have no definite factor that can be held responsible. The disease is certainly not due to any of the ordinary bacteria, as repeated attempts to grow microscopic organisms have been unsuccessful. The possibility that a filtrable virus may be the causative agent has as yet nothing to substantiate it.

The endocrine glands may have some bearing on the bone metabolism; but no constant findings have been reported. Hamann [23] cites a case which he studied, and in which he claims a remarkable cure was accomplished from the administration of hypophysis tablets. He draws the very sweeping conclusion from this case that osteitis cystoplastica, leontiasis ossea, and Paget's disease are due to hypofunction of the hypophysis. Nevertheless, the hypophysis has been reported without change in many of the necropsies of other observers. Meyer [54] found a tumor of parathyroid origin in a case of his and cites other similar findings of Schmorl, Erdheim, Askanazy, Strada, and Bauer in other closely related forms of bone disease. He concludes, however, that the finding is accidental and not a causative one. The other endocrines, especially the ovaries, have had their share of attention, but nothing final has been decided. There can be no question that there is some fundamental change in the calcium metabolism of these cases. It would be interesting to know whether the calcium salts were retained in high concentration in the blood and excreted more rapidly than in the normal, analogous to the sugar changes in diabetes mellitus.

ROENTGEN-RAY APPEARANCES

The roentgenogram in generalized osteitis fibrosa is typical. There is not the same necessity of differentiating these cases from the rarefactions due to acute infection—tuberculosis, syphilis, etc.—that exists in the single cyst cases; and even the malignant tumors of bone are rarely of such widespread occurrence. The only real conditions that might be confused with this form of the disease are osteomalacia and Paget's disease. In the first place, the periosteum does not take part in the disease and is smooth and normal in outline, except at the

64. Axhausen, G.: Arch. f. klin. Chir. **102**:281-331, 1910-1911.
65. Pommer: Untersuchungen über Osteomalazie und Rachitis. Leipzig. 1885, p. 87.

fracture places where it often heaps up a well marked callus. The epiphyses and joint surfaces also tend to remain unaffected. The cortex and marrow cavities show marked changes; the latter shows widening and irregularity in outline, and in places a mottled appearance, with here and there clear spaces which do not seem to have any calcium content. The cortical bone is also irregular, mottled, and in places thinned to a few millimeters only or destroyed. It is impossible at times to tell where the cortex leaves off and the marrow cavity begins, the process becomes so confluent. The whole bone picture is also striking because of the washed-out calcium content which gives a general translucence, and a honey-combed picture where cystic changes have occurred. Occasionally, cystic cavities show fine septal bridges making compartments, which some of the French observers compare to the cut surface of a tomato. Taken as a whole, the translucence of the bone, the irregular, rarefied patches and long porous streaks, the enlargement of the marrow space, and the replacement of the cortical bone and its lack of definition from the marrow cavity constitute a picture not liable to be mistaken for any other condition. The bony deformities are marked, and the bones are angulated where fractures have occurred so that a smooth curve is not the usual finding. The bones show expansion and reinforcement on the concavity of the cortex, but the latter never of marked density.

The roentgen-ray diagnosis from osteomalacia is not possible in one group of cases; the other offers no difficulty. Osteomalacia is usually a condition of marked calcium withdrawal and presents a uniform thinned shadow scarcely more dense than the surrounding soft parts. The cortical bone is regularly atrophied; cystic spaces occur but rarely, and fractures remain with very little sign of healing. Deformities are angular and the bone looks crumpled and bent, as if putty-like.

Paget's disease of the bone is in decided contrast, with its rough, irregular periosteum, tremendously thickened subperiosteal cortical bone, often two or three times the normal, marrow space that is mottled and gives a cloudy, furred, smoky appearing shadow generally distributed over the whole bone even to the epiphyses and joint surfaces, smooth even curves to the deformed bones, well healed fractures when they occur, and is especially distinctive with its markedly thickened calvarium which looks as if it were filled with cotton wool or rolling smoke. Cystic spaces do occur but are rarely more than 1 or 2 cm. in diameter. The outstanding feature is proliferation in this condition; the predominant thing in osteomalacia is calcium withdrawal, the so-called "bone-atrophy"; and the latter condition with bone replacement by cystic cavities, and tumors characterizes osteitis fibrosa cystica.

DIAGNOSIS

In one group of cases, diagnosis is made from the onset in early life, the chronic course, the absence of symptoms, the occurrence of fracture from a trifling injury, the good healing, and the characteristic roentgenogram. The slowly developing deformity of one or more bones is also a feature.

In the second group, the onset occurs later in life and practically all the cases have been described as osteomalacia, from which it is distinguished by microscopic examination of tissue. This is a very much more severe type of involvement and the general condition is bad; the deformities are marked and crippling, and the suffering is intense.

DIFFERENTIAL DIAGNOSIS

There are two conditions that may simulate generalized osteitis fibrosa cystica, and these are differentiated without much trouble.

The first of these diseases is osteomalacia, which exists in two general forms, the puerperal and the nonpuerperal. The puerperal form of the affliction comes on usually after twenty years in women who are pregnant or who are in the puerperium, and manifests itself first in the pelvis and bones in relation to it. There is a softening of these skeletal parts, often accompanied by pain and tenderness over the affected regions. Deformity of a characteristic type follows quite rapidly, the gait becomes waddling and uncertain, and the patients cannot get about with facility. The kyphoscoliosis, sinking in of the sternum, decrease in height, heart-shaped pelvis, bowed femurs with sharply contoured angulations, and the evidence of general metabolic disturbance—anemia, and emaciation—are not seen in any other condition, except one of the forms of generalized osteitis fibrosa, from which no distinction can be made in life. The nonpuerperal form may occur at any time of life, and is in no way different from the description given above. It may occur as juvenile or senile osteomalacia, though both these groups have been questioned, especially by von Recklinhausen. The roentgen-ray appearances serve in the differential diagnosis.

Paget's disease comes on later in life as a rule, though cases have been reported in the early twenties. It is more common in men; the course is a steady, slow progression, and does not go by fits and starts as in generalized osteitis fibrosa. Fracture is a relatively rare occurrence, in decided contrast to its frequency in osteitis fibrosa cystica. Cysts when they occur are very small, the skull is more frequently involved and the roentgenogram is entirely distinct.

PROGNOSIS

The groups of the disease not associated with general malacia, whether with or without giant cell tumors, have a very favorable outlook. The course is long and the progress slight. The fractures heal well, and deformed bones can be straightened by operation. This group of patients are not disabled by the disease unless malunion or nonunion results from fracture.

The other group in which general malacia plays a leading rôle has a much less promising outlook. The disease progresses with disabling deformities and pain, and, though it may extend over some years, it is in other cases quite rapid. The termination is with wasting anemia and bedridden invalidism.

TREATMENT

Nothing is known that will check the underlying metabolic process. The use of phosphorus and arsenic has not been successful in this class of cases. Calcium feeding does not seem to be of any use. Organotherapy can be tried; but reports are conflicting as to its value. Removal of the ovaries has led to no beneficial results. The treatment of symptoms is indicated whenever opportunity arises. Pain should be controlled if necessary by use of coal tar products; opiates should not be used on account of the chronicity of the condition. Fractures should be splinted as in ordinary cases unless a chance is offered of correcting the deformity by this means. Osteotomy should be resorted to freely and without anxiety as to the result when marked deformity demands correction. Malunion and nonunion of fractures have been successfully treated by freshening the ends and by the use of bone grafts (Meyerding[4]).

ACUTE HEMATOGENOUS OSTEOMYELITIS

CLARENCE L. STARR, M.D.
TORONTO, CANADA

In view of the fact that an early diagnosis is rarely made in cases of acute osteomyelitis, and that the recognized textbook treatment of this condition in the early stage is open to question, it seems desirable that the subject should be reviewed and the experience of a large hospital clinic placed before the surgical public.

The condition which we call osteomyelitis is essentially an inflammation of all the structures of the bone, and really should be designated a periosteomyelitis. It seems incredible that an acute infection could be limited to the cancellous bone or to the periosteum, in view of the easy access and free communication between these by means of the haversian canals and para-epiphyseal line.

ANATOMIC CONSIDERATIONS

It is necessary in studying this problem to remember some of the anatomic features as they relate to bone growth and development. The circulation of an ordinary long bone, as described by Lexer, is derived from three sources:

The nutrient artery enters the shaft at about its middle and divides, sending branches to either extremity, which, after numerous divisions, end in fine capillaries near the juxta-epiphyseal line or metaphysis.

The epiphysis gets its blood supply from the cortical branches, which find their way in from the cortex along the epiphyseal line and are distributed to the whole of the epiphysis.

The cortex of the entire shaft receives its nutrition from the periosteal vessels.

The epiphysis in each long bone is, in most cases, not united by bone until early in adult life. The growth takes place on the diaphyseal side of the growing line, as can be demonstrated by an attempt to separate the epiphysis.

By forcibly tearing off the epiphysis from the shaft in the growing bone, it is seen that the separation takes place at the diaphyseal side of the epiphyseal line, and leaves an irregular series of indentations. In the child, the periosteum continued down from the shaft dips into the epiphyseal line and becomes densely adherent at this point. This condition prevents, in most cases, direct extension of infection to the joint.

ETIOLOGY

Osteomyelitis is practically always a blood-borne infection from a primary focus situated elsewhere in the body. This primary focus may

be the tonsils or mouth cavity, but much more frequently some local infection of the skin, as boils or infected wounds and cellulitis. The commonest type of organism is *Staphylococcus aureus* and some strains of the streptococci.

The blood stream infection is most frequently transient and cultures may be obtained but rarely. When the blood culture is positive and repeated, a general septicemia results, and recovery is uncommon.

The element of trauma must play a part in determining the seat of invasion. When one remembers that it is possible to wrench an epiphysis in a growing child sufficiently to produce pain or even hemorrhage

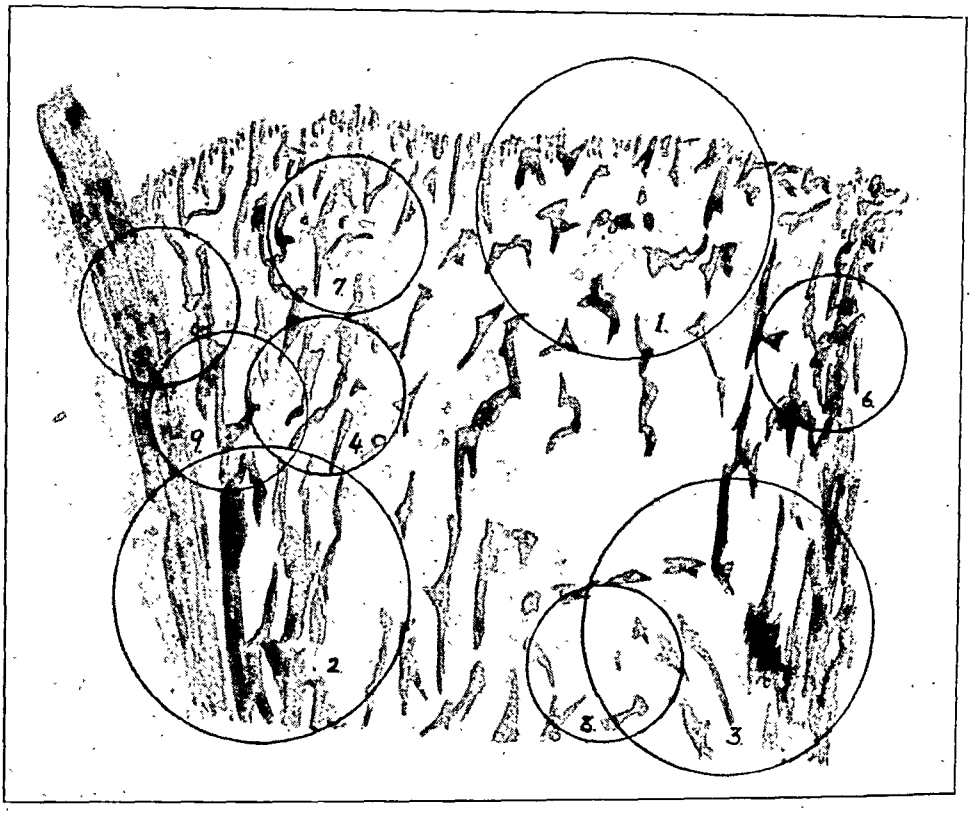

Fig. 1.—Drawing from photomicrograph, showing usual type of bone inflammation.

into the line of growth, it is easily seen that the resistance will be lowered at this point, and a good culture medium provided as well. Hence it is probable that an injury may be the determining factor in localizing the site of invasion.

In our experience, the bones primarily affected are, in order of frequency, the upper end of the tibia, the lower end of the femur, the lower end of the tibia and fibula, the lower end of the humerus, the upper end of the femur, the lower end of the radius, and then the ulna, the bones of the tarsus, the crest of the ilium and the scapula, in that order.

These findings strengthen the view that trauma is a distinct factor in the disease, as it is noted that they show a greater percentage of invasion at the points most subject to injury. The lower extremity shows a higher percentage than the upper, and the neighborhood of the knee the greatest of the lower extremity.

AGE

Acute osteomyelitis is essentially a disease of childhood. It occurs at this period because the actively growing bone is less resistant to infection than adult tissue, and because trauma at the epiphysis is possible only at this age.

It is extremely rare to find osteomyelitis in the adult, aside from that due to direct injury to bone and primary infection, such as is found in compound fractures and bullet wounds. The commonest age is from 2 to 10 years.

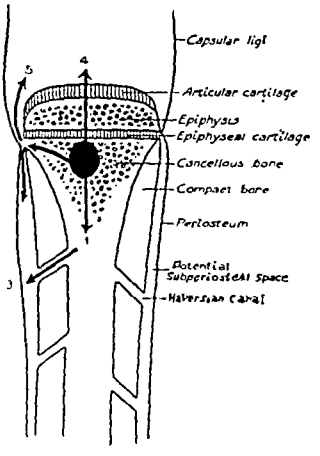

Fig. 2.—Schematic representation of a long bone, showing direction of possible spread of infection from the metaphysis (para-epiphyseal or juxta-epiphyseal region). (From Choyce, System of Surgery.)

SEX

Boys are slightly more frequently affected than girls, possibly owing to increased opportunity of injury.

PATHOLOGY

It is obvious that a true conception of the pathology of this condition must be built up, as upon this the treatment to be adopted necessarily depends. Our experience does not entirely correspond to the average textbook teaching, hence it is presented in more detail than might seem essential.

The offending organisms are carried through the blood stream to reach the finer capillaries in the juxta-epiphyseal region of a long bone. If the general resistance of the individual is lowered by ill health,

and the local resistance is lowered by trauma, the infective process is started, and a small inflammatory area in the cancellous bone near the epiphyseal line results. This area shows the usual type of bone inflammation, as is illustrated by Figure 1.

The commonly accepted view is that from this focus the infection spreads with greatest rapidity through the cancellous bone to the medullary canal, and in a few brief hours may involve the whole interior of the shaft. Then it is said to spread outward through the haversian canals to the periosteum, and to undermine this structure.

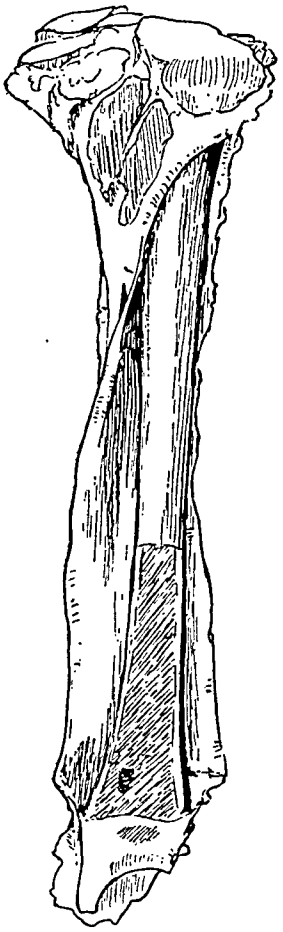

Fig. 3.—Necropsy specimen, showing early focus of infection in the tibia.

That it may spread downward through the epiphysis, and at times under the capsule of the joint, where it invades the joint, is also generally accepted.

Figure 2, taken from Choyce's System of Surgery, illustrates the commonly accepted view of the spread of infection. It is noted in the diagram that the chief spread is through the cancellous tissue into the medullary canal. In the text it is stated that "infection tends to spread through the cancellous tissue into the medulla, and *perhaps* also down under the periosteum."

In our experience, the focus of infection located in the metaphysis spreads fairly rapidly along the line of the epiphysis to reach the periosteum. Frank pus is here formed, and the infection spreads rapidly under the periosteum, stripping this structure from the bone surface. It spreads less rapidly through the cancellous tissue to the medullary canal, and the medullary canal is more frequently invaded through the haversian canals, secondarily to the periosteal infection.

This seems to be susceptible of demonstration by necropsy specimens which have been recovered from patients dying early of general septicemia, from roentgen-ray findings of the cases seen at all stages, and from animal experiments.

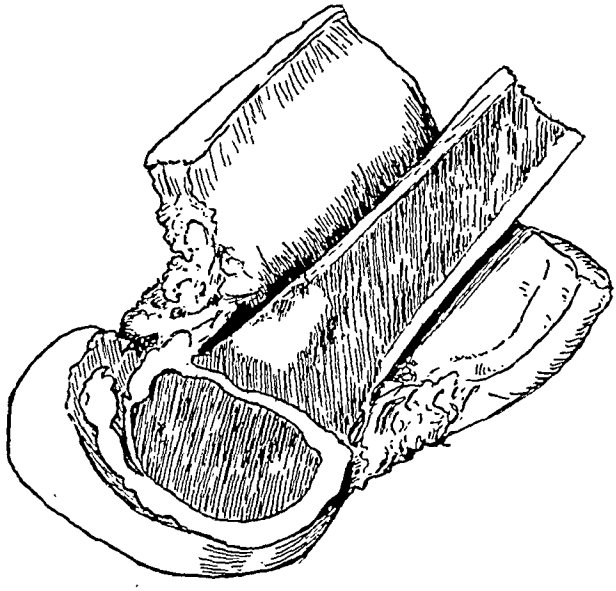

Fig. 4.—Necropsy specimen, showing early infection with inflammatory changes, marked at the periosteum and epiphyseal line.

The tibia shown in Figure 3 was recovered at necropsy from a child, aged 2 years, who died of septicemia forty-eight hours after the onset of symptoms. It is readily noted in the specimen that the focus of infection is just above the lower epiphyseal line, and of comparatively small extent. The gross appearance shows the inflammatory area localized in this region. The microscopic section shows large colonies of cocci in the same area, with marked infiltration of the cancellous tissue by large mononuclear leukocytes, and already some degeneration showing areas of necrosis. Higher up the shaft and in the medullary canal, there is no gross appearance of inflammation, and the sections show no organisms or evidence of inflammatory change.

The periosteum shows intensive infiltration in the neighborhood of this focus, and, as shown in the illustration, is stripped completely

from one epiphysis to the other and for nearly half the circumference of the shaft. There is marked inflammatory change throughout the whole area of the stripped periosteum.

The culture from this pus showed a hemolytic streptococcus, and a culture from the blood of the patient before and after death showed the same organism.

The specimen shown in Figure 4 was obtained at necropsy from an older child who died, on the third day after the onset of symptoms, of

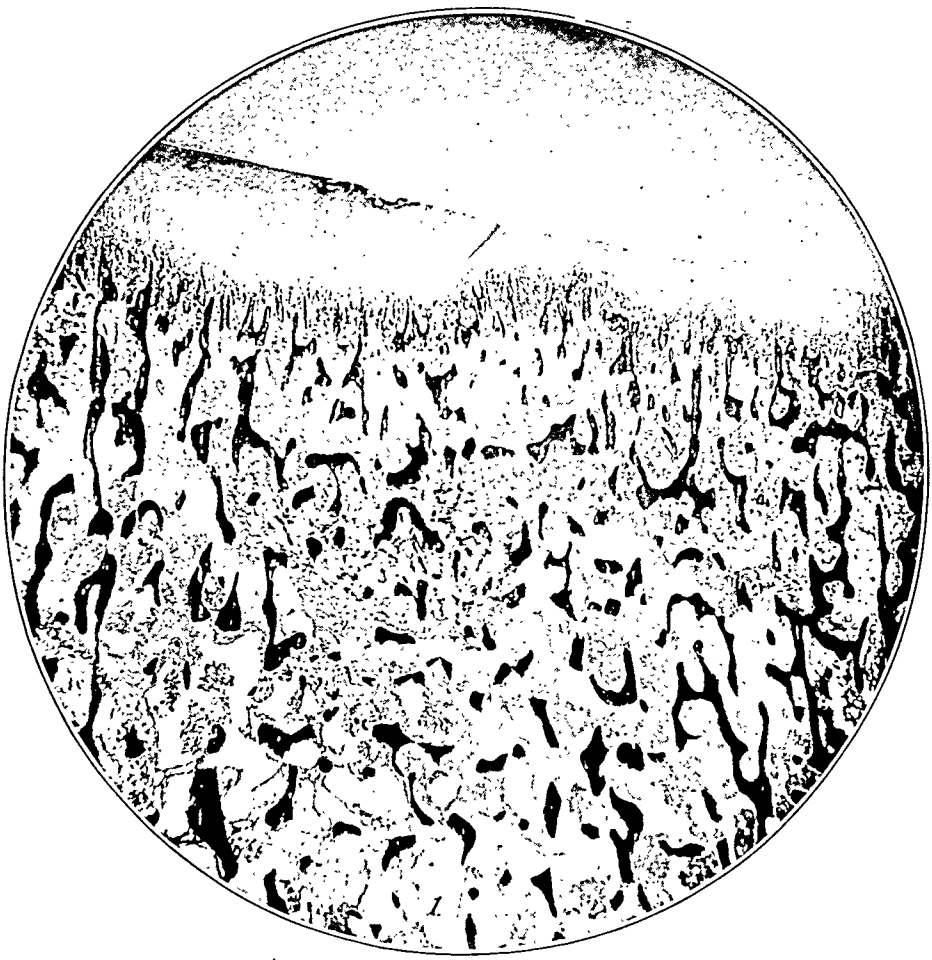

Fig. 5.—Photomicrograph of section from specimen shown in Figure 4.

acute septicemia. This shows even more characteristically the points brought out in Figure 3, but the periosteal stripping is not so extensive. The gross appearance shows an irregular area of gray necrosis, surrounded by dense infiltration of the cancellous tissue and an extension to the periosteum, with periosteal stripping for about 3 inches (7.6 cm.) up the shaft, and about two-thirds around the circumference of the shaft.

Figure 1, and the microscopic sections, present the microscopic appearance of this specimen and show a marked inflammatory process in the cancellous portion of the bone, concentrated and apparently most acute at the epiphyseal line. There are large colonies of cocci, with marked infiltration of the cancellous bone with large mononuclear leukocytes. Many of these have degenerated, leaving masses of necrotic material. There are large numbers of giant cells or osteoclasts in this area, which have dissolved the bone salts and left little depressions.

Fig. 6.—Photomicrograph of section from specimen shown in Figure 4.

The inflammatory exudate extends outward, and involves the periosteum on each side, showing diffuse and focal areas of infiltration with these large mononuclear cells. In the periosteal area, there is a moderate endarteritis, and some of the lymphatics are filled with cocci. Small areas, as indicated in the illustration by rings, show varying concentration of inflammation, greatest at the epiphyseal line and along the periosteal margins, as shown in Figures 5, 6, 7, 8, 9, 10, 11 and 12.

Figure 13, taken at the highest point of the cancellous tissue, near the center and approximating the medullary canal, is shown free from inflammatory exudate.

ROENTGEN-RAY FINDINGS

There are several facts of importance in the study of the roentgenograms.

1. Roentgen-ray findings are always negative in the early stages. It is not until gross destruction of cancellous bone has taken place, or until new bone begins to develop as an involucrum, that the roentgeno-

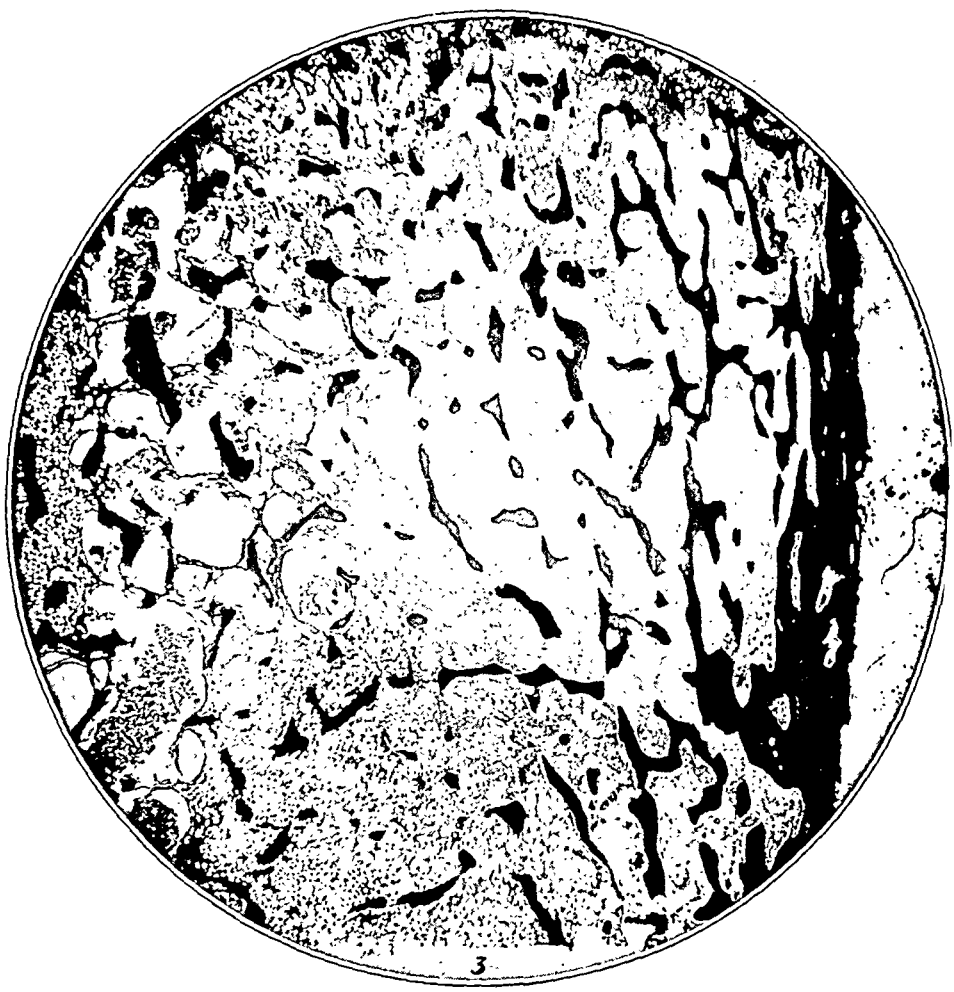

one, and no bony change was reported. On admission, on the same day that the accompanying roentgenogram (Fig. 14) was made, incision demonstrated pus in fairly large quantity under the periosteum, firm attachment of the periosteum at the epiphyseal line, and the periosteum stripped nearly to the upper end of the shaft.

Figure 15, taken six months later, shows the amount of the destruction of the shaft.

2. Roentgenograms of cases of osteomyelitis which have been opened through the periosteum even moderately early, all show a fairly

Fig. 8.—Photomicrograph of section from specimen shown in Figure 4.

similar picture. The bone changes always extend farther up the shaft on the periosteal side, than in the medullary area, and for the most part the periosteum is stripped higher on one side than on the other, and consequently, the destroyed part is wedge-shaped, with the base at the epiphysis and the apex on one side of the shaft.

Figure 16 shows a much greater advance of the disease along the cortical area than in the medullary area. This roentgenogram was

taken one month after onset, and the physician had evacuated pus from under the periosteum on the seventh day. The relief of tension under the periosteum had at once limited the extension of the disease both in the medullary area and under the periosteum.

Fig. 9.—Photomicrograph of section from specimen shown in Figure 4.

Fig. 10.—Photomicrograph of section from specimen shown in Figure 4.

3. Roentgenograms of still later cases, when the tension of pus under the periosteum has not been relieved, show a characteristic "spotty" infection, as if the organisms had been poured through the cortex at various places. This is well shown in Figure 15, where the periosteum was not incised until nearly entirely stripped.

Figure 17 was taken six months after the onset, during which time no treatment had been instituted, but the abscess had been allowed to burst. This also shows the spotty character of the infected bone, as well as areas of shaft and medulla which appear quite normal.



Fig. 11.—Photomicrograph of section from specimen shown in Figure 4.

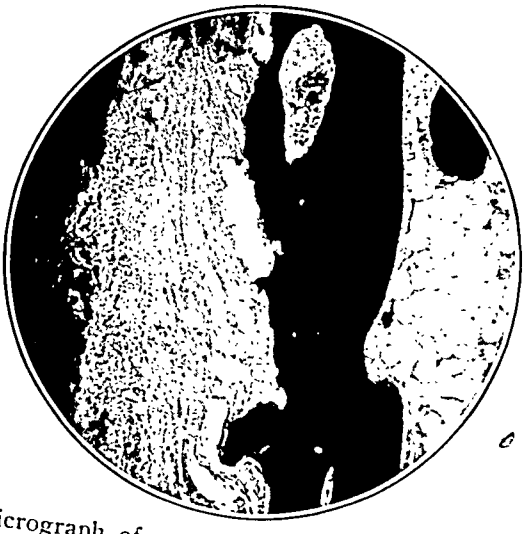

Fig. 12.—Photomicrograph of section from specimen shown in Figure 4.

ANIMAL EXPERIMENTATION

At first in our experimental work, which has been carried on largely by Dr. R. I. Harris, we found great difficulty in producing osteomyelitis in the dog, even with staphylococci or streptococci of known virulence in man. Therefore, our earlier demonstrations were

chemically produced with croton oil, sealed with agar and planted in the bone near the epiphysis, as employed by Bancroft and Clarke. These experiments succeeded in demonstrating the process of destruction and sequestration, but were not satisfactory as proof of the spread of infection. It was found that by tying off the appendix and its mesentery in the dog a general peritonitis is produced. The organisms from this infection if injected into a nutrient artery or into the traumatized metaphysis will produce an acute osteomyelitis in the growing dog. In every case the dog has died within forty-eight hours, but the osteomyelitis is characteristic. The periosteum is rapidly stripped, with findings similar to the sections shown.

No dogs lived long enough to allow the production of later changes and sequestration; but it is quite apparent that the early changes are

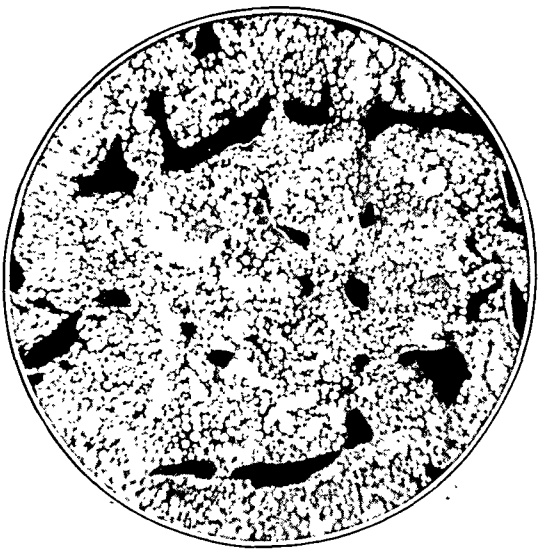

Fig. 13.—Photomicrograph of section of cancellous bone near medullary canal (Fig. 4).

in the nature of an inflammatory condition along the epiphyseal line, with rapid extension to the cortex, and frank pus under the periosteum.

From the foregoing presentation of early pathologic changes shown from human necropsy specimens, from the roentgen-ray findings of cases of longer standing, and some of late cases, and from the correspondence of the findings in the animal experiments, it seems reasonable to conclude, that, for the most part, infection starts in the metaphysis or diaphyseal side of the epiphyseal line; that it extends most easily along the epiphyseal line to the cortex and the periosteum; that it readily and early strips the periosteum, with increasing tension as more pus is formed; that with increased tension the infection probably spreads backward through the haversian canals at various levels, and invades the medulla from the cortex, giving this spotty character to the shaft infection.

One should feel that the firm attachment of the periosteum is a safeguard to direct extension to the joint by this route. It is also most unlikely that infection will travel through the epiphysis and articular cartilage direct to the joint.

Fig. 14.—Roentgenogram taken on the sixth day after onset, showing no bony change.

The neighboring joint is, no doubt, involved in a small number of cases; but I am beginning to believe that it is more often infected secondary to operation, than as a result of primary extension.

That a serous synovitis occurs from adjacent infection, and consequent hyperemia of the synovial membrane, is unquestioned; but these will usually subside without aspiration or incision.

The changes occurring in the later stages are so well known that they need no elaboration. The formation of a bony wall or involucrum on the under surface of the periosteum, the sinuses passing through

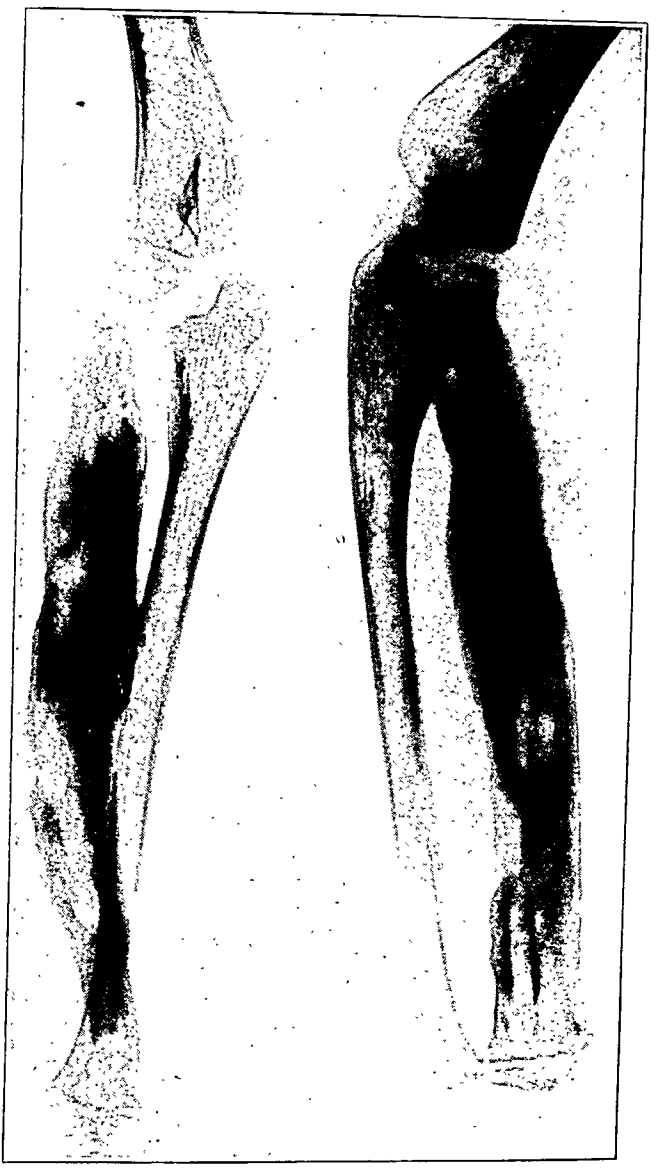

Fig. 15.—Roentgenogram of same case as that shown in Figure 14, six months later.

this bony covering, the gradual separation of the necrotic area or sequestrum by a layer of granulation tissue forming between the living and dead areas, are conditions which are well described in most textbooks.

SIGNS AND SYMPTOMS

Following a fall or moderate injury, there is complaint of pain, severe, of sudden onset, and located in the neighborhood of a joint. This may be preceded a few days by a sore throat or a discharging ear, or some other primary source of infection may be found. Accom-

Fig. 16.—Usual appearance of untreated bone.

panying the pain, there will be tenderness over a limited area, and most extreme at that point. There will be signs of toxemia, headache, dry tongue, sometimes vomiting, with a pulse rate as high as 120 or 130, a temperature of 103 or 104 F., and a marked leukocytosis as high as 25,000 or 30,000. If left alone, later symptoms of redness, swelling,

Fig. 17. — Roentgenogram taken at a late stage, showing "spotty" infection.

and marked edema develop. With these there is a corresponding increase in the toxic symptoms.

DIAGNOSIS

The diagnosis must be made on the signs present. Severe pain in the neighborhood of a joint, with a spot of extreme tenderness, in a growing child is extremely significant. If it is accompanied by high fever and rapid pulse, with high blood count, the diagnosis is moderately certain.

It is so essential that an early diagnosis be made, that one should be constantly on guard. The roentgen ray is of no assistance in early

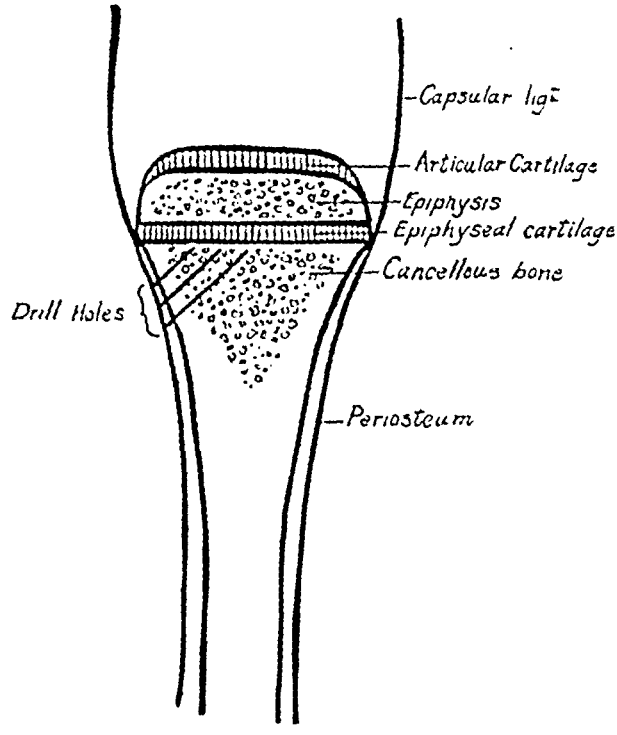

Fig. 18.—Series of drill holes from cortex to epiphyseal line.

diagnosis. Valuable time is consumed, which means more and more bone destruction. Salicylates should not be administered if time is lost thereby.

In rheumatism the onset is not usually so severe, nor the pain so excruciating. There is no sharp point of localized tenderness, and the pain is articular, not in the neighborhood of the joint. There is almost immediate swelling of the joint in rheumatism.

An infectious arthritis is sometimes confusing; but the joint manifestations are usually sufficient to differentiate this condition. There is muscle spasm, limited movement of the joint, and early swelling of

the synovial pouch. In osteomyelitis the joint is usually free of swelling, and movements are free if gently attempted. Do not wait for signs of swelling, redness and edema, as these are rather later signs. Of course, if these are present when the patient is first seen, they render the diagnosis still more certain.

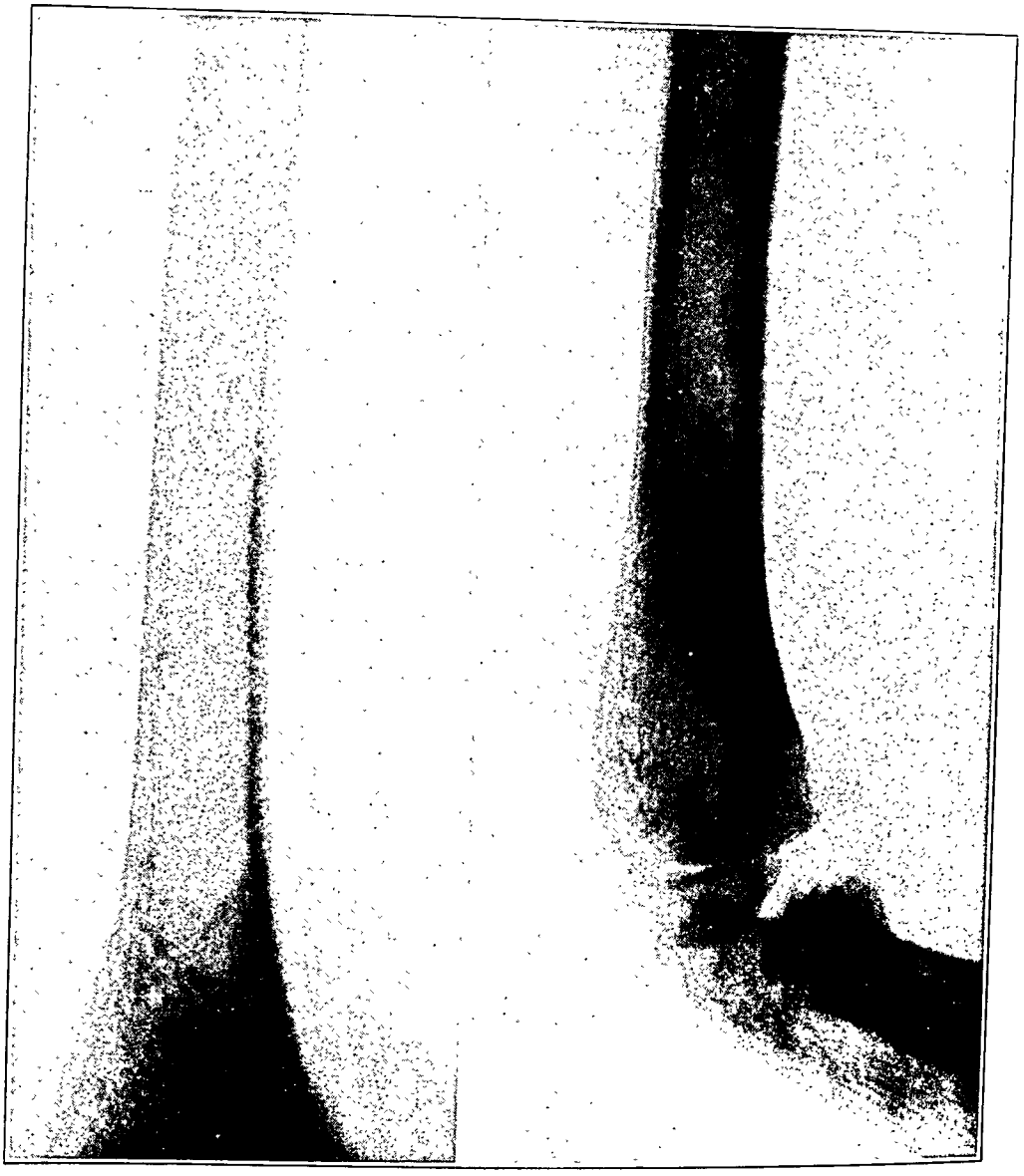

Fig. 19.—Arm of patient on admission.

TREATMENT

The diagnosis being made early, treatment should consist of incision over the area of greatest tenderness, through the skin, subcutaneous tissue and periosteum to the bone. Care should be exercised to keep the incision clearly on the diaphyseal side of the epiphysis to preserve

the periosteal attachment to the epiphyseal line. This safeguards to a large extent the possibility of extension to the joint.

If frank pus is encountered, our experience shows that this incision is sufficient, if a drain is kept in for a time. If no gross pus is encountered, the periosteum is stripped for a short distance on either side of the incision, to be sure that the incision is not in the wrong place.

If still no frank pus is seen, a series of possibly three drill holes is made from the cortex, obliquely downward toward the epiphyseal line. These are about one fourth of an inch (6.4 mm.) apart up the cortex, and extend at least into the center of the shaft at the epiphyseal line, as shown in the diagram (Fig. 18).

Cultures from the débris removed from these drill holes always show infective organisms, even though free pus is not obtained. These establish clear lines of least resistance, and within twenty-four hours pus is draining freely.

In no case have we opened the medullary canal, and in all cases the infected bone seems limited to the area present at the time of establishment of drainage.

The treatment, usually advocated, of trephining an opening into the medullary canal, 2½ inches (6.4 cm.) or more up the shaft, seems, in the light of our experience, to be pernicious.

If the periosteum is opened and holes drilled into the shaft at the metaphysis (Fig. 18), one can hope to relieve the symptoms and prevent necrosis sufficient to produce sequestration. Even if free pus has stripped the periosteum, if it is confined to a small area, regeneration of the necrotic area may take place without sequestration. The subjoined case illustrates this type.

A. B., a boy, aged 12 years (Fig. 19), had sore throat, headache and cervical adenitis, one week before onset of symptoms in the arm. Two days before admission he had pain, which increased in severity just above the left elbow. Slight swelling was noted the day before admission.

On admission he had pain just above the left elbow, some swelling and redness over the inner aspect of the humerus, with pitting on pressure and exquisite tenderness. Movement at the elbow was nearly complete in range, and only painful when the arm was extended to its extreme length. The temperature was 103 F.; the pulse 150; respirations 30; white blood cells 24,000; polymorphonuclear leukocytes 98 per cent.

A free incision over the inner side of the lower end of the humerus, above the epiphyseal line, opened a cavity containing ½ ounce (15 c.c.) of pus. Culture from this pus showed a hemolytic streptococcus. A blood culture taken at the same time was sterile.

The boy had a rapid convalescence, and was discharged from the hospital at the end of three weeks, with the wound healed. It has remained healed ever since, now one year.

Figure 20, a roentgenogram taken four months later, shows some periosteal thickening and no cancellous tissue change.

In the series of patients under treatment there are six that have been similarly treated; and the wounds have healed in three or four weeks without a sequestrum being formed. There are also three patients with positive blood cultures on repeated examination, who recovered with greater or less sequestration of necrotic bone.

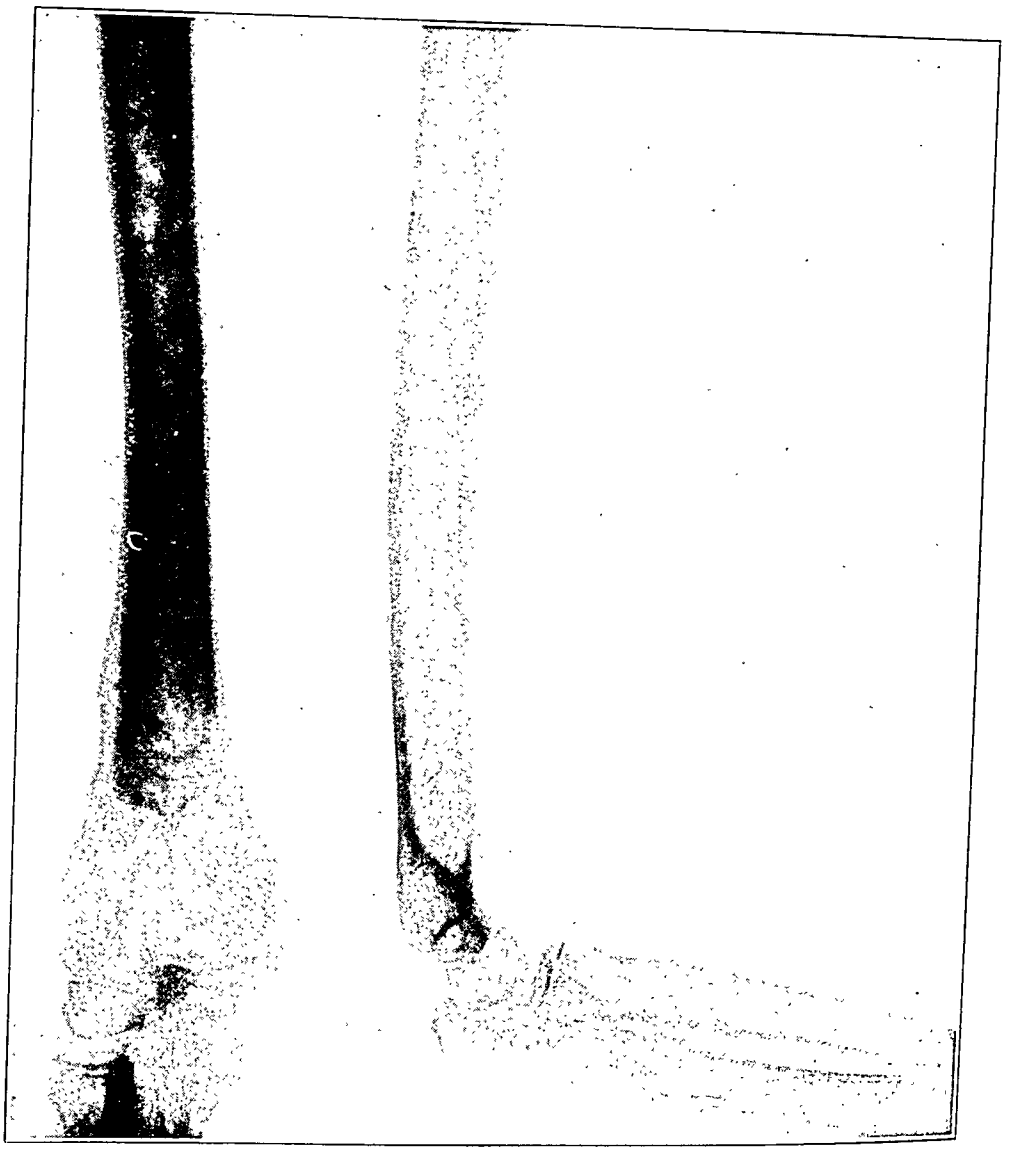

Fig. 20.—Arm of patient, four months later.

In the later stages the plan of treatment adopted is this: After efficient drainage has been established, operation is delayed until the sequestrum is separated. Then a channel sufficiently large to remove the sequestrum is chiseled through the involucrum; the cavity is gently

curetted until it is free of dirty granulations; the cavity is sponged with iodin, and packed tightly for forty-eight hours with iodoform gauze after which all packing and drains are removed. If the cavity left is too large to fill easily by granulation, the edges are made saucer-shaped, or flattened, to permit the soft tissues and periosteum to fall in and obliterate it.

It is rare to find in hematogenous osteomyelitis the large central cavities that one finds in osteomyelitis near the extremity of a long bone following a gunshot wound, which can best be obliterated by a transplanted muscle flap.

The practice of attempting to chisel away necrotic bone before it has delimited itself is to be condemned, as it is impossible to determine where the necrotic bone ends and where the living bone begins. Living bone is thus either taken away or necrotic bone left.

In the operation of making a depressed or saucer-shaped cavity the periosteum should not be widely separated from the living bone, as this is likely to interfere with the circulation of the bone tissue immediately underneath, which may also have its endosteal circulation cut off. This would, of course, make a new necrotic area and subsequent sequestrum.

The blind curetting of a bone cavity where there may or may not be a sequestrum, is not a procedure which is likely to produce any beneficial results. In our experience the sequestrotomy should be performed in a bloodless field, using a tourniquet wherever it can be safely used.

Ill-considered and incomplete operations in the latter stage are largely responsible for the fact that in so many of these bone cases discharging sinuses continue for years, and the patients are subjected to operations without number.

OPEN PNEUMOTHORAX IN ITS RELATION TO THE EXTIRPATION OF TUMORS OF THE BONY CHEST WALL*

CARL A. HEDBLOM, M.D.
ROCHESTER, MINN.

Perhaps no surgical condition of the chest is more germane to the discussion of pneumothorax than that of tumors of the bony chest wall. Such tumors are usually either malignant or potentially malignant, and often involve an extensive portion of the wall of the thorax. Complete extirpation with a wide margin necessitates an extensive resection, and furthermore, this operation, usually performed in one stage, results in a sudden collapse of the lung. In contrast to conditions following surgery for infectious diseases, there are no inflammatory adhesions of the pleura, and no thickening and fixation of the mediastinum. The posture of the patient, which is usually lateral or dorsal, is favorable to the collapse of the lung and to the transmission of atmospheric pressure to the other side. The operation is concerned with the chest wall, and not with the lung; retraction of a lobe of the lung outside the wound is neither necessary nor convenient during resection. There is consequently no steadying of the mediastinum. A study of operative pneumothorax incident to the resection of tumors under such conditions should be of importance, both with respect to the theoretical and to the practical considerations of the subject.

Resection of the entire chest wall with wide opening of the pleural cavity was practiced before the nature of pneumothorax or the dangers incident to it were adequately conceived. The first case of thoracotomy for tumor was recorded by Osias Aimar,[1] who, in 1778, removed an osteosarcoma involving the fifth, sixth, and seventh ribs; but he did not open the pleura. The first case of thoracotomy for tumor in which pneumothorax resulted was reported, in 1818, by Richerand,[2] who, with the assistance of Dupuytren, widely opened the pleural cavity by resecting a portion of the pleura with a carcinomatous growth involving the ribs. Richerand describes the onset of the pneumothorax, as follows:

---

* From the Section on Surgery, Mayo Clinic.

* Read before the fourth annual meeting of the American Association for Thoracic Surgery, Boston, June, 1921.

1. Aimar, Osias: Quoted by Parham, F. W.: Thoracic Resection for Tumors Growing from the Bony Wall of the Chest, New Orleans, 1899.

2. Richerand, quoted by Parham: Footnote 1, second reference.

"At this moment the exterior air made an eruption into the chest, rushing in with violence and compressing the left lung which, with the heart, was borne toward the orifice. I sought, by placing thereto the left hand, to moderate the entrance of air and to prevent suffocation, which appeared imminent, while with the right hand I applied to the wound a large bolster spread with cerate. The entrance of air was suddenly stopped by this greasy cloth." The patient recovered from the operation, but died of recurrence one month later.

It was not until 1855 that Sedillot [3] performed the second recorded intrapleural operation. In an exhaustive review of the literature from then until 1898, Parham [4] was able to collect twenty-six cases in which resections were performed without opening the pleural cavity, and fifty-four, including two of his own, in which it was opened. Of twenty-three additional cases of resection of the sternum, pneumothorax resulted in six. In one instance, both pleural cavities were opened, with resulting bilateral pneumothorax. The patient recovered. In considering the effect of pneumothorax, Parham classified forty-one selected cases into three groups: (1) those in which little or no disturbance followed opening of the pleural cavity, sixteen cases; (2) those in which there was moderate disturbance, ten cases, and (3) those in which there was marked disturbance, ten cases. He concludes that the size of the opening and the duration of the open pneumothorax are the most important factors in producing symptoms. He found that the respiration was interfered with to some extent in all, and that seven of the patients suffered severe collapse. In cases of extensive resection involving adjacent structures, such as the diaphragm and pericardium, he accredited the serious symptoms to the prolongation of the operation rather than to the severity of the procedure.

In 1898, Parham used the differential pressure method of Fell-O'Dwyer in operating on a patient with chrondrosarcoma. He employed positive pressure to inflate the lung, which was then sutured to the parietal pleura, after which he dispensed with the apparatus. A thorough search of the literature has brought to light reports of sixty-seven cases of tumor of the chest wall in which operation was performed since Parham's first patient was operated on under differential pressure. This includes twenty-eight cases reported by Lund,[5] in 1913, and one case in which he operated under intratracheal insuffla-

3. Sedillot, quoted by Parham: Footnote 1, second reference.

4. Parham, F. W.: Thoracic Resection for Tumors Growing from the Bony Wall of the Chest, New Orleans, 1899.

5. Lund, F. B.: Sarcoma of the Chest Wall. Ann. Surg. **58**:206-217. 1913

tion. The case reports of Gross,[6] Stukkei,[7] Hervy,[8] Degorce,[9] Palleroni,[10] and Zschucke [11] unfortunately were not available for this study.

The records of the Mayo Clinic since 1910 contain the histories of forty-nine patients with tumors of the bony chest wall. A complete report of these cases has been published recently.[12] Fifteen have been included in this study as having a bearing on the theme. With the fifty-eight cases from the literature, the total is eighty-two cases.

OPERATIONS UNDER DIFFERENTIAL PRESSURE

Eighteen (about 20 per cent.) of the eighty-two patients were operated on under differential pressure anesthesia. The type of differential pressure apparatus used was the Fell-O'Dwyer apparatus in one operation; Brauer's positive pressure chamber in four operations; Sauerbruch's negative pressure chamber in six, and Murphy's chamber in one operation. Intratracheal insufflation was used in four operations and intrapharyngeal insufflation in two.

Chloroform anesthesia was used in five operations, ether in eight, nitrous oxid and oxygen in one, and the anesthetic was not mentioned in four.

The resection was performed for chondroma in three, for sarcoma in nine, for endothelioma in one, for recurrent carcinoma following amputation of the breast in four, and for chronic inflammation in one.

The opening in the chest wall was stated or was suggested by the context to be small in one case (4 cm. in diameter); moderately large ("Handteller Grösse") in eight, and large (10 cm. by 18 cm.) in six. In one case, the size of the opening could not be determined, and in two, an opening was not made in the pleura.

The symptoms referable to the opening of the pleural cavity were weak, rapid pulse, and disturbed respiration in the two cases of Por-

6. Gross, G.: Sarcomes étendus de la région sterno-claviculaire; exstirpation; autoplastie par glissement et décollement, Rev. méd. de l'est. **45**:497-500, 1913.

7. Stukkei, L. G.: Case of Chondrosarcoma of the Manubrium Sterni, Russk. Vrach. **14**:977, 1915.

8. Hervy, J. M. J.: La chondrectomie (operation de Freund) est-elle une intervention bénigne? Bordeaux, Cadoret, 1915.

9. Degorce, A.: Sarcome de la paroi antéro-latérale du thorax à prolongement intrathoracique, Bull. Soc. méd.-chir. de l'Indo-Chine **5**:160, 1914.

10. Palleroni, G.: Sopra un caso di encondrosarcoma della parete toracica, Clin. mod. **9**:393-396, 1903.

11. Zschucke, J.: Ueber einen Fall von Myxochondrosarkom der Rippe bei einem zwölfjährigen Mädchen, München, Müller and Steinicke, 1912.

12. Hedblom, C. A.: Tumors of the Bony Chest Wall, Arch. Surg. **3**:56-85 (July) 1921.

ter[13] and Payr.[14] In both of these cases the diaphragm was resected, and the symptoms promptly abated. Pleural effusion occurred in one patient as a postoperative complication. Porter's patient died on the fourteenth day, and purulent bronchitis and pneumonia were found at necropsy.

OPERATIONS WITHOUT DIFFERENTIAL PRESSURE

Sixty-four patients were operated on without differential pressure. The ribs and adjacent structures included in the resection are listed in Table 1.

Chloroform was used for fifteen patients, gas and ether for one patient, and ether for fourteen patients; the anesthetic for the others was not mentioned. Pneumothorax was produced in forty-three of the patients, in two bilaterally. In the remaining twenty-one patients, the pleura was not opened, or there were extensive adhesions.

TABLE 1.—EXTENT OF RESECTION

	Cases	Structures Resected with Ribs							
		Clavicle and Sternum	Diaphragm	Cartilages	Diaphragm and Peritoneum	Diaphragm Pericardium and Lung	Sternum	Lung	Pericardium
One rib	11	2	1	..	..	..	..	..	1
Two ribs	20	4	2	..	1	..	..	..	..
Three ribs	18	..	3	..	1	..	1	..	..
Four ribs	15	..	3	..	..	1	..	..	..
Five ribs	1	..	..	..	..	..	..	1	..
Sternum	11	5	..	2	..	..	..	..	..
Vertebra	1	..	..	..	..	..	..	..	..
Structure not mentioned	7	..	..	..	..	..	..	..	..
Total	84	11	9	2	2	1	1	1	1

In the forty-three cases in which the pleural cavity was opened without differential pressure with resulting pneumothorax, the opening was stated or suggested to be small in nine, moderately large in three (about 7 cm. in diameter), and large in twenty-three. In the other cases the size of the opening was not mentioned. In several, the opening was so large that "both hands could be introduced at once into the pleural cavity."

It may be noted in Table 2 that of the forty-three patients in whom pneumothorax was produced there were symptoms referable to it in nine, and there were no symptoms in twenty-six. Symptoms were not mentioned in eight. Postoperative symptoms were designated as shock

13. Porter, C. A.: Two Cases of Extensive Thoracic Resections: The First for Enchondroma of the Ribs, the Second for a Closed Tuberculous Empyema of Many Years' Duration, Boston M. & S. J. **159**:861-864, 1908.

14. Payr: Fibrosarkom der Brustwand, Deutsch. med. Wchnschr. **37**:1147, 1911.

in nine; there were no symptoms in eighteen, and no mention of symptoms was made in sixteen. Of the patients without pneumothorax, there was postoperative shock in three, no symptoms in ten, and no mention of symptoms in eight. Table 2 shows, therefore, that while the majority of the patients with pneumothorax do not have marked symptoms referable to it, and only a very small percentage have symptoms at the time of operation, the incidence of postoperative shock is considerably greater if pneumothorax is produced. That this is largely due to the relatively greater extent of the operation on the latter is

TABLE 2.—SYMPTOMS AT THE TIME OF OPERATION AND AFTER OPERATION

	Patients Operated on With Differential Pressure Anesthesia	Patients Operated on Without Differential Pressure Anesthesia	
	Without Pneumothorax	With Pneumothorax	Without Pneumothorax
Shock at the time of operation	3	5	..
Shock after operation	1	9	3
Cyanosis at the time of operation	..	3	..
Cardiac collapse at the time of operation	..	1	..
No symptoms at the time of operation	6	26	10
No symptoms after operation	7	18	10
Symptoms at the time of operation not mentioned	9	8	11
Symptoms after operation not mentioned	10	16	8
Total number patients having symptoms at the time of operation	18	43	21
Total number patients having symptoms after operation	18	43	21

TABLE 3.—RELATION OF SYMPTOMS TO SIZE OF PLEURAL OPENING

Size of Opening	No Symptoms	Slight Symptoms	Marked Symptoms	Symptoms not Mentioned	Total
Small	4	1	..	4	9
Moderate	1	2	..	..	3
Large	14	2	4	3	23
Total	19	5	4	7	35

apparent from the fact that of the nine patients with marked shock after operation six had resections of adjacent structures, namely, the pericardium, the diaphragm, and in one case, the lung.

Table 3 shows that in five cases in which the opening into the pleural cavity was small, no symptoms were present in 80 per cent.; in twenty in which the opening was large, no symptoms occurred in 70 per cent., and marked symptoms were present in only 20 per cent. In the seven cases in which the opening was very large, there were no symptoms in two, slight symptoms in two, and marked symptoms in three. In the three with marked symptoms, the diaphragm was also resected in two. After suture the symptoms subsided.

Sufficient data were not forthcoming on which to base any observation as to the relation between the length of time the pleural cavity

was opened and the relative incidence of symptoms. The depth of anesthesia, the relative conditions of the patients, and the position on the operating table are additional factors which produce uncertainty in attempts to estimate the direct relationship of the pneumothorax and the symptoms. In the absence of symptoms, however, it may be assumed that the pneumothorax was relatively harmless.

In several cases in the Mayo Clinic series, it was well shown that the extent of the operation plays a large part in the production of shock entirely independent of pneumothorax. Several of the patients were practically pulseless after leaving the operating room following

TABLE 4.—POSTOPERATIVE COMPLICATIONS IN RELATION TO PNEUMOTHORAX

	Patients Operated on with Differential Pressure Anesthesia	Patients Operated on Without Differential Pressure Anesthesia	
		With Pneumothorax	Without Pneumothorax
Bronchitis	..	..	1
Pneumonia	1	2	..
Pleurisy with effusion	1	4	..
Empyema	..	5	..
Pulmonary congestion	..	1	..
Anuria	..	..	1
Total	2	12	2

TABLE 5.—POSTOPERATIVE MORTALITY

Cause of Death	Patients Operated on with Differential Pressure Anesthesia	Patients Operated on Without Differential Pressure Anesthesia	
		With Pneumothorax	Without Pneumothorax
Pneumonia	1	1	..
Empyema	..	3*	..
Shock	..	2	..
Anuria	..	..	1
Not given	..	1*	..
Total	1	7	1

* Double pneumothorax in one case.

resection for large tumors without opening of the pleural cavity. Loss of blood was slight, and in no case was the operation very long. Some of these patients were in fairly good condition; others were poor surgical risks. A two-stage or three-stage operation was performed in the latter cases. That a resection of the structures of the thoracic wall in itself produces shock is demonstrated in certain cases of radical amputation of the breast. Considerable shock may result in a patient who was a relatively good operative risk.

From Table 4, it will be observed that 11 per cent. of patients operated on with differential pressure anesthesia developed complications, while 28 per cent. of patients operated on without differential pressure anesthesia and in whom pneumothorax occurred developed

complications. Pleural effusion, both serous and purulent, is of much greater incidence in cases in which pneumothorax is produced.

Table 5 shows that one death occurred on the fourteenth day in a patient operated on under differential pressure anesthesia. This case was reported by Porter who considered the differential pressure anesthesia largely contributory to the unfavorable outcome. One of the patients in the Mayo Clinic died of pulmonary edema the second day following operation for intrathoracic tumor under intratracheal anesthesia. Seven deaths followed operation in the cases in which differential pressure was not used, and in which pneumothorax occurred. In two of these, however, a bilateral pneumothorax had been produced. The mortality rate was about 5.5 per cent. for the first group and 16.3 per cent. for the second. If the cases of shock, which may have been due to other causes, are subtracted, the mortality rate drops to about 11 per cent. Pneumothorax did not occur in the patient with anuria.

COMMENT

The cases presented and the results obtained have significance in relation to the question of the actual immediate risk of open operative pneumothorax, and in relation to postoperative complications. It is obviously not only possible but reasonably safe, so far as the immediate risk to the life of the patient is concerned, to open wide the pleural cavity without differential pressure anesthesia. The experience of many operators has shown that in the majority of patients in whom a large opening of the pleura has been produced, with collapse of the lung, symptoms have been absent or slight. Furthermore, it is always possible to convert a large opening into a small opening, or completely to close the opening by drawing together the skin edges or by covering the opening with a wet towel. Experience has also seemed to show that traction on the lung will promptly relieve alarming symptoms referable to inefficient respiration. Whether the apparently slight effect produced by wide-open pneumothorax in so large a proportion of cases is due to a previous thickening of the mediastinum or to partial adhesions of the lung may be questioned. It is certain that there was massive collapse of the lung in many cases; but even granting the presence of a thickened mediastinum and possibly adhesions, and if it is further admitted that patients without thickened mediastinums and without adhesions would become asphyxiated by a large opening, the objection to operating without differential pressure anesthesia in such cases would be largely overcome by the fact that when alarming symptoms are presented it is a simple matter to convert the open pneumothorax into a closed pneumothorax.

From a technical standpoint, however, an operation under differential pressure anesthesia can unquestionably be performed with greater assurance, less disturbance to the patient, and greater comfort to the surgeon. The impracticability to the average operator of differential pressure anesthesia chambers and the technical difficulties incident to the use of intratracheal insufflation and of other apparatus must be taken into consideration.

A study of these cases in relation to postoperative complications, with their increased mortality, indicates that the increased occurrence of complications furnishes the greatest support for the use of differential pressure anesthesia in resections for tumors of the chest wall. It has been demonstrated clinically and experimentally by Noetzel,[15] Tiegel,[16] Burkhardt,[17] and others, that pneumothorax renders a pleural cavity less resistant to infection. Robinson and Sauerbruch [18] showed that a sterile pleural effusion may develop, apparently due to the lack of contact between the pleurae. The presence of a dead space would also seem to contribute to a postoperative infection. The tendency to localization, as in the peritoneal cavity and, to some extent, in the normal pleural cavity, is absent. The aspiration of the air into the pleural cavity at operation probably also increases the risk of pulmonary infection. This could be largely obviated, however, by the use of gauze protection, as in abdominal surgery.

Empyema was the most potent cause of death in this group of cases; and it is reasonable to believe that the presence of pneumothorax at least contributed to the development of this complication. Therefore, from the standpoint both of maximum safety to the patient and of technical facility, differential pressure anesthesia is preferable in any case in which the thorax is likely to be opened wide and to remain open for some time. The greatest argument in favor of differential pressure anesthesia seems to rest in the fact that the development of postoperative complications, particularly pleural effusion, is apparently lessened by its use. This advantage may be gained, however, possibly equally well by some method of insuring an inflation of the lung at the end of the operation. In view of the advantages of local anesthesia for a preliminary incision, rib resection,

15. Noetzel, W., quoted by Sauerbruch, F.: Die Chirurgie der Brustorgane, Berlin, Springer **1**:396, 1920.

16. Tiegel, M.: Ueber operative Pleurainfection und Thoraxdrainage, Arch. f. klin. Chir. **98**:1022-1058, 1912; Experimentelle und klinische Studien über die postoperativen Komplikationen bei Eingriffen in der Brusthöhle, Beitr. z. klin. Chir. **80**:128-156, 1912.

17. Burkhardt, quoted by Sauerbruch: Footnote 15, second reference.

18. Robinson, S., and Sauerbruch, F.: Untersuchungen über die Lungenexstirpation unter vergleichender Anwendung beider Formen des Druckdifferenzverfahrens. Deutsch. Ztschr. f. Chir. **102**:542-560, 1909.

and so forth, a combination of local anesthesia with some type of differential pressure anesthesia apparatus would make possible the inflation of the lung at the end of the operation before closure. This method was used in one case in the series in the Mayo Clinic and represents a maximum of simplicity and of operative and postoperative safety to the patient. A simple intrapharyngeal insufflation anesthesia by the use of a gas and oxygen apparatus achieves this result.

The foregoing deductions seem justified by the actual experience of many surgeons with different methods and by my experience with ten patients, some of whom were operated on with differential pressure anesthesia, and others without it. Although I have not entered into a discussion of the pathologic physiology of pneumothorax, I wish to point out that the explanation of the phenomena incident to pneumothorax is not simple.

The work of Graham and Bell,[19] showing that in the normal thorax the pleural cavities function as one and that a change in pressure in one cavity is immediately transmitted to the other, seems fundamental to the study of the problem. This principle accounts for the prompt relief that results on converting an open pneumothorax into a closed pneumothorax, and for the relief obtained by traction on the exposed lung. It remains to be shown, however, why such a large proportion of patients do not develop alarming symptoms when the thorax is opened wide.

The symptoms produced in open pneumothorax are referable in the last analysis to disturbed circulation, to deficient aeration of the blood, and, possibly in some cases, to a pleural reflex. The return of the blood to the right side of the heart is dependent on the force of the heart's action through the capillaries, on the valve action in the veins, on the muscle tone as pointed out by Mann,[20] and on the aspirating effect of the respiratory pump. In open pneumothorax, this aspiratory action is lost, and cyanosis and engorgement of peripheral veins develop. Deep anesthesia, resulting in loss of peripheral tone, further hampers venous return. Deficient venous return results in a lowered output from the heart, increased pulse rate, and, eventually, in a fall of blood pressure and shock. A positive pressure anesthesia apparatus provides for aeration of the blood, but does not furnish a substitute for the aspiratory action of normal respiration. Sauerbruch holds that, on the contrary, positive pressure impedes the circulation in the lungs.

---

19. Graham, E. A., and Bell, R. D.: Open Pneumothorax: Its Relation to the Treatment of Empyema, Am. J. M. Sc. **156**:839-871 (Dec.) 1918.

20. Mann, F. C.: Personal communication.

Considerations which bear on the aeration of the blood are the relative amounts of blood passing through a collapsed lung as compared with that passing through a normal lung, the relative importance of the paradoxic respiration in the collapsed lung, the part played by the diaphragm, and the possible influence of disturbed nerve function. Other problems relate to the increased susceptibility of the pleural cavity in pneumothorax, to effusion and infection, and to the possible part of a pleural reflex in the sudden onset of symptoms incident to the abrupt collapse of the lung.

FRACTURE-DISLOCATION OF THE SPINE

TREATED BY FUSION

RUSSELL A. HIBBS, M.D.
NEW YORK

The cases reported herewith are from the service of the New York Orthopedic Dispensary and Hospital.

Of these twenty-two cases of fracture-dislocation of the spine, one was in the cervical region, two were in the dorsal region, two in the dorsolumbar region, and seventeen in the lumbar region. Of the last named, eleven were of the fifth lumbar vertebra.

There was a definite history of severe traumatism in the cervical case, in the two dorsal cases, in the two dorsolumbar cases, and in twelve of the lumbar cases. In five of the last, the injury had occurred in childhood. The symptoms in three cases, except those of short duration occurring immediately after the injury, did not appear until adult life when ossification of the vertebrae was complete. In one instance, Case 18, that of a motorcycle accident, the traumatism was severe; but the only conscious injury at the time was of the leg, although at operation, two years later, it was found that the patient had an ununited fracture of the four laminae of the third and fifth lumbar vertebrae. Another patient, Case 22, had an ununited fracture of both pedicles of the fifth lumbar vertebra, six years after the accident. In another instance, Case 16, the injury occurred at the age of 9; and at operation, fourteen years later, an ununited fracture of the lamina of the fourth lumbar vertebra, left side, was found.

In one case there was a history of slight injury, and in four cases no history of injury. In the four cases with no history of injury the fifth lumbar vertebra was involved, which, considering the fact that of the whole number seventeen were of the lumbar spine, and eleven of these of the fifth lumbar vertebra, emphasizes two points of importance: first, that the lumbar spine is the most susceptible to fracture, and, second, that the fifth lumbar vertebra is the one most frequently fractured. The explanation of these facts is suggested in the following considerations: The lumbar spine is subjected to great strain in all trunk movement on the pelvis, being exercised through wide arcs of motion by very great muscle pull, especially in persons with heavy muscles, engaged in laborious occupations requiring heavy lifting. The angle of the lumbar spine with that of the sacral places all of the lumbar vertebrae at a disadvantage, while the fifth, the end of the mobile spine, articulating with the immobile sacrum, is at the point of greatest

strain. Its position becomes more precarious as, and in the measure that the variation which takes place in this angle (which is about 40 degrees, from 100 to 140) approaches a right angle. The insecurity of the fifth lumbar vertebra is also increased by the variation which is often seen in the shape, size and planes of the articulation of the lateral processes of the fifth and first sacral vertebra, making inconstant and insecure their effect in checking movement and in stabilizing the fifth lumbar vertebra.[1]

It is debatable whether or not any considerable degree of displacement of a lumbar vertebra can take place without a fracture, or the disintegration, of these articulations by disease. (In Case 1, the patient had disintegration of these processes.) Should this happen, it will, in all probability, be of the fifth lumbar vertebra. It is also questionable whether in cases in which the angle of the lumbar vertebra with the sacral spine approaches a right angle (marked lordosis), there may not be sufficient strain at the lumbosacral junction to cause pain, thereby explaining some cases of chronic backache, otherwise obscure.

Four patients with displacement of the fifth lumbar vertebra had imperfect first sacral arches. This defect may impair the ligamentous stability of the joint.

In all instances in which the patient had a forward displacement of the fifth lumbar vertebra, the spinous process was felt to be less prominent. In some of these cases, the lordosis was increased and in others it was not, depending, it would seem, on whether or not there was also a forward displacement of the fifth lumbar vertebra at its articulation with the fourth lumbar vertebra. In Case 6, the displacement at the fourth lumbar vertebra was equal to that at the first sacral vertebra, and consequently the lordosis was not increased. In two instances of backward displacement of the fifth lumbar vertebra, the spinous process was more prominent.

There was direct contact of two or more spinous processes in seven of the lumbar cases and marked limitation of extension of the lumbar spine. In all trunk movement, the impingement of these bones on one another caused distressing pain.

In one instance, Case 14, the constant posture was that of forward bending and inclination to the left side. The fracture occurred at the age of 15, although the symptoms did not appear until adult life, since which time they had been constant and distressing when the patient was in an upright position. She had been subjected to every form of treatment, especially for sacro-iliac relaxation, without benefit, except for relief when lying in bed. It was finally believed that she was

1. Mills, Nathaniel: Congenital Malformations of the Vertebra, Boston M. & S. J. **184**:659-666 (June 23) 1921.

suffering from a psychoneurosis and she was sent to a sanatorium for treatment. She had mobility at the sacro-iliac joints, as demonstrated by mobility at the pubis; but that this mobility caused no symptoms, as is often the case, is demonstrated by the fact that her relief since operation has been complete, although the sacro-iliac mobility is unchanged.

In thirteen cases, there was fracture of the body and of the processes, and in nine cases, all lumbar, fracture of the processes only. In all of the dorsal cases, there was fracture of the body; only one patient (Case 12) having displacement as well. The explanation of this fact is found in the greater stability of these articulations, their limited motion and the protection of the thorax. In one instance, Case 17, the patient had six lumbar vertebrae. The sixth was fractured and displaced forward, with contact between the spines of the fifth and sixth lumbar vertebrae.

In six instances (Cases 6, 9, 12, 14, 16 and 22), the fractures occurred in childhood, although the symptoms did not appear in four of them until adult life, when ossification was complete. Of the two remaining cases, one patient, 18 years of age (Case 22), was found to have an ununited fracture of the pedicles of the fifth lumbar vertebra at operation six years after injury, the symptoms having been continuous. The other (Case 12) was a child of 5 at the time of operation, two and one-half months after injury.

There was no evidence of nerve root or cord injury in twenty-one cases. One patient (Case 19) had impairment of the sphincters, exaggerated patellar reflexes, and weakness of the legs for six weeks after the injury. In the cervical case, the patient had a great deal of pain in the neck and shoulders, with a protective posture of the head. In the dorsal and dorsolumbar cases, there were sensations of weakness, with more or less deformity, and one patient (Case 9) had a marked scoliosis. In the lumbar cases, the patients complained of pain and weakness in the lower back and of pain in one or both legs, sciatic in character. Many of these patients had the protective posture and limitation of motion of Pott's disease. In all of the cases, the patients were seriously handicapped by the severity of their symptoms, while some of them were unable to pursue any active occupation. In only three cases of the whole series (Cases 19, 20 and 21), all of which were recent fractures, had a diagnosis of fracture been made. In the other nineteen cases, the fractures had occurred from one to twenty-five years previously.

The shape of a vertebra and its relation to other structures make it difficult, or perhaps impossible, to secure a roentgenogram that will give exact and complete knowledge of the fracture. This is certainly true in cases studied long after the fracture has occurred. In all of

these cases, the patients were subjected to the most careful roentgen-ray study by anteroposterior, lateral, and stereoscopic roentgenograms. The lateral roentgenograms were especially important in differentiating fractures from disease, by showing clearly the condition of the bodies and the intervertebral disks. They were also important in showing accurately the degree of displacement. In every case, the operation revealed injury or displacement of bone not shown by the roentgen ray. For instance, in one case, the patient (Case 18) had ununited fractures of the laminae of the third and fifth lumbar vertebrae on both sides; another (Case 22) had ununited fractures of the pedicles of the fifth lumbar vertebra, six years after the injury, and another (Case 16), an ununited fracture of the lamina of the fourth lumbar vertebra on the left side, fourteen years after injury.

The roentgen ray revealed in every case a degree of abnormality of bone that, associated with the symptoms, justified operation. The operative findings made it evident that the fracture-dislocation had produced a profound and permanent change in the articulations of the vertebrae involved; that the symptoms had been caused by the mobility of these altered joints and ununited fractures and by the influence that their need of protection had in stimulating a protective limit in the joints adjacent, and that the severity and duration of the symptoms depended on the mobility of the region involved and the amount and character of the displacement and injury to the bone.

Since it is impossible to restore these joints to normal, the elimination of motion which takes place in them would seem to offer the only chance of securing complete and permanent relief. To this end, the fusion of the articulating bones is necessary. This has been successfully accomplished in all of these cases by the operative method which has been used at the New York Orthopedic Hospital in several hundred cases of tuberculosis of the spine and of scoliosis. As former descriptions of the technic have been misunderstood, it is perhaps well to describe the operative procedure again.

TECHNIC

An incision is made through the skin and subcutaneous tissue, from above downward, exposing the tips of the spinous processes of the vertebrae to be fused. The periosteum over the tips of these processes is split longitudinally, and, with a periosteal elevator, pushed to either side, leaving them bare. The periosteum and interspinous ligament in turn are still farther split and pushed forward a short distance from each spinous process, as two lateral halves, gauze packs being inserted to prevent oozing. The dissection is carried farther and farther forward upon each vertebra, in turn, until the spinous processes, the posterior surfaces of the laminae and the base of the transverse

processes, are bared, thereby exposing the ligamentum subflava attached to the margins of the laminae and the articulations of the lateral processes.

The ligament is removed from the laminae with a curet, and the articulation of the lateral processes is destroyed in order to establish bone contact at this point. With a bone gouge, a substantial piece of bone is elevated from the adjacent edges of each lamina, of half its thickness and of half its width. The free end of the piece from above is turned down to make contact with the lamina below, and the free end of the piece from the lamina below is turned up to make contact with the lamina above.

Each spinous process is then partially divided with bone forceps and broken down, forcing the tip to come into contact with the bare bone of the vertebra below. The spinous process of the last vertebra below should be turned up to bring about contact with the next above. As the spinous processes of the lumbar region are wide, it is sometimes practicable to split them, turning one half up and the other half down. Thus is established contact of abundant cancellous bone at the articulations of the lateral processes, laminae and spinous processes. The periosteum and ligament, which together have been pushed to either side and lie practically as an unbroken sheet, are brought together in the middle with interrupted sutures of ten-day chromic catgut. The subcutaneous tissue is then closed with a continuous suture of plain catgut; the skin wound is closed with sutures of ten-day chromic catgut, and sterile dressings and an immobilizing brace or plaster are applied.

The dissection may be made in a practically dry field, without injury to the muscles, if it is subperiosteal and if a free use is made of gauze packs. Only in an operative wound that is free from hemorrhage can the operator see to exercise the care necessary for thorough work. Not only the baring of the bones may be complete, but the periosteum may be separated from them in a practically unbroken sheet and without disturbance of its relation to the surrounding tissues and blood supply. The greatest care should be exercised in this dissection, since it is of primary importance, as the area of fusion is measured by its extent and thoroughness. After the bones are bared, they may be treated as indicated above, or in any manner which establishes their contact and stimulates bone formation. With the closure of the periosteum, what is practically a tube of periosteum is formed, with its abundant blood supply undisturbed, filled with healthy, living cancellous bone, lying in continuous contact. This situation is entirely consistent with the physiologic laws of bone growth; it furnishes a great stimulus to their operation, and insures a fusion of the lateral processes, the laminae and the spinous processes.

In each of the cases reported herewith, the fusion was made to include at least one healthy vertebra above and one below the injured vertebra. The patient was kept in bed for eight weeks and required to wear a support for from two to four months longer. The support in each instance was of the Taylor spine brace model, except in the lumbar cases, when it was shortened above to extend only to the tip of the scapula, and lengthened below to grasp the pelvis.

REPORT OF CASES

CASE 1.—Dr. S., aged 43, short, heavy set and of good muscular development, for many years had had an arthritis, involving the knees, hips, shoulders and lower spine. During the previous year, the pain in the back had become very severe; and for three months, a slipping sensation had been present at the lumbosacral joint. This was so painful that he was obliged to discontinue his work.

Examination.—The knees and hips were slightly flexed, and there was a marked exaggerated lordosis. The flexibility was greatly impaired; and on certain movements, a slipping sensation could be palpated at the lumbosacral junction. Roentgen-ray examination revealed an anterior displacement of the fifth lumbar vertebra on the sacrum.

Operation.—March 30, 1916, fusion extending from the third lumbar vertebra to the sacrum was accomplished. The articular processes of the fifth lumbar vertebra and the sacrum were found to have been disintegrated by the arthritis, permitting the forward displacement of the fifth lumbar vertebra on the sacrum.

Present Condition.—The posture is much improved, and the patient is entirely relieved of the symptoms for which the operation was performed. He has resumed the active practice of his profession. This case, although, strictly speaking, not a case of fracture-dislocation, was such a case in every essential.

CASE 2.—S. O., a laborer, aged 48, large, powerful and heavy set, fell from a ladder in October, 1918, since which time he had had severe pain in the back, with peculiar sensations in both limbs, especially the right.

Examination.—This demonstrated a protective posture, similar to that of Pott's disease, with a rounded kyphos in the dorsolumbar region, the apex of which was at the eleventh dorsal vertebra. There was some pain on attempted bending, marked limitation of motion, and slightly increased patellar reflexes, with sensations of paresthesia. The roentgen ray disclosed compression fracture of the eleventh and twelfth dorsal vertebra, with an apparently normal intervertebral cartilage.

Operation.—March 12, 1919, fusion extending from the tenth dorsal to the second lumbar vertebra was accomplished. The spinous process of the tenth dorsal vertebra was found to be broken off.

Present Condition.—The patient is completely relieved and is working daily.

CASE 3.—M. C., a ship steward, aged 44, fairly tall, slender and wiry, fell 40 feet (12 meters) from a gangplank in January, 1917, fracturing his legs and injuring his spine. Since that time he had had increasing pain and stiffness in the back and what was diagnosed as double sciatica.

Examination.—The posture was protective, with fair flexion, but there was marked muscular spasm on lateral motion and extension. There was slight

inclination to the right and tenderness over the lower lumbar spine and sacrum. The patellar reflexes were normal. The roentgen ray showed compression fracture of the fourth and fifth lumbar vertebrae, most marked on the right. List and rotation were especially sharp at the sacrum.

Fig. 1 (Case 3).—Compression fracture of the fifth lumbar vertebra, with lateral displacement.

Operation.—Jan. 19, 1918, fusion, from the second lumbar vertebra to the sacrum, was accomplished. The fourth and fifth lumbar vertebrae were found to be distinctly compressed, owing to crushing of the bodies and fracture of the articular processes.

Present Condition.—The patient is completely relieved and has resumed normal activities.

CASE 4.—T. K., a foundry worker, aged 33, heavy, strong and muscular, a year before examination began having pain in the back and legs. This grew

Fig. 2 (Case 6).—Anterior displacement of the fifth lumbar vertebra without suggestion of lesion in anteroposterior roentgenogram.

steadily worse, and a few months before he was seen here, his back had become crooked. There was no history of severe injury.

Examination.—The posture was very protective, with a severe inclination of the trunk to the left. The spine was held rigidly in this position. The

patellar reflexes were greatly exaggerated. The roentgen ray revealed complete sacral ossification, and what appeared to be a collapse of the lower left side of the body of the fifth lumbar vertebra and one-fourth inch (6.4 mm.) anterior displacement of this body on that of the fourth lumbar vertebra. Its relation to the sacrum could not be seen.

Fig. 3 (Case 6).—Anterior displacement of fifth lumbar vertebra.

Operation.—July 10, 1918, fusion from the third lumbar to the second sacral vertebra was accomplished. There was incomplete ossification of the first sacral arch, with motion between this vertebra and the second. The fifth lumbar vertebra had slipped forward between the fourth lumbar vertebra and the sacrum, fracture of the articular processes allowing its displacement.

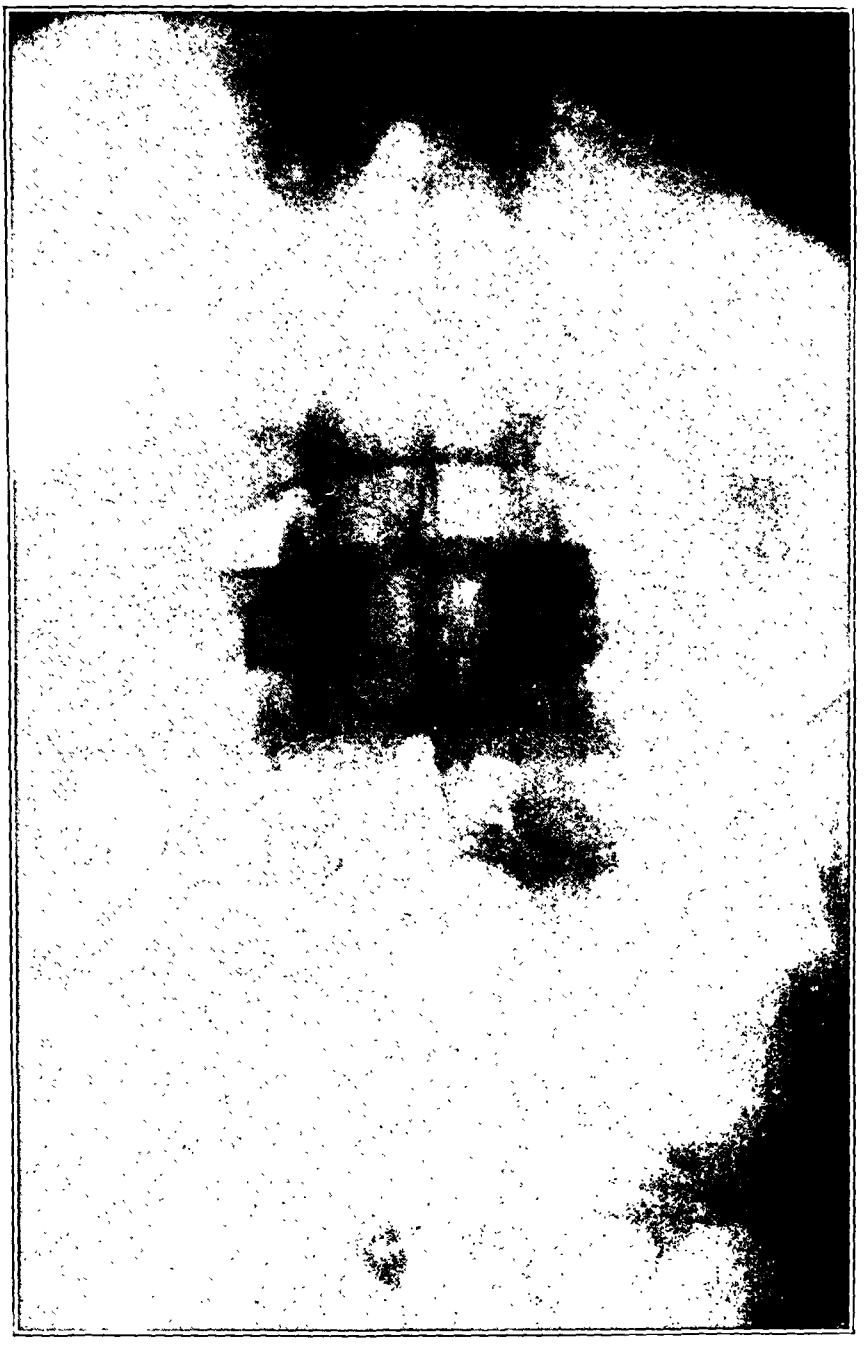

Fig. 4 (Case 8).—Anterior displacement of the fifth lumbar vertebra, with incomplete ossification of the sacral and fifth lumbar arches.

Present Condition.—There is complete relief from all symptoms. The patient is practically erect and is working.

CASE 5.—J. S., a prize-fighter, aged 22, thick set and of good musculature, when lifting a heavy timber in March, 1920, experienced a sudden sharp pain in the lower part of the back and in the right leg. This had persisted and was gradually becoming more severe.



Fig. 5 (Case 8).—Anterior displacement of the fifth lumbar vertebra. Impaired ligamentous strength suggested as a factor in this case.

Examination.—The posture was protective, the patient especially favoring the right leg. The trunk was inclined to the left, with free movement in this direction. All other motions were limited by pain and spasm, flexion, especially, often causing sharp pain which extended as far down as the right heel. The roentgen ray revealed incomplete ossification of the first sacral arch, sharp

left angulation between this segment and the fifth lumbar vertebra, and, to a lesser extent, between the fourth and fifth lumbar vertebrae; a slight collapse of the fifth lumbar vertebra, with an anterior and right displacement.

Operation.—Sept. 17, 1920, fusion, from the third lumbar vertebra to the sacrum, inclusive, was accomplished. The fourth lumbar spinous process was displaced downward and to the right of the fifth lumbar vertebra, which was forward and compressed between the fourth lumbar vertebra and the sacrum. Before operation the patient was placed in straight traction, following which there was much relief. One week after operation, he was again placed in traction, under which something "snapped" in his back, giving him complete and immediate relief.

Present Condition.—The patient is completely relieved and has taken up the fighting game again.

CASE 6.—W. V. L., a business man, aged 31, large, well built and heavy set. when a child fell from a trapeze, alighting in a sitting position. There had been more or less pain, stiffness and weakness since that time, with a marked increase in symptoms, especially on lifting, shortly before being examined here.

Examination.—The posture was only slightly protective; but the patient did not use the trunk of his body well. The fourth lumbar spinous process was very prominent, with a lost, lordotic curve. He had compensated above and had a slight inclination to the right. There was a moderate limitation of motion in all directions, with some pain on extension of the lumbar spine. The roentgen ray revealed one-fourth inch (6.4 mm.) anterior displacement of the fifth lumbar vertebra on the fourth lumbar vertebra and a one-half inch (12.7 mm.) displacement of the same on the sacrum. The fifth lumbar vertebra was tilted posteriorly down and the fourth tilted up, creating a wide gap between the fourth and fifth spinous processes and contact between the fifth spinous process and the sacrum.

Operation.—May 25, 1920, fusion extending from the third lumbar vertebra to the sacrum, inclusive, was accomplished. The fifth lumbar vertebra was found to be far forward between the fourth lumbar vertebra and the sacrum, while the fourth lumbar vertebra was posterior in its relation even to the sacrum. The laminae of the fourth overrode the fifth so far that they almost came in contact with the sacrum, although this vertebra was tilted up from the posterior position. There was contact with spur formation between the third and fourth spinous processes. The third, as a whole, was tilted slightly to the right, with a corresponding relation of the laminae.

Present Condition.—Complete relief followed operation and the patient has resumed his normal activity, playing tennis, golf, etc.

CASE 7.—D. S., a stock clerk, aged 20, small and fairly thick set, in September, 1919, complained of increasing pain in the lower part of the back and in the thighs. There was no history of accident.

Examination.—This revealed a rigid military posture, with slightly exaggerated lordosis. No motion was demonstrable except forced extension, which was painful. The right patellar reflex was increased. The roentgen ray revealed a slight left lateral deviation of the fourth lumbar vertebra, with anterior displacement of one-half inch (12.7 mm.) on the fifth and one-fourth inch (6.4 mm.) on the third lumbar vertebra. The spinous processes of the third and fourth lumbar vertebrae were in contact and sacral ossification was incomplete.

Fig. 6 (Case 12).—Compression fracture and displacement suggesting Pott's disease.

Operation.—July 9, 1920, fusion from the third lumbar vertebra to the sacrum, inclusive, was accomplished. Incomplete ossification of the first sacral arch was found, with good relations, however, between it and the fifth lumbar vertebra, although the articulations were poorly formed and very little motion could be demonstrated. The fourth lumbar vertebra extended so far forward on the fifth that the articular facets had almost completely slipped by. New ones had formed between the laminae themselves; and, owing to the upward tilt, there was contact between the spinous processes of the third and fourth lumbar vertebrae.

Present Condition.—There is complete relief and the patient is working daily.

CASE 8.—D. R., a policeman, aged 25, large, heavy set, with well developed mucles, when making an arrest in August, 1919, had been injured by the door of a taxicab which was slammed against his back. He had had severe pain and stiffness ever since.

Examination.—The posture was protective, with the lumbar spine held rigidly by muscular spasm. Any attempted motion caused pain. The sacro-iliac joints, especially the right, were tender, and there was slight exaggeration of the patellar reflexes. He wore a belt for a time, which gave partial relief. A roentgenogram showed attempted sacralization of the fifth lumbar vertebra, with incomplete ossification of the sacral and fifth lumbar arches. There was a one-fourth inch (6.4 mm.) anterior displacement of the fifth lumbar vertebra on the sacrum and a marked left-sided compression of the body.

Operation.—April 29, 1920, fusion from the third lumbar vertebra to the sacrum, inclusive, was accomplished. The right side of the first three sacral arches was found to be incomplete. The fifth lumbar vertebra was grossly abnormal, in that the lamina on the left side was not fused; and it, with the spinous process, was entirely loose. The right lamina was very short but firmly attached. The entire vertebra was crowded forward slightly and it was distinctly narrowed on the left.

Present Condition.—It is believed that this man's relief would be complete but for the fact that he is endeavoring to secure large compensation. He has been on duty since four months after operation but continues to wear a brace.

CASE 9.—F. B., a physician, aged 26, short, heavy set and powerful, when 14 years of age, fell from a tree, injuring his spine. He had undergone a variety of treatment, but his back had continued to be weak. He was easily fatigued and experienced a more or less constant ache. The deformity which appeared after the accident had increased.

Examination.—There was a slight general inclination to the left, with prominence of that hip. There was a moderately sharp curve to the right, reaching from the eighth dorsal to the second lumbar vertebra. This was in conjunction with a moderate bulging type of kyphosis in the same region. Right lateral flexion and extension were distinctly limited. The roentgen ray revealed a moderate right curve from the eighth dorsal vertebra down, including a slight tilt of the fifth lumbar vertebra. Rotation was very sharp, especially at the first and second lumbar vertebrae. The greatest convexity was at the first lumbar vertebra, owing to marked lateral wedging of this vertebra and of the twelfth dorsal and second lumbar vertebrae. The third lumbar vertebra was only two thirds of its normal size. Laterally, there was an exaggerated dorsal curve in consequence of sharp wedging of the first and second lumbar vertebrae. The spinous processes of the twelfth dorsal and the first lumbar

Fig. 7 (Case 12).—Compression and displacement.

vertebrae were in contact, whereas those of the first and second lumbar vertebrae were widely separated. Rib formation was normal.

Operation.—June 9, 1920, fusion from the tenth dorsal vertebra to the second lumbar vertebra, inclusive, was accomplished. The first lumbar spinous process was large and very prominent, owing to actual posterior displacement of this vertebra on the second. The laminae on the left of the twelfth and first dorsal vertebrae were shorter than normal and so close that fusion had nearly taken place. The articular process of the twelfth dorsal vertebra was far back, as a result of rotation and displacement. The spinous processes were in the same relation as suggested by the roentgen ray. The tenth and eleventh dorsal vertebrae were sharply related to the curve because of the deviation below.

Present Condition.—There is complete relief from symptoms and a marked improvement in posture and the appearance of the trunk. He is active in tennis and all athletics and is now serving an internship.

CASE 10.—D. A., a stationary engineer, aged 47, tall, wiry and with good musculature, about six months previous to his examination in this dispensary, complained of pain in the lower back and down the limbs, especially the right. In the previous few weeks, it had become so severe that walking was difficult. He gained slight relief by bending far forward and supporting himself with a cane.

Examination.—The posture was extremely protective, with the lumbar spine held rigidly in a flat position. Both thighs were held flexed at 160 degrees, although most of his pain was down the right thigh. The fifth lumbar spinous process was more prominent than normal and the distance between it and the fourth was distinctly increased. The patient had a great deal of difficulty in turning over in bed. The roentgen ray revealed a one-fourth inch (6.4 mm.) posterior displacement of the fifth lumbar vertebra on the fourth. Its relation to the sacrum seemed normal.

Operation.—Aug. 4, 1920, fusion from the second lumbar vertebra to the sacrum, inclusive, was accomplished. The fifth lumbar vertebra was posteriorly placed, giving the appearance of having been squeezed back between the fourth lumbar vertebra and the sacrum. The articular processes of the fifth lumbar vertebra had slipped back and upward a trifle. Fusion was extended to the second lumbar vertebra because of contact between all of the spinous processes.

Present Condition.—The patient is completely relieved; he has a normal back contour and stands perfectly erect. He is doing his usual work.

CASE 11.—T. M., a factory worker, aged 28, tall, slender and wiry, July, 1920, complained of pain in the lower spine and left hip region. This had become progressively worse, with increasing stiffness. There had been no severe injury.

Examination.—The posture was protective, with a slightly diminished lordosis and rigidity in this position. He walked in a stooped position, and the left thigh was held slightly flexed. There was tenderness over the left sacro-iliac joint. The roentgen ray revealed slight anterior displacement of the fourth lumbar vertebra on the fifth, and a similar condition of the fifth lumbar vertebra on the sacrum.

Operation.—Oct. 8, 1920, fusion from the third lumbar vertebra to the sacrum, inclusive, was accomplished. The spinous process of the fifth lumbar vertebra was found to be grossly abnormal, in that the superior border extended horizontally back three fourths of an inch (19 mm.) and the posterior border

Fig. 8 (Case 13).—Compression fracture of the twelfth dorsal vertebra and first lumbar vertebra.

extended downward 1¼ inches (3.2 cm.), bringing about contact with the second sacral spinous process. The relationship of the articular processes was not determined, although there was distinct displacement, as evidenced by the roentgen ray.

Present Condition.—The patient is actively engaged in his usual work and is without symptoms.

CASE 12.—L. A., boy, aged 5 years, stockily built, was run down by an automobile two and a half months previously, receiving injuries to the spine, head and right knee.

Examination.—The posture was awkward and difficult, with moderate rigidity and muscular spasm. There was a slight left curve, with a marked round back deformity, and great prominence of the first lumbar spinous process. The distance between this process and that of the twelfth dorsal vertebra was much increased. There were no symptoms of cord compression. The roentgen ray revealed a compression fracture of the twelfth dorsal and the first lumbar vertebrae, with a half inch (12.7 mm.) posterior displacement of the first lumbar vertebra on the twelfth dorsal vertebra and wide separation of the spinous processes.

Operation.—Dec. 7, 1920, fusion from the eleventh dorsal vertebra to the first lumbar vertebra, inclusive, was accomplished. The tenth dorsal and the second lumbar vertebrae were exposed and found to be in good position. The first was posteriorly placed on the twelfth dorsal vertebra so far that the articular processes had slipped completely by. The twelfth dorsal vertebra was tilted forward and downward, exposing a large section of the cord membrane.

Present Condition.—There is distinct improvement in the degree of displacement of the vertebrae, much improvement of the deformity and complete relief of symptoms.

CASE 13.—C. G., a cadet at West Point, aged 24, small, slender with fairly good musculature, in October, 1912, fell 30 feet (9.5 meters), alighting on the buttocks. Since that time he had had periods of severe pain in the back, with treatment by bed rest and plaster jackets. For ten months previous to his examination here, he had been wearing a jacket, in spite of which there had been increasing pain, weakness and loss of weight.

Examination.—The posture was moderately protective, with marked muscular spasm and pain, especially on hyperextension. The twelfth dorsal spinous process was prominent as a nodular kyphos, and pressure in this region produced a sensation of nausea. All movements were limited. There was no disturbance of cord function. The roentgen ray revealed a severe compression fracture of the twelfth dorsal vertebra, with a wide gap between the spinous process and laminae of this vertebra and the first lumbar vertebra.

Operation.—Jan. 14, 1921, fusion from the tenth dorsal to the first lumbar vertebra, inclusive, was accomplished. All exposed spinous processes were normal, except the twelfth, which was a mere spike, directed straight back and close up under that of the eleventh dorsal vertebra. There were normal relations between the tenth and the eleventh dorsal vertebrae. The twelfth dorsal vertebra had slipped and was impacted so far up under the eleventh that only remnants of the ligament remained. Considerable absorption had taken place on both sides, but it was more marked on the left. Very little motion was present. The displacement between the twelfth dorsal vertebra and the first lumbar

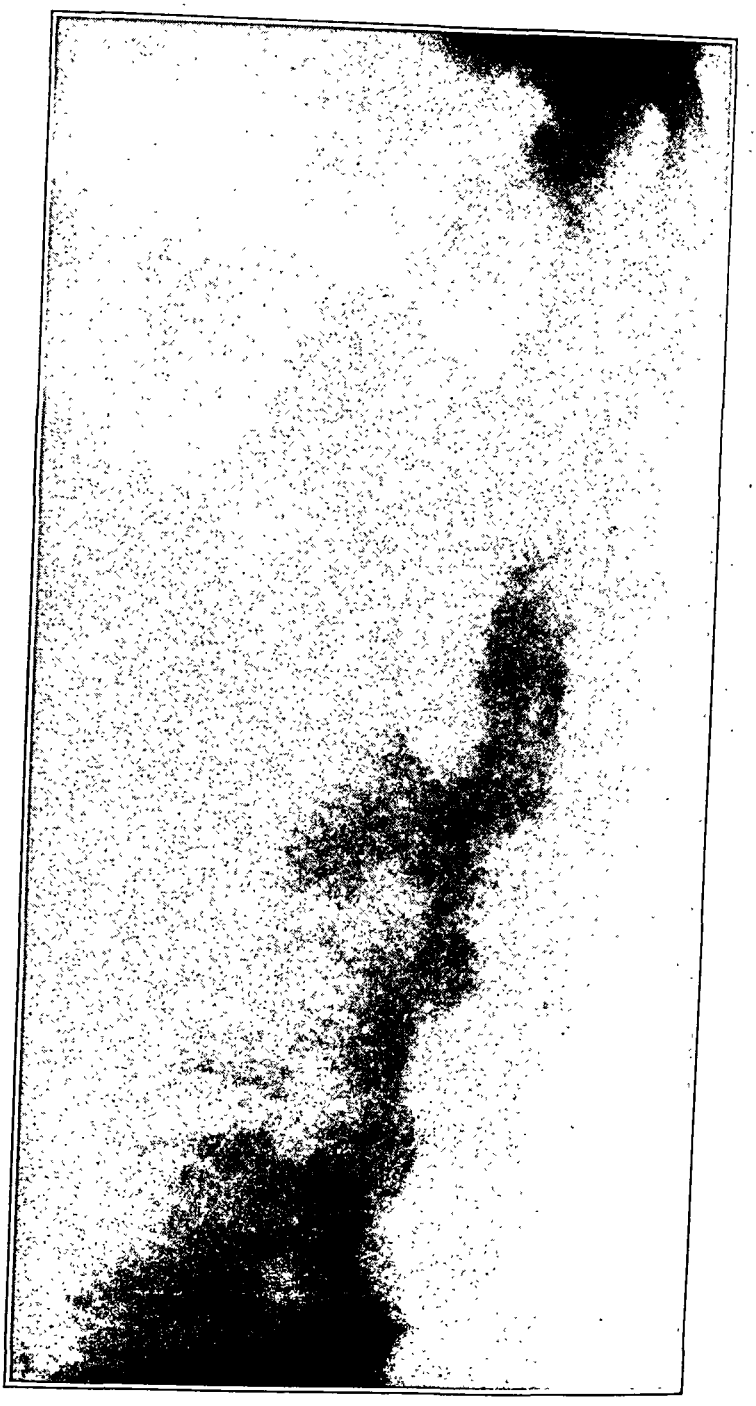

Fig. 9 (Case 13).—Fracture more clearly outlined.

vertebra was so great that contact was made between the articular processes of the first dorsal vertebra and the transverse processes of the twelfth dorsal vertebra. Fusion had taken place. There was a 1 inch (2.5 cm.) gap between the spinous process of the first lumbar vertebra and what remained of the twelfth dorsal vertebra. This gap was well filled in laterally by the fused processes.

Present Condition.—All symptoms are completely relieved. The patient is in good general condition and his normal activities have been resumed.

CASE 14.—Mrs. H. P., aged 35, well built and rather stocky, when 11 years of age fell from a rock, injuring her spine. She wore a plaster jacket for a short time. She had had increasing pain and weakness in her back and limbs since her eighteenth year. Every conceivable treatment, including long periods of bed rest, had been tried, with only temporary relief. At one time she was placed in a sanatorium for her mental condition. She is the mother of three children.

Examination.—The patient stooped slightly, inclining her body to the left side. Motion in all directions was distinctly limited by lumbar rigidity. Pressure in this region caused pain, which was radiated down the limbs. The roentgen ray revealed slight anterior and right displacement, with left rotation of the fifth lumbar vertebra on the sacrum. The spinous processes of the third, fourth and fifth lumbar vertebrae impinged and there was sacro-iliac relaxation, as indicated by abnormal mobility at the pubic synchondrosis.

Operation.—Jan. 28, 1921, fusion from third lumbar vertebra to the sacrum, inclusive, was accomplished. The third spinous process exhibited a bony exostosis as a result of its rubbing on the fourth lumbar vertebra. The fourth was displaced forward from the fracture and impinged tightly on the fifth lumbar vertebra. The first sacral vertebra was very short and laterally displaced. The laminae of the fifth lumbar vertebra were thrust forward under those of the fourth to an abnormal degree, and there was slight lateral deviation of the spine in a general way, with its greatest convexity at the fourth lumbar vertebra. All the articular processes had slipped slightly in accommodation to the deformity.

Present Condition.—The patient is perfectly free from symptoms, perfectly erect and enjoying normal activity.

CASE 15.—W. B., an architect, aged 61, of stocky build and good muscular development, ten years previously had fallen downstairs, alighting on his neck and forcing the head violently forward. Since that time, there had been constant pain in the neck and shoulders. A year before he was seen, the pain was increased by another accident and at the time of examination was very acute.

Examination.—He held his head and neck in a distinctly protective posture, he was unable to extend his head beyond a point of slight flexion. Rotation was about 75 degrees, whereas flexion was nearly complete. Both were limited by pain, which radiated to the midscapular region. The roentgen ray revealed an impacted fracture of the fourth and fifth cervical vertebrae, with tilting forward and downward of the fourth cervical vertebra in such a manner as widely to separate the spinous processes. Bony callus bridged the bodies of the fifth, sixth and seventh vertebrae, anteriorly. The intervertebral disks were very thin.

Fig. 10 (Case 18).—Compression fracture of the fifth lumbar and first sacral vertebra and anterior displacement of the fifth lumbar vertebra.

Operation.—Feb. 18, 1921, fusion from the fourth to the seventh cervical vertebra, inclusive, was accomplished. There was only slight motion between the fourth and fifth vertebrae and between the fifth and sixth. Motion between the sixth and seventh vertebrae was normal.

Present Condition.—The patient is completely relieved. He continues to be active in professional work, plays golf, etc.

CASE 16.—A. P., a maid, aged 23, stocky and well built, at the age of 9 fell downstairs, injuring her spine, which had been weak since that time. Three years ago she fell from a second story window, after which she suffered severe pain which radiated to the thighs. Recently this had been so severe that she had been compelled to give up work altogether.

Examination.—The posture was only slightly protective, although there was tenderness in the lumbar region and pain in the lower back and thighs on forced flexion or hyperextension. There was a depression just below the fifth lumbar spinous process and there was also a moderate left dorsolumbar curve. The roentgen ray revealed incomplete ossification of the first sacral arch, a compression fracture of the fourth and fifth lumbar vertebrae, with resulting left curve and distinct posterior dislocation of the fifth lumbar vertebra on the sacrum. Laterally, there was a wide gap between the bodies of the fourth and fifth lumbar vertebrae.

Operation.—April 12, 1921, fusion from the third lumbar vertebra to the sacrum, inclusive, was accomplished. The first sacral arch was found to be incomplete; the fifth was dislocated posteriorly and to the left and rotated sharply to the right. This displacement caused a considerable luxation of the articular processes and allowed a right sided dislocation of the fourth lumbar vertebra. The lamina of the fourth lumbar vertebra on the right was markedly posterior, because of the rotation; on the left, it was fractured and ununited. The lamina of the fifth lumbar vertebra on this side was irregular, also a result of fracture.

Present Condition.—There was immediate complete relief.

CASE 17.—J. C., a laborer, aged 44, big framed and very muscular, at the age of 19 had injured his back by lifting, and it had never been strong since that time. During the year preceding examination here, there had been considerable pain low down, with radiations into the right side and limb. At times, this pain had become so acute that he had had to discontinue his work.

Examination.—The posture was moderately protective, and the lumbar spine was rigid. Motion was almost completely absent, and when elicited it was accompanied by pain. There was tenderness over the fifth and sixth lumbar spinous processes and over the sacro-iliac joints. The roentgen ray revealed a lumbosacral angle of nearly 90 degrees, with anterior displacement of the sixth lumbar vertebra (there were six), and a thinning of the intervertebral spaces above and below it.

Operation.—May 18, 1921, fusion from the fourth lumbar vertebra to the sacrum, inclusive, was accomplished. The spinous processes of the fourth and fifth lumbar vertebrae were tightly wedged together. The entire sixth lumbar vertebra was abnormally mobile and tilted slightly forward. The lumbosacral angle, as viewed from behind, was very acute.

Present Condition.—Relief was complete and the patient is working daily.

CASE 18.—G. de W., a truck driver, aged 30, rather slender, although well-built and of good muscular development, two years previous to his examination

in this dispensary, had been thrown from a motor cycle against a fence. The left leg was injured but apparently the spine was not. Six weeks later, when he commenced work, pain appeared in the lower back; and instead of disappearing, it had become worse. Recently, it had extended down the right limb and had become so severe that he had had to go to bed.

Fig. 11 (Case 18).—Compression and anterior displacement.

Examination.—The posture was protective, with the lumbar region flat and held rigid by muscular spasm. All motion was greatly impaired; and while there was no evidence of cord pressure at the time of examination, he had had some difficulty from that source. The roentgen ray revealed compression fracture of the fifth lumbar and first sacral vertebrae, with one-fourth inch (6.4

mm.) anterior displacement of the former and much decalcification throughout. The third and fourth lumbar vertebrae were apparently normal.

Operation.—May 31, 1921, fusion from the second lumbar vertebra to the sacrum, inclusive, was accomplished. The laminae of the fifth lumbar vertebra were broken loose through the pedicle on the right side and at the base of the spinous process on the left. This part was dislocated posteriorly. The fifth lumbar vertebra itself was thrust forward. The spinous process was flattened from side to side and its long axis was in a lateral position. The fourth vertebra seemed normal; but the laminae of the third were free, as a result of ununited fractures at their bases. The relations were good and the second was in normal condition.

Present Condition.—The patient has experienced complete relief and has resumed his occupation of truck driver.

CASE 19.—F. K., a lead burner, aged 33, stocky, well built and of good muscular development, while working in M—— in April, 1921, when a scaffolding gave way, fell 20 feet (6 meters), amidst numerous rolls of lead. A diagnosis of fractured spine was made, and a plaster jacket applied. Soon after he was sent back to the United States. Severe symptoms of pressure on the cord persisted for more than a month.

Examination.—There was a small, rounded kyphos, with its apex at the first lumbar vertebra. The spinous processes in this region were so close together that they could not be differentiated. There were active pain and spasm on any motion, but especially on extension and right lateral flexion. He had some numbness in the right thigh, and the patellar reflexes were greatly exaggerated. There was a suggestion of ankle clonus. The roentgen ray revealed a compression fracture of the first lumbar vertebra, with a normal intervertebral disk between it and the twelfth dorsal vertebra, and one that was thinned between it and the second lumbar vertebra. The transverse processes of the first, second, third and fourth lumbar vertebrae were fractured on the right side.

Operation.—June 14, 1921, fusion from the eleventh dorsal to the second lumbar vertebra, inclusive, was accomplished. The first lumbar vertebra was displaced backward on the second by impaction between the laminae. Those of the first and twelfth vertebrae were widely separated; and in the midline, the pulsating cord membranes could be seen. The spinous process of the first was directed to the right in its lower aspect. The vertebra itself was very stable.

Present Condition.—There is complete relief, and he has resumed his occupation.

CASE 20.—M. G., woman, bookkeeper, aged 18, heavy set and fat, about three and a half years previously, had fallen five stories, alighting on her feet and buttocks, and fracturing both legs and her spine. She had had constant treatment of all kinds but had never since been free from pain.

Examination.—The posture was severely protective, with marked muscular spasm on manipulation, and limitation of motion in all directions. A small kyphos was present, with its apex at the third lumbar vertebra. The roentgen ray revealed a compression fracture of the second and third lumbar vertebrae, with the third body dislocated slightly to the right side and sharp wedging, anteriorly, of both. The intervertebral disk was partially destroyed. The fourth lumbar vertebra was displaced a short distance to the left side and its spinous process was down next to that of the fifth lumbar vertebra. The spinous processes of the second and third lumbar vertebrae were also impinging.

Operation.—July 12, 1921, fusion from the second lumbar to the fifth lumbar vertebra, inclusive, was accomplished. The spinous processes of the second and third lumbar vertebrae were tightly opposed to one another, even though the third was dislocated downward sufficiently to make contact with the fourth, and the fourth overrode the fifth on the left side for nearly one-fourth inch (6.4 mm.). The second lumbar vertebra was slightly displaced posteriorly on the third, the third was jammed down so far on the fourth that the interlaminal space was almost obliterated. The third was not stable. The fourth was dislocated a short distance to the left side, making possible its peculiar relation to the fifth, which seemed normal. The articular facets were displaced, in keeping with the other parts of the vertebrae.

Present Condition.—The patient is back at work, free from symptoms.

CASE 21.—M. W., a volunteer fireman, aged 29, very large, powerful, and big-boned, a year ago last May was thrown from a fire truck and received what was diagnosed as a fracture of the spine. He was in bed three months, and wore a plaster support for six. The pain in the lower back and down the right thigh, however, had continued. He had been on light duty since September, 1920.

Examination.—The posture was good, except for a slight deviation of the trunk to the left. Flexibility was fairly free, except to the right. Muscular spasm could be elicited only when manipulations were forced. The roentgen ray revealed a compression fracture of the fourth and fifth lumbar vertebrae on the left side, with spinal inclination to the same side and slight posterior displacement of the fifth on the sacrum.

Operation.—Aug. 9, 1921, fusion from the fourth lumbar to the sacrum, inclusive, was accomplished. The spinous processes of the third and fourth lumbar vertebrae were bifurcated in the lower aspect of the tips, and were in contact with the fifth. The fifth lumbar vertebra was dislocated back and down on the sacrum, fully a half inch (12.7 mm.), the articular facets nearly passing one another. The same condition was true of the fourth and the fifth, but only to about half the extent. The relations between the third and fourth were normal except for the spinous processes; so the third vertebra was not included in the fusion.

Present Condition.—The patient is back at work and has no symptoms.

CASE 22.—S. S., a monument worker, aged 18, tall, with fair musculature, when 12 years of age had fallen 10 feet (3 meters), alighting on his buttocks. He was not completely disabled; but since he had been active, there had been a great deal of aching in the lower back and some sharp pain between the shoulders. Also, on one occasion, after an accident, there had been pain in the left hip.

Examination.—The posture was military, with an exaggerated lordosis; but there was prominence of the upper end of the sacrum. The seventh dorsal spinous process was also prominent. There was a wide gap between it and the eighth lumbar vertebra and also between the fourth and fifth lumbar vertebrae. All spinal movements were limited, especially flexion. The lumbar muscles were greatly hypertrophied. The roentgen ray revealed an anterior displacement of the fifth lumbar vertebra on the sacrum, of nearly three-fourths inch (19 mm.). Its relation to the fourth lumbar vertebra seemed normal, although there was thinning and collapse of the bodies of both this vertebra and of the first sacral vertebra. No abnormality of the seventh or eighth dorsal vertebra could be seen.

Operation.—Aug. 31, 1921, fusion from the third lumbar vertebra to the sacrum, inclusive, was accomplished. Fully three-fourths inch (19 mm.) anterior displacement of the fifth lumbar vertebra on the sacrum was found. The neural arch of this vertebra was loose through ununited fractures in the pedicles on either side. The laminae of the fourth lumbar vertebra almost came into contact with the anterior and upper portions of those of the first sacral, although the fourth was tilted down in such a way as to direct them nearly straight back. The position was not stable, but no ununited fracture could be demonstrated. The articular facets of the third vertebra had slid half way past those of the fourth lumbar vertebra, while those of the fifth and first sacral vertebrae were almost completely absorbed. The relations between the second and third were normal.

Present Condition.—The patient is now in school and the symptoms are relieved.

CONCLUSIONS

It is evident from the study of these cases that:

1. Many fracture-dislocations of the spine are not recognized.

2. They occur with greatest frequency in the lumbar spine; and the fifth lumbar vertebra is the one most often injured.

3. Those which take place in childhood may not cause symptoms until adult life, when the completed ossification of the vertebrae destroys their capacity for accommodation to altered shape and position.

4. The symptoms are caused by the mobility of these altered joints and ununited fractures. Elimination of motion is essential to complete and permanent relief.

5. Fusion of the articulating bones is a means to that end. It has been accomplished by the operation herein described, with complete relief in every case.

6. The safety and completeness of the exposure made in this dissection would seem to justify its use as a means of diagnosis in exceptional cases of patients seriously disabled, when every other means has failed, such as Cases 16, 18 and 22.

CARCINOMA OF THE LUNG: A STUDY OF ITS INCIDENCE, PATHOLOGY AND RELATIVE IMPORTANCE

WITH A REPORT OF THIRTEEN CASES STUDIED AT NECROPSY *

MOSES BARRON, M.D.

MINNEAPOLIS

The increasing incidence of carcinoma of the lungs is attracting the attention of many observers. Since the time it was first recognized by Bayle,[1] in 1810, who described it as "phtisie cancereuse," one of his six varieties of phthisis, it has almost been a tradition that carcinoma of the lung is an extremely rare disease of negligible clinical importance and that its antemortem diagnosis is practically impossible. Very few textbooks devote more than a paragraph to the whole subject. A review of the more recent literature shows that it is time to discard these false concepts. The relatively frequent occurrence of the disease is today making imperative for its recognition a more detailed knowledge of its pathology, symptomatology and differential diagnosis.

Hampeln [2] states that the idea of the rarity and undiagnosability of the primary tumors of the lung has been gradually changed since 1895. Not only is there an absolute increase in the number of cases but there is a threefold relative increase. Undiagnosability simply resolves itself into unfamiliarity with the more or less characteristic signs and symptoms. Packard [3] and Fishberg [4] call attention to the evident increasing frequency. The latter adds that this increase has been noted principally by pathologists when making postmortem examinations. Even Adler,[5] as late as 1912, stated that primary malignant neoplasms of the lung are among the rarest forms of disease.

---

* From the Departments of Pathology and Medicine, University of Minnesota Medical School.

* Read in abstract before the Minnesota State Medical Society, Duluth, Minn., Aug. 25, 1921.

1. Bayle: Recherches sur la phtisie pulmonaire, Paris, 1810, cited by Cottin et al., Ann. de méd. **8**:435, 1920.
2. Hampeln: Zur Symptomatologie und Diagnose der primären malignen Lungentumoren, Mitt. a. d. Grenzgeb. d. Med. u. Chir. **31**:672, 1919.
3. Packard, M.: Primary Malignant Neoplasms of the Lung, Am. J. Med. Sc. **154**:351 (Sept.) 1917.
4. Fishberg, M., and Steinbach, M.: The Diagnosis of Intrathoracic Neoplasms, Med. Rec. **99**:513 (March 26) 1921.
5. Adler: Primary Malignant Growths of the Lungs and Bronchi, New York, Longmans, Green & Co., 1912.

STATISTICS

A careful review of the literature demonstrates the increasing importance of this disease. Some of the reports are not reliable because cases are reported as primary carcinoma without necropsy or histologic studies. Statistical study, therefore, loses in value on account of the unverified cases. Postmortem studies, of course, are generally reliable. According to Weller,[6] the prerequisites of an "authentic" case are: first, necropsy; second, nature of the lesion, verified by the microscope; third, establishment of the fact that the neoplasm is not secondary. Wolf,[7] in a series of 20,116 necropsies in the Dresden Hospital from 1852 to 1894, found forty-five cases of primary lung carcinoma (0.223 per cent.). Füchs [8] reported 0.065 per cent. in a series of 12,307 necropsies from the Pathological Institute of Munich from 1854 to 1885. Reinhardt,[9] in 1878, reported five cases, or 0.057 per cent., of lung tumors among 8,716 necropsies from the City Hospital of Dresden. Pässler [10] found 870 cases of carcinoma among 9,246 necropsies in the Pathological Institute of Breslau, from 1881 to 1894. Of these, sixteen cases, or 0.183 per cent. of the total, were pulmonary cancers. Rolleston and Trevor [11] gave statistics from St. George's Hospital covering the period from 1890 to 1902. Among 3,983 necropsies, there were six sarcomas and only two carcinomas of the lung (0.05 per cent.). They state that primary malignant disease of the lung is very rare and most difficult to diagnose and that sarcomas are more frequent than carcinomas. Von Wiczskowski [12] reports 126 cases among 58,497 necropsies (0.21 per cent.). Briese [13] gives a very careful classification of the necropsy findings in 12,971 cases at the Pathologic and Hygienic Institute of Chemnitz, from 1898 to 1916. Among 1,287 cases of carcinoma encountered in this series, 60, or 0.46 per cent. of the total number of necropsies, were primary tumors of the lung. In a list giving the twenty-four principal organs that were the primary seat of carcinoma, the stomach comes first, with 458 cases; the uterus second,

6. Weller, C. V.: Primary Carcinoma of the Larger Bronchi, Arch. Int. Med. **11**:314 (March) 1913.

7. Wolf, K.: Der Primäre Lungenkrebs, Fortschr. d. Med. **13**:725, 1895.

8. Füchs: Beiträge zur Kenntniss der primären Geschwülstbildungen in der Lunge. Diss. München, 1886.

9. Reinhardt: Der Primäre Lungenkrebs, Arch. f. Heilkunde **19**:369, 1878.

10. Pässler: Ueber das Primäre Carcinom der Lunge, Virchows Arch. f. path. Anat. **145**:191, 1896.

11. Rolleston, H. D., and Trevor, R. S.: A Case of Primary Sarcoma of the Lung Simulating Empyema, Brit. M. J. **1**:361, 1903.

12. Von Wiczskowski: Ueber der Primären Lungenkrebs, Wien. klin. Wchnschr. **26**:1067, 1913.

13. Briese: Zur Kenntniss des Primären Lungenkarzinoms mit statistischen Angaben, Frankfurt. Ztschr. f. Path. **23**:48, 1920.

with 187 cases; the lungs and bronchi sixth, with 60 cases; the breast seventh, with 40 cases, and the pancreas tenth, with 24 cases. I give this series to show how early in the list the pulmonary tumors come. It is of interest that the lung tumors come even before those of the breast. A probable explanation for this fact is that patients with operable carcinoma, such as that in the breast, are most likely to die outside of hospitals, from recurrence or metastasis. Oerstrom [14] gives the percentage as 0.31 in 10,272 necropsies at the Charité Pathological Institute in Berlin from 1900 to 1907. Cottin [15] reports twenty-nine cases encountered in the Cantonal Hospital in Geneva during the years 1900 to 1920. Unfortunately, the total number of necropsies is not given. Symmers [16] reports five cases encountered at the Pathological Laboratory of Bellevue Hospital from 1907 to July, 1919; while from July, 1919, to December, 1920, eight cases were encountered Fishberg [4] reports thirty-three cases from the Montefiore Hospital in New York City during the past five years.

In a series of 4,362 necropsies performed in the Department of Pathology of the University of Minnesota from 1899 to June, 1921, there are recorded thirteen cases of primary carcinoma of the lung (0.29 per cent.). From 1899 to 1911, there is not a single case of carcinoma of the lung recorded in a series of 1,333 necropsies. From 1912 to 1918, inclusive, a period of seven years, there are recorded four cases in a series of 2,026 necropsies, or 0.2 per cent. From January, 1919, to June, 1921, a period of two and one-half years, there were performed 1,003 necropsies; and in this series, nine cases of primary pulmonary carcinoma were found. This makes 0.9 per cent. for this series, giving the highest figure recorded in the literature. Of course, one cannot draw any conclusions from a series so small. Nevertheless, it is of extreme interest to find the figures up to 1918 corresponding very closely to those found in the literature, but that in the period from 1919 to the present time the figure rises abruptly to about four times the average incidence as revealed by large statistics. Kaufmann [17] gives 1.76 per cent. as the frequency of pulmonary carcinoma in relation to carcinomas in general. Since all forms of carcinoma comprise about 10 per cent. of all cases studied at necropsy, Kaufmann's percentage for pulmonary tumors would be less than 0.2 per cent. Ewing [18] places the percentage even lower, approaching more nearly

14. Oerstrom, cited by Edlavitch, B. M.: J. A. M. A. **59**:181 (July 20) 1912.

15. Cottin, Cramer et Saloz: Du Diagnostic de Cancer primitif du Poumon, Ann. de méd. **8**:435, 1920.

16. Symmers, cited by Fishberg and Steinbach: Med. Rec. **99**:513 (March 26) 1921.

17. Kaufmann: Spezielle pathologische Anatomie, Ed. 6, 1911, **1**:310, 1911.

18. Ewing, James: Neoplastic Diseases, Philadelphia, W. B. Saunders Company, 1919, p. 785.

0.1 per cent. The apparent increase in the number of primary lung tumors encountered by the authors above mentioned is: Reinhardt, 1878, 0.057 per cent.; Füchs, 1885, 0.065 per cent.; Pässler, 1894, 0.083 per cent.; Wolf, 1894, 0.223 per cent.; Oerstrom, 1907, 0.31 per cent.; Briese, 1916, 0.46 per cent., and our series, 1919-1921, 0.9 per cent.

ETIOLOGY

The etiology of pulmonary cancer offers the same difficulties of solution as any other type of cancer. Trauma plays perhaps an even lesser rôle that in neoplasms elsewhere, since the lungs are so well protected by a bony cage; but Ewing believes that it has figured prominently in the history of many cases. Race and heredity are apparently unimportant factors. There is a definite relation to sex, the proportion being given as three in the male to one in the female (Adler,[5] Briese,[13] Kaufmann,[17] and Ewing [18]). The greatest incidence is in the sixth decade (about 30 per cent.); and more than 75 per cent. of the cases occur between the ages of 40 and 70. In Briese's series, the youngest patient was 26. Adler cites six cases occurring between the ages of 10 and 20 and Ewing tells of one case in a girl, 7 years old. In our series, 92 per cent. of the cases occurred between the ages of 40 and 70—the youngest patient being 42 and the oldest 72 years.

Perhaps the chief etiologic factors are inflammatory conditions, and of these, tuberculosis is the most important. This is contrary to Rokitansky's old dictum that carcinoma and tuberculosis are incompatible—that tuberculosis practically precludes cancer. Many series of cases in the literature have proved that carcinoma is not infrequently found associated with tuberculosis, developing especially in the scars and walls of tuberculous cavities. The explanation for Rokitansky's statement probably lies in the fact that tuberculosis is a disease of early adult life while carcinoma is a disease of late adult life; the two diseases, therefore, having different age incidence. Paterson [19] suggests that persons possessing an inherited tendency to tissue proliferation might be resistant to the development of tuberculosis.

Kaufmann states that the tumor develops in the walls of bronchiectatic cavities as well as in those of tuberculosis. The bronchiectasis encountered, however, is more often probably the result, rather than the cause, of the neoplasm; the dilatation arising from partial stenosis and secondary inflammatory changes consequent on the new growth. Several of our cases, especially Cases 6 and 10, show this fact very plainly. The unusual statistics from the cobalt, nickel, and bismuth

19. Paterson: Pulmonary Tuberculosis, in Tice, Frederick: Practice of Medicine, Hagerstown, Md., W. F. Prior Company **2**:475, 1920.

mines of Schneeberg, Silesia, for the period of 1879 to 1884, so often quoted in the literature, are now no longer invoked to prove the relation of chronic irritation to cancer. According to these statistics, among from 600 to 700 men employed, there was a yearly mortality of from 28 to 32, of which 75 per cent. were said to be due to pulmonary cancer. It is now believed that most of the lesions then reported were inflammatory and not neoplastic in origin.

I believe that it is not at all unlikely that another chronic inflammatory process may be responsible for a number of pulmonary cancers encountered during the past few years. It is possible that this might explain the rather striking increase in incidence recently. I have in mind the influenza epidemic of 1918-1919. The rather striking increase in the number of cases in our series during the past two and one-half years (nine cases) over that of the previous eighteen years (four cases) was also the experience of Dr. Symmers of Bellevue Hospital in New York, where from July, 1919, to December, 1920, during a period of a year and a half, they encountered eight cases, while during the previous twelve and a half years they had encountered only five cases. In discussing this subject with pathologists from other hospitals, I found that the same impression of an increase in incidence since 1918 seems to obtain. It is, therefore, not far fetched to assume that there may be a causal relation between the residual pulmonary lesions from the influenza epidemic and the present apparent increase in lung carcinomas.

PATHOLOGY

Carcinomas of the lung vary greatly in the gross and microscopic appearances. Some authors try to differentiate between the bronchial and parenchymal carcinomas in their classifications but this distinction is now being discarded. Grossly the tumors may be classified in three types: (1) nodular; (2) diffuse or lobar; (3) infiltrating. The third type is the most common and the second type the least common of these tumors. Most of our thirteen cases belong to the third group. There was not a single case encountered of the second, or diffuse, type. As the name implies, the nodular form is a circumscribed tumor which on section is grayish white or yellowish in color and occasionally shows areas of necrosis and small cavity formation (Fig. 1). The second, or diffuse, type sometimes resembles lobar pneumonia, involving one or several lobes. This type is best illustrated by the case reported by Briese. A man, 49 years old, developed a sudden attack of weakness, dyspnea, slight fever and rapid emaciation. There was marked expectoration but few physical signs. Death occurred within nine weeks after the onset. At necropsy both lungs were found to be equally consolidated and enlarged, the right one weighing 2,360 gm.

and the left one 2,750 gm. There was little crepitation, and the tissues of both lungs sank in water. The cut surface was grayish white; the septums appeared anthracotic and a glairy mucus escaped from the bronchi and parenchyma. The bronchial tree was not infiltrated and there were no metastases except into the prevertebral and peribronchial lymph nodes. Microscopically, the tissue showed the alveolar structure well retained and the principal changes were in the lining epithelium. In place of the very flat alveolar cells, there were single layers of high columnar, closely packed, nonciliated cells. The cytoplasm of these cells stained deeply and many of them showed vacuoles. Some of the large alveoli contained papillary projections. Some areas showed low columnar, cubical or flat cells. Indeed, all gradations from the normal to the high columnar type of cell could be traced out. Most of the alveolar spaces were filled with hyaline or granular masses of mucus and débris. The metastases into the lymph nodes showed the same glandular structure as that of a papillary adenocarcinoma.

A case similar to the one described above is that described by Gordon.[20] A woman, 51 years old, was sick four months, with cough, dyspnea, tachycardia, profuse perspiration and progressive anemia. Physical examination revealed consolidation of the right lung suggesting pneumonia. At necropsy, the entire right lung, except the lower portion, was found to be solid, grayish in color, suggesting the gray hepatization of lobar pneumonia. Microscopically, the alveolar structure was well preserved. The general appearance was the same as that described in the previous case. Another case of this type is reported by Ravenna[21] in a man, 45 years old, who presented consolidation of the right lower lobe. Studies at necropsy revealed changes similar to the preceding. Ravenna believes that this tumor originated in the bronchial epithelium and not in the alveolar epithelium. He quotes Marchiafava[22] and Malassez[23] to support his contention.

The infiltrating variety generally starts from one of the larger bronchi and infiltrates the surrounding lung tissue; sometimes the tumor follows closely along the bronchial ramifications.

The size of the tumors varies. Occasionally, they are so small that only the metastases produce the symptoms. As to location, most

---

20. Gordon, A. K.: Primary Diffuse Alveolar Carcinoma of the Lung, Lancet **2**:501 (Sept. 4) 1920.

21. Ravenna: Contribution à l'étude du cancer primitif du poumon, Arch. de Méd. exper. et d'anat. Path. **21**:87, 1909.

22. Marchiafava: Di un cancro primitiva del polmone a cellule cilindriche con reproduzione vel cervello e nell osso frontale, Riv. de clin., Bologna **4**: 150, 1873.

23. Malassez: Examen histologique d'un cas de cancer encéphaloïde du poumon, Arch. de physiol. norm. et path. **2**:353, 1876.

authors agree that the right lung is more often involved than the left and that the upper lobe is more frequently affected than the lower. Hampeln, in a large series of cases, found the upper lobe involved about three times as often as the lower.

HISTOGENESIS

The histology of the lung presents three types of epithelial elements which may give rise to tumors: (1) bronchial epithelium; (2) bronchial mucous glands, and (3) alveolar epithelium. The histogenesis of most of the tumors encountered is very difficult to determine except perhaps in very early stages. The difficulty is due to the fact that the morphology of neoplastic cells is modified by inflammatory processes associated with the new growth and that the lung tissue by its very nature is especially susceptible to the development of extensive inflammatory reactions. Besides, the three types of epithelial cells just mentioned are very closely related morphologically; the secretory cells of the mucous glands and the pavement cells lining the alveoli are only slightly modified columnar cells which line the bronchi. It is far-fetched, therefore, to conclude, as some authors do, that the squamous-cell carcinomas have their origin in the alveolar epithelium merely because they happen to be flat squamous cells. Similarly, some authors trace the origin of certain tumors to the mucous glands simply because there is an abundant mucoid secretion in the tissue; but the presence of intracellular or intra-acinar mucus is no evidence of the origin of the tumor from the glands, to the exclusion of its origin from bronchial epithelial cells, since the latter also secrete mucus.[6] Thus, we find that the criteria for the origin of some of the tumors described in the literature are erroneous.

Most authors believe that the majority of these tumors arise from the bronchial epithelium and that only a very few arise from the parenchymal or alveolar epithelium. The cases of Briese, Gordon and probably Ravenna, cited above, most likely belong to the latter group; but these cases are so rare that, as Adler well points out, a primary carcinoma of the lung is a bronchial carcinoma. Pässler claims that no definite case has as yet been shown to have originated from the alveoli. Kaufmann believes, on the other hand, that these tumors arise principally from the mucous glands.

Histologically, lung cancers may be classified into several groups:

1. Cylindric cell carcinoma: (*a*) adenocarcinoma; (*b*) carcinoma simplex; (*c*) scirrhous carcinoma; (*d*) alveolar carcinoma; (*e*) medullary carcinoma, and (*f*) colloid or gelatinous carcinoma.
2. Squamous-cell carcinoma (cancroid).
3. Mixed type.

The cylindric cell carcinomas are the most common of the lung tumors. These may be subdivided into types, depending on the arrangement and grouping of the cells. Of these, the adenocarcinoma is the one most often encountered. Figure 7 represents a typical example of adenocarcinoma. There are typical glandlike structures, lined by one or several layers of cylindric epithelium. In cases of diffuse (alveolar) carcinoma, large papillary invaginations are often present, suggesting the papillary type of adenocarcinoma. Many of the lining cells show vacuoles containing mucoid secretion. In a few cases reported, the alveoli are filled with quantities of mucinous material. When this material is very abundant, both the gross and microscopic pictures suggest colloid or gelatinous carcinoma. Both Aschoff [24] and Kaufmann [17] refer to this type. Some authors are of the opinion that this abundance of mucus demonstrates the origin of this type of tumor from the mucous glands. As has been mentioned, this is not a safe basis for such conclusion. Another group of tumors shows arrangements strongly resembling the bronchial mucous glands (Fig. 3). In these glandlike structures, the individual cells have very distinct cell outlines and cell walls. This fact I believe to be of importance in tracing their histogenesis from the bronchial glands.

Carcinoma Simplex.—This tumor arises from either the bronchial epithelium or from the mucous glands. It shows irregular, solid nests or cords of undifferentiated epithelial cells surrounded by a connective tissue stroma.

Scirrhous Carcinoma.—Some tumors are slow growing and present enormous amounts of connective tissue proliferation with relatively few tumor cells. It is quite likely that this type of tumor originates most frequently from the mucous glands. Figure 11 illustrates this type. Langhans [25] reports a scirrhous type of carcinoma in which he traced an unbroken series of hyperplastic glands into infiltrating cords of tumor cells. His case is very similar to our Case 13. Some areas show an overgrowth of glands which break up and become dislocated in the dense connective tissue stroma, as cords and strands of cells. Langhans believes that the deeper acini are the ones to become first involved.

Alveolar Carcinoma.—Large solid masses of pleomorphic cells occupy spaces resembling lung alveoli. Often the connective tissue septums between the tumor cells are the remains of the alveolar walls, a fact demonstrable by the use of elastic tissue stains which show the presence of elastic fibers.

Medullary Carcinoma.—A small group of cases present microscopic pictures which make it difficult at times to differentiate between

24. Aschoff: Pathologische Anatomie, Ed. 3 **2**:333, 1913.

25. Langhans: Primärer Krebs der Trachea und Bronchien, Virchows Arch. f. Path. Anat. **53**:470, 1871.

carcinoma and sarcoma. The cells are often compact, small, pleomorphic and have very little cytoplasm. Figure 4 illustrates such a case. It is quite likely that a number of tumors reported as sarcomas in the literature belong to this type. Ewing believes that of the ninety cases of sarcoma reported by Adler only a minority present sufficient evidence to justify their separation from the diffuse carcinomas. From the description, the case reported by Blumgarten [26] corresponds more to a carcinoma than to a sarcoma, though he reported it with the latter diagnosis. He describes closely packed cells, collected into islands or columns or forming the lining of the alveolar spaces. Rolleston and Trevor state that the primary tumor of the lung is generally in the nature of sarcoma, a conclusion directly opposed to that of most observers. Aschoff, for example, states that of the primary lung tumors sarcoma is extremely rare. It is very likely that the English authors are confused in the identification of these tumors.

Colloid or Gelatinous Carcinoma.—This type of tumor I have already described under the adenocarcinomas. No case of this type was encountered in our series.

Squamous-Cell Carcinoma.—This is a very interesting type of tumor, especially from the standpoint of its histogenesis. It has attracted the attention of many observers. Statistics vary as to its frequency. In our series we had one cornifying and one non-cornifying type of cancroid. In classifying eighty-five cases of carcinoma from the literature, Henrici [27] found twelve cases of acanthomas, of which only four were cornifying. Wolf [28] found eight acanthomas among fifteen bronchial carcinomas. According to the statistics of Watsuji,[29] 32.2 per cent. of all pulmonary carcinomas are of the pavement cell variety. This is certainly not borne out by statistics in general. The statistics of Knieriem [30] relative to his findings on the proportions of pulmonary cancers appear to coincide more accurately with the general statistics on this subject. He reported, in 1909, that in Leipzig during nine years there were seven acanthomas in a total of seventy-five cases of cancer of the lung—an incidence of about 10 per cent.

---

26. Blumgarten: Primary Malignant Tumor of the Lung, M. Clinics N. Am. **2**:1145, 1919.

27. Henrici: Primary Cancer of the Lung, J. M. Research **21**:395, 1912.

28. Wolf, cited by Ewing, James: Neoplastic Diseases, Philadelphia, W. B. Saunders Company, 1919, p. 789.

29. Watsuji: Ztschr. f. Krebsforsch. **1**:445 (cited by Adler: Footnote 5).

30. Knieriem: Ueber ein primäres Lungenkarzinom, Verhandl. d. deutsch. path. Gesellsch. 1909, p. 407.

The origin of this type of tumor is still under discussion. Schottelius [31] believes that it has its origin in the lymphatic endothelial cells. This view has, of course, been discarded. Another view is that it originates in the basement epithelial cells of the alveoli. Edlavitch [32] reports a case of acanthoma in which he says the tumor cells have a striking resemblance to the squamous epithelium normally lining the air spaces; and he, therefore, concludes that the tumor arose from the alveolar epithelium. I have already pointed out the fallacy of such a conclusion. Another theory is that these tumors arise from epithelial rests. This is a possibility; but the more accepted theory is that of cellular metaplasia. The consensus of opinion now is that the acanthomas nearly always arise through epithelial metaplasia in the bronchi. Ernst [33] believes that the tumor may develop in an area of preexisting squamous-cell metaplasia. He cites the case of Seigert [34] in which a benign papilloma with epithelial pearls was found in the trachea at the bifurcation. He believes that such a benign tumor may undergo malignant change. Haythorn,[35] working in the Magie Laboratory of the Mercy Hospital, Pittsburgh, found areas of squamous-cell metaplasia in the epithelium of the bronchi in three cases of pneumonia. He believes that the squamous epithelium replaced the columnar epithelial cells after the latter disappeared through the inflammatory process. Davis and LeCount,[36] in their case of squamous-cell carcinoma of the main left bronchus, found that the mucosa of the trachea from 1 cm. above the bifurcation, extending well into both primary bronchi, resembled skin. In this case, also, the metaplasia apparently appeared first.

As has already been mentioned, a condition often associated with acanthoma is tuberculosis. Kaufmann, Aschoff and others believe that most cases of this type of tumor originate in the scars and fibrotic walls of tuberculous cavities. Askanazy [37] has shown that squamous epithelium may result from irritation in the respiratory tube. He found patches of this type of epithelium replacing the columnar ciliated epithelial cells of the trachea and bronchi in thirty-eight out of ninety

31. Schottelius: Ein Fall von Primären Lungenkrebs., Diss. Würzburg, 1874.

32. Edlavitch, B. M.: Primary Carcinoma of the Lung, J. A. M. A. **59**: 181 (July 20) 1912.

33. Ernst: Ein verhorenden Plattenepithelkrebs des Bronchus: Metaplasie oder Aberration, Beitr. z. path. Anat. u. z. allg. Path. **20**:155, 1896.

34. Seigert: Ueber primäre Geschwülste der unteren Luftwege, Virchows Arch. f. path. Anat. **129**:413, 1892.

35. Haythorn, cited by Henrici: J. M. Research **21**:395, 1912.

36. Davis and Le Count: Report of Two Cases of Primary Bronchus Carcinoma, Tr. Chicago Path. Soc. **7**:129, 1908.

37. Askanazy, M.: Ueber die Veränderungen der grossen Luftwege besonders ihre Epithel-mätaplasie bei der Influenza, Cor.-Bl. f. schweiz. Aerzte **49**: 80 (Jan. 18) 1919.

cases in which the patients had died in the influenza epidemic of 1918. The multiple layers of stratified epithelium extended into the ducts of some of the glands. He believes that such epithelial metaplasia may predispose to tumor formation. Ernst calls attention to the fact that cornifying squamous epithelium is not infrequently encountered in ozena, chronic endometritis, tuberculosis of the trachea, ichthyosis of the tongue, etc. Squamous epithelial cells are sometimes found also in the gallbladder and kidney pelvis as a result of irritation from calculi. Figure 10 shows an excellent example of a cornifying squamous-cell carcinoma and Figure 2 shows a noncornifying one.

The possibility of these tumors arising from metaplasia of alveolar epithelial cells as well as of bronchial epithelium cannot be denied.

Mixed Type.—A few tumors have been encountered in which there are several types of cells and structures. Meyenburg[38] has found such a tumor in the lower part of the trachea. The tumor showed areas of typical basal-cell carcinoma with areas of cornification on the surface and areas containing cylindric cells and ciliated columnar cells in other parts. No tumor of this type was encountered in our series.

METASTASES

The metastases from lung carcinomas are frequent and numerous. According to Adler, the principal metastases in his collection of 374 cases were to these organs: (1) lymph nodes, 117; (2) liver, 103; (3) lungs, 66; (4) kidneys, 58; (5) suprarenals, 38; (6) brain, 28 (dura mater, 10), and (7) bones (vertebrae, 5).

Briese in his series of sixty cases found metastases absent in only four cases. Of the twenty-one organs and tissues listed in the order of frequency, the principal ones involved were: (1) regional lymph nodes, 43; (2) liver, 25; (3) pleura, 17; (4) kidney, 17; (7) lungs, 11; (8) brain, 11; (9) bones, 9; (12) ovary, 7; (13) suprarenals, 6, and (17) dura, 3.

These statistics are fairly representative of the findings of most observers. The relative frequency of kidney, brain, thyroid and suprarenal metastases is worthy of note. The sparseness of cases reported with bone metastases may be due to the fact that, at routine postmortem examinations, the involvement of bones is often overlooked. Often in only those cases in which definite symptoms had resulted from bone lesions are the bones examined. As previously mentioned, the metastasis sometimes presents the principal and only symptoms. Numerous cases may be found in the literature in which only the necropsy revealed the true primary lesion when the clinical diagnosis

38. Meyenburg: Ueber eine Basalzellengeschwulst der Trachea mit teilweiser Differenzierung zu Pflaster- und Zylinder bzw. Flimmerepithel, Centralbl. f. allg. Path. u. path. Anat. **30**:577, 1920.

of cerebral hemorrhage, brain tumor or abdominal tumor had been made. Boecker[39] reported a case of primary carcinoma of the right lung in which the clinical diagnosis had been cerebral apoplexy. The necropsy, however, revealed the true lesion. Brain metastases are so frequent that one should always keep this fact in mind in cases in which brain symptoms develop in conjunction with evidences of indefinite, progressive, pathologic conditions of the chest. In one of our cases (Case 7) the brain symptoms predominated; while in another case (Case 13) the only findings elicited clinically were those of lumbar Pott's disease.

SYMPTOMATOLOGY

The symptoms of lung tumors may be so variable as to cause great confusion in diagnosis. The reason for this is quite obvious: The entire respiratory tract is subject to such a large variety of inflammatory processes which produce symptoms and findings that fairly blend into one another. Besides, lesions in the mediastinum also produce secondary effects on the lungs. In addition to these processes, there is still a third complication which causes great confusion in symptoms, that of inflammatory processes, such as bronchiectasis, which so frequently complicate pulmonary tumors. The symptoms, therefore, are at times inflammatory rather than neoplastic in origin. Case 10 illustrates this fact very well, when even the roentgen-ray findings varied so much from time to time that some of the staff, including the roentgenologist, thought the process must be an inflammatory one.

Although cancer of the lung presents no pathognomonic symptoms, there are groups of symptoms that are fairly common in this disease. I shall discuss the most important ones.

1. *Cough.*—This is a frequent and early symptom. It is often very annoying. At first the cough is dry but later it may become rasping and productive.

2. *Pain.*—This is commonly present. At times it consists only of a sense of discomfort or oppression in the chest. In some cases, there are unilateral intercostal neuralgias or pain in one shoulder or arm These have a slow onset and not the acute onset of ordinary neuralgias. The pain may be due to the cancer cells infiltrating the nerve bundles. Figures 6 and 13 show how extensive this infiltration frequently becomes.

3. *Dyspnea.*—This is a late symptom. Early there is a sense of oppression in the chest which gradually may develop into a mild and later into a severe dyspnea. At times it may go on to orthopnea.

39. Boecker: Zur Kenntniss der primären Lungenkarzinom, Virchows Arch. f. path. Anat. **202**:38, 1910.

4. *Weakness.*—In some cases, a general sense of weakness begins quite early.

5. *Cachexia.*—Usually, the cachexia is not marked except in the late stages. The loss of weight as a rule is only mild or moderate.

6. *Fever.*—This symptom is not infrequent because of the inflammatory complications so often present. Some patients even have chills and night sweats.

Of the physical findings, only a few need be mentioned. One of these is flatness of the chest when an effusion is present. A prominent finding is "cornage," a condition which is dependent on partial obstruction to a bronchus. The persistence of this sign when other findings were disappearing was the basis of insisting on the diagnosis of carcinoma in one case of our series (Case 10).

The term "cornage" was first used by a Frenchman, Behier,[40] and designates a peculiar type of tubular breathing elicited by auscultation, which is caused by the narrowing of the bronchus by compression. Cornage, together with bloody sputum, is very significant.

LABORATORY FINDINGS

Examination of the blood furnishes nothing characteristic. The sputum is frequently tenacious and may be blood streaked. A sanguinous sputum is fairly common during some stage of the disease. Occasionally, the so-called "current jelly" sputum may be obtained. Some patients have recurrent periods of expectoration of large quantities of mucopurulent or purulent material. This is generally due to bronchiectasis which develops as a result of stenosis of some part of the bronchial tree. A history of a thin mucosanguinous sputum extending over a period of weeks or months without much fever, chills or night sweats is very suggestive of a bronchial ulceration from a neoplastic growth. Of course, chronic passive congestion of the lungs must be borne in mind. Some authors have described large clear fatty cells in the sputum but these are not at all constant. According to Fishberg, a pleural exudate is present in 50 per cent. of the cases. This exudate is yellowish at first but later may become sanguinous or purulent. However, the fluid is not characteristic. The large cells containing vacuoles sometimes present in the fluid, which are considered of some importance by a few observers, are probably nothing more than degenerating desquamated endothelial cells.

DIAGNOSIS

Some cases of uncomplicated cancer should offer no difficulty in diagnosis. When there is a history of gradual insidious onset, per-

40. Behier: Hôp. de la Petie, Gaz. d. hôp. **45**:177, 1867, cited by Cottin: Ann. de méd. **8**:435, 1920.

sistent thin mucosanguinous expectoration, slight or no increase in temperature, thoracic pain, evidence of pulmonary induration on physical examination associated perhaps with "cornage," a definite asymmetry of the chest together with subclavian or axillary adenopathy and, in addition, perhaps some roentgen-ray findings—such a group of symptoms and findings obviously enough point to a definite diagnosis, but, unfortunately, only a few of the cases present so classical a picture. Since no symptoms or physical findings per se are entirely pathognomonic (that which may be decisive in one case may be negligible in another), it is very important that a detailed history be taken and a complete and thorough physical examination be made. All facts obtainable in the case should be carefully collected and correlated. The sputum should be examined both for the absence of tubercle bacilli and for positive cytologic findings. Whenever indicated, paracentesis should be performed and the exudate studied. If enlarged lymph nodes are present, especially when these nodes appear in unusual locations on the chest wall, biopsies should be resorted to. Cottin and his co-workers found adenopathy in about 66 per cent. of their cases. Most of the recent observers state that the clinical diagnosis is made principally on the history, course, symptoms and physical signs; the laboratory procedures, such as roentgen-ray, sputum and chest fluid examinations, though useful and necessary, are more for confirmation than for actual diagnosis.[41] Fishberg and Steinbach state that they failed, only once during the past five years, to make a correct diagnosis in their series of thirty-three cases, while only four cases of this same series were diagnosed correctly before admission. The preliminary diagnoses in this series indicate some of the conditions that are to be considered in differential diagnosis. They are tuberculosis (13 cases), pleurisy with effusion or empyema (7 cases), chronic pneumonia (2 cases), neurologic (1 case), lung abscess (2 cases), cardiac disease (2 cases) and carcinoma of the lung (4 cases). To this list may be added mediastinal tumor (mediastinal [Hodgkin's] sarcoma), aortic aneurysm and mediastinal and encysted abscesses. Fishberg points out that there are two symptoms in carcinoma which are rarely seen in early tuberculosis: (1) pain in the chest, and (2) dyspnea. He says:

"Nearly all patients with malignant growths in the chest cough and expectorate sputum. It is important to think of a pulmonary neoplasm when a patient in the cancer age, showing no symptoms of cardiac, renal or arterial disease, begins to cough and is short-winded. In patients who have passed middle age, pain in the chest, with or without a pleural effusion, is suggestive. Patients with enlarged tuber-

41. Fishberg, M., and Steinbach, M.: Footnote 4; Von Wiczskowski: Footnote 12.

culous glands in the neck hardly ever have signs of active disease in the lungs, while when the glands are malignant we find signs of extensive changes in the lungs."

I would recommend the reader to refer to Fishberg's original article for a concise detailed study of the diagnosis of intrathoracic neoplasms.

Another author emphasizes the possibility of properly diagnosing lung tumors clinically by making very exact physical examinations. Sehrt [42] states that during twelve years of practice he diagnosed correctly during life nine cases out of a total of ten cases which he encountered.

Many authors have found the roentgenogram either of negative value or at times even misleading. This is contrary to the statement of McMahon and Carman [43] that in most instances the roentgenologic findings in primary carcinoma are pathognomonic of the disease and may be the first to suggest the exact nature of the pulmonary lesion. I have observed in our series of cases, as well as in the reports from the literature, that this is not the usual experience. It is readily seen that the concomitant inflammatory reactions and bronchiectases may give conflicting shadows, a condition well illustrated in Case 10 of our series. Two other means of diagnosis are mentioned here, simply because they are sometimes invoked for aid. These are bronchoscopy and pulmonary biopsy. Both are so difficult to perform that their use is not to be encouraged at the present time. When, however, the tumor infiltrates and finally perforates the chest wall so as to present subcutaneous nodules, then a biopsy is indicated.

COMPLICATIONS

Bronchiectasis is a very common and important complication. Pulmonary hemorrhages may occur from erosions; but these are usually small. Very rarely, there are erosions of the large branches of the pulmonary artery or vein with resultant fatal hemorrhages. Stillman [44] reports a case which presented a marked swelling of the neck. Necropsy showed that this was due to thrombosis of the inferior vena cava resulting from a tumor mass around the right bronchus.

PROGNOSIS

The prognosis at the present time is hopeless. The course varies from several weeks to four or five years, the majority of cases running a course of about one or one and a half years.

42. Sehrt, cited by Wiczskowski: Wien. klin. Wchnschr. **26**:1067, 1913.

43. McMahon and Carman: The Roentgenologic Diagnosis of Primary Carcinoma of the Lung, Am. J. M. Sc. **155**:34 (Jan.) 1918.

44. Stillman: Carcinoma of the Bronchus with Thrombosis of the Superior Vena Cava, Proc. New York Path. Soc. **20**:66, 1920.

TREATMENT

The difficulties of treatment in this disease are enhanced by the location, the lesion being enclosed in a bony cage, the chest cavity. Surgical interference is not readily applied to this location. Besides, most of the tumors are located at the hilum of the lung, a location in close proximity to the cardiac space and also directly in the region of the pulmonary vessels. In a few cases, excision of the affected tissue has been attempted; but the results are disappointing. Roentgen-ray and radium therapy have thus far also proved of little or no value. The treatment, therefore, resolves itself entirely into the treatment of symptoms.

CARCINOMA IN ANIMALS

Primary carcinoma of the lungs in animals is not infrequent. Slye [45] reports the occurrence of cancer of the lung in about 1 per cent. in a series of 6,000 mice. Tyzzer [46] also reported large spontaneous lung tumors in mice. Seigert [47] reported a case of a large primary cylindric-cell carcinoma in the lower lobe of the lung of a dog. Histologically, he could trace the origin and gradual transition of the tumor from the superficial epithelium of the bronchus.

The thirteen cases in our series are taken from the records of the Department of Pathology, University of Minnesota, covering a period of about twenty-one years. Only concise abstracts of the histories and necropsy protocols will be given. The first case of the series occurred in 1912. Cases 7 and 10 were under my personal observation at the University Hospital and will be given in somewhat greater detail.

REPORT OF CASES

CASE 1 (Necropsy 12-114 [48]).—Mrs. I. T., aged 52, became sick in March, 1912. In July, she developed a severe cough with profuse expectoration. She lost considerable weight; a right-sided effusion developed, and she died Aug. 31, 1921. No clinical diagnosis was stated in the records.

The necropsy was performed by Dr. H. E. Robertson. The body was poorly nourished. The right pleural cavity contained about 2 liters of brownish-red fluid. The middle and lower lobes of the right lung were atelectatic and solid. The upper lobe was normal. There was a large tumor mass surrounding the bronchi near the hilum. This had a soft necrotic reddish-brown center about 2.5 by 4 cm. in extent, with a grayish periphery of infiltrating tumor about 1.5 cm. in thickness (Fig. 1). Small tumor nodules were scattered through the

45. Slye, Holmes and Wells: Tumors of the Lungs in Mice, J. M. Research **25**:417, 1914.

46. Tyzzer: A Series of Spontaneous Tumors in Mice, Fifth Report, Cancer Commission Harvard University, 1909, p. 153.

47. Seigert: Zur Histogenesis der primären Lungenkrebs, Virchows Arch. f. path. Anat. **134**:287, 1893.

48. The first two figures of the necropsy number represent the year in which the necropsy was performed.

Fig. 1.—Right lung from Case 1, showing the centrally located, large tumorous mass with the necrotic center and cavity formation. Its spread is peripherally, from around the secondary bronchi.

Photomicrographs were made by Mr. Henry W. Morris, medical photographer, Department of Pathology, University of Minnesota.

parenchyma. There was a tumor nodule in the left lung near the hilum. The peribronchial lymph nodes were enlarged and infiltrated. Microscopically, sections of the lung showed tumorous areas of glandlike structures lined with irregular columnar epithelial cells. The diagnosis was adenocarcinoma of the right lung with metastases into the lung parenchyma and peribronchial lymph nodes.

CASE 2 (Necropsy 13-63).—J. F. O'N., man, aged 50, in November, 1912, developed a troublesome cough. Later he suffered severe pain, like neuritis, in the right sacroiliac joint. He was sent to a hospital for an operation but none was performed. The cough was persistent and occasionally the sputum was blood-streaked. He died suddenly, April 19, 1913.

Necropsy was performed by Dr. H. E. Robertson. The body was well nourished. There was a palpable mass above the clavicle. The left pleural cavity contained about 200 c.c. of fluid. There were numerous grayish-white

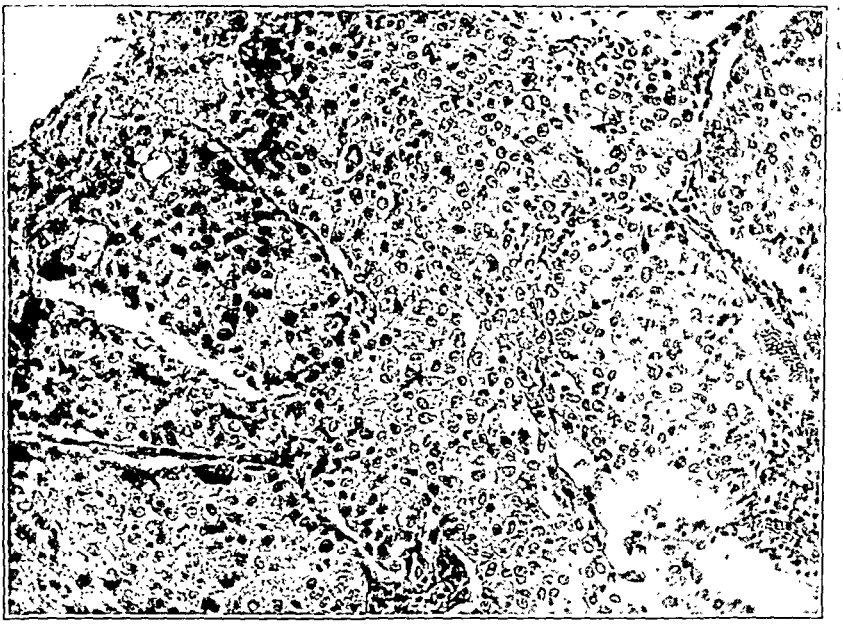

Fig. 2.—Section from tumor of lung from Case 2, showing the closely packed epithelial cells and the narrow strands of connective tissue stroma, probably remnants of the alveolar walls. There is no keratinization but intercellular bridges are visible. This is a good example of a nonkeratinizing squamous-cell carcinoma.

nodules, 2 to 10 mm. in diameter, in the posterior portion of the left lung. Near the base, there was a necrotic, hemorrhagic tumor mass the size of a hen's egg. On section, a mucoid substance came from the cut surface. The tracheal, bronchial, periaortic and inguinal lymph nodes were markedly enlarged. The right pelvic floor was infiltrated. Microscopically, the lung alveoli were partially filled with pleomorphic cells. The nuclei were vesicular. The cytoplasm was deeply staining and contained numerous vacuoles. The alveolar walls were well retained. Numerous mitotic figures were present. Some areas on section showed marked fibrosis; and there was an infiltration of round cells

and small clumps and cords of tumor cells. In some of the clumps of tumor cells, intercellular bridges might be seen; but there was no cornification or epithelial pearl formation (Fig. 2). The diagnosis was nonkeratinizing squamous-cell carcinoma of the left lung, with metastases into the lymph nodes and pelvic floor.

CASE 3 (Necropsy 14-133).—H. K., man, aged 52, first felt ill in March, 1914. He developed pain in the stomach, anorexia and vomiting after each meal. He gradually lost in weight and strength. He was admitted to a hospital, May 5, 1914, where he died, July 12, 1914, no clinical diagnosis having been made.

Necropsy, performed by the author, revealed a poorly nourished body. The left pleural cavity was completely obliterated by strong adhesions. There were a few adhesions at the right apex. There were small grayish nodules at the right apex and around the bronchi of the middle and lower lobes. There was a large tumorous mass near the hilum which infiltrated the parenchyma around the bronchi. There was an increased amount of cerebrospinal fluid in the subarachnoid space and in the ventricles. A tumor mass, 3 cm. in diameter, involved the basal nuclei in the floor of the right ventricle. There was another tumorous mass, 1 cm. in diameter, in the right lobe of the cerebellum. Microscopic examination of the lung revealed alveolar spaces lined with single or multiple irregular layers of columnar cells. The alveolar walls were thickened. Another section showed marked fibrosis, anthracosis and chronic tuberculosis with tubercle formation, containing giant cells. The diagnosis was adenocarcinoma of the right lung with metastases to the brain.

CASE 4 (Necropsy 17-214).—W. R., man, aged 55, admitted to the University Hospital, June 8, 1917, complaining of pain in the right axilla, shoulder and chest, had always been well until Oct. 2, 1916, when he first noticed pain in the left shoulder, anorexia and beginning weakness. From this he recovered slowly and went back to work. In February, 1917, he noticed a swelling of the face which was present only in the daytime at first, but later became persistent. He developed a severe cough and marked dyspnea. He had considerable expectoration. He had to quit his work, May 5, 1917, because of the severity of the symptoms.

Physical examination revealed hyperresonance and impaired voice transmission over the scapular region on the right side. Some areas showed absence of breath sounds. The superficial veins over the trunk and head stood out prominently. There was edema of the face and hands. The pain gradually extended upward over the thorax. Oct. 3, 1917, general anasarca developed. The fingers became clubbed and the finger nails became shaped like watch-crystals. He developed marked dyspnea and Cheyne-Stokes' respiration. He died, Oct. 18, 1917.

The laboratory examinations of the sputum and blood and the phenolsulphonephthalein test and Wassermann reaction were negative.

Necropsy, performed by the author, revealed a poorly nourished body. There was edema of the face, neck, left forearm and hand. Both pleural cavities were obliterated by strong adhesions. The lower portion of the right upper lobe was hard and nodular and adhered strongly to the chest wall by means of infiltrated tumor masses. The lower two thirds of the left upper lobe was also firm and nodular, presenting a tumor mass around the bronchus, 8 by 3 cm. The outer portion of this mass was necrotic and showed intense anthracosis. The color was bluish black. A tumor mass, 3.5 cm. in diameter, was present in the right

lower lobe. This infiltrated the pleura and the diaphragm. The superior vena cava, together with the lower portion of the subclavian and jugular veins, was plugged with tumor masses mixed with thrombus. The anterolateral portions of the first, second, third and fourth ribs on the right side were destroyed by infiltrating tumor masses.

Microscopic sections of the lung showed marked fibrosis with hyalinized connective tissue through which were scattered nests and cords of closely packed pleomorphic epithelial cells. Irregular areas of necrosis were scattered throughout. The diagnosis was carcinoma simplex of the left lung with metastases into the lung, peribronchial lymph nodes, pleura, ribs and superior vena cava.

This case closely resembles the one reported by Stillman.[44]

CASE 5 (Necropsy 19-35).—J. P., woman, aged 58, was admitted to the University Hospital, Dec. 22, 1918, complaining of weakness, shortness of breath, excessive perspiration and severe attacks of coughing. She was sent in with the diagnosis of lumbago, bronchitis and possible bronchopneumonia. Her illness began in June, 1918, with weakness and a sense of continuous exhaustion. About that time she fell from a ladder and struck her chest with a plank. Later she caught cold and developed a cough. She was confined to her bed because of weakness. Examination demonstrated a shallow jerky type of breathing with diminished resonance and vocal fremitus over the left apex. The breath sounds were of a high pitched bronchovesicular type over this area. The sputum showed no tubercle bacilli and no red blood cells. The blood examination, blood chemistry and blood pressure were practically normal. The roentgenogram showed a dense shadow at the left base with infiltration of both apexes which was thought to be an old tuberculous process. The temperature rarely rose above 99.6 F. The pulse ranged between 100 and 130. Respirations ranged from 20 to 32. The patient was discharged, Jan. 26, 1919, with a diagnosis of carcinoma of the lung.

She was admitted to another hospital, Feb. 17, 1919, complaining of dyspnea, cough, blood-streaked sputum, soreness of the chest, hoarseness, occasional attacks of vomiting, marked weakness and progressive loss of weight. A diagnosis of pulmonary tuberculosis was made. Physical examination at this time showed marked emaciation with retraction, asymmetry and relative dulness of the left chest. Sputum was negative for tubercle bacilli on five occasions. Several days before her death, March 10, 1919, she developed fluid in the left chest.

Necropsy, performed by Dr. E. T. Bell, revealed a poorly nourished body. There was edema of the feet. Each pleural cavity contained about 2,000 c.c. of clear fluid with fibrinous flakes. There were a few adhesions at both apexes. The left lower lobe was hard and nodular. The cut surface showed closely approximated irregular whitish tumor masses. There were small tumor nodules in the right lower lobe, in the liver, suprarenals and kidneys.

Microscopic sections of the tumor showed irregular glandlike structures lined by very sharply defined large cuboidal and columnar epithelial cells. Numerous desquamated epithelial cells with abundant mucoid material were present in most of the lumina (Fig. 3). The type of cells suggested glandular epithelium. A diagnosis was made of adenocarcinoma of left lung (probably originating from bronchial mucous glands) with metastases into lung, peribronchial and mediastinal lymph nodes, liver, suprarenals and kidneys.

CASE 6 (Necropsy 20-316).—H. O., male, aged 42, was admitted to the surgical service of the University Hospital in January, 1920, with a diagnosis of empyema or malignancy. The illness dated back to August, 1919, when the

Fig. 3.—Section of tumor from Case 5, showing the atypical glandlike structures containing a mucoid secretion and desquamated epithelial cells. The individual cells have sharply defined cell walls and lightly staining cytoplasm. This is an adenocarcinoma, probably originating from the mucous glands.

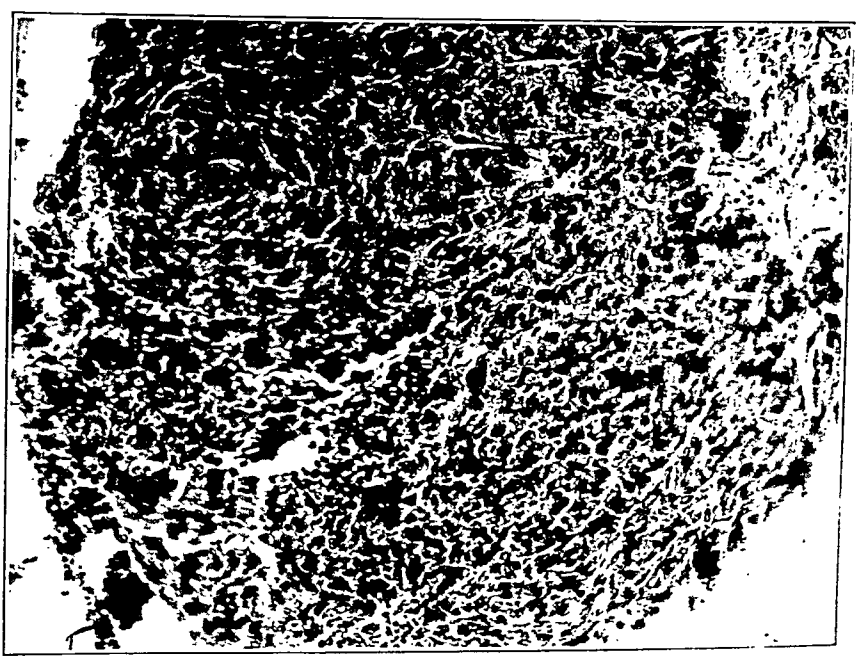

Fig. 4.—Section of tumor from Case 6, showing the closely packed spindle-shaped cells which strongly suggest sarcoma. It is only by careful study of sections from the different organs that the epithelial nature of this tumor can be identified. This tumor may be classed among the medullary carcinomas.

patient became sick suddenly, with chills, severe cough, fever, pain in the left side of the chest, loss of appetite and weakness. He was in bed about a month. The cough was productive, slimy, and on one occasion the sputum was bloody. The diagnosis at the time was bronchopneumonia. Since then he had had occasional attacks of shooting pains over the left chest with shortness of breath and severe coughing spells. The patient thought he had been gradually improving. Physical examination at the hospital revealed a marked lagging of the left side of the chest with a friction rub, anteriorly and posteriorly. There was dulness and hyperresonance over the left apex and left base. The breath sounds were markedly diminished at the apex and absent at the base. The chest was aspirated for fluid but none was obtained. The blood showed a slight leukocytosis. The urine was negative. The roentgenogram showed a dense shadow in the left side of the chest with the heart displaced to the left. The diagnosis was marked thickening of the pleura, probably an unrecognized empyema. He was discharged from the hospital with this diagnosis

He was admitted to the Minneapolis General Hospital, Aug. 8, 1920. He then complained of hoarseness and bloody sputum of about a month's duration. For several months, he had felt that food stuck in his throat. He lost 35 pounds (15.9 kg.) in weight. The roentgenogram at that time showed an opacity of the mediastinum extending through most of the left upper lobe of the lung. The diagnosis was mediastinal sarcoma. He died, Aug. 13, 1920.

Necropsy, performed by Dr. T. H. Sweetser, revealed edema of the feet and ankles. The left lung was very firmly adherent to the chest wall. The pericardium contained a seropurulent exudate. The mediastinum was involved in a tumor mass made up of large white lymph nodes which were matted together. A tumor mass infiltrated the parenchyma around the upper and main branches of the left bronchus. The bronchus was ulcerated in this region. Small masses were scattered through the parenchyma. Numerous large bronchiectatic cavities were scattered throughout the lung. The spleen was enlarged and on section showed a tumor mass, 8.5 by 6.5 cm. There was a tumor, 3 by 4 cm., in the tail of the pancreas.

Microscopically, sections of the spleen showed masses of closely packed, irregular, spindle-shaped tumor cells, containing very little cytoplasm. Many mitotic figures were present. This section suggested sarcoma very strongly (Fig. 4). The peripheral sinuses of a lymph node contained tumor cells, singly and in clumps, having vesicular nuclei and abundant cytoplasm. These cells were fairly characteristic epithelial cells. Section through the bronchus showed the epithelial type of tumor cells infiltrating the stroma. The diagnosis was medullary carcinoma of the left lung with metastases into the mediastinal lymph nodes, pleura, spleen and pancreas. This type of tumor offered great difficulties in differentiating carcinoma from sarcoma. Some observers might include this case under the sarcomas; but careful study of sections from the different organs convinces me that it is an epithelial type of tumor.

CASE 7 (Necropsy 20-363).—L. H., man, aged 46, was admitted to the University Hospital on the neurologic service, Sept. 16, 1920. He was sent in with a diagnosis of left-sided hemiplegia and left-sided pleurisy. The past history was unimportant. He had always been a strong, healthy, hard working farmer. In the fall of 1919, he developed a slight cough and later noticed that the sputum was blood tinged on a number of occasions. His physician told him that the blood probably came from the tonsils. In February, 1920, he developed severe pain in the right thigh and leg, which was treated as sciatica.

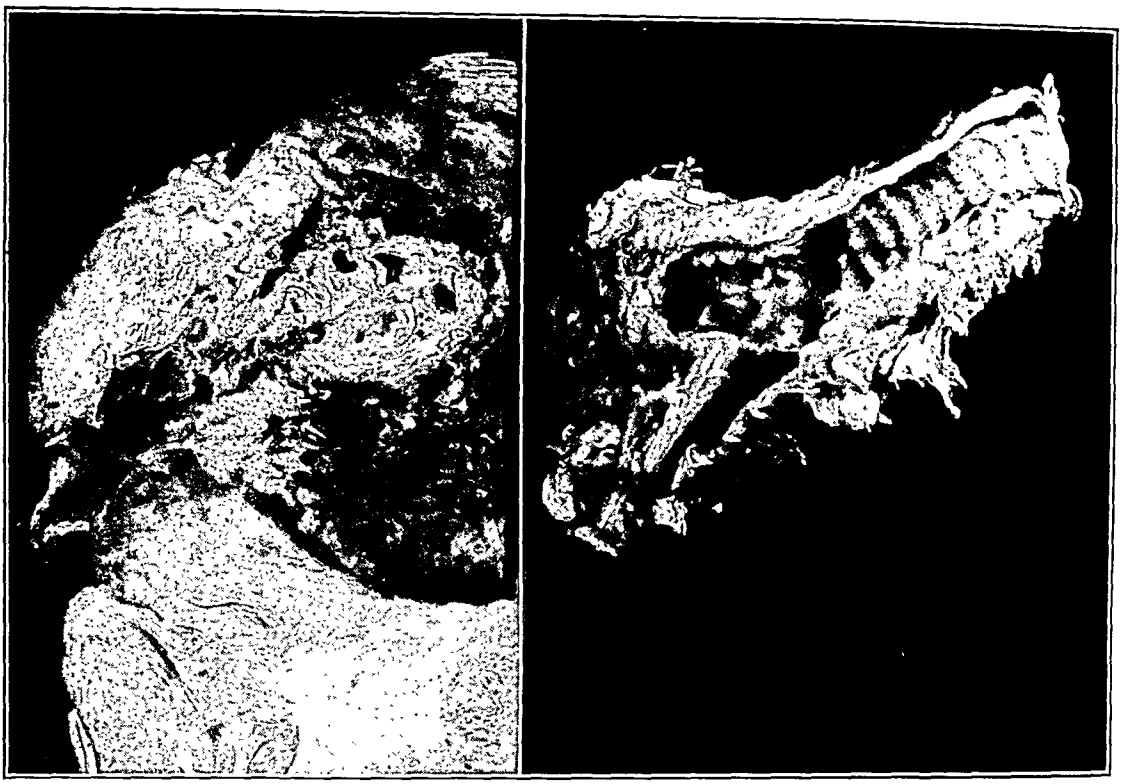

Fig. 5.—Trachea and lung from Case 7, showing the complete occlusion of the left bronchus by the tumor mass, both in the bronchus itself below the tracheal bifurcation and in the cross-section of the lung at the hilum, transversely to the bronchus. The pulmonary artery and vein are seen adjacent to the tumor mass which contains the occluded main bronchus. The lung parenchyma is completely collapsed.

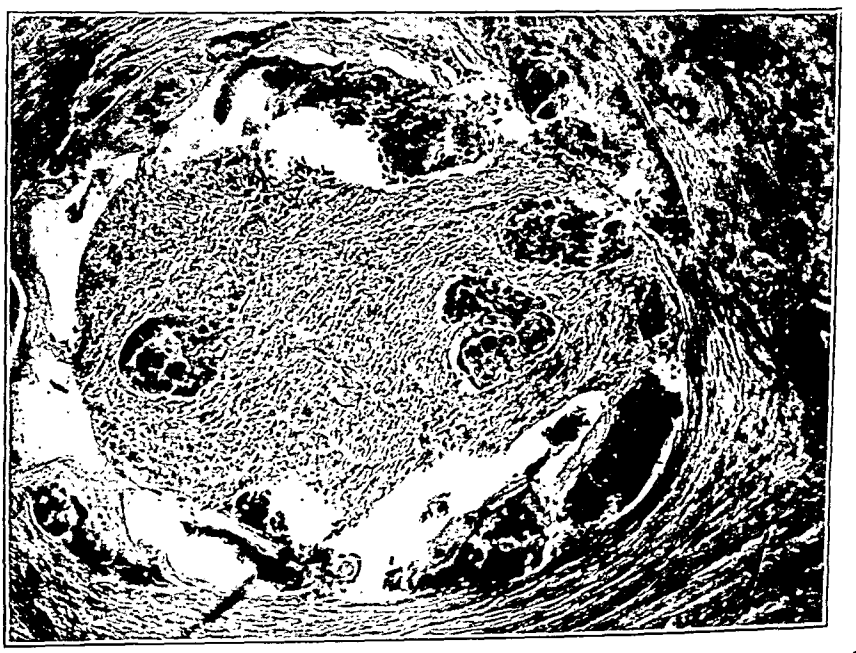

Fig. 6.—Cross-section of a nerve bundle from Case 7, showing invasion of the tumor cells. Compare with Figure 13.

June 2, he suddenly developed a peculiar attack during which everything seemed to turn black before his eyes. He stiffened out, but did not lose consciousness. The next day he went back to work as usual, feeling entirely well. About six weeks later, he first noticed a weakness in his left arm. This increased progressively. Later he noticed a weakness also in his left leg. During the first week of September, he was in bed because of a fever, ranging between 101 and 103 F. From then on he began losing in weight and in strength quite rapidly. He lost 30 pounds (13.5 kg.) in about two months.

Physical examination demonstrated asymmetry of the left chest which was depressed and revealed practically no movement in respiration. It was flat on percussion and the dulness fused with that of the cardiac dulness. The breath sounds were absent. The right cardiac border was displaced to the left to about the midsternal line. There was a flaccid paralysis of the left arm and paresis of the left leg. There was definite atrophy of the muscles of the left chest, shoulder, forearm and hand with a marked loss of tone.

The patient showed marked mental depression, crying a great deal. Examination of the eye grounds revealed a papillo-edema of the third degree but he complained of no headache. Temperature, pulse and respiration were normal. September 22, paracentesis of the left chest was performed; 500 c.c. of clear yellowish fluid was obtained. The fluid contained 430 cells, nearly all lymphocytes, per cubic millimeter. No tubercle bacilli were found. September 27, 250 c.c. of similar fluid was obtained. The blood showed a leukocytosis ranging from 12,000 to 15,000.

A roentgenogram report stated that there was a massive shadow which involved the entire left chest: The heart was displaced to the left. The diagnosis was either a thickened pleura or old empyema or a primary new growth of the pleura.

The patient became gradually weaker and died, Oct. 1, 1920. Because of the history of bloody sputum and the marked asymmetry of the chest, together with the signs of obstruction of the bronchus and the development of hemiplegia associated with signs of intracranial pressure, a clinical diagnosis of primary tumor of the lung with metastasis to the brain was made.

Necropsy, performed by the author, revealed a markedly emaciated body. There was fulness of the neck above the clavicle. The left pleural cavity appeared to be filled by the pericardial sac, which was enormously distended. The left lung was entirely collapsed and retracted, being about the size of an orange. About 800 c.c. of amber fluid was present in this cavity. The pericardial sac contained about 1,500 c.c. of thin dark colored bloody fluid. The pericardium showed no evidences of ruptured blood vessels to explain the blood. The pericardial reflections at the bases of the large vessels were greatly thickened and injected. The posterior third of the right lung showed edema and congestion. The left lung was small and hard. It measured 15 by 12 by 6.5 cm. and weighed 400 gm. It did not crepitate and it sank in water. Numerous small nodules were scattered over the pleura and over the adjacent pericardium. On section of the lung, the lower lobe looked like a triangular fibrous mass. Numerous yellowish nodules were scattered over the cut surface, particularly along the course of the main bronchus. The upper lobe appeared less fibrous and was dark red. Small tumor nodules were also scattered through this lobe. Examination at the hilum revealed an apparent absence of the bronchus. Careful examination of the left bronchus showed that it was completely occluded by a tumor from a point 2.5 cm. below the tracheal bifurcation (Fig. 5). The right



Fig. 7.—Section of tumor in the lung from Case 8. This is a typical example of the common type of adenocarcinoma. The pleomorphic type of columnar cells lining the spaces and the small papillary projections may be noted.

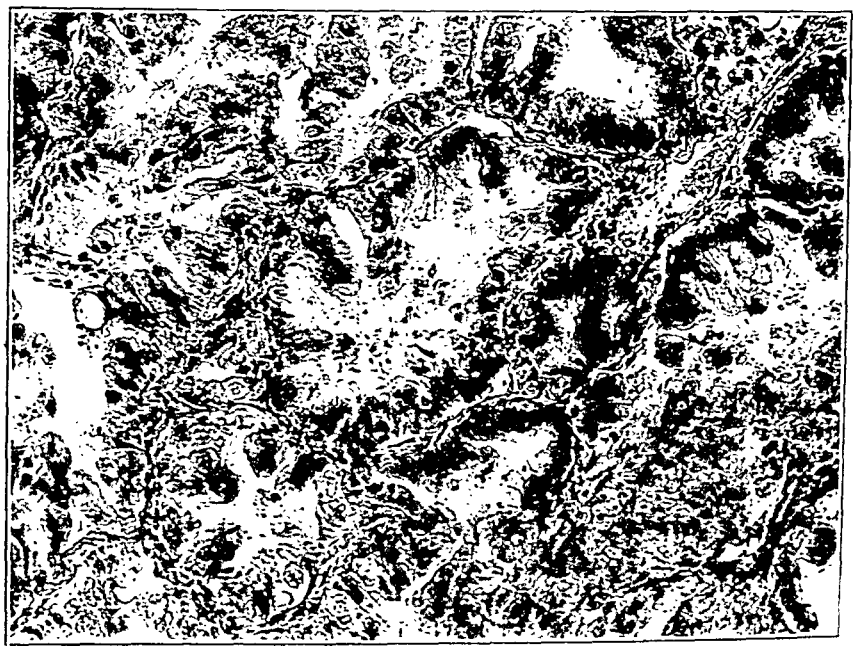

Fig. 8.—Section of lung from Case 9, showing the closely approximated glandlike spaces lined by lightly staining high columnar cells, possessing very sharp cell outlines. The clear spaces within the cells contain a mucoid secretion and some of these look like goblet cells. This is an adenocarcinoma, arising probably from the mucous glands.

suprarenal was large and infiltrated by tumor. In the brain, a tumor mass, 7.5 by 6.5 by 2.5 cm. was found involving the right frontoparietal region. It appeared to involve the dura mater primarily with extension into the cerebral cortex.

Microscopically, the lung showed atypical glandlike structures lined by high columnar cells. The cartilage of the bronchus was invaded by tumor masses. There was marked invasion of the nerve bundles with tumor cells (Fig. 6). The mucosa of the lumen was greatly thickened by papillary projections of infiltrated tumor cells. The heart showed the epicardium infiltrated with small nests of tumor cells and lymphocytes; numerous hemorrhages were scattered throughout the epicardium (this explained the extensive hemopericardium). The adventitia of the pulmonary artery was infiltrated with adenomatous structures and solid masses of tumor cells containing calcified corpora amylacea. These corpora appeared to arise from clumps of necrotic tumor cells. In the brain, the invading tumor mass showed atypical glandlike structures; many cells contained clear spaces filled with mucoid material. The diagnosis was adenocarcinoma of the left bronchus with metastases to the lungs, pericardium, suprarenal and brain.

Case 8 (Necropsy 20-396).—G. E., man, aged 72, was admitted to a hospital, Oct. 17, 1920, complaining of anorexia, vertigo, headache, dimness of vision and some deafness. These symptoms began about Aug. 1, 1920. Up to that time he had been entirely well. Since then he had been losing in weight. Physical examination showed the left pupil to be irregular; and there was a slow nystagmus. There was decreased tactile fremitus and breath sounds over the left lung, posteriorly. There was a firm mass, 8 by 4 cm., in the abdomen just to the left of the umbilicus. The blood showed 13,800 leukocytes with a normal differential count. A clinical diagnosis of pulmonary tuberculosis with abdominal tumor was made. Death occurred, Oct. 30, 1920.

Necropsy, performed by Dr. E. T. Bell, revealed a poorly nourished body. There was edema of the dependent parts. There were numerous strong adhesions at the right apex. Scattered through both lungs were tumor nodules, from 5 to 10 mm. in diameter. There was a large tumor, 5 cm. in diameter, in the middle of the posterior border of the right lung. The cut surface of this was grayish white in color and firm. The bronchi and bronchioles were apparently uninvolved. The liver showed a number of tumor nodules. There was a small nodule in the thyroid.

Microscopically, lung sections showed pleomorphic, cuboidal and columnar cells, lining glandlike spaces (Fig. 7). Many lymphatics were plugged with clumps of tumor cells. Sections of the thyroid and liver showed areas of atypical glandlike structures. The diagnosis was adenocarcinoma of the right lung, with metastases into lungs, liver and thyroid.

Case 9 (Necropsy 21-8).—J. E., woman, aged 61, was admitted to a hospital, Dec. 1, 1920, complaining of sharp, stabbing pain in the chest, emphasized by inspiration. She had been operated on for goiter, November 11, and ten days later had noticed pain in the left side of the chest which was not relieved by strapping. She developed some dyspnea.

Physical examination revealed asymmetry of the chest, with lagging, impaired resonance and a bronchovesicular type of breathing over the left side of the chest. There were tenderness and rigidity of the left upper abdomen. The laboratory examinations were negative except that the urine showed a trace

of albumin and a few waxy and hyaline casts with leukocytes and red blood cells. The roentgenogram showed a definite shadow involving the left hilum. The patient died Jan. 3, 1921. No clinical diagnosis was stated in the record.

Necropsy, performed by Drs. J. S. McCartney and E. T. Bell, revealed a poorly nourished body. Both lungs contained numerous miliary nodules. There was a large firm tumor mass involving the left upper lobe, which was continuous with a smaller mass which involved and almost obstructed the upper left bronchus. The lymph nodes along the left sternocleidomastoid muscle were enlarged. There was a small tumor nodule in the thyroid. The pleura over the seventh, eighth and ninth ribs on the left and the eighth and ninth ribs on the right was elevated, thickened and boggy, being invaded by tumor tissue which had also involved and destroyed the contiguous ribs.

Microscopically, the lung showed irregular glandlike structures lined by irregular layers of high columnar cells (Fig. 8). The cell outlines were very sharp and distinct. Many of the cells contained vacuoles filled with mucoid secretion. Some suggested goblet cells. The tumor tissue resembled very closely secreting grandular tissue. Sections of the tumor masses in the thyroid, lymph nodes, pleura and striated muscles showed solid clumps and cords of epithelial cells separated by masses of connective tissue. There were no adenomatous structures. These areas resembled more a nonkeratinizing squamous-cell carcinoma. The diagnosis was atypical adenocarcinoma, probably arising from mucous glands, with metastases into the lungs, lymph nodes, thyroid, ribs and muscles.

Case 10 (Necropsy 21-147).—S. M., man, aged 48, was admitted to the University Hospital, Jan. 5, 1921, complaining of a severe cough, especially on lying down, dyspnea, weakness and pain in the right chest. He had lost 50 pounds (22.7 kg.) in weight during the past two years, his average weight having been 165 pounds (75 kg.) while now it was 115 pounds (52.2 kg.). He was sent in with a diagnosis of aneurysm(?), bronchiectasis(?), asthma(?). His past history was unimportant up to two years previously, when he began tiring easily and losing in weight. About the middle of the summer of 1920, he developed daily nosebleeds and a cough which soon became associated with severe pain in the right upper chest. About October 1, the nosebleeds stopped and he began to spit up small quantities of blood. Since that time he had been coughing and spitting blood daily. About November 25, he had to quit his work.

The patient was markedly emaciated. The upper right chest lagged and there was increased fremitus with relative dulness over the right apex, both anteriorly and posteriorly. The breath sounds were tubular and bronchovesicular in type over this area and also in the right axilla. The inspiratory tone was rough and grating, followed by a very prolonged expiratory note—cornage. The tone was much like that due to a partial compression of the trachea. During the first few weeks in the hospital, the patient spat up thin tenacious, bloody sputum. Later this became purulent in character. Because of the history of bloody sputum, the pain in the chest, the dulness and tubular breathing (cornage), the absence of crepitant râles and the usual absence of temperature, a tentative diagnosis of primary carcinoma of the lung was made.

The roentgenologic studies, January 11, revealed a nonpulsating mass in the mediastinum extending into the right upper chest. The diagnosis was mediastinal tumor or aneurysm, probably the former. February 17, the stereoscopic

roentgenograms showed an old pleurisy at the right base, with the remains of an interlobar pleurisy of the upper and middle lobes on the right side. The diagnosis was fibroid tuberculosis of the right upper lung. The mass previously described was gone and probably represented an atypical pneumonia or some acute glandular involvement which had subsided. March 14, the roentgenologic diagnosis was bilateral pulmonary tuberculosis, more marked on the right side.

The physical signs, February 15, showed a marked improvement, but the cornage remained. March 10, the physical signs reappeared over the upper

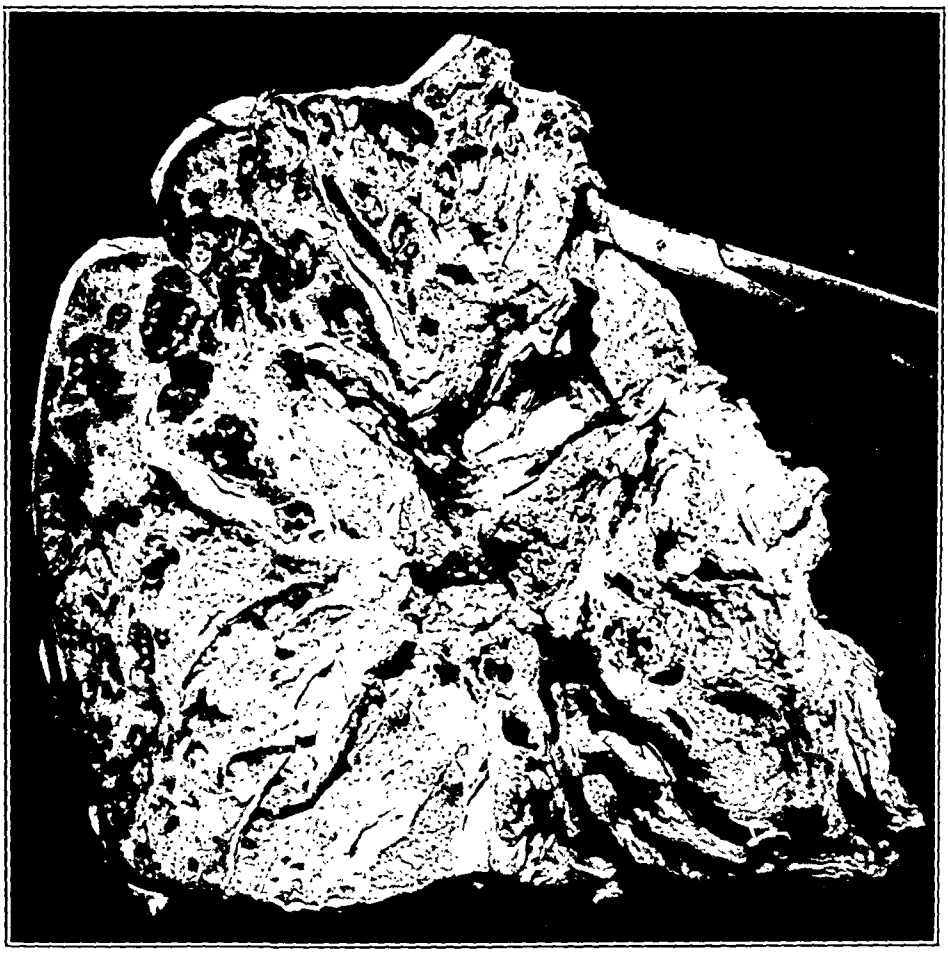

Fig. 9.—Right lung from Case 10, showing irregular carcinomatous masses in the hilum surrounding the bronchus. The peripheral portion of the lung is riddled with bronchiectatic cavities containing precipitated thick pus.

right lobe. The cough became more severe and the sputum more abundant. March 20, the patient developed a severe chill, and within a few hours the temperature rose from normal to 103 F., with a pulse of 130 and respirations, 38. He complained of great pain and discomfort in the chest. Examination at this time revealed a marked lagging of the right chest with evidences of consolidation and persistence of the tubular breathing.

Examination of about twenty specimens of sputum disclosed absence of tubercle bacilli. The urine was negative. The blood was generally negative but on one or two occasions showed a leukocytosis of from 24,000 to 28,000, of which 90 per cent. were polymorphonuclears. The hemoglobin dropped somewhat during the stay in the hospital. The blood Wassermann reaction was negative. Blood chemistry was negative.

His weight dropped to 100 pounds (45.4 kg.) on February 2, a loss of about 15 pounds (6.8 kg.) from the time of admission. This rose again to 115 pounds (52.3 kg.) on March 6, at the time when there was an apparent general improvement in his condition. He died, March 25, 1921.

Necropsy, performed by Dr. H. S. Diehl, revealed a poorly nourished body. The right pleural cavity was obliterated by firm fibrous adhesions. There was a small quantity of thin purulent exudate between the adhesions. The pericardial cavity contained 100 c.c. of thick purulent exudate. The left lung was normal.

Fig. 10.—Section of suprarenal from Case 10, showing clearly the nests of epithelial cells of different sizes containing concentric cornified epithelial centers. The epithelial pearls in this case are unusually typical. All the metastases as well as the primary lesion are true to the type of squamous-cell carcinoma.

The right lung was solid except in the inferior part of the lower lobe. Section through the upper and middle lobes showed numerous bronchiectatic cavities, from 5 mm. to 1.5 cm. in diameter (Fig. 9). These cavities were filled with thick pus. There was a tumor mass in the right bronchus, bulging into and markedly obstructing the lumen. Section of this mass showed it to be of a grayish white color and firm. It extended along the bronchus and for a short distance into the surrounding parenchyma of the upper lobe. The lymph nodes at the hilum of the lung were markedly enlarged, filled with whitish

masses. There were several small tumor nodules in the liver. Both suprarenals were somewhat enlarged and firm and infiltrated with tumor masses. There were tumor nodules throughout both kidneys. Small tumor nodules were scattered throughout the thyroid.

Microscopically, the lung showed fibrosis with areas of necrosis. Scattered throughout the section were masses of tumor cells composed of squamous epithelium showing cornification with the formation of epithelial pearls. Some of the veins appeared to be thrombosed and organized and through them were scattered cords of tumor cells. Section of the suprarenal showed an infiltration of masses of squamous epithelium containing epithelial pearls identical with those found in squamous-cell carcinoma of the skin (Fig. 10). Sections of the liver and thyroid also showed masses of squamous epithelium with epithelial pearls. The diagnosis was squamous-cell carcinoma of the lung arising from the right bronchus with metastases into the peribronchial and mediastinal lymph nodes, liver, suprarenals, kidneys and thyroid.

Case 11 (Necropsy 21-191).—A. F. H., man, aged 63, in February, 1921, developed malaise and a severe cough. Physical examination was negative. Fluoroscopic examination of the chest demonstrated a mass to the right of the heart which on subsequent examinations showed increase in size, filling up the upper right chest cavity. The cough and dyspnea became progressively worse. He developed a constant severe pain in the right arm, associated with edema. The left pupil was dilated; the right contracted. They did not respond to light or accommodation. The neck became large and the veins appeared large and tortuous. The Wassermann reaction was negative. The sputum was negative. The blood was normal. He developed a rise of temperature and died April 30, 1921.

Necropsy, performed by Dr. J. S. McCartney, revealed a well-nourished body. There was marked edema of the right forearm and hand. The right pleural cavity contained 300 c.c. of fluid. The upper right lobe was adherent to the chest wall by dense fibrous adhesions. The entire upper lobe was hard, nodular and grayish white on section. The tumor mass surrounded the bronchus. The mucosa from a point 3 cm. above the bifurcation downward to 5 mm. into the left bronchus and 3 cm. into the right bronchus appeared raised and roughened but apparently not ulcerated. The tumor infiltrated peripherally. The tumor mass extended around the vessels of the neck and the superior vena cava and filled up the space beneath the arch of the aorta. There was also invasion of the pericardiums and a nodule 1 cm. in diameter projected into the pericardial cavity. Tumor nodules were present in the base of the right lobe. The liver and kidneys contained small tumor masses.

Microscopically, the wall of the trachea was densely infiltrated with pleomorphic tumor cells; the cartilage was not invaded. Lung sections showed irregular masses of tumor cells surrounded by connective tissue stroma. The cells were large, pleomorphic with deeply staining nuclei, and were closely packed together (compare Fig. 4, Case 6). The tumor cells in the kidney appeared the same as in the lung. The diagnosis was medullary carcinoma of the right lung, with metastases into the lower lobe, liver, kidneys and pericardium with extension into the posterior mediastinum.

Case 12 (Necropsy 21-216).—J. R. McK., man, aged 60, began ailing in the winter of 1920 but had no definite symptoms. In August, 1920, he developed a cold and in one of the coughing spells he suddenly experienced a sharp pain

in the left side of the chest, posteriorly. This was relieved by morphin. The pain recurred in about a month and from then on persisted in spite of opiates. Later, this pain radiated down into the left arm and at times also into the right arm and upward into the neck. He developed cyanosis of the arms, neck and head. For two months he noticed great difficulty in swallowing food and in speaking. He developed marked dyspnea. A diagnosis of mediastinal tumor, probably sarcoma, was made. He died, May 14, 1921.

Necropsy, performed by Drs. J. S. McCartney and H. B. Sweetser, revealed a fairly well nourished body. There was edema of both feet. The mesenteric lymph nodes were large and firm. There was a nodule in the peritoneum over the lower pole of the left kidney. There was a fusiform enlargement of the third and seventh ribs on the right side. The left pleural cavity contained 500 c.c. of slightly turbid fluid. There were dense adhesions at the apex. The right cavity contained a similar amount of fluid. The left upper lobe was nodular. There was occlusion of the main bronchus by a tumor mass which infiltrated the surrounding parenchyma. Smaller masses were scattered throughout other parts of the lung. They were also present over the pleura and over the external surface of the root of the aorta. The lymph nodes at the bifurcation of the trachea were greatly enlarged. The tumor mass surrounded the root of the aorta and the main branches of the arch. The spleen, suprarenals and kidneys contained small tumor nodules. The lymph nodes in the left side of the neck were enlarged and on section showed tumor masses.

Microscopically, sections of the different organs showed atypical gland-like structures lined by cylindric cells. Many of these contained quantities of mucoid material. The cellular outlines were very sharp and distinct. The diagnosis was adenocarcinoma of the left lung, probably originating from the mucous glands, with metastases into the cervical, peribronchial, mediastinal, mesenteric and retroperitoneal lymph nodes, ribs, kidneys, suprarenals, spleen and extension into the mediastinum.

Case 13 (Necropsy 21-239).—C. M. W., man, aged 46, was well until the summer of 1918, when he first noticed a pain in the back while playing golf. This was diagnosed as rheumatism. Then, suddenly, a deformity developed in the back. In February, 1920, he went to take mud-baths. He had pain in both legs and felt very weak. He then went to a chiropractor under whose treatment he became much worse. At Christmas time, 1920, he went to Rochester where a diagnosis of Pott's disease was made. He was admitted to a tuberculosis sanatorium, March 21, 1921, after having had a variable experience with physicians and hospitals. Physical examination demonstrated large lymph nodes in the left inguinal region and a knuckle deformity in the region of the twelfth dorsal vertebra. He had large decubitus ulcers. Examination of the chest revealed nothing abnormal. The diagnosis of Pott's disease was made. April 30, physical examination revealed dulness in the right chest with breath sounds distant at this point. Paracentesis was performed but no fluid was obtained. He died, June 2, 1921.

Necropsy, performed by Dr. J. S. McCartney, revealed a poorly nourished body. There were large decubitus ulcers. There was a caseous nodule in the lower lobe of the left lung, 5 mm. in diameter. There was a definite thickening of the left primary bronchus with invasion of the adjacent portions of the secondary bronchi. There was no definite ulceration. There were large tumor

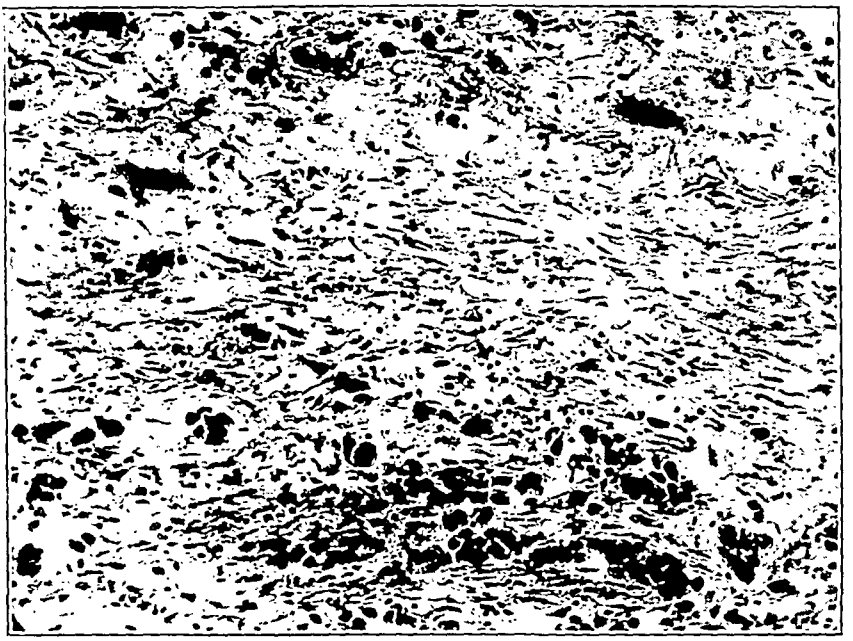

Fig. 11.—Section of lymph node from Case 13, showing clearly the few small nests of epithelial cells scattered through the connective tissue stroma. This is an example of a scirrhous carcinoma.

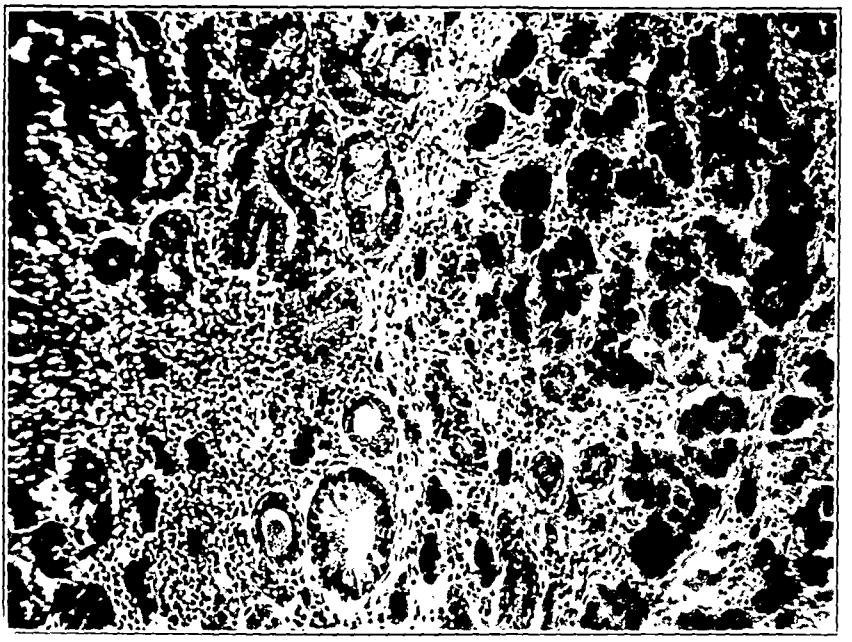

Fig. 12.—Section through wall of bronchus in region of primary nodule from Case 13 (same case as Fig. 11), showing the fairly normal mucous gland ducts and acini next to structures in which there is a breaking away of the epithelial cells into the surrounding stroma, which at the same time assume a deeper cytoplasmic stain. At the margins of the section, frank carcinomatous tissue can be seen. A study of sections from this case convinces me of the origin of this tumor from the mucous glands.

nodules in the right kidney and in the periaortic lymph nodes. There was an irregular tumor mass which invaded the second and third lumbar vertebrae. This extended throughout the bodies into the spinal canal, pressing on the cauda equina. There were tumor masses around the twelfth dorsal and first, second, third and fourth lumbar spinal roots.

Microscopically, sections of the lymph nodes showed dense masses of fibrous connective tissue with very small groups and cords of epithelial tumor cells (Fig. 11). There were a few giant cells of the Langhans' type. Section of the bronchus showed the epithelium intact in most areas. The mucous glands showed transitions from the normal appearance to a marked distortion with breaking through of the epithelial cells into the surrounding stroma (Fig. 12). The retroperitoneal tissue showed a marked infiltration of tumor cells with invasion of nerve bundles (Fig. 13). Sections of the spinal cord showed extensive degeneration, a transverse myelitis. There was a perivascular infiltration with peculiar large pleomorphic cells, possessing abundant bluish

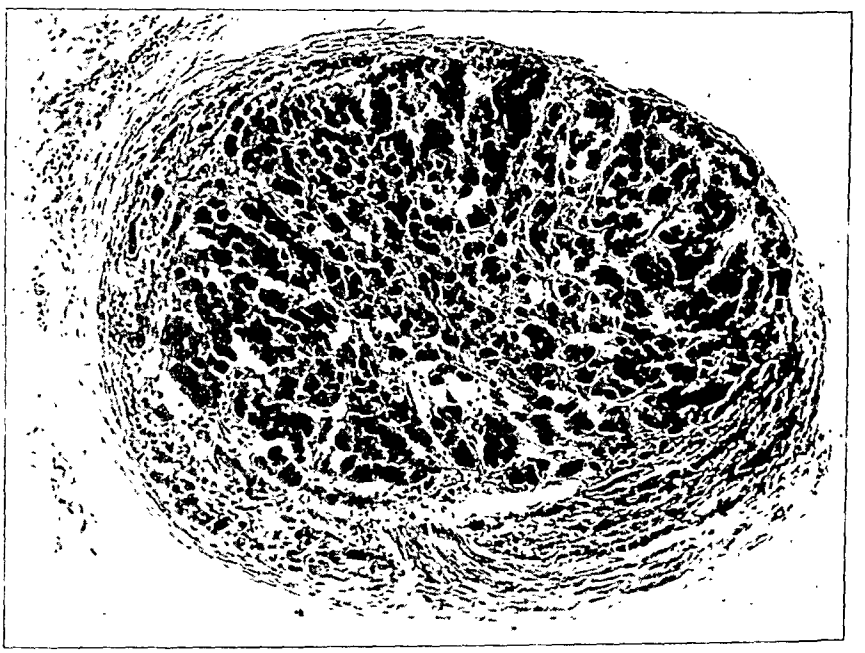

Fig. 13.—Section through a nerve bundle from the retroperitoneal tissue of Case 13. The extensive invasion of the carcinomatous tissue and the almost complete destruction of the nerve fibers may be noted. Compare with Figure 6.

cytoplasm and deep staining nuclei. These cells were also diffusely scattered through the degenerated parts of the cord. The diagnosis was scirrhous carcinoma of the left lung, originating from the mucous glands of the bronchus, with metastases into the lumbar lymph nodes, vertebrae, dura mater and left kidney.

COMMENT

In a brief résumé of this relatively small series of thirteen cases, it will be seen that the findings bear out in a striking manner the observations in the literature as to the characteristics and peculiarities of the disease. As to age, the youngest of the series of patients was

42 and the oldest 72, with an average of about 55 years. Ten were men and three were women. The right lung was primarily involved five times; the left, eight. This is not entirely in accord with the statistics, which give a predominance of right-sided involvement. The shortest duration of symptoms was six weeks and the longest three years, the average about seven months. A severe cough was present in nine cases and bloody sputum in five. Pain in the chest was a prominent symptom in six cases, while one patient (Case 3) complained of pain and distress in the stomach. There was a marked loss of weight in seven cases and there was more or less dyspnea in about 50 per cent. of the series. A pleural effusion was present in six instances and a pericardial effusion in two. In none of these was the fluid at all characteristic except perhaps in Case 10 in which the pericardial fluid was sanguinous and very abundant. Tuberculosis was definitely associated with the disease in only one case and periods of fever in four cases. On five occasions, the chest was grossly asymmetrical. Massive bronchiectasis occurred twice. Metastases were present in every case; and in two instances (Cases 7 and 13), the metastases produced the predominating symptoms. The organs involved together with the frequency of their involvement may be listed thus:

Lungs	10
Lymph nodes	9
Peribronchial and mediastinal	7
Cervical	2
Abdominal	2
Kidney	5
Suprarenal	4
Liver	4
Bones	4
Ribs	3
Vertebrae	1
Thyroid	3
Brain	2
Spleen	2
Superior vena cava	2
Pericardium	2
Pancreas	1

Of the types of carcinoma encountered, adenocarcinoma leads, with seven cases; acanthoma and medullary carcinoma, of each two cases; carcinoma simplex and scirrhous carcinoma, of each one case.

Correct clinical diagnoses were made in only three instances (Cases 5, 7 and 10). In one of these (Case 5), a diagnosis of tuberculosis was made both clinically and by roentgenogram after a diagnosis of pulmonary carcinoma had been made in another hospital at a previous admission. Necropsy proved that the first diagnosis was correct. In Case 8 a clinical diagnosis of pulmonary tuberculosis and abdominal tumor was made. This abdominal tumor proved at necropsy to be nothing more than a deformity of the vertebral column in the lumbar region, which was easily palpable through the thin abdominal

wall. One case was diagnosed as mediastinal sarcoma and another case as Pott's disease. The latter case is of especial interest because the metastases produced the sole and only symptoms and because of the prolonged course of the disease, three years. The roentgenologic studies did not assist in a correct diagnosis in a single case and in several cases they were definitely misleading.

One patient (Case 2) complained of a severe neuritic pain in the right sacro-iliac joint. Similarly, another patient (Case 7) was treated for right-sided sciatica. It is very likely that both patients developed these symptoms from the pressure of tumor metastases on the spinal cord or nerves, though the exact source of the pain was not identified at the postmortem examination.

In Cases 6 and 7, the heart was displaced markedly to the left, toward the affected side. This is sometimes the result of adhesions pulling the pericardium; but in carcinoma of the lung, the mechanism of this displacement is quite different. The occlusion of the bronchus by the tumor mass prevents the air entering into the distal lung parenchyma and, with the gradual absorption of the gases resulting in a negative pressure on the affected side, the relatively increased pressure on the nonaffected side gradually pushes the mediastinum over. In Case 10, the heart was pushed over entirely into the left pleural cavity because the left lung had contracted to the size of an orange and only a small quantity of fluid was present to compensate for the loss of lung mass. The development of this negative pressure on the affected side also explains the asymmetrical chest, with the definite lagging and immobility. The cardiac displacement and the asymmetry of the chest are very important findings for diagnosis.

In Case 6, the patient was apparently improving at one stage of his illness after he had been sick in bed for one month with what was thought to be bronchopneumonia. This probably was an attack due to extensive bronchiectasis, resulting from the bronchial stenosis. Another patient (Case 10) had several similar attacks though of shorter duration. In both of these cases, extensive bronchiectases were found at the postmortem examinations. The very confusing roentgenologic reports in Case 10 can readily be explained by a filling up and emptying of the many diffuse bronchiectatic cavities (Fig. 9).

Cases 6 and 10 had periods of remission with general improvement of the conditions of the patient, subjectively as well as objectively. There is a common impression that loss of weight and weakness are progressive in cancer. This is not always true, however, as the patient in Case 10 regained 15 pounds (6.8 kg.) in weight, as well as his strength, at one time while in the hospital. This fact led some to believe that the patient was on the road to recovery and that the tentative diagnosis of carcinoma of the lung was erroneous.

Case 13 is of interest from the standpoint of diagnosis. Some of the best men in the country had failed to diagnose the case correctly. The completely negative chest findings were very misleading, as they precluded the possibility of locating the primary lesion in the lungs. The metastases to the vertebrae must have occurred rather early, while the primary tumor itself grew very slowly. This scirrhous type of carcinoma is often very slow growing. A study of the microscopic sections in this case reveals the histogenesis of the cancer from the epithelium of the bronchial mucous glands. All gradations from the normal glands of the bronchi to completely unrestricted, anarchistic growth of tumor cells can be traced out in the sections.

SUMMARY

1. Carcinoma of the lung is a rare disease; but its rarity is exaggerated by the failure to recognize many of those cases that do occur. It is only at necropsy that many are revealed.

2. Carcinoma of the lung may be diagnosed clinically. However, a diangosis is possible only when careful and detailed histories are taken and accurate physical examinations are made. Laboratory and roentgenologic studies may also be helpful. All facts obtained must be carefully correlated. Statistics show that complete examinations of the patients have, in the hands of certain practitioners, resulted in correct clinical diagnosis in from 80 to 95 per cent. of the cases.

3. This disease is apparently increasing in frequency, especially during the past few years. Chronic inflammations, such as tuberculosis, are possible factors in the etiology of the disease. The last great influenza epidemic is perhaps another factor. The average incidence has been about 2 per 1,000 necropsies. In our series, during the past few years the increase has been about fourfold. The disease has formed about 2 per cent. of the cases of cancer encountered at the postmortem studies.

4. Most pulmonary carcinomas develop from the bronchial epithelium. Some originate from the bronchial mucous glands and only a few arise from the alveolar epithelial cells.

5. Epithelial metaplasia is relatively common in bronchial mucous membranes. This may explain the origin of the comparatively large number of squamous-cell carcinomas in this region.

6. Metastases are common in this disease and often are numerous. The frequency of metastases to the brain, suprarenals and thyroid is very striking.

7. Pain in the chest, cough and dyspnea occur early. Bloody sputum, cornage and asymmetry of the chest are important findings in these cases. Laboratory procedures and roentgenologic studies have thus far not proved of very great assistance in the differential diagnosis.

8. Bronchiectasis is an important complication, especially since it may give misleading physical and roentgenologic findings during the course of the disease.

9. The study of the thirteen cases reported in this paper shows the importance of assuming a new attitude toward this disease with reference to its prevalence and diagnosability. The two cases encountered at the University Hospital during the past year were both recognized clinically; but ten of the remaining eleven of this series were not diagnosed correctly. This fact points strongly to the necessity of greater familiarity with the signs, symptoms and pathology of the disease.[49]

---

49. After this article had been sent to the publishers, another case of carcinoma of the lung came to necropsy at the University Hospital. This case had been studied for many months at the hospital, and had been diagnosed as carcinoma of the lung before this article had been completed; but since no cases that had not come to necropsy were included in the present study this case was not discussed. Within a period of less than one year, three patients with carcinoma of the lung have been admitted to the University Hospital and their cases have been diagnosed. The last case will be reported later.

COMPARATIVE RESULTS OF THE LIGATION OF THE HEPATIC ARTERY IN ANIMALS

ITS APPLICATION TO MAN *

MOSES BEHREND, M.D., H. E. RADASCH, M.D.
PHILADELPHIA

AND

AMMON G. KERSHNER, M.D.
NORRISTOWN, PA.

In a preliminary report [1] the reason for this study was pointed out to be an injury of the hepatic artery sustained by a boy, aged 12 years, who was run over by a wagon, the wheels passing over the epigastric region. He had all the symptoms of an internal hemorrhage. At operation, the hepatic artery was found to be severed. Both ends of the artery were tied. The boy did well until the tenth day, when he developed a slight jaundice, accompanied by vomiting. He died on the fourteenth day, of symptoms resembling acute yellow atrophy of the liver. A postmortem examination was refused. Our desire to duplicate this injury in animals has developed these experiments.

In our preliminary studies, rabbits were used exclusively; but in our later experiments, dogs, cats, guinea-pigs and rabbits were employed. These animals may be divided into the carnivorous and herbivorous types. We found the former particularly resistant to the effects of the ligation of the hepatic artery, while the latter succumbed in every instance. This difference in their susceptibility to the ligation may be due to changes in the metabolism in these two types of animals. This problem is occupying our attention at the present time and the results will be reported in the near future.

However, the anatomic variations may be a sufficient reason alone to cause such a tremendous difference in the mortality rate of the different animals. To arrive at a definite conclusion concerning the difference in the ability of these animals to resist the ligation performed in a similar manner, a study of the comparative anatomy of the four animals used was deemed essential (Figs. 1, 2, 3 and 4). It will be

---

* Research work performed at the laboratory of pathology, Philadelphia General Hospital, Dr. E. H. Krumbhaar, Director; Baugh Institute of Anatomy, Jefferson Medical College, Dr. J. Parsons Schaeffer, Director. Clinical work performed at the Jewish and Mount Sinai hospitals.

1. Behrend, Moses: Surg. Gynec. & Obst. **31**:182 (Aug.) 1920.

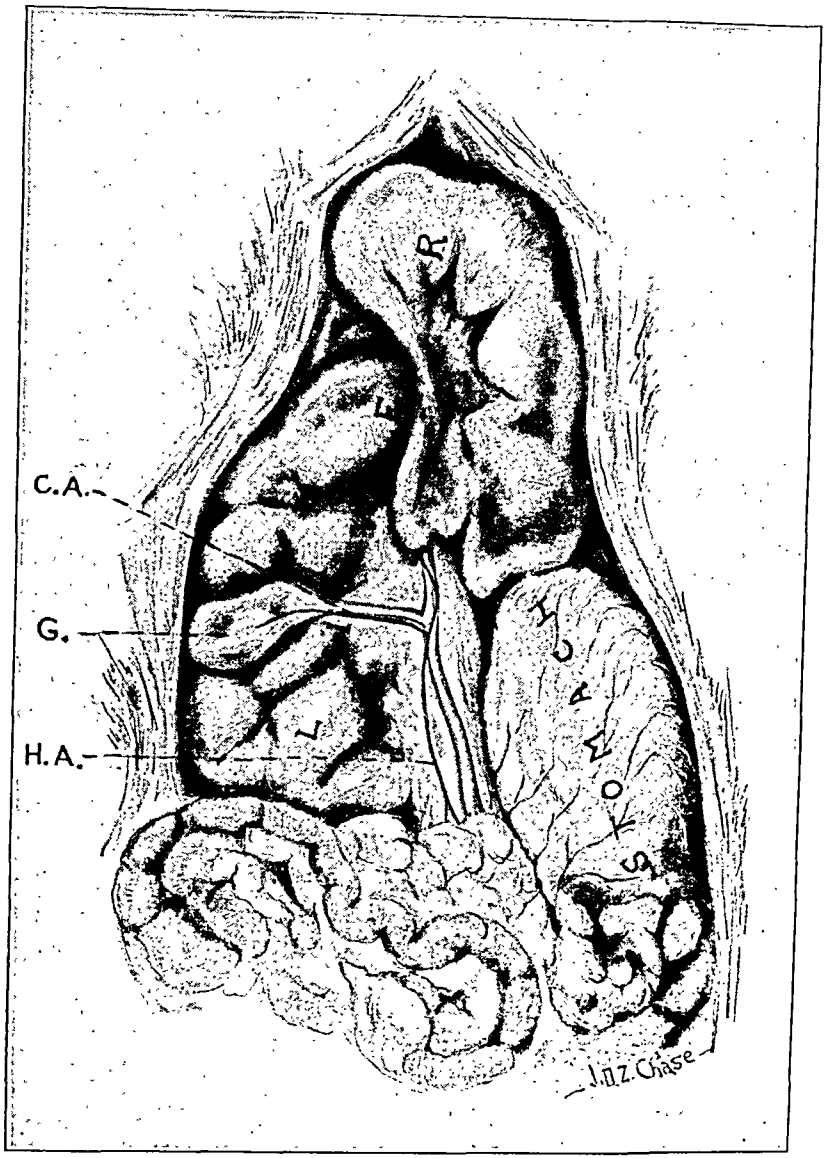

Fig. 1.—Hepatic artery of the guinea-pig. The hepatic artery is simply a line running over the gastrohepatic omentum: *C. A.*, cystic artery; *G.*, gallbladder and *H. A.*, hepatic artery.

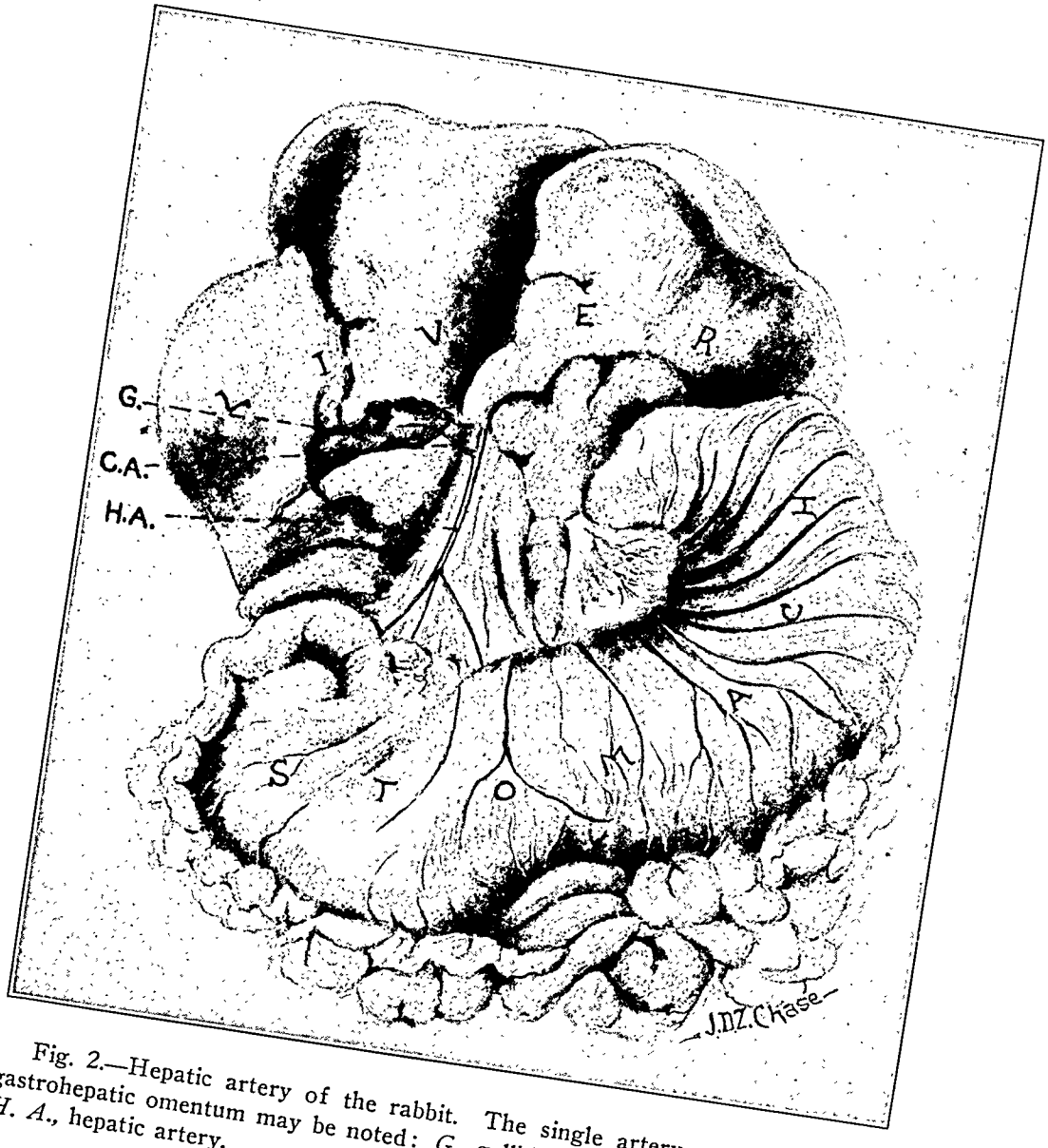

Fig. 2.—Hepatic artery of the rabbit. The single artery running over the gastrohepatic omentum may be noted: *G.*, gallbladder; *C. A.*, cystic artery, and *H. A.*, hepatic artery.

readily seen that the anastomosis of blood vessels in the cat and dog is rather intimate when compared to that of the rabbit and guinea-pig.

The anatomy of the hepatic artery and its variations in man were reported in previous papers, as well as the variations of the bile ducts.[2] These studies have shown, however, that in certain cases in which there is no anastomosis at all of the hepatic artery before it enters the liver, and in which the hepatic artery is derived from the celiac axis only, there is considerable danger in ligating the sole source of

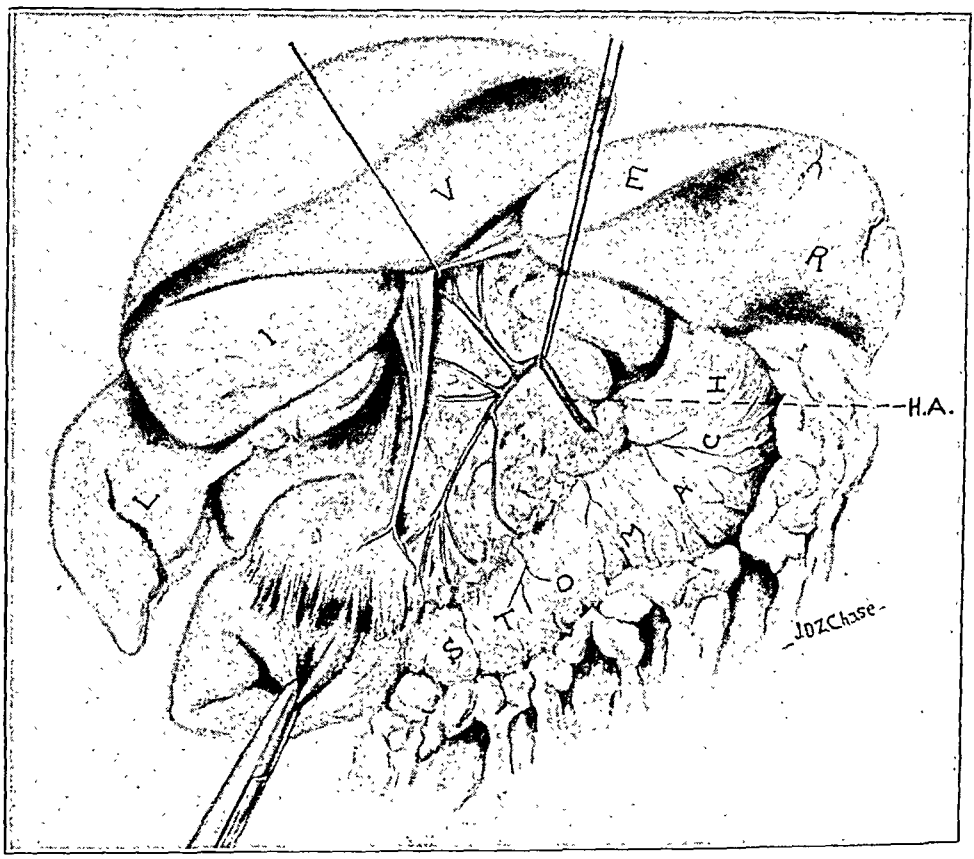

Fig. 3.—Hepatic artery of the dog. The artery runs behind the lesser omentum. The intimate anastomosis accounts for the resistance of the dog to its ligation: *H. A.*, hepatic artery.

arterial blood to the liver. This is especially true since the hepatic artery is an end artery (Figs. 5 and 6). When an accessory hepatic artery is derived from the superior mesenteric or the left gastric artery there is probably less danger to the patient, but there is no question that accidental ligation of the main vessel even in such a case exposes the patient to danger of necrosis of the liver.

2. Behrend, M.: Failure of Surgery on Extrahepatic Biliary Passages, J. A. M. A. **73**:892 (Sept. 20) 1919; Improved Technic for Removal of Gall-bladder, J. A. M. A. **75**:222 (July 24) 1920.

Our experiments have shown that if even a branch of the hepatic artery is tied there is a microscopic change in the liver cells (Fig. 7). This change in the liver cells may still be seen weeks after the experiment has been performed. Figure 8 illustrates the microscopic changes in the liver cells of a dog, killed 113 days after the ligation. The fact that degeneration of liver cells may be detected easily by the microscope even weeks afterward may explain the cause

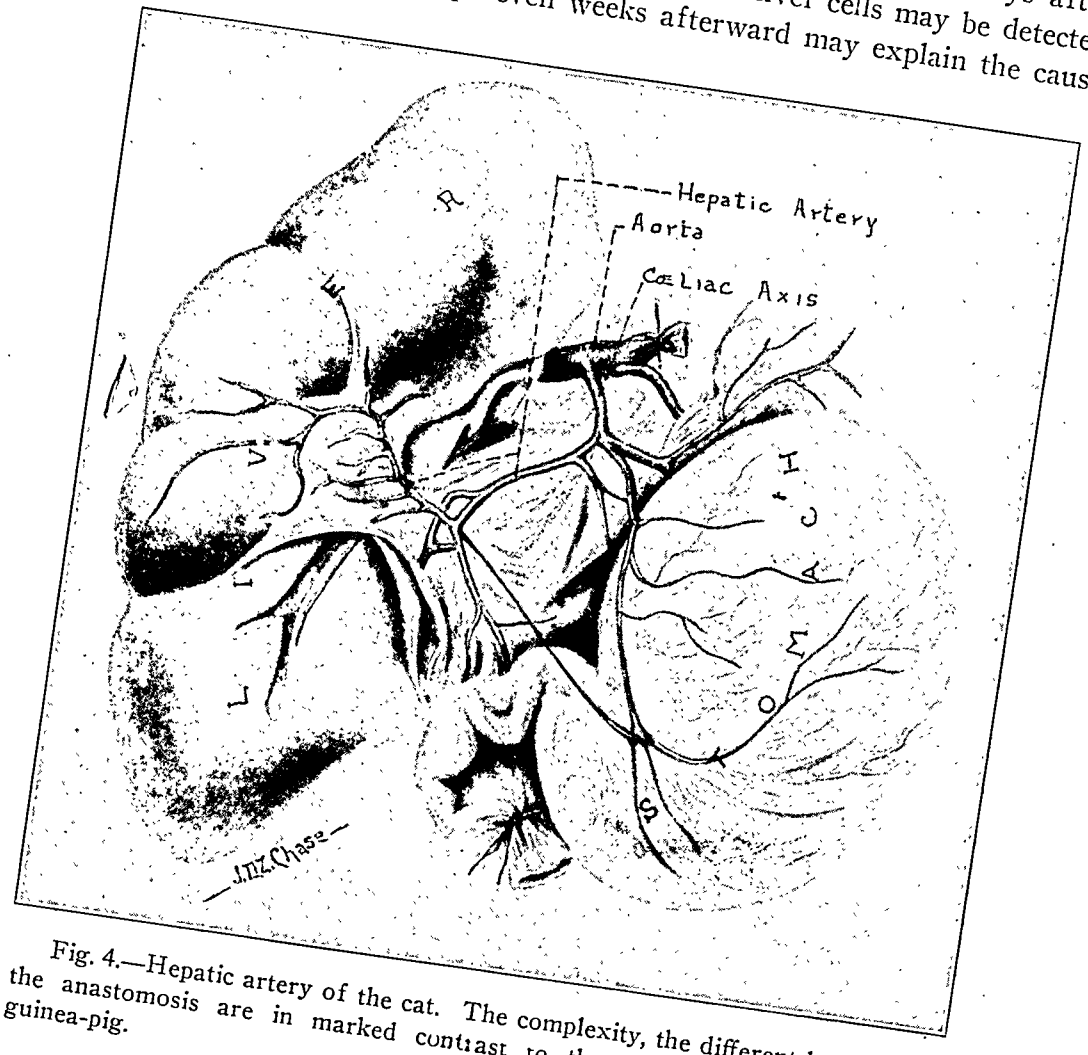

Fig. 4.—Hepatic artery of the cat. The complexity, the different branches and the anastomosis are in marked contrast to those found in the rabbit and guinea-pig.

of death of a patient who was admitted to the Mount Sinai Hospital a few months ago. About two years before admission, a cholecystectomy had been performed. The patient was brought to the hospital in an unconscious condition. Her face was tinged slightly yellow. A diagnosis of acute yellow atrophy of the liver was made, which was confirmed at necropsy. Unfortunately, before a minute dissection of the liver could be performed, the specimen was destroyed An oppor-

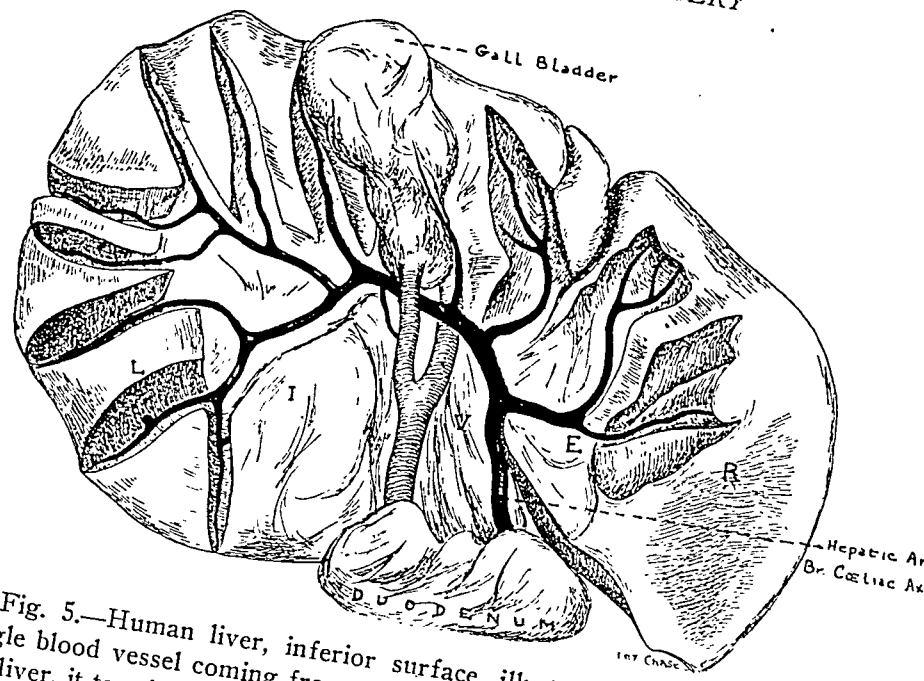

Fig. 5.—Human liver, inferior surface, illustrating the hepatic artery as a single blood vessel coming from the celiac axis. After the hepatic artery enters the liver, it terminates as an end artery without anastomosis.

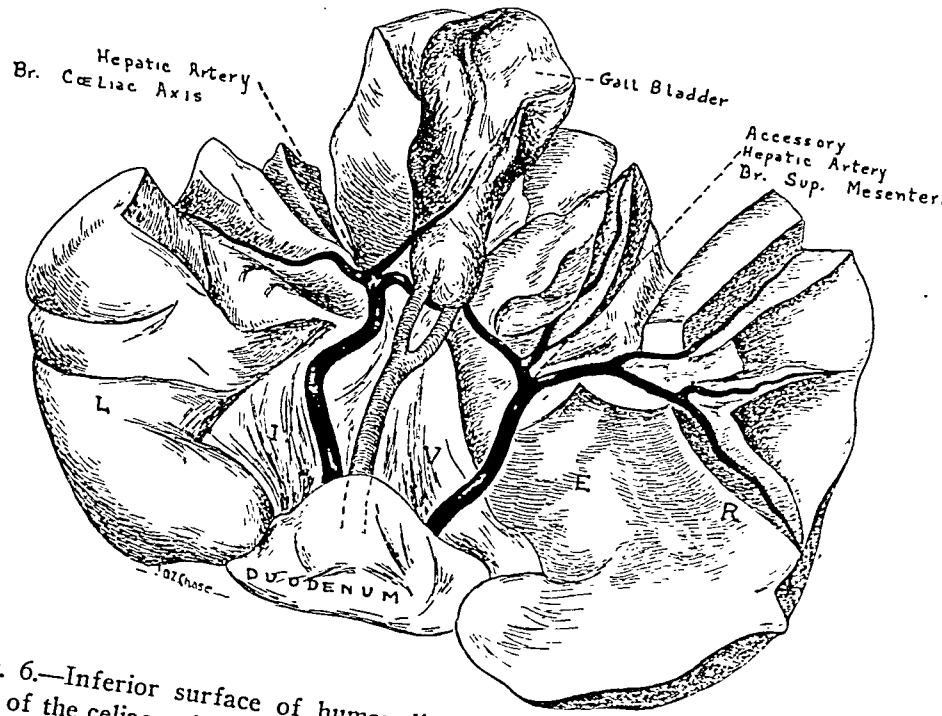

Fig. 6.—Inferior surface of human liver, showing the hepatic artery as a branch of the celiac axis; an accessory hepatic artery as a branch of the superior mesenteric artery. As in Figure 5, the liver has been dissected to show that the hepatic artery is an end artery.

tunity seldom encountered to prove our contention that ligation of the hepatic artery is fraught with the greatest danger was lost. Microscopically, the liver showed a fatty degeneration typical of acute yellow atrophy of the liver.

TABLE 1.—SITES OF LIGATION AND RESULTS OBTAINED AFTER THE OPERATION ON THE HEPATIC ARTERY OF THE RABBIT

Rabbit	Site of Ligation	Death Following Operation	Death by Chloroform	Liver Changes	
				Gross	Microscopic
1	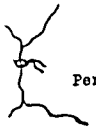	18 hours		No pathologic condition noted	(No sections made)
2	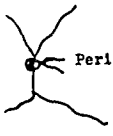	4 days		Liver shows several white areas, where tissue appears cheesy in consistency extending deeply into liver	Large area of necrosis, with peripheral zone of cellular infiltration; marked dilatation of central vein of lobules; hepatic arterioles difficult to find, and show hyalinization
3	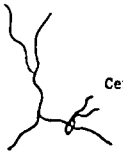		20 days	No liver changes except dense adhesions involving omentum, mesentery and under surface of liver	(No sections made)
4		5 days		Massive necrosis in area similar to Rabbit 2	(No sections made)
5	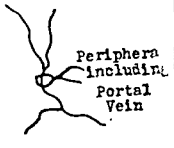	17 hours		Anemic, pale and flabby	Necrosis of cells near central part of lobules; cells stained poorly; collapse of cells
6		Died during operation		Normal	(No sections made)

As has been stated, the site of ligation of the hepatic artery and its branches is important in developing the conclusions of our study. Let us divide the steps of a ligation into the central and peripheral, or a combination of the two (Tables 1 to 6). By a central ligation is meant the ligation of the hepatic artery just as it leaves the celiac axis. By a peripheral ligation is meant the ligation of the hepatic artery

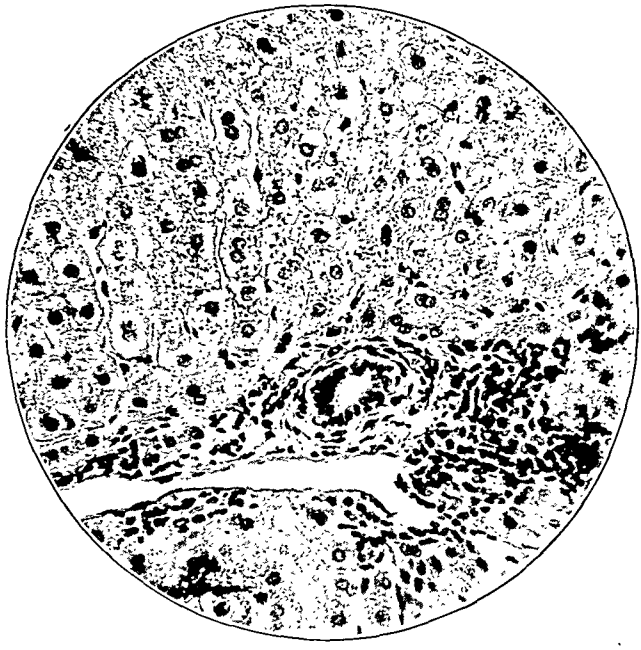

Fig. 7.—Degeneration of the nuclei as a result of ligation of a branch of the hepatic artery (Kershner).

Fig. 8.—Liver of dog killed 133 days after ligation of the hepatic artery; nuclei dissolved (Kershner).

close to the liver in the folds of the gastrohepatic omentum. In a central ligation, on account of the anastomosis with the gastroduodenal and the right gastric arteries, death of the animal is not certain. This fact is confirmed in man by Chiari.[3] Rabbits and guinea-pigs may even resist a ligation of this character; but if a successful

TABLE 2.—SITES OF LIGATION AND RESULTS OBTAINED AFTER THE OPERATION ON THE HEPATIC ARTERY OF THE RABBIT

Rabbit	Site of Ligation	Death Following Operation	Death by Chloroform	Liver Changes	
				Gross	Microscopic
7		19 hours		No gross change noted	(No sections made)
8		18 hours		No color change	(No sections made)
9		23 hours		Massive necrosis in all but one lobe; this lobe had blood supply intact	Massive necrosis at one end of section; very little reaction against same; liver cells stained poorly; portal veins thrombosed and hugely dilated
10	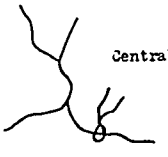		50 days	Extensive adhesions; several large cheesy masses encased in liver substance; color, paler than normal	Hepatic cells stained poorly; much degeneration; central veins show dilatation
11			18 days	Adhesions	(No sections made)
12		36 hours		Characteristic necrosis, especially of lobe to which gallbladder is attached; few adhesions found	Areas of necrosis, with zones of reaction against same; dilatation of portal venules

peripheral ligation is performed in herbivorous animals, such as rabbits and guinea-pigs, all die in from seventeen hours to three or four days. This confirms our experiments reported in our preliminary note. Dogs are most resistant and live in spite of the ligations, which fact coincides

3. Chiari: Quoted by Baruch, Beitr. z. klin. Chir. **45**:502, 1915.

with the work of Whipple.[4] Kehr and Narath [5] state that fatal necrosis in rabbits is common because all the branches of the hepatic artery are easy to ligate, while in dogs it is very different because of numerous anastomoses and sources of blood supply from the diaphragm. In his dissections of the liver of the dog, Dr. Benjamin Lipshutz, working in our laboratory, found no arterial supply going to the liver from any source except through the agency of the hepatic artery as illustrated in Figure 3. Dogs and cats will show the effects of a ligation for several days afterward. They are not so playful and there is an appreciable loss in weight. Still they recover from the effects of the operation.

Fig. 9.—Massive necrosis of liver of cat after every vessel had been ligated that entered the liver (Kershner).

In only one cat were we able to cause death by ligation of every vessel running into the liver. This included also the ligation of the vessels of the diaphragm, which, according to some authorities, keep the animals alive after the hepatic artery has been ligated. The microscopic study of the liver of this animal showed it to be in a state of complete necrosis (Fig. 9).

The most important deductions from our studies will be their application to the human being. Naturally the experimental operation cannot be performed in man; but from our studies in the anomalies of the hepatic artery in the anatomic laboratory and at the operating table, we are convinced that the hepatic artery instead of the cystic

4. Whipple: Bull. Johns Hopkins Hosp. **20**:281, 1909.
5. Kehr and Narath: Deutsch. Ztschr. f. Chir. **135**:305 (March) 1916.

artery may easily be ligated. It is our opinion that some unexplainable deaths are due to necrosis of the liver, caused by the ligation of the hepatic artery, especially in those cases in which there is no anastomosis before the hepatic artery enters the liver and in which there is no accessory hepatic artery.

TABLE 3.—SITES OF LIGATION AND RESULTS OBTAINED AFTER THE OPERATION ON THE HEPATIC ARTERY OF THE GUINEA-PIG

Guinea-Pig	Site of Ligation	Death Following Operation	Death by Chloroform	Liver Changes	
				Gross	Microscopic
1	 Peripheral	12 hours		Liver soft and flabby, irregular white areas	Areas of focal necrosis, hydropic degeneration; few vessels contained coagulum
2	Peripheral	2½ days		Liver shows irregular white areas of necrosis, cheesy and friable in consistency	Typical pale infarct, zone of reaction surrounding same; portal veins dilated; rest of tissue shows congestion and cloudy swelling
3	Central	3½ days		Some adhesions, one lobe pale and anemic; small white areas of necrosis in rest of lobes; distinct anemic infarct, reaction against same being poor	Thrombus in portal vein; fatty infiltration and hydropic degeneration
4	 Central	9 days		Very few adhesions; no gross changes	Cloudy swelling predominating; hydropic degeneration near central vein area; sinusoids greatly injected in places
5	Peripheral	5 days		Irregular areas of necrosis marked; adhesions profuse on under surface of liver	No area of necrosis included in section; cells generally show hydropic degeneration; arterioles difficult to find

The deliberate ligation of the hepatic artery in man has been performed by others, and it illustrates our contention that death results following the operation. Baruch,[6] in referring to an hepatic aneurysm

6. Baruch: Beitr. z. klin. Chir. **45**:502-512, 1915.

states that the ligation of the hepatic artery is tragic on account of its lethal effect. He also reports eight deliberate ligations of the hepatic artery. Tuffier,[7] in operating on what was supposedly a hydatid cyst, opened an aneurysm of the hepatic artery. The bleeding that followed was so profuse that he was compelled to ligate the hepatic artery proximal to the aneurysmal sac. Death followed within four days. There was

Fig. 10.—Necrosis and degeneration of liver cells and cloudy swelling (Radasch).

no liver necrosis; but death was thought to be due to hepatic insufficiency. Kehr's [8] patient is the only one, whose case is reported, that lived after the ligation of the hepatic artery. He states that after ligation of the hepatic artery above and below the aneurysm, the latter bled pro-

7. Tuffier: Presse méd. **17**:153, 1909; Allessadria: Bol. Acad. de med. de Roma, **32**:63-67, 1906.

8. Kehr: München. med. Wchnschr. **1**:1861-1867, 1903.

fusely after it was opened, necessitating a tight tamponade. Kehr concluded from this observation that ligation of the hepatic artery was the proper treatment. Baruch dissents from this opinion on account of the occurrence of experimental necrosis following the ligation of the hepatic artery in animals.

TABLE 4.—SITES OF LIGATION AND RESULTS OBTAINED AFTER OPERATION ON THE HEPATIC ARTERY OF THE DOG

Dog	Site of Ligation	Death Following Operation	Death by Chloroform	Liver Changes	
				Gross	Microscopic
1	 Central		33 days	Paling of portion of under surface of liver	(No sections made)
2	Central		38 days	No changes noted except for adhesions in gastrohepatic region	Portal veins dilated; organizing thrombi in some vessels; liver cells swollen and fine vacuoles present; yellow, amorphous pigment present
3	 Central		35 days	None noted, except dense adhesions about gastrohepatic region	(No sections taken)
4	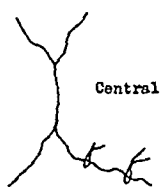 Central	4 days from sepsis		Appears normal except for few small areas of gray coloration	Capsule normal; central zone of each lobule shows destruction of liver cells and replacement by cellular detritus red blood cells, and amorphous pigment; large bacilli scattered throughout detritus
5	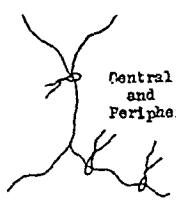 Central and Peripheral		113 days	Liver of normal consistency and color; very few adhesions	Liver cells are swollen, pale, and filled with fine vacuoles; nucleus absent in many instances; yellowish, amorphous pigment in abundance; portal veins not dilated

Narath has collected all the articles on ligation of the hepatic artery, particularly the work of von Haberer. The data disclose that the vitality of the liver depends on the site of the ligation. The more centrally the ligature is placed, the greater the chance of recovery. The results also show that ligation of a branch of the hepatic artery in most cases resulted in the death of the animal from hepatic necrosis.

If death does not follow, the necrotic area is encapsulated. All this is in conformity with our own experimental work. In addition, we found that one or two animals survived because of adhesions of the liver to the diaphragm and of the great omentum to the parietal peritoneum, forming, so to speak, an accessory anastomosis similar to that following a

Fig. 11.—Same as Figure 10, but showing a lesser degree of degeneration (Radasch).

Talma operation for cirrhosis of the liver. The occurrence was so striking that our attention was directed to this phenomenon.

TECHNIC

Prior to operation all animals were shaved, tincture of iodin was applied to the skin, and then the field of operation was surrounded with a sterile sheet. The instruments were boiled between operations, when more than one was per-

formed on the same day. The hands were thoroughly scrubbed. Gloves were not used. Ether anesthesia was used altogether, except in the case of cats, when chloroform was employed to induce stupor only, after which ether was given. Chloroform was tried on dogs, but they were so susceptible to it

TABLE 5.—SITES OF LIGATION AND RESULTS OBTAINED AFTER OPERATION ON THE HEPATIC ARTERY OF THE CAT

Cat	Site of Ligation	Death Following Operation	Death by Chloroform	Liver Changes	
				Gross	Microscopic
1			23 days	No changes noted	(No sections made)
2	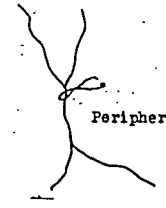		23 days	No changes noted	(No sections made)
3	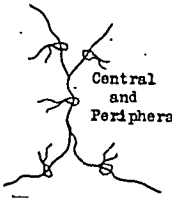		20 days	Liver shows no gross change; gallbladder thickened and tough; adhesions	Hydropic degeneration of liver cells; immediate subcapsular region is congested; some central veins contain coagulum; portal veins dilated
4			19 days	Dense adhesions in region of gallbladder; no other changes noted	Capsule normal; central veins congested; liver cells generally show hydropic degeneration, but are best preserved in subcapsular areas
5	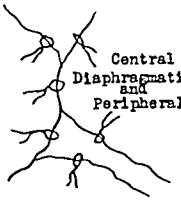	48 hours		Soft, succulent, and paler in some areas than in others	Universal necrosis

that we were compelled to use ether exclusively. Silk was used in all ligation; the wounds were closed with catgut and silk sutures. A pad was always placed at the border of the ribs posteriorly so as to render the structures around the foramen of Winslow nearer to the field of operation.

MORPHOLOGIC AND HISTOLOGIC REPORT

The following morphologic and histologic report by one of us (Dr. Radasch) describes the results of our experimental work mentioned in the preliminary note. In the main, these descriptions were confirmed in our final experiments.

The necropsy of one of the rabbits that died between four and five days after ligation showed that the liver had undergone serious changes. Between

Fig. 12.—Parenchymatous degeneration; portal canals unusually prominent (Radasch).

the right lobe and the diaphragm, there was a layer of light yellow material that seemed to be necrotic liver tissue. The left lobe of the liver was mottled with reddish and whitish patches. The cardiac part of the stomach also showed a yellowish patch.

The surface of sections showed a thick layer of granular material which under the higher power was seen to consist of many leukocytes (chiefly polymorphonuclear cells and some lymphocytes) and necrotic substance. In

some areas, the cells predominated and in others the granular necrotic material was predominant. Separating this necrotic layer from the liver cells was the scarcely perceptible capsule of the liver. In places the capsule seemed absent and the liver cells underneath had undergone a degenerative change in varying degrees; some were entirely destroyed, while others were very nearly so, or showed only early changes. Many areas of focal necrosis were noticeable and

TABLE 6.—SITES OF LIGATION AND RESULTS OBTAINED AFTER OPERATION ON THE HEPATIC ARTERY OF THE CAT

Cat	Site of Ligation	Death Following Operation	Death by Chloroform	Liver Changes	
				Gross	Microscopic
6		18 hours		Pale, soft and flabby	Total necrosis
7			14 days	Many adhesions; two lobes of liver a degree paler than normal	Portal veins injected; central veins distended; hydropic degeneration of liver cells; no massive necrosis
8	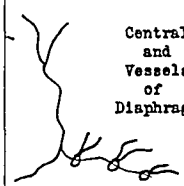		63 days	Many adhesions; liver considerably paler than normal; no change in consistency	Irregular focal necrosis in central parts of lobules; hydropic degeneration of cells toward periphery of lobule; some enlargement of all the vessels
9			40 days	Liver much paler than normal; gallbladder apparently normal; inferior surface of liver shows small, pale, raised areas	Cells swollen and pale; certain areas contain irregular, clear vacuoles; nuclei generally pale, and some entirely missing (hydropic degeneration)
10			27 days	Adhesions but no other changes	(No sections made)

some of these were quite large and chiefly subcapsular. The hepatic cells in general exhibited parenchymatous changes, especially the nuclei. The latter responded very poorly to the stain. Some of the larger biliary ducts showed changes. The epithelium was partly desquamated and the remainder showed cloudy swellings (Figs. 10 and 11).

Another section of liver from a rabbit that lived five days after the operation showed a somewhat thickened capsule and the cells showed proliferation on the deeper surface. The hepatic cells in general showed parenchymatous degeneration to a marked degree. There were a few small necrotic areas, and small groups of round cells were noted. The cell chains were very much attenuated in places, and the cells showed atrophy. The portal canals were unusually prominent (Fig. 12).

Fig. 13.—Most extensive changes. The liver in fresh state showed many small holes (Radasch).

Another section exhibited the most extensive changes so far studied. Even in the fresh state (at removal), the liver showed many small cavities that communicated with one another. In section this condition was emphasized and gave the appearance of having been riddled with shot. The same section represented the thin margin of the liver, and with the unaided eye the numerous small spaces left by the removal of the necrotic tissue gave characteristic appearance to the section. The capsule showed very little thickening, and the mesothelium for the most part was absent. Most of the remaining hepatic epithelium showed marked parenchymatous degeneration. A few cells gave

a good nuclear stain, but these cells were mostly small and atrophic with enlarged sinusoids between them. The portal canals all stood out prominently and in some of these areas the branches of the bile ducts showed desquamation of the epithelium. In the interlobular tissue of the portal canals an unusually large number of thin walled blood vessels of considerable caliber may be noted (Fig. 14).

Conclusions.—(Dr. Radasch).—The lesion resembles somewhat the changes that occur in acute yellow atrophy of the liver. The diminution in size is not so marked, but the mottling is apparent.

While the microscopic changes in acute yellow atrophy usually show fatty degeneration and the presence of fat droplets and hyaline material, in the section studied there seemed to be an absence of fatty material of all kinds. The cells have undergone a rapid parenchymatous and necrotic change so that the architecture is destroyed and there remains only an amorphous mass of granular necrotic material. The term "necrobiosis" seems well chosen to express the condition, as a "living death" seems to be exemplified in the shrinking and degenerating cells.

This result of ligation of the artery seems to indicate an acute anemia of the liver. The hepatic vessel is far too small a vessel to act as the nutrient vessel of the organ, that is the function of supplying the liver with food.

The liver is an important oxidizing organ. The various toxins formed by the putrefaction of proteins in the intestines are brought to the liver by the portal vein, and through the action of the liver cells, these substances are oxidized and rendered harmless substances that the kidneys later eliminate. If the liver cells are deprived of this and other oxygen, they cannot perform these chemical changes, and also degenerate as the result of the presence of these toxins and the inability to repair their own wear and tear.

It would appear that any injury which prevents the proper amount of oxygenated blood from getting into the liver gives rise to an acute anemia that is followed by general necrobiosis of the hepatic tissue.

GENERAL CONCLUSIONS

Ligation of the hepatic artery is dangerous at all times. This has been proved in the few cases reported in which a deliberate ligation in man was one of necessity on account of aneurysm or other pathologic conditions. (Only one patient recovered [Kehr's].)

There is a varying susceptibility of animals to the effects of ligation of the hepatic artery. This depends on the point of ligation to a certain extent, namely, whether the ligation is made centrally or peripherally.

Rabbits and guinea-pigs always succumb to successful peripheral ligation. Dogs and cats resist the ligation and continue to live indefinitely in spite of a combination of a peripheral and central ligation.

An important point to be kept in mind is that histologically we have found degeneration of the liver cells in all animals in which ligation was performed.

INGUINAL HERNIA: A STUDY OF THE PRINCIPLES INVOLVED IN THE SURGICAL TREATMENT

P. W. HARRISON, M.D.
BAHREIN, PERSIA

There is no lack of recent literature on the subject of inguinal hernia, and no lack of variety in the operations suggested for its relief. All manner of technical procedures have been described; and varying degrees of success have been reported. These articles, however, have dealt with details. There has been a surprising absence of any effort to submit the principles governing all the accepted operative procedures to a really adequate analysis and criticism.

ANATOMY

The abdomen forms a closed sac, and its walls are exposed to a slight constant intra-abdominal pressure. In addition to this, whenever the trunk is in the upright position, the lower part of the abdominal wall must withstand a supplementary pressure approximately equal to that of a column of water 25 cm. high. If observations at operation can be trusted, these factors are trifles compared with the strain put on the wall in coughing, heavy lifting, etc. Under these circumstances, the intra-abdominal pressure, for a brief period, must reach a much higher figure.

PATHOLOGY

In certain places, the abdominal wall sometimes proves unequal to the strain put on it, and a hernia develops. The most frequent site of such a failure is the internal abdominal ring, and next to it, Hesselbach's triangle. Femoral hernia is much less common, and occasionally we see a hernia through Petit's triangle, and in many other places.

It is a matter of some importance to find out which of the structures forming the abdominal wall is at fault when it gives way. The problem is most easily studied in direct hernia, in which the beginning of the process is not infrequently observed. I have had occasion within the last year to operate in two very early cases of direct hernia. In these two patients, there was no noticeable bulge on coughing or straining. Following heavy lifting, the patient complained of pain in the region of the external ring, which recurred on exertion, and which in the few days since the onset had been growing worse. A tentative diagnosis of beginning direct hernia proved correct in each case, and although at operation the muscular structures of the abdominal wall seemed to be quite normal in development and arrangement, the transversalis fascia was found to be giving way over an area, in one

case, the size of a dime, and in the other case, nearly the size of a nickel. The area of defective transversalis fascia was sharply defined and the bulge had reached the size of half a small hickory-nut in one case, and somewhat less than that in the other. There was no abnormality in the other structures of the abdominal wall. The other early cases that I have seen have been farther advanced, with a definite sac, and with the structures of the wall correspondingly displaced. Whether the fascia in question was congenitally weak or whether the strain of heavy work had injured a normal structure, it was not possible to say. There could be no doubt, however, that the essential factor in the pathology of the condition was a change in the transversalis fascia, and it was equally evident that the lesion was sharply limited, the remaining part of the transversalis fascia, exposed by the operation, showing no tendency to give way.

The observations mentioned above contribute nothing new to our ideas regarding direct hernia, for it is generally supposed that a direct hernia results from an insufficiency of the transversalis fascia. No such unanimity, however, obtains as to the cause of indirect hernia. Here there is much confusion in present day surgical thought. It is most unfortunate that we have had our attention centered on the vaginal process and its theoretical persistence after the descent of the testicle. Such an abnormally persistent processus vaginalis is assumed in the case of every man that later develops an indirect hernia. When we consider the dozens and hundreds of men who first show a hernia at 50 and 60, after their active life is over, the hypothesis becomes improbable, to say the least. However, the main objection to the theory is that, even if true, it gives us no useful guidance. In and of itself the persistence of a more or less elongated, narrow processus vaginalis would not predispose to a future hernia, if all the elements of strength present in the wall of the abdomen were also present in the wall of the process. Indeed, if its wall were of equal strength, it would enjoy a slight mechanical advantage, for the abdominal contents are not absolutely fluid, and its narrow mouth and elongated shape would serve to shield it somewhat. If such an extension of the abdominal wall is more inclined to give way than the wall generally, it must be because it lacks some element of strength that the main wall possesses, and the important thing is to find out what that lack is.

We have had no opportunity to observe the earliest stages of an indirect hernia. The most recent have been some weeks or months old, and have shown a distinct bulge at the external ring. Possibly in its very early stages, an indirect hernia does not cause so much pain as a direct hernia, and therefore is not so likely to come to operation. In these early cases of indirect hernia, there is already a widening of the inguinal canal and a displacement of the muscular and fascial struc-

tures that bound it. The muscles, however, appear to be normal in size and strength. The floor is formed by a conjoined tendon, apparently normal in strength and thickness, as are the internal oblique muscle and the pillars of the external ring. We frequently see an indirect hernia coming through an abdominal wall, much superior in the strength of its musculature and the snugness of its external ring to many walls that show no hernia. The impression is very strong that the displacement of the muscular and fascial structures accompanying an indirect hernia is the effect of the hernia and in no sense its cause.

This conviction is much strengthened by a consideration of the further development of such a hernia. A Bedouin boy fell from his camel, and, following the accident, an inguinal hernia began to develop. Six months later, he reported to the Mason Memorial Hospital with the largest hernia that has ever come under my observation. It reached below the knees. Such a history, however, is exceedingly rare. Usually the pressure-resisting capacity of the abdominal wall at the internal ring does not drop to zero or anywhere near it. It barely sinks under the necessary 100 per cent. and a hernia develops, the growth of which proceeds very slowly and in most cases stops altogether after a time. In ninety-three hernias in which this matter was investigated, fifty-seven had ceased to enlarge after a longer or shorter period, and there had been no increase in size since. This is a country where the influence of trusses may be disregarded. The external ring in some of these cases was very large, the hernia recurring immediately after reduction, in other words, the laws of fluid pressure must have been practically 100 per cent. effective. Indeed, the same conditions are found in those infrequent hernias that are partially or wholly filled with fluid, and in which the laws of hydrostatic pressure must be quite unmodified.

The weakness of the wall in such a hernia has become compensated and the hernia withstands the intra-abdominal pressure adequately. It does so, however, with no help from the muscular abdominal wall. A hernia of long standing shows two layers, which apparently are the effective agents in withstanding the intra-abdominal pressure: an external fascial layer that is continuous with the external oblique fascia, and an inner layer, intimately connected with the peritoneal sac itself. The scattered fibers of the cremaster muscle cannot be considered as rendering any significant help.

The natural conclusion is that the cause of an indirect hernia, as of a direct hernia, is the failure of the transversalis fascia to withstand the intra-abdominal pressure to which it is subjected. It is not surprising that of all the transversalis fascia the weakest spot is the place where its continuity was interrupted in fetal life to allow the descent of the testicle. There is no reason to assume the persistence of an open

processus vaginalis in every case, in the absence of any demonstration of such a phenomenon. The descent of the testicle must certainly leave the fascia weak in this locality; and this would seem sufficient to explain the fact that here it most frequently gives way.

A second conclusion is that once the transversalis fascia gives way, the muscular abdominal wall offers no effective obstacle to the growth of the hernia, and that compensation is eventually established with no help from that wall, but by a hypertrophy of derivatives of the transversalis and external oblique fascias.

If hernias occur because of the failure of the transversalis fascia to withstand the pressure to which it is subjected, the natural method of operative correction would seem to be the repair and strengthening of that fascia. The surgical attack on the problem, however, has developed along an entirely different line. Previous to the appearance of Halsted's article in 1889 and of Bassini's article in 1890, it could hardly be said that any coordinating idea existed. Those two articles laid down the main principles of procedure that have been followed ever since; first, that after removal of the hernial sac, its recurrence is to be prevented by a repair of the muscular and fascial structures of the abdominal wall; and second, that the principle feature of this repair is a solid attachment between the internal oblique muscle and the conjoined tendon on the one side, and Poupart's ligament on the other. Around this central idea, every imaginable technical variation has been advocated, each constituting an enormous improvement in the mind of its sponsor, and proving to be no improvement at all in the hands of anybody else. The cord has been brought out below, in its normal position close to the pubic bone, and it has been transplanted and brought out higher up. When thus transplanted it may be placed between the internal and external oblique muscles, or it may be placed subcutaneously. The medial leaf of the external oblique fascia has been sutured above Poupart's ligament, and it has been sutured below it. The cord has been brought out through a single opening, and it has been separated into veins and vas, and brought out through two smaller openings. Postures for the patient have been studied whereby the hiatus between the conjoined tendon and Poupart's ligament can be reduced. An untried technical rearrangement of the available material can scarcely be imagined, but always under the guidance of the two principles that Halsted and Bassini laid down.

It is unlikely that anything is to be gained by further efforts along this line. The two principles introduced by Halsted and Bassini have done, for the surgery of inguinal hernia, all that they are capable of doing. There is, indeed, a rather surprising lack of precise information as to what this procedure does accomplish. Any one who has had occasion to operate on recurrent hernias knows that it does not accom-

plish what is usually supposed. We do not produce an abdominal wall where a close apposition of the internal oblique muscle and the conjoined tendon on the one side and Poupart's ligament on the other prevent the recurrence of a hernia. What we produce is a mass of scar tissue, densely adherent on the external side to Poupart's ligament, on the internal side to the internal oblique muscle and the conjoined tendon, and below to the pubic bone. Through this plate of scar tissue, the spermatic cord makes it exit, either higher up or lower down, according to the type of operation performed.

Compared with conditions before the articles of Halsted and Bassini appeared, results have been very good. Compared with any permissible ideals of the present, they are bad. They are certainly not nearly so good as we have supposed. Johns Hopkins Hospital estimates its recurrences in the neighborhood of 10 per cent., and the Massachusetts General Hospital reports 8 per cent. of recurrences in cases followed and examined. Series of private cases from the upper classes, with no investigation of end-results, are not to be weighed against these figures. It is not likely that improved technic has much to offer us over what these two hospitals report. Apparently these figures represent the limit of development of this method of attacking this problem. A detailed analysis of published results would undoubtedly show that present methods are adequate for the hernias of children, reasonably satisfactory for small indirect hernias, and very unsatisfactory for direct hernias, and for those cases with large external rings and atrophied conjoined tendons.

The experience of the late war is interesting in this connection. It seems regrettable that the unique opportunity for a thorough study of the whole hernia problem was not realized. We shall hardly have such an opportunity again. However, one war-time conclusion is worthy of note from the standpoint of this article; namely, that the important point in the operative procedure is a high dissection of the sac, the treatment of the abdominal musculature being a comparatively minor matter.

TECHNIC EMPLOYED AT BAHREIN

Before proceeding to describe the operation for hernia that has been developed in the Mason Memorial Hospital, a word more must be added regarding the anatomy of a hernia. A hernia of some years' standing shows a well developed fascial layer, intimately associated with the peritoneal sac, and a second layer springing from the external oblique fascia. These layers, however, are not absolutely uniform in strength and thickness. Over the neck of the sac, they are thickened and more or less fused. Apparently, owing to this local hypertrophy, the hernial sac, however large it may become, always retains its comparatively narrow neck. Even when the external ring is large and the contents

slide in and out with no obstruction, there is little tendency for the neck to enlarge. Lower down, the fascia gradually thins out and coincidentally the neck widens into the diameter of the sac.

In the operation that we use in Bahrein for inguinal hernia an effort is made to repair and strengthen the transversalis fascia. Local anesthesia is used (procain and epinephrin), except in small children. Silk is used for suture material. The skin is cleaned with alcohol, painted with iodin, and varnished. A layer of sterile gauze is laid on the varnish, and the usual incision is made through it and carried well down over the pubic bone to make possible a good exposure there. I have found that with this technic, there is no need of fearing the filthy condition of the skin in this region. The skin of the Arab is dark, and iodin appears to cause no trouble. The external oblique fascia is split in the direction of its fibers, up from the external ring as far as seems indicated. The peritoneum is grasped high up, next to the internal oblique muscle, and its isolation is carried to the level of the pubic bone. At this point, the sac is opened, the intestines are replaced in the abdomen if necessary, and the neck of the sac is reinjected with anesthetic solution from within, as high up as desired. The neck of the sac is then completely isolated from surrounding structures, and the sac is amputated. No effort is made to dissect the sac out and remove it, except in unusual cases. I have left the sac in this manner many times, and have yet to see a hydrocele or any other untoward result. The dissection of the neck of the sac is then carried very high up. There is a lack of precision on this point, in textbooks and in special articles as well. Every one emphasizes the importance of a high dissection of the neck of a hernial sac, but no one gives definite standards or landmarks. A dissection which does not demonstrate the deep epigastric vessels, I regard as insufficient. Frequently, they must be pushed back, if the dissection is to be carried beyond the limits of the sac to normal peritoneum and transversalis fascia. This dissection constitutes the first part of the operation.

The second part of the operation, namely the repair, is begun by dividing the neck of the sac into an upper and a lower leaf, by means of two lateral divisions. The lines of division are carried down on each side, well to the limit of the dissection. The lower leaf is then carried up inside the abdomen for an inch (2.5 cm.), or more, to the limit of the operative field, pulled fairly taut, and sutured into place. The upper leaf is carried down, overlapping the lower, and sutured to the lowest point that the dissection makes available. The overlap should amount to at least an inch (2.5 cm.), or an inch and a half (3.8 cm.). Care must be exercised or the deep epigastric vessels may be injured. It is the hope that normal peritoneum and transversalis fascia from above and below will be overlapped by this procedure,

and in many cases, I am certain that they are. When the external ring was too large to permit this, the leaves of thickened fascia and peritoneum of the neck of the sac have been overlapped from above and below, leaving a doubled layer which stands ready to withstand the intra-abdominal pressure.

Following this, the cremaster is sutured under the internal oblique muscle and the conjoined tendon, a procedure described by Dr. Halsted in 1893. I believe that the cremaster muscle so placed is a help in retaining the sutured parts in position until solid healing has occurred. In some cases after the peritoneum with its transversalis fascia has been overlapped from above and below and sutured in place, the patient is able by coughing and straining to force omentum out of the angles of the overlap. After suturing the cremaster muscle under the internal oblique muscle and conjoined tendon, the repair is beautifully snug and efficient. I make it a rule to test the operative repair at this point by having the patient cough violently and strain. I believe that the test is of considerable value. The cremaster muscle may not contribute anything of great value to the permanent repair of the hernia. If the ideas outlined above are correct, its contribution in any case should not be needed. Its effectiveness, however, in holding the repaired parts in place and making the repair completely effective during the days immediately following the operation, no one can doubt who has tested it in this way.

This practically completes the operation. The external oblique muscle is repaired, restoring the external ring, which I endeavor to leave more or less normal in size. I do not try to make it unusually snug, being careful to avoid any pressure on the cord at this point. The operation has already traumatized the vessels of the cord, and every effort is made to reduce further insults to a minimum. The subcutaneous tissue is united and the skin sutured.

Direct hernia I regard as presenting a distinct problem from that of an indirect hernia described above. The fascia of the neck of a direct hernia shows little tendency to hypertrophy, and the vascular layer of fat which lies between it and the peritoneal sac leads nearly always to a fairly complete destruction of the transversalis fascia before the sac is isolated and disposed of. Thus the operation leaves a considerable defect in the transversalis fascia; and under such circumstances, a recurrence is to be anticipated. The commonly used operations for indirect hernia have given better results than those used in direct hernias for the dissection does not destroy the transversalis fascia, and if it is carried up to the region of the hypertrophied fascia of the neck of the sac, or higher still, to the region of normal transversalis fascia, we have the materials for an efficient repair. A simple ligature around the

neck of the sac is far from being an ideal means of repairing the fascia; but with a smooth primary union, the results show that it has been effective in 90 per cent. of the cases.

Whether the theory as outlined above is correct or not, there is no question concerning the fact that recurrences after operations for direct hernia are very common. Downes definitely recommends that certain types of such hernia be treated by trusses. We have had the same experience as others. To operate on a small direct hernia and have it promptly recur as a much larger and more troublesome affair, is a very disquieting experience.

The operation for a direct hernia used here in Bahrein is the same as that for an indirect hernia, until we come to deal with the sac, which is entirely isolated. Every effort is made to preserve the transversalis fascia while cleaning off the peritoneal sac. Practice has improved the technic and the results; but the results are far from uniformly successful even yet. As the peritoneal sac is often quite tough and substantial, it is split into an upper and lower leaf, and overlapped as described for an indirect hernia. The transversalis fascia is then sutured over it, or, indeed, overlapped if there is sufficient material for that. The most important feature of the operation, however, is the step that follows. A piece of fascia lata an inch (2.5 cm.) square, or larger, if necessary, which has been previously removed from the thigh, is then sutured carefully into place, reinforcing the transversalis fascia over the weak area, and overlapping normal fascia on every boundary. The size of the transplant required can be readily ascertained before the operation by examination of the patient. We do not attempt to suture this fascia under tension. The effort is made rather to fasten it accurately in the location desired, and the cremaster muscle is then sutured under the internal oblique muscle and the conjoined tendon, to carry the strain of coughing, straining, etc., until healing is solid and complete. This transplantation of fascia is a very simple procedure, adding not more than fifteen minutes to the time required for the operation, and I have yet to see a transplant that made the least trouble afterward. Hernias which are composed of a direct and an indirect sac are treated by division of the deep epigastric artery and the repair completed as in a simple direct hernia. Recurrent hernias are treated as direct.

RESULTS

Nov. 1, 1921, the operations described had been in use for nine months, during which time 201 hernias had been repaired by this method: 142 indirect hernias, and fifty-nine direct. The Mason Memorial Hospital is located in a very sparsely populated country, and is the only place where surgical service is to be obtained for hundreds of miles, in practically any direction. As might be expected, patients

who travel these long distances are usually those with severe lesions, and the cases of hernia form no exception. They are usually men of middle age, or older. The average age in this series, including children, was 43 years. Arabs and Persians practically never know their ages, and the figure given is the average of the physician's estimate for the different patients. The average duration of the hernias, excluding those which were congenital, was seven and one-half years. Thirty-six were recorded as being as large as coconuts, or larger; and of these four were extremely large, one reaching to the level of the patella, and three others to within 2 or 3 inches (5 or 7.6 cm.) of its upper border. The external ring admitted the tips of three or more fingers in thirty-five cases, and the conjoined tendon was atrophic in fifty-six cases. By this I mean that the examining finger slipped without difficulty through the external ring to the posterior aspect of the pubic bone. Six were sliding hernias, cases being so designated only when practically the whole of the posterior wall of the sac was composed of adherent cecum, colon, and the terminal part of the ileum. Three in the series were strangulated hernias; but, during this period, we were fortunate in receiving the strangulated cases early, before gangrene of the bowel had occurred, so that operatively they differed in no significant way from the others.

Technically, the series is not one of which to be proud. Two of the wounds suppurated. In one of these, the incision passed across a long narrow brand, a few days old. This is a favorite Arab treatment for almost anything, hernia included. It was one of the three strangulated hernias, so the operation was undertaken after a careful cleaning of the infected ulcer. The resulting suppuration was superficial, and the final result was good. The other case of suppuration was due to some grave error in technic. There were eleven insignificant suture infections, including those in two patients who reported to the clinic after their discharge following the removal of sutures. There were three serious hematomas, and a number of small ones. There were four deaths, one from an epidemic of infectious diarrhea in the hospital, one from heat stroke, a day or two before the expected discharge of the patient, and one from postoperative pneumonia. The fourth was the result of one of the hematomas mentioned above. About the fifth or sixth day, a patch of gangrene developed at the bottom of the scrotum, septicemia set in, and the patient died on the tenth day.

Previous to the adoption of the new operative procedure, our results had been far from satisfactory. Our hernia list has grown during the past four years, from 150, more or less, to nearly twice that figure for the past year. No follow-up system is possible in Arabia, where such things as posts and telegraphs are utterly unknown, and where probably not one in ten of the patients can read

and write. There is no way of knowing the exact number of recurrences. We have been accustomed to operate in about a dozen cases of recurrence in the course of the year. We have used both the Halsted and the Bassini operations. The immediate predecessor of the present operation was Hoguet's modification of Bassini's operation, in which the medial leaf of the external oblique fascia is sutured below Poupart's ligament, along with the conjoined tendon, and the internal oblique muscle. With increasing experience, the number of recurrences seems to have diminished somewhat, in spite of the larger number of operations performed, which indicates a considerable percentage of improvement. So far as could be seen, however, the improvement was due to an increasingly high dissection of the neck of the sac, rather than to modifications in the treatment of the abdominal wall. We consoled ourselves with the idea that considering the type of hernias dealt with, perhaps no better results could be expected.

Since adopting the operation described in this article, we have yet to see a recurrence. The series includes four patients with recurrent hernia whose original operations antedated the introduction of the new procedure; but the operation as described has yet to be followed by a recurrence. Nine months is too short a time, by far, to justify definite conclusions, and 200 hernias form far too small a series. I believe, however, that results so satisfactory in hernias of this type go far to indicate the correctness of the principles on which the operation is based, and possibly justify the publication of these results, in the hope that the operation may be tested by other men, in cases in which follow-up systems will give more positive conclusions as to its merits.

AN UNUSUAL CASE OF INTESTINAL OBSTRUCTION

A. MURAT WILLIS, M.D.
Professor of Clinical Surgery, Medical College of Virginia
RICHMOND, VA.

The case herewith reported presented a condition which I had never previously encountered, nor have I been able to find a similar instance reported in the literature.

REPORT OF CASE

History.—W. M., boy, white, aged 11 years, admitted to the Johnston-Willis Sanatorium, Nov. 25, 1920, with an unimportant family history, had had mumps and pertussis and, two years previously, typhoid. His appetite was good, and previous to the present illness the patient had never suffered from any attacks of abdominal pain, vomiting, or diarrhea. November 20, the patient was suddenly seized with severe, generalized abdominal pain. He soon became nauseated and is said to have vomited steadily for two hours. At the end of this time, the pain gradually subsided and soon ceased entirely. There was no recurrence of the pain until November 24, when an attack similar to the first occurred. Examination at this time revealed an oblong mass, about 4 inches (10 cm.) long, in the right lower quadrant of the abdomen. The pain diminished, but some pain persisted until the following day, when the patient was admitted to the hospital.

Examination.—The patient did not seem sick. He was well developed and well nourished. The lungs were clear both on percussion and auscultation. The heart showed no enlargement or murmurs. The abdomen was symmetrical and lay slightly above the level of the ribs. There was definite, slight tenderness in the right lower quadrant. Also in this region, a moderately hard mass, suggestive of an old appendiceal abscess, could be palpated.

The white cell count was 16,000. The Wassermann reaction was negative. The urine was amber, clear and acid, with a specific gravity of 1.021. There was no sugar and a very slight trace of albumin. Sediment showed an occasional epithelial and pus cell.

The history very obviously suggested a diagnosis of recurring attacks of intestinal obstruction. The common causes of recurrent intestinal obstruction in children are intussusception or adhesions resulting from appendiceal inflammation. In this case, the palpation of a mass in the right iliac fossa, together with the fact that the leukocyte count was 16,000, led to a provisional diagnosis of partial obstruction from appendiceal abscess, though the possibility of intussusception was borne in mind. Since the child did not seem ill, it was deemed best to delay operation so that if an abscess were present sufficient time would pass for it to become definitely walled off.

Operation.—November 27, the leukocyte count had fallen to 6,000; the temperature was 98.6 F., and the pulse was 98. The condition seemed favorable for operation.

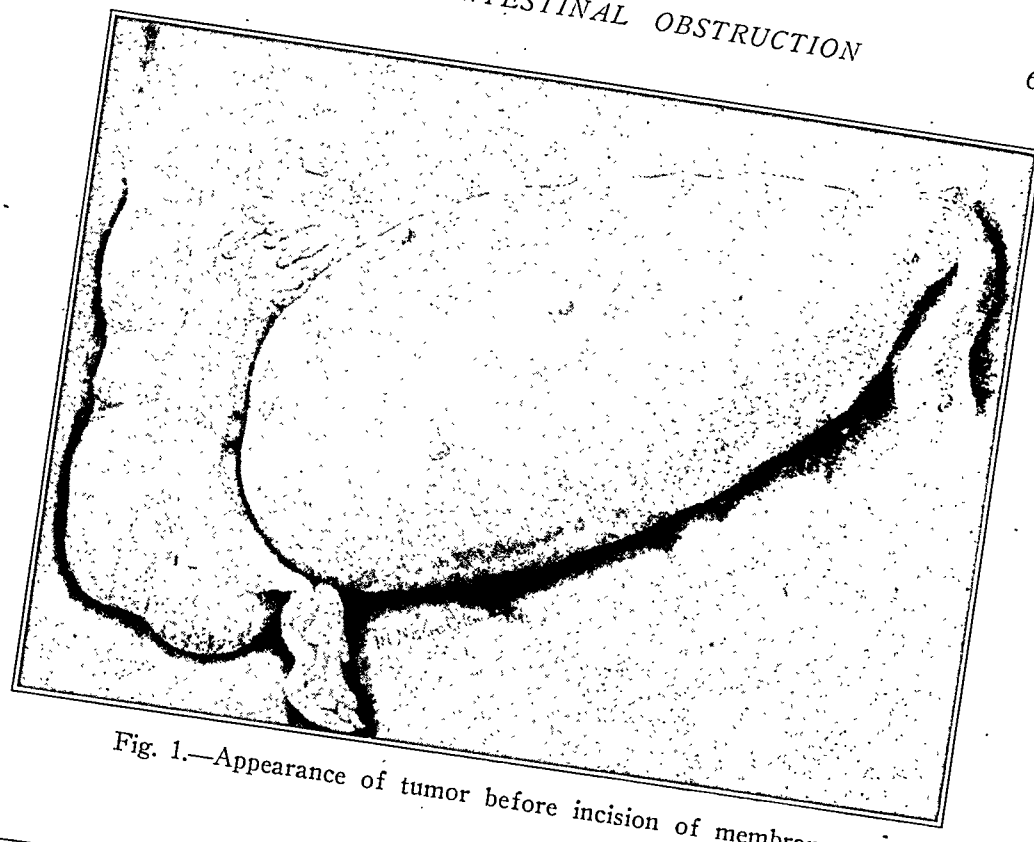

Fig. 1.—Appearance of tumor before incision of membrane.

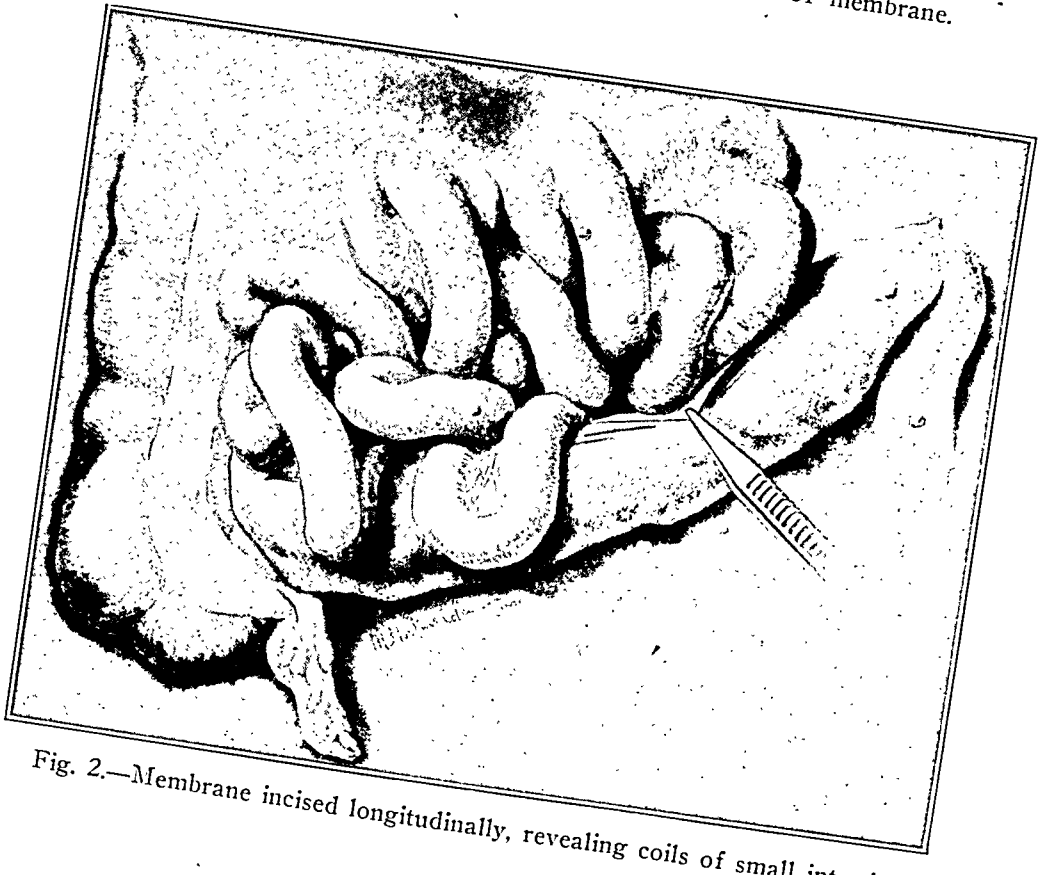

Fig. 2.—Membrane incised longitudinally, revealing coils of small intestine.

Under ether anesthesia, a right rectus incision was made. It was seen that the mass which was palpated at the time of the patient's examination was due to an enlargement of the lower portion of the ileum, above the ileocecal junction, the enlargement suggesting strongly the presence of an intussusception of this portion of the bowel. The mass lay entirely in the pelvis; and, in order to deliver it, the incision had to be enlarged. Upon delivery, the mass was found to be about 6 inches (15.2 cm.) long and 3 inches (7.6 cm.) across, somewhat ovoid in shape. The covering resembled the visceral peritoneum, except that it was somewhat paler. Palpation produced a doughy sensation, similar to that felt on palpation of an intestine filled with ascarides. Careful inspection showed that what was at first thought to be a dilated intestine, representing the intussuscipiens of an intussusception, was in reality a sac, formed from a membrane which appeared to cover the whole of the small intestine. Above and below the sacculated portion, this membrane was quite closely approximated to the intestine, somewhat like a loosely fitting glove finger. This sheath could be slipped about an inch (2.5 cm.) in either direction, downward or upward; further movement was then prevented by some connection which existed between the wall of the intestine and the inner surface of the sheath. The sacculated portion was split longitudinally, in the direction of the mesentery, and it was found that within the sac there were 30 inches (76.2 cm.) of small intestine, much coiled and folded, the terminal portion showing multiple diverticula. There were no adhesions between the adjacent coils of intestine; but a few delicate strands of connective tissue ran from the intestine to the inner surface of the sac. The redundant portions of the membrane, forming the sac, were trimmed off, freeing the contained intestine. It was deemed unnecessary to interfere with the portions of the membrane above and below the sacculated portion.

COMMENT

It was apparent that the cause of the recurring attacks was a displacement of the mass of intestine contained in the sac. When this mass was fitted down into the pelvis, it caused no symptoms; when it was displaced upward, it caused an angulation of the intestine and the consequent obstruction. The explanation of the nature of the membrane is not so simple. The absence of any evidence of an inflammatory process indicates that the condition was the result of some developmental defect. Histologic examination of a portion of the membrane made by Dr. S. W. Budd showed that it was made up of fibrous tissue. Dr. Budd suggested that it represented remnants of a persistent ventral mesentery which failed to disappear normally and was drawn over the gut at the time of the latter's rotation.

SEVENTEENTH REPORT OF PROGRESS IN ORTHOPEDIC SURGERY*

ROBERT B. OSGOOD, M.D.; ROBERT SOUTTER, M.D.; HARRY C. LOW, M.D.; MURRAY S. DANFORTH, M.D.; LLOYD T. BROWN, M.D., AND PHILIP D. WILSON, M.D.

BOSTON

CONGENITAL CONDITIONS

Congenital Torticollis.—Feil [1] calls attention to the occasional fusion of the atlas with the occiput as both a primary cause of, and a contributing factor in, cases of congenital torticollis. In certain of his cases this fusion was present from birth, and in others it did not become apparent until about the age of 20. In two of his cases it was associated with the ordinary shortened sternomastoid and accounted for the slight deviation of the head which persisted after full operative correction of the muscular contraction had been accomplished.

Feil,[2] also, in another article, discusses the anatomy and clinical picture of six different types of malformation of the cervical vertebrae, which he illustrates by concrete examples.

Cervical Ribs.—A. S. Taylor [3] believes that the incidence of cervical ribs is about one in 300 persons and that the condition is usually bilateral. They vary in size from a complete rib down to a mere exaggeration of the transverse process. The symptoms are due to irritative pressure on the seventh or eighth cervical, or first dorsal, nerve, especially in those ribs that have a bladelike edge. Ribs with rounded borders are less likely to give important symptoms. He considers the treatment of these symptoms to be operative removal of the rib.

Trostler [4] has studied from a roentgenologic point of view sixty-five cases of cervical ribs. The diagnosis was correctly made clinically in only seventeen cases. In thirty-seven cases diagnoses such as neuritis or progressive muscular atrophy had been made, and in the remaining eleven cases the findings were incidental. There were more than twice as many females as males in the series. The symptoms were more

---

* This report is based on a review of 524 articles selected from 627 titles having to do with the surgery of the extremities and spinal column, appearing in medical publications, chiefly between May 1, 1921, and Oct. 1, 1921. Only those articles have been chosen for comment which seem to represent progress in this branch of surgery.

1. Feil: Presse méd., Paris **29**:515 (June 29) 1921.
2. Feil: Progrès méd., Paris **36**:301 (June 25) 1921.
3. Taylor, A. S.: Cervical Ribs, J. A. M. A. **76**:1603 (June 4) 1921.
4. Trostler: Med. Rec. **100**:504 (Sept. 17) 1921.

frequent on the right than on the left side, and only nine persons showed symptoms on both sides. The average duration of symptoms was forty-five months. Of the thirteen patients operated on, all were partially or wholly relieved of the symptoms.

Pressure on the brachial plexus from costal elements has been discussed by Bramwell and Dykes.[5] They conclude that pressure symptoms may be caused by a cervical rib, by a rudimentary first dorsal rib, or by a normal first dorsal rib. They, as well as Trostler, find a much greater number of females than males affected. In twenty cases the average age of onset was 22 years. They believe faulty posture and, notably, confinement to bed are important etiologic factors. When the symptoms are not pronounced, attention to the general health, correction of posture, and temporary support of the arm by a sling may be expected to relieve the pain. When muscular weakness or atrophy produces constant annoyance, surgical intervention is indicated and is usually completely successful.

[Ed. Note.—We have referred to this syndrome in earlier Reports of Progress and to the frequent failures of diagnosis, especially when no true cervical ribs are found to exist. Sir Harold Stiles has recently called attention to the common anatomic variations in the arrangement of the brachial plexus. There is the prefixed or high plexus, in which the first dorsal nerve may take no part, and the postfixed, or low plexus, into which the second dorsal nerve may enter. The neural elements embryonically are developed before the costal elements and influence the growth of these costal elements. The first rib is found in most of these symptomatic cases to be somewhat rotated and to show a deep groove for the first dorsal root. When removed and laid on a flat surface, it rocks instead of lying flat, as in the normal case. With a postfixed plexus and a rocking first rib, Sir Harold believes that the symptoms of irritation of the first dorsal root frequently occur. These symptoms are pain along the ulnar side of the arm, weakness in the muscles, chiefly of the ulnar distribution, and atrophy of the adductor and interossei of the thumb. The removal of the portion of the first rib over which the root passes has been successful in his cases. Undoubtedly, we should review with more care and understanding cases of persistent "neuritis" and arm weakness. The common onset of these symptoms in later life, although the anatomic variation has been of congenital origin, would suggest that correction of posture or change of occupation might be expected to relieve many patients. These cases, we believe, may well be confused with cases showing a degenerative or hypertrophic arthritis of the cervical spine. One would expect to find helpful differentiating evidence in involve-

5. Bramwell and Dykes: Edinburgh M. J. **27**:65 (Aug.) 1921.

ment of the sympathetic ganglion in these deeper changes, and changes in the pupil; but pupillary involvement does not occur in all the cases showing marked changes of a hypertrophic arthritic character, many of which are relieved by Thomas collars and physiotherapeutic and antiarthritic treatment.]

Congenital Malformations of the Vertebrae.—Spina Bifida: Crouzon and Béhague [6] have found bifid spinous processes in the dorsolumbar region in seventeen out of thirty-one patients. They believe that it is more common in tuberculous patients and has no connection with spina bifida occulta.

Léri and Engelhard [7] call attention to the frequency of anatomic variations of the vertebrae, most commonly the partial sacralization of the last lumbar vertebra in association with cases of scoliosis, spina bifida, "lumbago," "sciatica," and renal lithiasis. The lumbarization of the first sacral is rare but it is occasionally found.

An interesting and well written article has been published by Woltman.[8] The etiologic theories are discussed from Morgagni's article, in 1779, to Von Recklinghausen's, in 1886. Morgagni considered the condition due to a hydromyelia from overactivity of the choroid plexus, while von Recklinghausen believed that it was primarily due to a failure of the mesodermal envelop of bone and dura to approximate. He looked on the ectodermal dysontogenesis as secondary. Spina bifida and other anomalies have been experimentally produced. For example, Morgan and Tsuda [9] prevented closure of the blastophore by placing frog's eggs in a 0.6 per cent. solution of sodium chlorid, and Hertwig,[10] elaborating the method, actually produced permanent spina bifida. Stockard,[11] by use of solutions of magnesium chlorid, occasionally was able to bring about spina bifida in the common minnow (*Fundulus heteroclitus*). Moll [12] has noted that other malformations usually accompany spina bifida. Woltman [8] says that from experimental and clinical observations spina bifida cannot be explained on the basis of any single factor. There must be either some abnormal character of the gametes or mechanical, chemical, or physiochemical factors influencing the embryonic rudiments either before or after differentiation. The mechanistic action of accumulated cerebrospinal fluid, which Sharpe [13]

6. Crouzon and Béhague: Bull. et mém. Soc. méd. d. hôp. de Paris **45**:403 (March 18) 1921.
7. Léri and Engelhard: Bull. et mém. Soc. méd. d. hôp. de Paris **45**:454 (April) 1921.
8. Woltman: Minnesota Med. **4**:244 (April) 1921.
9. Morgan and Tsuda: Quart. J. Micr. Sc. **25**: 1894.
10. Hertwig: Arch. f. mikr. Anat. **39**:1882.
11. Stockard: Anat. Rec. **3**:167, 1909.
12. Moll: J. Morphol. **29**:1906.
13. Sharpe: Ann. Surg. **61**:151, 1905.

considers from his experiments on dogs to be so important, Woltman believes could act only as a secondary cause. The findings in 187 cases are discussed. Twenty-four and six-tenths per cent. of these were of the occulta type. Hypertrichiasis, on the whole, is not common. Deformity of the foot, usually clubfoot, is one of the most common, and may be due to muscular weakness. Forty-nine patients over 5 years of age (excluding the occulta type) were studied. Eighty-four per cent. of this group showed evidence of cord involvement, and 71 per cent., sphincteric disturbances. There was motor paralysis in 53 per cent. and sensory changes in 45 per cent. Incontinence is common, and, while often not discovered early, becomes one of the most troublesome complaints. Of the fifty-seven patients operated on in the Mayo Clinic, twenty-two were cured, twenty-three improved, and twelve died. Two patients had postoperative hydrocephalus.

Christopher [14] has made a collective review of spina bifida occulta, quoting Wheeler's study of 1,000 roentgenograms of the lumbar region in which the incidence of incomplete closure of the posterior vertebral arches in the last lumbar vertebra was 2.3 per cent. The entire sacral canal was open in 2.89 per cent. of the entire series. After reviewing the experimental work on spina bifida, he considers the symptomatology. The cord may be normal or rendered abnormal by pressure or by reason of a false anlage, or by traction of the strand which connects the cord to the skin. Katzenstein,[15] however, has called attention to the fact that frequently the symptoms first appear between the ages of 9 and 17. He believes this may be explained by the fact that between these years the skeletal growth is at its maximum and consequently a maximum amount of pull is exerted on the cord by the band remaining adherent to the skin and passing through the adjacent bony structures.

The foot symptoms are variable, the commonest being talipes equinovarus; but equinovalgus and cavus occur. Paresis of the interossei has been reported by Guthrie,[16] and a chronic osteitis of the metatarsal bones by von Recklinghausen.[17] A very constant physical sign is the presence of one or two sacral dimples, commonly a small pit posterior to the anus. Cramer [18] says it is present in 40 per cent. of all infants; but if it has not disappeared by the tenth or twelfth year a spina bifida will usually be found.

The results from treatment have not been brilliant. Brickner [19] collected reports of twelve operative cases up to 1918 and added five of

14. Christopher: Internat. Abst. Surg., p. 2, Supp. to Surg., Gynec. & Obst. **33**: July, 1921.
15. Katzenstein: Arch. f. klin. Chir. **64**:602, 1901.
16. Guthrie: Tr. Med. Soc. London **29**:399, 1895.
17. Von Recklinghausen: Deutsch. Ztschr. f. Chir. **18**:1, 1883.
18. Cramer: Ztschr. f. orthop. Chir. **32**:440, 1913.
19. Brickner: Am. J. Med. Sc. **155**:473 (April) 1918.

his own. There was no mortality, but rarely great improvement. He believes that one would be justified in operating on children without symptoms, in the hope of obviating later disturbances.

Katzenstein considers that the best chance for a good operative result would be furnished by those cases showing first symptoms in early youth or at puberty.

Chute [20] reports four cases of retention apparently due to disturbance of the normal innervation of the bladder. A spina bifida occulta was discovered in all four cases. These symptoms of retention occurred in adult life, from 22 to 35 years in the reported cases. He thinks the late occurrence is due to the unequal growth of the canal and the cord and to the gradual traction on the nerves by the membrana reuniens. Chute states that freeing these sacral nerves has in some cases brought remarkable results and that the danger of the operation is slight.

[Ed. Note.—It is well to have our attention directed to this rather obscure condition of spina bifida occulta and to realize that it may be the cause of serious progressive symptoms and deformities. Its possible existence must not be forgotten, especially in slowly developing contractures and paralysis of the lower leg muscles in which no other etiologic factor appears. Operative interference, to have any chance of success, must apparently be early and the prognosis is doubtful even then. We must also remember that the condition exists in a large number of persons who show no symptoms which can be attributed to it. It is a very frequent finding in roentgenograms of the low spine which have been made for various purposes.]

Congenital Dislocation of the Hip.—Ridlon [21] records 437 personally observed cases of congenital dislocation of the hip. Eighty-seven per cent. were in females and 13 per cent. in males. Seventy-one per cent. of the cases were unilateral.

The report of the commission appointed by the American Orthopedic Association to study the end-results of congenital dislocation of the hip is important.[22] The commission was made up of Dr. J. E. Goldthwait, chairman, Dr. Z. B. Adams, and Dr. DeForest P. Willard. The commission decided that three years must have elapsed since operation in order that the then existent condition be considered a true end-result. The number of cases in which records were available for study proved to be very small compared to the number of patients treated. The records of the New York Orthopedic Dispensary and Hospital were the best. In general, it may be said that from the

20. Chute: J. Urology **5**:317 (April) 1921.
21. Ridlon: J. Orthop. Surg. **3**:365 (Aug.) 1921.
22. Goldthwait: J. Orthop. Surg. **3**:353 (Aug.) 1921. Adams: Ibid. **3**:357 (Aug.) 1921.

material available it was evident that few hips were normal in their bony form either before or after treatment. An anatomically normal hip was rarely seen. There was no suggestion that these changes were due to rickets. From the point of view of function, many cases were entirely satisfactory. Certain points in the anatomic structure were suggested as influencing the possibility of replacement and the permanence of the result. These were the obliquity of the innominate bones, the axis of the neck vertically and anteroposteriorly, and the inclination of the epiphyseal cartilage. From the results observed, it is evident that the very least possible violence should be employed in whatever form of reduction is used, since the capital epiphysis may be easily damaged, with resulting serious interference with its development. The commission makes a strong plea for better records as to the details of the reduction and the after-care. Next in interest to the great number of marked changes in the shape of the capital epiphysis in successfully reduced and, often well functioning, cases were the statistics as to the older cases. The cases of forty-six patients who were 6 years of age or older when the reduction was attempted were studied. On the forty-six patients, in fourteen of whom the condition was double, seventy attempts at reduction had been made. Twenty-four hips remained in; twenty-nine did not; one result is questionable, and six are marginal. Of the double cases, four reductions were attempted by the machine methods; three of these patients have one hip in and one out. One has both hips in; but the head of one of the bones has almost disappeared. Of three patients manipulated on the Hibbs' table, one patient has both hips in and has fair function; one double case is questionable on both sides, and the third patient has one hip in and one is questionable. One of Dr. Stern's eleven patients has both hips in and good function. Of the remaining six double cases, one patient has one hip in and one is questionable, and five patients have both hips out. The statistics for these older double cases studied are surely not very favorable. They are better, obviously, in the older single hip cases. The classical Trendelenburg sign was found still present in certain of the anatomically reduced hips in which the glutei were weak, and it was not always present in cases in which there existed a true dislocation. It is, therefore, not an entirely dependable diagnostic sign.

Léri [23] has studied an hitherto undescribed familial disease to which he gives the name pleonostosis familiale, because of the epiphyseal overgrowth and premature ossification. The condition is a skeletal dystrophy present in a father, aged 30, a daughter, aged 4 years, and a son, aged 3 months. It is most evident in the father and least evident in the son, but the condition is pronounced, definite, and exact in each. The hands are short and broad and the fingers very large; the arms are

23. Léri: Bull. et mém. Soc. méd. d. hôp. de Paris **45**:1228 (July 29) 1921.

bowed, and all joint motions in the upper and lower extremities are limited. The neck is short and thick, but the head itself is normal. The roentgenograms show precocious bony growth in thickness, especially in the diaphysis and at the joints of epiphyseal growth. The thickened epiphysis limits motion and causes a premature disappearance of the cartilage.

Renal Dwarfism.—Barber [24] describes a form of interstitial nephritis in children which gives rise to dwarfism and bony deformities. Only five postmortems have been obtained; but the findings have been similar in type, varying only in degree. The kidneys are very small. Although the children have been considered a little under sized since birth, the condition is not very noticeable until about 6 or 7 years, after which the stunted growth becomes striking. Bone deformities, especially genu valgum, have been present in eight of the ten cases. Steady progression of the disease has been the rule, with a fatal termination usually in the second decade. No treatment has been found to affect the condition.

TUBERCULOSIS

Tuberculosis of Bone.—In an article reporting a microscopic study of specimens from fifty cases of bone tuberculosis, Allison [25] discusses the variety of lesions observed in bones and neighboring tissues which result from one infective agent, the tubercle bacillus. The different character of these lesions Allison believes is due to the different reaction of different tissues. No instance in his series suggested primary synovial tuberculosis, the bone being the focus from which it extended in every case. He further states: "In all instances in this study in which tuberculous bone lesions were observed there was both bone destruction and bone proliferation. When cancellous bone was involved, destruction predominated. When compact bone was involved, proliferation predominated." Allison concludes that the classification of tuberculous lesions as observed in the different tissues should be much simplified. He believes that all of the various changes observed are only the natural and usual reactions to infection of the special tissue involved. Certain of these tissues have the quality of quickly reacting to stimulation with proliferation, while others show little or no tendency thus to react, and suffer destruction.

Cole,[26] in a paper read before the Mississippi Valley Conference on Tuberculosis, considers that pure diaphyseal bone tuberculosis without joint involvement is extremely rare in this country. He also cites the findings of tubercle bacilli in the mesenteric glands of still-born infants as proof of the possibility of true hereditary or congenital infection.

24. Barber: Quart. J. Med. **14**:205 (April) 1921.
25. Allison, Nathaniel: Tuberculosis of Bone, Arch. Surg. **2**:593 (May) 1921.
26. Cole: Minnesota Med. **4**:228 (April) 1921.

[Ed. Note.—The Editors have no microscopic evidence which justifies them in differing from the conclusions of Allison. His careful work is a confirmation of the earlier work of Nichols,[27] who also reached the conclusion that all joint tuberculosis was primary in the bone. It is well to remember, however, that John Fraser[28] and the Edinburgh school hold that synovial tuberculosis, especially of the bovine type, is often primary; and they have certain microscopic evidence to substantiate their claim. Clinically and roentgenologically, of course, the evidence strongly suggests, but does not scientifically prove, that the primary synovial form does occur, and we see no reason why it should not occur if primary pleural and peritoneal and tenosynovial tuberculosis is admitted. It is fair to conclude, however, that joint tuberculosis most commonly originates in the bone, and that the diagnosis of purely synovial tuberculosis must be made with great caution. We are inclined not to agree with Cole that diaphyseal tuberculosis without joint involvement is so rare in this country as to be negligible. In the series of bone lesions studied clinically, roentgenologically, and pathologically by Lovett and Wolbach,[29] there were several proved cases of diaphyseal tuberculosis without joint involvement, and in the type of dactylitis called spina ventosa the involvement is almost wholly diaphyseal.]

Serologic Tests in Surgical Tuberculosis.—Fried and Mozer[30] believe that incipient syphilis and tuberculosis may be detected by serologic tests long before they are clinically manifest. In sixty-eight tuberculous children the tests were positive in more than 70 per cent. when the known tuberculous process in the spine, hip, or knee was of less than three years' duration, but in only about 30 per cent. when it had existed longer than this. In grave cases with fistulas the reaction existed less frequently. In 165 children with rickets the percentage of reaction was only 7.5.

Tuberculous Spondylitis.—Treves[31] pleads for the treatment of Pott's disease in recumbency and by heliotherapy, but without the employment of plaster jackets. These he believes prevent chest expansion, cause atrophy of the back and body muscles, and actually lessen the efficacy of recumbency.

[Ed. Note.—Fixed and irremovable jackets we also believe are of no advantage in recumbency, but the use of plaster posterior shells or of fixation on a Bradford frame in hyperextension would seem to

27. Nichols: Boston M. & S. J. **141**: Jan. 27, 1898.

28. Fraser, John: Tuberculosis of Bones and Joints in Children, New York, The Macmillan Company, 1914.

29. Lovett and Wolbach: Surg., Gynec. & Obst. **31**:111 (Aug.) 1920.

30. Fried and Mozer: Presse méd. **29**:436 (June 1) 1921.

31. Treves: Bull. méd. **35**:197 (March) 1921.

offer a wise restraint to the activity of most children, even in bed. This apparatus may be removed several times a day if desirable for massage and even light muscular exercise, and in no way does it diminish the power or range of chest expansion.]

Of a series of 2,790 cases of osteo-articular tuberculosis treated from 1899 to 1919 at the Rizzoli Institute, 1,271 were of the spine, forming 45.5 per cent. Valtancoli [32] reports the result of a study of 1,004 cases of tuberculous spondylitis treated at the Institute from 1907 to 1919. Of these, 47.2 per cent. were males and 52.8 per cent. females. The statistics show the disease is one of the first thirty years of life; also that for the first fifteen years it attacks males and females equally; that from 15 to 45 years it attacks females more frequently, and after 45 males more frequently. The greatest number of cases occur between 3 and 5 years of age, the larger number occurring at 4 years. Thirteen per cent. showed a tuberculous heredity; 7.3 per cent. gave a history of a definite preceding trauma; 21 per cent. had had pleurisy previously; 19.7 per cent. had a concomitant tuberculosis elsewhere. The localization of the spondylitis follows: suboccipital, 1.5 per cent.; cervical, 7.8 per cent.; cervicodorsal, 2.8 per cent.; dorsal, 40.8 per cent.; dorsolumbar, 16.2 per cent.; lumbar, 31 per cent.; lumbosacral, 1.2 per cent.; sacral, 0.4 per cent. Abscesses occurred in 26.6 per cent. It is interesting that in 39.2 per cent. of the cases with abscesses no kyphosis was present. Symptoms were distributed thus: 75.6 per cent. had pain; 73.3 per cent., rigidity; 68.6 per cent., deformity; 18.7 per cent., scoliosis, and 3.9 per cent., paraplegia. Results of cases followed from one to five years were: good, 41 per cent.; fair, 25.4 per cent.; stationary, 13.1 per cent.; bad, 8.7 per cent.; dead, 11.6 per cent. Results of cases followed for fifteen years were: good, 68.6 per cent.; fair, 11.1 per cent.; stationary, 3 per cent.; bad, 1.5 per cent.; dead, 15.1 per cent. The mortality in 612 cases followed was 16.5 per cent.

Tuberculous Coxitis.—Vacchelli [33] presents a statistical study of tuberculosis of the hip occurring at the Instituto Ortopedico Rizzoli. Of 2,790 cases of osteo-articular tuberculosis, treated from 1899 to 1919, 26.9 per cent. were of the hip. Of his series of 506 treated from 1907 to 1919, 52 per cent. were males and 48 per cent. females. The right hip showed 52.8 per cent.; the left, 45.9 per cent., and both, 1.3 per cent. It is chiefly a disease of the first eighteen years of life, and occurs especially in the second three years of life. In 29.6 per cent. of the cases there was a history of tuberculosis in a near relative; in 16 per cent. of the cases there was a history of a recent trauma; in 28 per cent. of the cases there was a history of a previous concomitant tuberculous lesion elsewhere.

32. Valtancoli: Chir. d. org. di movimento. **5**:127 (April) 1921.
33. Vacchelli: Chir. d. org. di movimento. **5**:159 (April) 1921.

Pain was the first symptom in a majority of the cases and a limp was almost as common. Limitation of motion is almost always present. Some abnormal position was present in about three fourths of the cases. Shortening was present on admission in 36.3 per cent., and lengthening in two cases. There were twenty-eight cases of luxation in the series of 506 cases. Abscesses occurred in 40.5 per cent.

Roentgenographic studies showed diffuse lesions (synovial?) in 52 cases; isolated foci in 122, of which 60 were in the femoral head, 24 in the neck, 30 in the acetabulum, and 8 in the trochanter. Diffuse foci of the head and acetabulum were present in 220.

In the vast majority of cases treatment was nonoperative. In early cases or in those with active symptoms, rest in bed with traction was employed. In late cases, immobilization, usually with plaster-of-Paris casts, was used. In case the lesion was in the upper part of the head or in the roof of the acetabulum, a metal staff was inserted in the cast, which extended below the foot, so that the weight came on it and with counterpressure on the tuber ischii. Researches of Sangiorgi at the Rizzoli Institute have demonstrated that bone destruction and shortening in severe cases of tuberculous coxitis, involving the superior part of the head or the roof of the acetabulum, and in the synovial forms with marked bone atrophy, are much greater in patients in whom weight bearing is allowed than in those in whom it is prevented. Forcible correction of deformities has been given up. Heliotherapy has been used only a little, but this is due only to lack of opportunity. Abscesses are treated if possible by aspiration, repeated as needed. Glycerin with iodoform has been used for injections into abscesses with some success. In the case of fistulas, the use of Beck's paste has been given up. Heliotherapy offers the best results. The author states that operative treatment of tuberculous coxitis as such has been given up at the Rizzoli Institute, as conservative treatment gives better results. Subtrochanteric osteotomy was performed in forty-two cases, with good results in thirty-nine, and with recurrence of the deformity in three. Duration of the treatment varied from a minimum of one year to a maximum of twelve, with an average of from three to four years. Experience has taught that it is wise to maintain fixation for a long period after the disappearance of every symptom of an acute process. Four hundred questionnaires were sent to patients and 276 replies were received. Of those replying, forty-nine had pain; twenty-two had fistulas; 170 had shortening; 155 had rigidity (total); fifty-six had partial fixation; 196 had a limp; twenty-nine were dead. Of the 276 studied, as last seen, the results were classified as follows: excellent, 11.2 per cent.; good, 62.6 per cent.; fair, 13.7 per cent.; unchanged, 2.1 per cent.; dead, 13 per cent.

Tuberculosis of the Knee Joint.—Sacco [34] reports 402 cases of tuberculosis of the knee treated at the Rizzoli Institute from 1907 to 1920. Two hundred and thirty-seven (58.18 per cent.) were males, 165 (41.21 per cent.) were females. The right knee was involved slightly more frequently in men and the left knee in women. In only about 6 per cent. was there an hereditary taint. It is a disease of the first thirty-five years. Trauma played only a small part as a predisposing cause. Pleurisy as a direct precursor had a considerable rôle (10 per cent. of the cases).

The picture was usually of a swollen knee, with the leg flexed on the thigh, subluxated, and in external rotation. Diagnosis was made from the clinical picture, roentgenograms and focal tuberculin reaction. The pathologic picture is drawn from sixty-nine resections, of which thirty-seven showed the disease largely in the bone, thirteen in the synovia, eight in both bone and synovia, and various changes in the other cases. Fistulas developed in fifty-three cases. Deformity of the knee occurred in 145 cases. Two hundred and twenty cases were treated by immobilization, while in 182 some form of surgical intervention was used, sixty-nine typical resections and forty so-called economic operations, such as supracondylar osteotomies, curvilinear osteotomies, and cuneiform resections. Of the sixty-nine typical resections, forty-one gave excellent results. Of the forty so-called economic operations, thirty-seven gave excellent results. Of the 220 cases treated by immobilization, 138 cases indicated that the results would be good, while eighty-two were still under observation. Final end-results were not given.

Tuberculosis of the Foot.—Cicconardi [35] reports 145 cases. The article cannot, as a whole, be abstracted. Two methods of treatment were used. So-called conservative treatment in which immobilization was the most important feature was used in 112 cases. Operative treatment was employed in thirty-three cases. Of the 112 patients, thirteen were cured, forty-five improved, twenty-two were still under treatment, twenty-nine were discharged unimproved, one was unknown, one was worse, and one was dead of another cause. Of the thirty-three cases in which operation was performed, fourteen patients were cured, six were improved, four had had amputation and were cured, the results in two were unknown, two were under treatment, four were worse, and one was dead of another cause.

Referred Pains of Spondylitis.—Ramond and Jacquelin [36] and Marchal [37] emphasize the importance of referred pain and tendon

34. Sacco: Chir. d. org. di movimento. **5**:193 (April) 1921.
35. Cicconardi: Chir. d. org. di movimento. **5**:209 (April) 1921.
36. Ramond and Jacquelin: Prog. méd. **36**:155 (April 9) 1921.
37. Marchal: Arch. méd belges **74**:206 (March) 1921.

reflexes in syphilitic and tuberculous disease of the vertebrae. Arm and chest pain may be the only signs in the upper regions, while epigastric pain and gastric crises may be caused by a radiculitis and the irritation of the splanchnic nerves at the seat of the spinal lesion. These referred pains have long been recognized in spinal lesions; but the authors do well to point out the fact that they may entirely obscure the local vertebral signs and may simulate very closely those of a gastric or duodenal ulcer or gastritis. Food often brings on the acute symptoms, but sodium bicarbonate gives no relief.

Guillain and Laroche[38] have observed such severe symptoms following lumbar puncture in several cases of vertebral caries that they believe the method should be used with great caution as a diagnostic measure in probable Pott's disease. Paralysis of the legs occurred in several cases.

Hypertrophic Osteo-Arthropathy in Pulmonary Tuberculosis.—Corper, Cosman, Gilmore, and Black[39] have examined the hands and feet of 102 patients with pulmonary tuberculosis under treatment in a Denver hospital. There is found a high percentage of convex nails, regardless of the stage of the disease, and a transverse ridging is more common and marked than in normal persons. Hypertrophy of the soft tissues at the tips of the fingers and toes, which is rarely found in so-called normal persons, is common in the consumptive. Bone hypertrophy seen at the tips of the distal phalanges and as periosteal thickening of the shafts of the phalanges and metacarpals and tarsals, may occasionally be found in so-called normal persons; but it is common to a pronounced degree in active cases of pulmonary tuberculosis.

SYPHILIS

Experimental Syphilis in Rabbits.—Brown, Pearce, and Witherbee[40] have been studying the affections of bone, cartilage, tendons, and synovial membranes in rabbits experimentally inoculated with suitable strains of *Spirochaeta pallida*. It was found that syphilis of the skeletal system of rabbits was a very characteristic thing and might combine features of both the acquired and the inherited form in man. The conditions are not identical, but contain many fundamental characteristics, thereby affording, in the experimental form, opportunities for the study of lesions of the skeletal system. The parts of the animal involved, in order of their frequency, were the facial and cranial bones and cartilages, the feet and leg bones, the tendons and joints, the

38. Guillain and Laroche: Bull. et mém. Soc. méd. d. hôp. de Paris **45**:794 (May 27) 1921.

39. Corper, Cosman, Gilmore and Black: Am. Rev. Tuberculosis **5**:357 (July) 1921.

40. Brown, Pearce and Witherbee: J. Exper. Med. **33**:495 (April) 1921.

cervical and caudal vertebrae, the ribs and the sternum. Clinical manifestations were often present; but at times the changes could only be detected roentgenologically or pathologically. Three aspects of this experimental study are significant: (1) the analogy between certain forms of the animal and human infections; (2) the relation of syphilis of the osseous system to other evidences of the disease, and (3) the frequent occurrence of obscure bone lesions.

Klauder,[41] reporting five cases of "backache" due to syphilis, concludes that in the majority of cases it is a symptom of spinal cord affection. Backache, stiffness, and general tiredness are the chief complaints. A plea is made for a careful history and physical examination of every syphilitic patient in order that treatment may be administered in the meningeal stage of neurosyphilis instead of in the late parenchymatous stage.

Finck[42] reports a case of arthritis deformans which he believes was attributable to a syphilitic involvement of the thyroid and parathyroids in a woman of 46 years.

Eloesser[43] believes that the occasionally encountered painful tabetic fracture or Charcot joint may be explained by the fact that while a true and complete analgesia of the bone exists in these cases, the skin and soft parts still retain their sensibility, and that the pain is due to the distention of these soft part structures. This dissociation of bone and skin pain sense may well indicate that the pain fibers for these different tissues run in different paths in the spinal cord.

PARALYSIS

Nerve Injuries Due to Birth Trauma.—Friedman,[44] in a series of 2,000 consecutive neurologic cases examined at the Children's Hospital in Boston, found 101 cases of obstetric paralysis the cause of which was definite trauma during labor. There were sixty-three cases of spastic paralysis, sixty cases of feeblemindedness, and twenty-four miscellaneous cases in which birth injury seemed to Friedman to be the probable cause. He believes that thirteen per cent. would be a conservative estimate to attribute to this cause in the series studied. None of the doubtful cases were included.

Surgical Treatment of Brachial Plexus Injuries.—Adson[45] has studied 101 cases of brachial plexus injuries recorded in the Mayo Clinic since 1910. Forty-five of these were birth palsies; and in all but

41. Klauder: Arch. Dermat. & Syph. **3**:761 (June) 1921.
42. Finck: Bull. méd. **35**:466 (June 4) 1921.
43. Eloesser, Leo: Sign Occurring in Cases of Tabes Complicated by Charcot Joints, J. A. M. A. **77**:604 (Aug. 30) 1921.
44. Friedman: Boston M. & S. J. **184**:482 (May 12) 1921.
45. Adson: New York State J. Med. **21**:331 (Sept.) 1921.

five there was a history of a difficult or operative delivery. Dislocations of the shoulder were noted in thirteen cases; but the incidence of this condition was much greater in the age group above 2 years, from which he argues that Turner Thomas's theory of primary shoulder dislocation with laceration of the capsule and resultant axillary inflammation as the etiology of the lesion is not borne out. Treatment (presumably nonoperative) was attended by great improvement in function, especially in the early cases. Fifty-six cases of traumatic brachial paralysis were studied; twenty-three of these were produced by trauma to the shoulder and neck without fracture; twelve were associated with fracture or dislocation of the humerus or clavicle; thirteen were caused by belt injuries; eight by gunshot or stab wounds. Twenty-five of these patients were operated on; and exploration of the plexus usually revealed laceration of the nerve roots close to the intervertebral canal, with such wide involvement in scar tissue that it was only rarely possible to resect and anastomose. Fourteen of the twenty-five operations were failures. Eleven patients were improved to approximately 40 per cent. of function. Thirty-one of the patients were treated without operation, and only four showed little or no improvement. Twenty-six regained at least 45 per cent. of function. Failure, therefore, resulted in 58 per cent. of the cases in which operation was performed and in 15 per cent. of the cases in which operation was not performed. Adson also presents a preliminary report on experimental tears of the brachial plexus produced on cadavers soon after death. He concludes that while production of complete laceration or avulsion is difficult, it is possible, and, depending on the manner in which the force is applied, may affect the upper or lower portion of the plexus with avulsion of the sympathetic ganglion. Owing to the proximity of these lacerations to the intervertebral canal, operative repair is very difficult. He believes that many of the brachial palsies are due to lacerations of the cervical fascia, epineurium, perineurium, fasciculi, and blood vessels, rather than to complete tears or avulsions of the nerve cords themselves.

Maragliano,[46] after discussing the various theories of etiology of obstetric paralysis, concludes that the usual cause is injury to the plexus. The treatment which he has employed of fixing the arm in abduction, external rotation, flexion of the elbow, and extension of the wrist and fingers has been most successful.

Poliomyelitis.—Peabody[47] reports the results of the study, by the Harvard Infantile Paralysis Commission, of the treatment of poliomyelitis by serum injection in the epidemics of 1916 and 1920. In forty-three cases in which the diagnosis was confirmed by lumbar puncture, but in which no serum was employed, 65 per cent. did not develop any

46. Maragliano: Chir. d. org. di movimento **5**:32 (Feb.) 1921.
47. Peabody: Boston M. & S. J. **185**:174 (Aug. 11) 1921.

paralysis. Reviewing the cases treated with serum, and similar groups reported by Draper, Amoss, Zingher, Rosenow, and others, we find that the percentage of cases not developing paralysis is about the same. More prolonged study of the nature of the disease must be awaited before anything more definite as regards treatment by serum can be offered.

Rosenow [48] feels more hopeful concerning the results of treatment by means of his immune horse serum prepared by repeated injections of increasing doses of freshly isolated strains of pleomorphic streptococci. The favorable results were in general proportionate to the earliness of the injection. When improvement occurred it was with such regularity and of so marked a degree in the early cases that Rosenow believes that accidental occurrence can be excluded. The absence of death, the low incidence of paralysis, and the almost total absence of residual paralysis are attributed by him to the early administration of the serum. The early diagnosis must be made by spinal puncture in all suspicious cases. Rosenow noted improvement in clinical symptoms, but does not seem to show any marked reduction in the percentage of paralytic cases.

Levine,[49] as a result of work with the Harvard Infantile Paralysis Commission, states that there is no difficulty in making a diagnosis of poliomyelitis when definite paralysis has set in. The early diagnosis before this occurrence is, however, most to be desired. He believes, as a result of a large experience, that stiffness of the neck, with a slight fever, is a seriously suspicious sign. The only other diagnostic measure of value in the incipient cases is lumbar puncture. As a therapeutic measure it is of little value, though there may be slight relief due to the lessening of pressure. A normal cell count practically rules out poliomyelitis. A clear fluid with an increased number of cells is characteristic of poliomyelitis. Tuberculous meningitis, cerebral syphilis, and epidemic (lethargic) encephalitis show a similar fluid, but exhibit other symptoms which usually readily differentiate them.

The Surgery of Poliomyelitis.—Teece [50] believes that the mechanical aspects of tendon transplantation have obscured the physiologic aspect. The fundamental essentials are a thorough understanding of the function and action of individual muscles, an accurate determination of the muscles that are paralyzed and their possibilities of recovery, and a knowledge of the methods of encouraging recovery by reeducation. He makes the following points: (1) Muscle training before operation is important. Contraction, relaxation, isolated individual action, and

48. Rosenow, E. C.: Treatment of Acute Poliomyelitis with Immune Horse Serum, J. A. M. A. **77**:588 (Aug. 20) 1921.
49. Levine: Boston M. & S. J. **185**:238 (Aug. 25) 1921.
50. Teece: J. Orthop. Surg. **3**:405 (Aug.) 1921.

dissociation should be mastered. (2) Bony deformity must be corrected before transplantation operations. (3) Synergists should be favored for transplantation. (4) Transplantations of a complex nature should be avoided. (5) In extensive paralysis it may be advisable to perform an arthrodesis of one or more proximal joints before transplantations are undertaken for the peripheral portions of the limb. (6) The gliding mechanism must be preserved if possible. (7) The tendons must be sutured under adequate tension.

Rugh [51] reviews the history of surgery in its attempts to correct the deformities of poliomyelitis. The tenotomy of Stromeyer in 1831, the arthrodesis of Albert in 1878, and the astragalectomy of Whitman, he considers the only methods which have survived unchanged. He believes that the use of silk and fascia as ligaments has failed. Only simple tendon transplantations are advocated. Muscle intelligence and muscle sense must be acquired before the transplanted muscle can fulfil its new function.

Hannah [52] reports an unusual type of acute infantile paralysis. There was absence of fever, headache, pain, and convulsions, and the presence of a hemiplegic type of paralysis with facial involvement.

[Ed. Note.—A few similar cases have come under the Editors' cognizance during severe epidemics of poliomyelitis.]

Report of Commission on Stabilizing Operations for the Foot in Cases of Poliomyelitis.—The Commission appointed by the American Orthopedic Association to review the results of the different stabilizing operations for paralytic deformities of the foot made the following report (A. G. Cook, chairman, and W. G. Stern [53]): 1. The use of metal plates, wires, screws, nails, etc., silk ligatures, and bone grafts is objectionable or unreliable. 2. Excellent results in cases of lateral instability have been obtained by arthrodesis. The best results may be expected to follow the triple arthrodesis of Ryerson or the sub-astragaloid arthrodesis of Davis. Arthrodesis of the ankle joint is rarely indicated. 3. Astragalectomy with backward displacement of the foot after the method of Whitman, first for calcaneovalgus, second, for dangle feet, third, for lateral deformity, gives by far the best results. 4. Horizontal transverse tarsectomy after the method of Davis gives by and large less perfect results than astragalectomy and is a more difficult, bloody, and less surgical procedure. 5. The use of living ligaments after the methods of Gallie, Putti, Peckham, and others has afforded isolated successes, but as a general rule has not been satisfactory. 6. Failures following tendon transplantation were common, and the commission believes that the main use of tendon transplantation is as an adjuvant to a stabilizing operation.

---

51. Rugh: Ann. Surg. **74**:61 (July) 1921.
52. Hannah: Med. Rec. **100**:364 (Aug. 27) 1921.
53. Stern: J. Orthop. Surg. **3**:444 (Sept.) 1921.

[Ed. Note.—The commission has been continued, and it is hoped that it will report subsequently on the skeletal adjustments of Hoke of Atlanta, which seem to the Editors to show such excellent results and to be so nicely conceived and executed. They would seem to be less deforming and less likely to interfere with growth than other bony operations, and to furnish excellent stability. It is to be hoped also that the commission will further review the work of Gallie with living sutures and ligaments. The Editors have observed Gallie's own results, and the success is so much greater than the results of the method in other surgeons' hands that it seems possible that other men have perhaps not mastered Gallie's own technic and that the method may yet prove of great value in selected cases.]

Paralysis in Children Due to the Bite of the Wood-Tick.—McCornack,[54] in 1903, first reported finding a large wood-tick in the skin at the base of the spine of a woman, aged 22, suffering from motor paralysis. The removal of the tick was followed by the rapid disappearance of the paralysis. In the last ten years, McCornack has observed ten more cases of paralysis in children associated with bites of the wood-tick *(Derniacentor venustus)*, which is also responsible for Rocky Mountain spotted fever. Paralysis in sheep due to the wood-tick has been reported from Cape Colony. Hadwen, in 1913, succeeded in producing paralysis in animals experimentally from bites of the wood-tick. It has been impossible to reproduce the disease by inoculation. Experimentally incubation seems to require about eight days in the lamb. Improvement began soon after the onset of the paralysis, and complete recovery usually occurred from the twelfth to the sixteenth day. One attack seems to confer a lasting immunity. The sudden onset may be accompanied by convulsions, rapid pulse, and slight rise in temperature. There is weakness in the muscles of the extremities, staggering, and disinclination to play, followed in a few hours by more or less complete motor paralysis. Consciousness is not impaired. A large engorged wood-tick is found somewhere on the body, in the axilla, ear, temporal region, occiput, and other places. The recovery is usually complete and rapid, following the removal of the tick. Occasionally, when the tick is not removed, death results from respiratory failure. The diagnosis may readily be confused with poliomyeltis and depends on finding the tick, usually in the hairy scalp or other protected places. The only case in the author's series in which a complete blood examination was made showed an eosinophilia. In removing the tick much care must be exercised in removing the head. Gentle traction usually suffices. It may be covered with grease and as it moves to breathe it can be picked off. These symptoms by no means always supervene on the bite of wood-ticks.

54. McCornack, P. D.: Paralysis in Children Due to Bite of Wood-Ticks, J. A. M. A. **77**:260 (July 23) 1921.

[Ed. Note.—If the bite of the wood-tick has been definitely proved to cause a type of motor paralysis without any cerebral disturbance, it seems to us that it should greatly stimulate the further search for some agent, especially some insect agent, which may be responsible for the epidemics and sporadic cases of poliomyelitis. The wood-tick paralysis is usually transitory, but, according to the Harvard Commission, in 65 per cent. of the undoubted cases of poliomyelitis the patients recover without permanent paralysis. According to McCornack, the wood-tick paralysis may go on to respiratory paralysis and death in certain cases if the tick is not removed. Again the analogy is suggestive. The mud hornet, according to Shurtleff (private communication), makes sure that its hatching larvae shall have fresh meat by stinging a spider, which becomes completely paralyzed. He is placed by the thoughtful parent at the bottom of the larvae's mud hole and there he continues to live, unable to escape until the hatching larvae are ready to devour him. There is much to suggest other than human carriers of poliomyelitis. An epidermiologist and an entomologist might perhaps be very helpful partners in such a search.]

ARTHRITIS

Pemberton [55] has published another excellent article on the subject of arthritis. It is limited to a statement of the principles on which the dietary treatment rests and is replete with words of caution against the indiscriminate use of this method, which will end by bringing it into disrepute without real trial. The observations on which the dietary treatment is based are certain altered metabolic factors seen in arthritis. These are chiefly a high blood creatin, which tends to disappear as the patients improve, and a lowered sugar tolerance, which occurs in direct relation to the severity of the arthritis and grows less or disappears as convalescence proceeds. The lowered sugar tolerance is not specific for arthritis and should be interpreted only as reflecting part of the underlying pathology of this disease, which from experimental studies apparently consists in an interference with the respiratory functions of the circulatory blood. The sugar tolerance returns to normal most abruptly after the removal of causative foci of infection. Dietary restrictions cater to this weakened function, probably an oxidative function, dislocated in most cases by some inflammatory process, usually in the form of focal infection. Following on a chronic focus of infection, however, there may be a more or less permanent dislocation of normal physiology, as illustrated by the lowered sugar tolerance, such that removal of the focus is not sufficient to restore it; and this explains the frequent disappointing results following eradication. A preponderating number of patients with chronic arthritis, if placed on a

55. Pemberton: Am. J. M. Sc. **161**:517 (April) 1921.

sharply reduced intake of food or on a starvation basis, will show, within a period of from one to four days, an improvement. This may occur even in the presence of causative foci of infection; but it is evidently a mistake to use this therapy in the presence of such removable infection. Its use should not be attempted except after thorough search for and eradication of these. Before beginning dietary treatment it is advisable to determine over a period of from seven to ten days, under conditions approximating the average life of the person, the accustomed food intake in terms of calories. It is also useful to know the percentage distribution of calories in fat, protein, and carbohydrate, because of the indications that it is the latter that is the chief offender by virtue of its quick combustion and the large rôle it assumes in average dietaries. Dietary restriction must be determined for each individual case. No generalization is possible. Treatment must be carried to the point where the patient is spared the necessity of metabolizing as much food as he had been previously ingesting. When patients are suffering from chronic malnutrition, a lowering of the caloric content is attended by danger, and it must be remembered that in itself arthritis is not a fatal disease.

No rule can be advanced for any given case; but the nearest approach to such help is based on the recognized approximate requirements of 30 calories per kilogram of body weight under resting conditions. This may not achieve a result in all cases; but with this as a basis, other forms of therapy, such as massage, which were formerly inoperative, may now become operative. Sometimes a period of absolute fasting will demonstrate dramatic results; but it is too dangerous to be generally advised. In the early stages of a sharply restricted diet there may be a rapid loss in weight. Under these conditions there may be marked improvement due to the fact that catabolism is running ahead of anabolism. Later equilibrium is established, and improvement may cease, or even an exacerbation may occur. It is at this time that the test of the applicability of the diet comes and other measures may be required. When convalescence is thoroughly established, an increased caloric intake is often possible, sometimes to such a degree that the individual can resume his previous activities with even added efficiency.

Nonspecific Therapy.—Betz [56] reports the treatment of fifty cases of arthritis by injections of nonspecific protein. The typhoid vaccine was employed in all but two cases, in which gonococcus was substituted. Nearly all the acute cases cleared up after one injection. In two cases three injections were necessary. Ninety per cent. of the subacute cases cleared up after one or more injections. In the chronic cases with marked ankylosing tendencies a moderate improvement was the rule.

56. Betz: Med. Rec. **99**:920 (May 28) 1921.

The contraindications are that in alcoholic patients, delirium may be caused, and in pregnant women there is danger of abortion. High blood pressure is also a contraindication as is also a history of anaphylaxis. The average dosage is 250 million. Larger doses make the reaction uncertain, if not dangerous. There was no evidence to suggest that intravenous injections had any untoward effect on the heart or kidneys. In the series mentioned above Betz states that other forms of treatment have been tried and found unavailing.

[ED. NOTE.—Our personal experience in the past in a few cases of the more chronic type has not been encouraging. The conflicting reports and the temporary discomfort to the patients would seem to emphasize the necessity of further careful work before any general employment of the method is undertaken.]

Influenzal Arthritis.—Roello [57] reports two cases of purulent arthritis in infants following influenza, one in the shoulder joint in an infant of 13 months, and one in the hip of a child of 3 years. The shoulder was opened early and pus containing typical lanceolate gram-positive diplococci was found. Perfect motion was obtained eventually. The hip joint was not operated on early, but discharged of itself. A redislocation occurred and acetabular changes made it impossible to reduce it. Early arthrotomy in suppurative joints of this etiology would seem advisable.

Gonococcal Arthritis.—After a careful study of 100 cases of gonococcal arthritis seen in the Bellevue Hospital in New York, in which treatment by different comparative methods was instituted, Lowsley's [58] views on treatment are as follows: In the acute cases he advises rest in bed and massive doses of gonococcal vaccine, which allays pain in many instances; the joint should be completely immobilized for two weeks and then the splint removed for daily mobilization and physiotherapeutic measures. If the seminal vesicles are distended with pus which cannot be emptied by stripping, excision is to be advised and may be expected greatly to benefit the condition. Lowsley believes that possibly the operation might be wisely performed in the early stages of a gonococcal arthritis. After the acute joint symptoms have subsided, the seminal vesicles and prostate should be treated until they are cured; otherwise a slumbering volcano exists.

Cunningham [59] believes that the importance of chronic infection of the prostate and vesicles as a source of infection in chronic arthritis is not sufficiently recognized. The gonococci may have died out and left in their wake pyogenic cocci. Cunningham has been impressed with the poor results of nonoperative treatment, estimating the failure

57. Roello: Riforma med. **37**:654 (July 9) 1921.
58. Lowsley: New York M. J. **113**:641 (May 4) 1921.
59. Cunningham: Surg., Gynec. & Obst. **32**:501 (June) 1921.

of these methods at 90 per cent. He admits that the operation of removing most of the vesicles and draining the prostate is difficult; but he considers the results brilliant. It renders the patients sterile, but not impotent. His later experience following his reported 120 cases has confirmed his enthusiasm.

[ED. NOTE.—It is well for us to consider these views of well known genito-urinary surgeons concerning this obstinate form of arthritis. In the acute fulminating cases, arthrotomy and lavage and closure may be expected to arrest the local process and conserve joint motion. Many of the subacute joints subside under fixation alone. The satisfactory immediate local results may tend to make us careless in insisting on careful genito-urinary after-treatment, and, as Towsley says, leave the patient with a slumbering volcano which later may cause a chronic deforming arthritis hard to overcome.]

Roentgenologic Appearances of Gonorrheal Arthritis.—Costa and Garcin [60] have systematically examined the roentgenograms of 200 cases of gonorrheal arthritis. They conclude that there is no characteristic type of change to be discovered. The appearances are varied, and, while in a general way osteoporosis is always found, there are many other bizarre changes which make it impossible to typify the findings.

Intermittent Hydrarthrosis.—Bierring [61] has reviewed the literature of this peculiar affection, finding seventy-six cases and adding one of his own. Patients of all ages are susceptible to the disease; it attacks the sexes equally, and trauma is a negative factor. One or both knees were involved in all the cases, the elbow in three cases, the ankle, hip, and wrist in one each. He assumes that transitory influences, acting either through the circulation or the nervous system (psychic or reflex), mildly infective or toxic, can produce this unique syndrome. The condition, while persisting for many years, tends to improve and gradually ceases.

GOUT

Oxalic Acid Gout.—Loeper [62] has written many articles on this subject during the last ten years and his experience leads him to a firmer conviction of the pathologic action of oxalic acid retention. The joints suffer most from a deforming hypertrophic arthritis, involving mostly the small joints of the hands. The connective tissue and bones are chiefly affected in an oxalemia in contradistinction to the uric acid affection of the cartilage and periarticular tissues. In true gout the blood pressure is high; in oxalic acid gout the blood pressure

60. Costa and Garcin: J. de radiol. et d'électrol., February, 1921.
61. Bierring, W. L.: Intermittent Hydrarthrosis, J. A. M. A. **77**:785 (Sept. 3) 1921.
62. Loeper: Médecine **2**:768 (July) 1921.

is low and an anemia exists. The excess may be eliminated in time by a freshet through the kidneys. The most common disturbances in oxalemia are gastro-intestinal and urinary, owing to the injury caused by the elimination of the crystals of calcium oxalate. The bones may become porous from loss of calcium. Rhubarb, chocolate, the purins, and nucleins should be eliminated from the diet. Phosphorus for its remineralizing action and magnesium preparations as antidotes for the oxalic acid should be administered.

True Gout.—In an editorial in the *Journal of the American Medical Association,*[63] the problem of gout is discussed. Thannhauser and Czoniczer have shown that it is not faulty metabolism of the precursors of uric acid in the blood that leads to gout. The view is generally held that the human organism is virtually incapable of destroying uric acid, so that failure to destroy can play no part in the etiology. It seems a fundamental fact that the kidneys rather than the tissues, or faulty metabolism, are a prime factor. Interest remains centered, therefore, on the problem of elimination.

BOOK REVIEW

GOUT: With a Section on Ocular Disease in the Gouty by W. M. Beaumont. By LLEWELLYN JONES LLEWELLYN. Cloth. $7.50. Pp. 469, with one illustration. St. Louis: C. V. Mosby Company, 1921.

This large octavo of 469 pages is more likely to terrify than to attract the busy physician, particularly in America, where gout is a rare disease. Nevertheless, a perusal from cover to cover will prove of value to those desiring a comprehensive survey of the subject. The author, who holds the position of governor and senior physician at the Royal Mineral Water Hospital at Bath, writes in a delightful style and from a background of rich clinical experience. He has not spared himself in searching the literature, both ancient and modern. Particularly to be commended are the chapters on the metabolism of proteins, nucleins, and uric acid. One feels that the chapters on therapeutics are tinged by his own experience with spa treatment. His conclusions that gout is due to inherent metabolic defects and that the acute paroxysms are the result of bacterial invasion from foci of infection may not be accepted by all; but no one can disagree with the statement that neither the purely chemical nor the physical theory is alone sufficient to explain the phenomena of the disease at present.

RETROCALCANEAN BURSITIS

This annoying affection of the bursa between the insertion of the Achilles tendon and the tuberosity of the os calcis may be caused by too short shoes or by an infection. There is local tenderness and swelling. The application of high heels may avert surgical intervention. Nielson [64] reports a rapid cure as a result of this simple expedient.

---

63. The Problem of Gout, Editorial, J. A. M. A. **76**:1578 (June 4) 1921.

64. Nielson, A. L.: Diagnostic and Therapeutic Point in Retrocalcanean Bursitis, J. A. M. A. **77**:463 (Aug. 6) 1921.

[ED. NOTE.—Transverse strapping with adhesive plaster and removal of the posterior portion of the counter of the shoe may also be expected to relieve the irritation and cause subsidence of the acute condition. Roentgenograms will frequently show a very sharp corner amounting to an abnormal prominence of the superior posterior portion of the os calcis; and surgical removal of this is sometimes necessary to avoid repeated irritation of this superficial bursa.]

RICKETS: OSTEOCHONDRITIS JUVENALIS (LEGG-CALVÉ-PERTHES): OSTEITIS FIBROSA

Rickets.—An experimental study carried on at the University of Glasgow by Paton and Watson [65] on dogs led them to the following conclusions: (1) In young dogs under laboratory conditions liberal allowance of milk fat neither prevents the onset of rickets nor cures it when developed. (2) Pups kept in the open air may escape the development of rickets on an intake of less than 1 gm. of milk fat per kilogram of body weight. (3) Scrupulous care as to cleanliness is of greatest importance in pups reared in the laboratory in order to prevent rickets. (4) The results of these experiments do not support the conclusion of the Accessory Food Factors Committee of the Medical Research Council that rickets is a deficiency disease due to lack of an antirachitic factor associated with milk fat.

Mackay,[66] working with kittens, at the Lister Institute in London, has reached the same conclusions as those of the American investigators, namely, that Mellanby's claim that the ultimate cause of rickets is a substance identical with fat-soluble vitamin A, is not substantiated. Kittens fed on a diet, generally adequate, but deficient in vitamin A, become emaciated, cease growing, have diarrhea, and show abdominal distention; but at postmortem, Tozer [67] found no evidence of rickets. Hess, McGann, and Pappenheimer have reached similar conclusions. Recent perfection of technic has made possible the study of the inorganic elements of the blood, and Howland and his associates have shown that deficiency in the calcium content of the blood is not responsible for rickets. On the other hand, the inorganic phosphorus of the serum is said to be reduced always in active rickets. Normally, the ratio of the concentration of calcium to that of phosphorus in the serum of nonrachitic children is almost identical to the ratio in the tertiary phosphate whch makes up about 90 per cent. of the salts of normal bone. The deficiency in phosphorus in the serum found so constantly in rickets would seem to cause a difficulty in the precipitation of this tertiary phosphate. In healing, apparently from some unknown

65. Paton and Watson: Brit. M. J. **1**:594 (April 23) 1921.
66. Mackay: J. Biol. Chem. **15**:19. 1921.
67. Tozer: J. Biol. Chem. **15**:28. 1921.

cause in the spontaneous cases or as the result of the administration of cod liver oil, the normal calcium phosphorus balance becomes restored. The finding of a low content of inorganic phosphorus in the serum of a young child, for example, 3 mg., or less, per hundred c.c., would seem to indicate active rickets.

McCollum, Simmons, Shipley, and Park [68] have shown experimentally that in the rat, faulty rations containing 2 per cent. of added calcium carbonate give rise to pathologic conditions in the skeleton essentially identical with those found in human rickets. The cartilage undergoes degenerative and metaplastic changes and fails to take up calcium phosphate with any regularity. These rachitic changes occur when there is disturbance in the optimal ratio between calcium and phosphorus in the absence of an organic substance, supplied, for example, by sufficient quantities of cod liver oil. So far as calcium and phosphorus are concerned, the experiments seem to show that the physiologic relation between the two is of infinitely greater importance in insuring normal calcification than the absolute amount of the salts themselves.

Sherman and Pappenheimer [69] reach almost the same conclusions as a result of dietary experiments in white rats. They say that while in their experiments the addition of potassium phosphate to the diet increased the assimilation and normal deposition of calcium, it may be the quantitative relationship between the inorganic ions rather than the actual deficiency of any one of them which was the determining factor in the cause or prevention of rickets.

Hess and Unger [70] report that by the ultraviolet ray they are able to bring about a cure of rickets, and in the paper here reviewed they state that marked improvement, as shown by muscle tone, roentgenologic examination, and general condition, has resulted from direct exposure to the sun's rays. Even relatively short exposures, for example, those of 25 degrees, in two weeks showed definite results.

[Ed. Note.—The problem of rickets seems suddenly to be nearer solution than ever before. The restoration of the normal calcium phosphorus balance seems to be the essential chemical factor in bringing about a recovery, and various internal medications seem capable of restoring this balance. The striking curative effect which certain forms of radiation produce is quite startling. Park's last paper, read before the National Association for Child Hygiene, confirms the curative effect

68. McCollum, Simmons, Shipley and Park: J. Biol. Chem. **47**:507 (Aug.) 1921.

69. Sherman and Pappenheimer: J. Exper. Med. **34**:189 (Aug.) 1921.

70. Hess, A. F., and Unger, L. J.: The Cure of Infantile Rickets by Sunlight, J. A. M. A. **77**:39 (July 3) 1921.

of sunlight. Without any internal medication whatever, exposure to the sun's rays may be expected to result in a return to the normal deposition of calcium.]

Thorax in Rickets.—Park and Howland [71] have pointed out that the skeletal changes in the course of severe and prolonged rickets may threaten life and even cause death. The chief danger is from loss of rigidity of the thorax. The respiration becomes enfeebled by the depression, at first dynamic and later static, of the sides of the thorax, whose size becomes diminished. Atelectasis of the lungs may ensue; the pulmonary circulation becomes impeded, and hypertrophy of the right side of the heart follows. If such a respiratory mechanism, barely able to perform its task, is subject to an intercurrent infection, it fails. It is difficult to control these changes by any orthopedic appliance, and reliance must be placed on prophylactic measures (cod liver oil and sunlight) and the avoidance of abdominal distention. The seriousness of these thoracic deformities has also been emphasized by Brusa,[72] who reports five cases of bronchopneumonia in children with rachitic deformities of the chest. Two of these patients died.

Osteochondritis Juvenalis, Coxa Plana (Legg-Calvé-Perthes Disease).—Calvé [73] proposes the term coxa plana for this condition. He considers that the inflammatory process, whatever its nature, is buried so deep in the cartilaginous epiphysis that it does not reach the joint surface, but temporarily destroys the ossification center, which later regenerates. His theory is so closely in accord with the findings in a very carefully worked up case of Phemister [74] as to be extremely interesting. Phemister encountered a "typical" case in a boy of 10. Recumbency with traction had entirely relieved the slight pain; but the limp had persisted and increased. There were no constitutional symptoms. The roentgenologic findings were entirely characteristic of the condition. An exploratory operation demonstrated turbid, straw colored joint fluid and a mild synovitis. A window, 1 cm. square, was removed from the smooth, shining, flattened head, extending into the center of ossification, and including a small portion of the epiphyseal line. It was then seen that this center of ossification was almost entirely broken down in its lateral portion and a cavity existed, partly filled with granulation tissue and partly with débris in which were several sequestrums. The cultures and guinea-pig inoculations were all negative. The histologic picture was that of an old, probably pyogenic, infection, which had destroyed most of the bony center in the

71. Park and Howland: Bull. Johns Hopkins Hosp. **32**:101 (April) 1921
72. Brusa: Rev. d. chir. e ped. **29**:210 (April) 1921.
73. Calvé: Presse méd. **29**:383 (May 14) 1921.
74. Phemister, D. B.: Operation for Epiphysitis of Head of Femur. Arch. Surg. **2**:221 (March) 1921.

head of the femur. The hip was immobilized in a plaster spica for two months and a roentgenogram at the end of five and three-fourth months showed the defect entirely filled up with new bone and the size of the bony center slightly greater than before operation. Phemister considers that the operative and pathologic findings point strongly to an infectious nature of the disease. It is a common experience to obtain negative cultures in cases of mild localized osteitis of long duration. The center of ossification is surrounded by cartilage, and as Calvé points out may not be easily penetrated and keeps the infection localized. After some months, the infection may penetrate the narrower epiphyseal line and produces the changes in the neck which have been often noted. Cartilage is not penetrated by nerve fibers and the center of ossification is without nerve supply, which explains the common absence of pain. Legg and Kidner have both reported cases in which the epiphyseal line had been perforated and a broken down process was curetted from the adjacent neck, the culture showing staphylococcus.

Osteitis Fibrosa.—Bryan [75] reports an instructive case of osteitis fibrosa in a child of 10. A pathologic fracture of the humerus had occurred and the entire diseased section of the humerus, 4 inches (10.2 cm.) long, was excised. A boiled beef bone graft, 5 inches (12.7 cm.) long, seven-eighths inch (22.2 mm.) wide, and one-third inch (8.5 mm.) thick, drilled with holes in the ends and sides, was inserted and healed perfectly with ingrowth of new bone. The roentgenogram showed a rarefied and expanded area in the upper third of the humerus. The pathologic report was: "The continuity of the bone shaft is lost in an irregular mass of new tissue, which is pink in color, of great firmness, and not very vascular. This tissue occludes the medullary cavity and no cysts are present. Histologically, the mass consists chiefly of firm fibrous tissue in which there are very few blood vessels. In some parts a more cellular growth is found consisting chiefly of spindle shaped cells. The transition from spindle shaped cells to firm fibrous tissue can be observed in the section. With the spindle cells are many multinuclear giant cells, but their character does not suggest malignancy."

FOOT STRAIN: POSTURE: SCOLIOSIS

Mechanism of Human Foot in Walking.—Gibson [76] suggests that the term arches of the foot is really not descriptive, for an arch is a structure which remains in a fixed position. The kinetic mechanism of the foot is really a series of springs: a short hard spring on the lateral aspect of the foot, and a long flexible spring on the mesial aspect of

75. Bryan: Lancet **1**:129 (May 28) 1921.
76. Gibson: J. Orthop. Surg. 3:188 (May) 1921.

the foot. In the art of walking the weight first borne on the heel is shifted to the outer side and transmitted through the heads of the metatarsals (the anterior transverse spring) to the long flexible mesial spring. As in other machines, the long flexible spring is most likely to give way when a deforming stress is applied, either too great in amount or for too long a time for the spring to recover completely. By exercise the muscles which support these springs must be made strong enough to do their work.

Three Frequent Causes of Weak Feet.—Rugh [77] enumerates three anatomic-mechanical defects which may induce foot strain: (1) shortening of the Achilles tendon. In trying to compensate for the inability to flex the foot dorsally to 90 degrees, these patients toe out and this tends to produce foot strain. (2) Hypertrophy of the mesial border of the scaphoid, which as a congenital or developmental change, hooks round the mesial border of the astragalus and blocks adduction of the foot; and (3) the presence of the supernumerary tibiale externum just back of the scaphoid, making adduction less free.

Posture and Ptosis.—Parlavecchio [78] describes in detail three causes for the symptoms arising from ptosis of the abdominal organs: (1) the effects due to the mechanical displacements; (2) the effects due to the concomitant endocrine disturbance, and (3) the effects due to the changes in the sympathetic system.

Dickson,[79] writing on the effect of posture on the health of the child, reports a study of forty-eight cases. He concludes that the symptoms are due to muscle strain and fatigue, early visceral ptosis and the concomitant gastro-intestinal disturbances. In his series there were twenty-four cases of hip or knee pain all relieved or cured by postural treatment; twenty-eight cases of fatigue and overtire, all completely relieved; ten cases of failure to gain weight, all of which patients were improved; twenty-one cases of nervous irritability, in twelve of which the symptoms disappeared, and were improved in six. Twelve patients complained of restlessness at night, and nine of these were improved; fifteen complained of constipation, eight were cured, four improved, and three unaffected; two had periodic gastro-intestinal attacks, and in one these disappeared and in one they were greatly lessened.

Scoliosis.—Bradford [80] looks upon spinal curvature not as a definite disease but as a fault of growth; and his treatment is based not so much on correction of the curves as upon guidance of growth toward

77. Rugh: Ann. Surg. **73**:499 (April) 1921.
78. Parlavecchio: Riforma med. **37**:481 (May 21) 1921.
79. Dickson, F. D.: Effect of Posture on Health of Child, J. A. M. A. **77**:760 (Sept. 3) 1921.
80. Bradford: Boston M. & S. J. **184**:512 (May 19) 1921.

a normal standard of trunk shape and carriage. Easily tired backs should be rested, backs with weak muscles should be strengthened, and stiff portions of the spine should be made flexible. His conclusions from his wide experience are that flexible curves without structural changes in healthy patients can be restored to normal, even when some abnormal stiffness is present. Fixed rotary curves require energetic measures if improvement is to be expected, even in young children. He does not consider it a difficult task, as a rule, to prevent the increase of the curvature in healthy adolescents if careful treatment can be carried out for a long period.

SURGERY OF THE PERIPHERAL NERVES

Worster-Drought [81] believes that injuries to the posterior tibial nerve are frequently overlooked because they cause no striking paralysis. The movements at the ankle are normal; and if the lesion lies below the origin of the nerves to the flexor longus hallucis and flexor longus digitorum, the power of flexing the toes remains. Loss of sensation in the plantar region and loss of power in the intrinsic muscles of the foot are signs of posterior tibial nerve lesion. These diagnostic signs should be borne in mind in all wounds of the calf followed by pain and weakness in the foot. Babcock and Bower [82] report end-results of 608 cases of peripheral nerve injury. They performed three types of operation: (1) simple neurolysis, that is, freeing the nerve and splitting the sheath to determine the condition of the contained bundles, the tests for conductivity being made with a small faradic coil; (2) hersage, consisting of freely but carefully splitting the trunk in a number of longitudinal planes if the interior of the nerve was found to be fibrous or cicatricial. If no nerve fibers were seen, these incisions were continued until the undamaged portions of the nerve were connected by multiple fine fibrous fibrils. There were 169 such cases and only twenty-five, or 14 per cent., showed no improvement. One patient was made worse. (3) Suture, the ends of the divided nerves being trimmed with a sharp razor blade until well formed nerve bundles were shown, and then very accurate approximation was obtained by finest black silk sutures. Of 182 sutures, only eight showed failure of regeneration and in all of these some mechanical feature was found to account for the lack of regeneration. Large gaps were treated by extensive freeing of the nerves, transposition and flexion of the neighboring joints.

[Ed. Note.—We gain the impression from this article that the results reported are much more favorable than those which other well qualified surgeons have been able to attain. Drs. Babcock and Bower owe it to the profession to present a still more detailed account of

81. Worster-Drought: Brain **44**:54 (April) 1921.
82. Babcock and Bower: Pennsylvania M. J. **24**:533 (April) 1921.

individual cases, types of lesion, and final end-results in quantitative function. In relation to this very hopeful article, the review of Platt's work which follows is interesting.]

Platt[83] has analyzed the results in 510 cases in which he has operated between March, 1915, and December, 1920. Two hundred and forty-eight of these patients he has examined six months or more after the operation. He realizes that not all of them can be considered true end-results. Of 150 end-to-end sutures, there were only five musculospiral nerves and two external popliteal nerves which regained complete and perfect recovery. The factors which militate against this he considers to be: (1) period of delay between injury and operation, there being apparently little difference in the amount of improvement up to eighteen months, after two years the improvement appearing much more slowly or not at all; (2) recrudescence of septic infection in the limb; (3) anatomic situation of the suture; (4) influence of topography; (5) influence of perineural surroundings—the nerve bed; (6) influence of complications, and (7) continuance of active interstitial neuritis in the proximal segment of the nerve. He is led to believe that in complete lesions of the median and ulnar nerves in the upper arm, restoration of function in the proximal muscles is to be expected even after long periods of delay, but distal recovery is unlikely. Exploration in these cases is generally advisable; but unless resection and suture are performed, little or nothing can be expected. This total resection and suture may be unjustifiable. In complete lesions of the median and ulnar nerves in the forearm, the restoration of sensation in the median distribution is of such great importance as to warrant any well conceived procedure to attain it. In lesions of the median nerve in which partial sensory conduction is present, even with complete motor loss, resection and suture are at the present time to be condemned. In ulnar lesions in which only the intrinsic musculature is affected, resection and suture are to be advised. In the complete sciatic lesions, in which end-to-end suture is possible, the procedure may be expected to succeed. In musculospiral lesions, exploration of the nerve should precede tendon transplantation.

Maud Forrester Brown,[84] convinced that little or nothing can be expected from nerve bridgings, enumerates the procedures by which more length can be gained for end-to-end suture: (1) By extensive freeing of the nerve from its bed; after this has been done, 1½ inches (3.8 cm.) can be gained for the median and ulnar in the upper arm and 1 inch (2.5 cm.) in the forearm. By freeing the sciatic in the thigh, 2 inches (5 cm.) can be gained. (2) By fixing the neighboring joints in certain positions; adduction of the arm at the shoulder gives an

83. Platt: Brit. M. J. **1**:596 (April 23) 1921.
84. Brown: J. Orthop. Surg. **3**:277 (June) 1921.

added inch to the median, ulnar, musculospiral, and musculocutaneous. Flexion of the elbow gains 2 inches (5 cm.) for the median and 1 inch (2.5 cm.) for the musculospiral. Extension of the elbow gains 1 inch (2.5 cm.) for the ulnar. Flexion of the wrist gains 1½ inches (3.8 cm.) for the median and ulnar in the forearm. Flexion of the knees gains about 2 inches (5 cm.) to the sciatic and popliteals. (3) By altering the course of the nerve—transposition; for the ulnar, two-thirds inch (17 mm.) may be gained by this method, and an inch (2.5 cm.) for the musculospiral. (4) By stripping up any anchoring branches; extra stretch can be gained in this manner for the musculospiral, median, ulnar, sciatic, internal popliteal, and posterior tibial. The external popliteal and posterior interosseous do not lend themselves to this expedient. (5) Sacrificing branches above the lesion and compensating for the motor disturbance later by tendon transplantation are sometimes justifiable. The median has been thus lengthened 6½ inches (16.5 cm.). (6) In ununited fractures the shortening of the bones is often helpful. (7) Two-stage operations often gain from 2 to 3 inches (5 to 7.6 cm.). Of eleven cases thus lengthened there have been signs of beginning return in nearly all and in two definite sensory and motor return though not absolutely complete.

Ney [85] prefers local anesthesia for nerve operations after a wide experience. Identification sutures he believes greatly aid in preventing torsion. He considers transposition of the ulnar and musculospiral anteriorly and transposition of the median to a position superficial to the superficial head of the pronator radii teres valuable aids in gaining length. The muscular branches must be mobilized intraneurally in order to be able to do this. If in addition flexion relaxation of joints and two-stage operations are employed, the necessity for nerve bridging practically never occurs.

OSTEOMYELITIS

Acute Osteomyelitis of Long Bones in Children.—Mitchell [86] divides acute osteomyelitis of the long bones in children into three types: (1) localized infection at the end of a long bone with a comparatively long history and no severe general infection (Brodie's abscess?). Treatment by removal of all bone denuded of periosteum will allow for drainage of the medulla, which should not be curetted. (2) A short history of trouble, twenty-four hours or less, severe general infection with strictly localized exquisite tenderness on pressure at one end of the shaft. Treatment by incision will often reveal no pus, but the periosteum will be found beginning to separate over a small area. The bone should be opened freely and usually a little pus will be detected.

85. Ney: Ann. Surg. **74**:37 (July) 1921.
86. Mitchell: Brit. M. J. **1**:807 (June 4) 1921.

Drainage of these early cases will be followed by a speedy convalescence.

(3) The most common type is the acute type, in which there is considerable denudation of the periosteum, in the acute cases over the whole shaft. Mitchell believes that the removal of the whole thickness of the shaft over the whole area of denudation is indicated. A Gigli saw is used and treatment with surgical solution of chlorinated soda (Carrel-Dakin solution) instituted for a few days and then a secondary suture made. A Thomas splint is applied and active early movement of the muscles allowed.

Acute Hematogenous Osteomyelitis.—In interesting contrast to this radical treatment advised by Mitchell are the conclusions reached by Bancroft [87] after careful experimental work and a large clinical experience. He has produced a chemical osteomyelitis in animals by inserting capillary tubes filled with croton oil into the medulla. An involucrum and extensive sequestrums have been formed and the other changes characteristic of clinical osteomyelitis. These sequestrums, no matter how extensive, have always been absorbed and replaced by new bone. He concludes from these experiments that sequestrums in acute infectious osteomyelitis would behave in the same manner if it were possible to sterilize them. He reports also eleven cases of acute hematogenous osteomyelitis treated at the New York Hospital. Sixty per cent. had a history of trauma, and some previous experiments of Bancroft confirmed Lexer's findings that it is often possible to produce osteomyelitis in animals by traumatizing a bone and then introducing staphylococci intravenously. These eleven clinical cases were typical children's cases and the bones were usually involved near the metaphysis. One child died within twenty-four hours after admission. All the others are well save one, who had a small persisting sinus when last seen, two years ago. Several had metastatic joint infections, for which he advises only aspiration and irrigation, unless drainage proves absolutely necessary. In the acute stage he advises drainage with removal of a shell of cortex, followed by Carrel-Dakin treatment. In the septicemic cases he found the intravenous injection of commercial peptone most useful. In the subacute stage in which the patient is progressing favorably he is convinced that bone which appears dead may frequently be saved, and he advises against too radical an operation. The roentgenograms of his cases show great diminution in the size of the sequestrums under conservative treatment. He believes that Carrel-Dakin treatment disinfects dead bone, which then behaves like any bone graft.

87. Bancroft: Ann. Surg. **73**:681 (June) 1921.

Osteomyelitis Following War Injuries.—Stephens,[88] reporting on work at a Public Health Service hospital, found 35 per cent. of the cases to consist of an osteomyelitis following war wounds. This osteomyelitis is extremely chronic and it is almost impossible to determine when a case is cured. This emphasizes the importance of efficient early treatment. In these chronic cases operative treatment is almost always indicated. All remaining foreign bodies and sequestrums should be removed and disinfection should be attempted. When this has been accomplished, the cavity should be obliterated by filling the space with overlying soft parts or a muscle flap. Conservative rather than radical treatment should be employed.

Wood [89] also has become convinced that the pedicle muscle flap is the most efficient plug. It is living, with its own blood and often nerve supply. It acts as a hemostat and is able to resist low degrees of infection.

Hedri [90] reports surprisingly satisfactory results in closing osteomyelitic bone cavities by the method of Payr of Leipzig. A large flap of skin and subcutaneous tissue is planned with a proximal pedicle. A smaller muscle flap is fashioned with a distal or lateral pedicle. Lifting this flap, the bone cavity is exposed and thoroughly cleaned out and wiped with Lugol's solution. The muscle flap is immediately turned in and the skin flap sutured in place over it. In eight cases permanent healing was primary and in six it was secondary, but with no sinus. Two cases healed with a sinus which closed in three months. Six patients are still in the ward, but all cases bid fair to heal without a sinus within six weeks after the operation. The roentgenograms show an obliteration of the cavity after six months.

Subacute Osteomyelitis of the Spine.—Kidner [91] presents three cases of spinal lesion which he believes represent low grade pyogenic infections similar to the Legg-Calvé disease of the hip. The localization of the disease in a small area of bone, the slight tendency to collapse, the new bone formation, and the tendency to recovery make Kidner believe that we are dealing with a staphylococcus of low vitality. Early operative fixation of the diseased area apparently brings about a speedy cure.

Pathogenesis of Osteomyelitis.—Hobo [92] demonstrates in a handsomely illustrated article that bacteria tend to accumulate at the points of sluggish flow of the blood stream. This occurs most frequently in the venous capillaries of the bone marrow, liver, and spleen. The

88. Stephens: J. Orthop. Surg. **3**:138 (April) 1921.
89. Wood: Brit. J. Surg. **8**:460 (April) 1921.
90. Hedri: Zentralbl. f. Chir. **48**:698 (May 21) 1921.
91. Kidner: J. Orthop. Surg. **3**:459 (Sept.) 1921.
92. Hobo: Acta scholae med. univ. imp., Kioto **4**:1 (March) 1921.

capillaries of the marrow are extremely tortuous; and conditions are most favorable for their accumulation and extremely unfavorable for phagocytosis.

BONE, JOINT, AND TENDON SURGERY

Transplantation of Bone.—An article by Durand [93] deserves comment. It is a complete review of the history of the so-called bone graft, the earliest reference to the employment of this method being in 1670. He discusses the various forms of graft which have been employed and are being employed and states his belief as to their comparative value and applicability.

Delagénière [94] advocates the osteoperiosteal transplants and describes his technic. He looks upon them not as grafts but as implants of those elements indispensable for the new formation of bone. He takes issue with Albee, declaring that by their employment it is possible to reconstruct any portion of the skeleton and cure any pseudarthrosis much more certainly than with the Albee method. He employs transplants of about 1 mm. in thickness, consisting of periosteum lined with a thin layer of bone. Operations on the jaw, nose, skull, or shoulder are illustrated.

Haas [95] reports another careful piece of experimental work, this time to determine the influence of function in relation to transplantation of bone. From one paw of an animal, a metatarsal, metatarsophalangeal articulation and a proximal phalanx were removed and transplanted into the muscles of the back. In the other paw the same elements were completely removed and then reimplanted in their original bed. These reimplanted bones lived and developed normal density under functional use. The same elements implanted into the back muscles degenerated and completely disappeared in three years. He concludes, therefore, that function exerts a definite influence upon the viability of transplanted bone. Bony union between the transplant and the host is essential; and functional use should not be instituted until this union is well established.

Henderson [96] reviews 413 cases of bone transplantation performed at the Mayo Clinic during the last eight years. Of 166 cases of spinal caries in which operation was performed by the Albee technic with slight modifications, he has been able to trace 132 patients on whom the operation had been performed at least eighteen months previously. Only nine of these were children. When patients were free from pain

93. Durand: Lyon méd. **130**:473 (June 10) 1921.
94. Delagénière: J. de chir., Paris **17**:305 (April) 1921.
95. Haas, S. L.: Function in Relation to Transplantation of Bone, Arch. Surg. 3:425 (Sept.) 1921.
96. Henderson, M. S.: Autogenous Bone Transplantation, J. A. M. A. **77**: 165 (July 16) 1921.

and able to resume wage earning occupations the disease has been classified as arrested or cured. Exactly 50 per cent. of these 132 cases were thus classified. Of the patients 21.99 per cent. were improved; 16.66 per cent. were unimproved; 9.09 per cent. died later of disseminated tuberculosis, and there was a 2.26 per cent. operative mortality. Only 2.4 per cent. had postoperative infection. Occasional complications were: loss of graft, two cases; fracture of the graft, four cases; loosening of one end of the graft; ulceration over the prominence of a large kyphos.

Two hundred and forty-seven patients were operated on for delayed union, nonunion, and other conditions, and more than half of these had been previously operated on elsewhere. Fifty-nine of them had been infected and in many there was much scar tissue and the skin was often adherent to bone. Two hundred and twenty-three of the patients have been traced, and on these 176 operations had been performed. Of these operations, 72.16 per cent. were successful, 85 per cent. of the tibia cases, 50 per cent. of the femur cases, and 60 per cent. of the humerus cases. There were four deaths. In 247 operations, there was infection following 15.7 per cent. of the operations; in 9.9 per cent. of the clean cases, and in 41.3 per cent. of the previously infected cases. The method which Henderson now employs is the inlay graft, fastened in place with bone screws. He has abandoned the use of the intramedullary transplant because of the poor results.

Loose Bodies in Joints.—Fisher[97] in a Hunterian Lecture before the Royal College of Surgeons, England, has made a very complete study of loose bodies composed of cartilage or of cartilage and bone occurring in joints, with special reference to their pathology and etiology. He reminds us that Sir James Paget's theory of "quiet necrosis or osteochondritis dessicans" has been interpreted by American authors as a dissecting process and called "dissecans." Under the pathology and symptomatology, he makes three groups of bodies: (1) Those occurring in connection with some more or less general pathologic process, for example, osteo-arthritis, tabes, tuberculosis, or infection. (2) Loose bodies formed from a detachment of a portion of the articular cartilage in otherwise normal joints. Proliferative changes in these loose bodies take place when they are incompletely detached or form reattachments. (3) Synovial chondromas. Etiologically, he believes the second group represents true traumatic detachments. Pathologically, he believes that clinically and experimentally the cells retain their vitality and after a time actually proliferate. He is convinced of this in spite of Redfern's dictum that cartilage cells are destitute of the power of repair. The nutrition of articular cartilage

97. Fisher: Brit. J. Surg. **8**:493 (April) 1921.

may come from the synovial fluid, from plasma exuded from capillaries in the cancellous spaces, abutting on the calcified layer of the articular cartilage, or from plasma from the plexus of vessels beneath the synovial membrane at the margin of the articular cartilage. In loose bodies quite free in the joint, there is no evidence to show any proliferation of the osteoblasts. On the other hand, loose bodies of traumatic origin which have acquired an early attachment to the synovial membrane show active proliferation of osteoblasts, with formation of new bone. He discusses the classical symptoms of locking, which may be present for a period, to disappear if the body becomes attached and sessile, and reappear if it again becomes free. He considers the treatment operative, always preceded by roentgenologic examination. He considers the method of transfixing with a needle and removal through a button hole incision as unscientific and likely to be incomplete.

ARTHROPLASTY

Putti [98] considers, in enlightening detail, the indications and contraindications for arthroplasty. His views are based on an experience of ten years, during which time he has performed 113 mobilizations. The absolute indications for such attempts he considers to be ankylosis of the temporomaxillary joint, bilateral ankylosis of the hip joints, ankylosis of the elbow in extension, and ankylosis of several of the important joints in one limb. In determining the indications in cases other than these, he believes that the surgeon must carefully consider: (1) the general health of the patient; (2) his age; (3) his mental condition and social state. Between 20 and 50 years is the most favorable age. Men do better than women. The posttraumatic arthritides present the most favorable group. The results are better in the cases of bony ankylosis than in the painful fibrous ankylosis. After an infectious arthritis any thought of an operation for mobilization must be deferred until at least a year has elapsed after the subsidence of joint sensitiveness. At present Putti considers that ankylosis is the best result in tuberculous arthritis. In connection with arthroplasty of the knee, Putti believes that it should be advised only when a precise indication is present and should be undertaken only by a surgeon who has acquired great skill in the reconstruction of joints. Under these conditions he believes that it should be accepted with greater faith and executed more frequently. The essential operative methods are these: (1) A complete exposure of the joint. (2) In functional reshaping of the articular ends, resection of enough bone to provide a space of at least 1 inch (2.5 cm.) between the ends is advisable. (3) Free aponeurotic (fascial) flaps should completely cover both ends. (4) Drainage should not be employed. After the operation the joint should be immobilized in

98. Putti: J. Orthop. Surg. 3:421 (Sept.) 1921.

plaster with distal traction. Hot air treatment is begun as soon as the wounds are closed. Painless mobilization is begun on the tenth day, but traction is maintained for a month. In Putti's series the highest percentage of successful results has been obtained in the elbow, the next highest in the knee, the third in the jaw, and the fourth in the hip. There were two operative fatalities.

Campbell [99] reports the results of twenty arthroplastic operations on the knee, in which he has employed pedunculated flaps, free fascia, and absorbable membranes. In four cases the membrane was extruded. In three the failure was, in Campbell's opinion, due to the dense low grade osteomyelitic bone through which the operation was performed. Of the remaining thirteen patients, nine obtained some voluntary motion, in four of these not sufficient to be of practical use, but in five enough to provide satisfactory function, making the successes in his series 25 per cent.

Typhoid Bone and Joint Disease.—Wilson [100] reports a case of typhoid osteitis from which cultures both from swab and from removed bone showed a growth of pure *Bacillus typhosus.* The Carrel technic was instituted for four days and then secondary suture was successfully accomplished.

Bureau and Marchand [101] illustrate the fact that typhoid bone lesions may become appreciable only long after the acute disease is over, by the case of a woman in whom spinal suppuration did not develop until seventeen months after the fever. This continued at intervals for two years and was finally arrested, they believe, by autogenous typhoid vaccine treatment.

Sicard and Robineau [102] also report seven cases of typhoid bone lesion in which recovery was, in their opinion, greatly accelerated by vaccine treatment. They believe that the combination of surgical treatment with autogenous vaccine therapy is usually promptly effective. They say that Rathery has obtained great benefit, especially in typhoidal spondylitis, from injection of antityphoid serum directly into the focus of disease.

Rupture of Biceps Cubiti Tendon at Insertion.—Nutt [103] describes an unusual case of rupture of the biceps tendon at its insertion into the radius. This occurred during gymnastic exercises and was accompanied by so little pain that the patient continued his exercise. Noting a

99. Campbell: J. Orthop. Surg. **3**:430 (Sept.) 1921.

100. Wilson: Boston M. & S. J. **185**:201 (Aug. 18) 1921.

101. Bureau and Marchand: Bull. méd., Paris **35**:511 (June 18) 1921.

102. Sicard and Robineau: Bull. et mém. Soc. méd. d. hôp. de Paris **45**: 465 (April 8) 1921.

103. Nutt, J. J.: Rupture of the Tendon of Insertion of the Biceps Flexor Cubiti, J. A. M. A. **76**:1825 (June 25) 1921.

difference in the contour of his arms he sought advice. The diagnosis was made and the patient was operated on the next day, the tendon being sutured. Immobilization in plaster for six weeks and the application of a right angle splint for two weeks longer was followed by gradual return of function. Three months after the operation the tendon had acquired its normal size and strength.

Snapping Finger.—In a case of snapping (trigger) finger of the right hand, Hoogveld [104] palpated an enlarged, tender portion of the flexor tendon. The tendon sheath was incised and fat tissue sutured over it without closing the sheath. All symptoms promptly ceased.

Prevention of Adhesions in Tendon Transplantation.—Lange,[105] after many experiments on animals, has employed, in more than 100 cases, thin crêpe paper to prevent adhesions in tendon transplantations. He reports great satisfaction with the method and almost complete success even when the transplanted tendon played over bone or fascia. Two layers of paper have been usually employed. The length of time of absorption depends on the thickness of the interposed paper.

Arthrodesis of the Sacro-Iliac Joint.—The operative plan described by Gaenslen [106] has been used in four cases, brief reports of which are given. A curved incision is made parallel to, and about one-half inch (12.7 mm.) above, the crest of the ilium through the skin and subcutaneous tissue extending from just behind the middle of the crest to the posterior inferior spine of the ilium. The flap is then dissected free from the outer margin of the crest. With a broad flat chisel the posterior portion of the ilium is split into an inner and outer leaf. The outer flap is broken at its base and deflected outward as far as possible, the periosteum being stripped off from the adjacent portion of the ilium just below and anterior, in order to increase the working space. With a chisel, the inner leaf of the split portion of the ilium is cut from a point just above the posterior inferior spine to the extent of 2 inches (5 cm.), extending anteriorly. A vertical cut, about 1½ inches (3.8 cm.) in length is made from the anterior end of this incision, extending upward toward the crest of the ilium to a point joining the middle and posterior third of the crest. The two points are now joined with a third chisel cut, a triangular piece of bone being removed. The destruction of the joint thus exposed is begun at the lowermost border of the sacro-iliac joint, where it is plainly in view, and is carried forward from this point, working forward and slightly outward, in general, in the direction of the anterior superior spine of the same side. After eradication of the joint, the deep trough is

104. Hoogveld: Nederlandsch Tijdschr. v. Geneesk. **1**:2663 (May 14) 1921.
105. Lange: Ztschr. f. orthop. Chir. **41**:6, 1921.
106. Gaenslen: Wisconsin M. J. **20**:20 (June) 1921.

filled with healthy cancellous bone chips removed during the course of the operation. The deflected outer leaf of the ilium is then brought into position and sutured along the crest to the inner leaf of the ilium, which has been allowed to remain standing. In several cases the inner leaf was broken off toward the medial side; but in perfecting the technic of the operation on the cadaver, it was found that the inner leaf could be left standing without adding to the difficulties of the operation.

Smith-Petersen [107] describes a new method of approach to the sacro-iliac joint for purposes of arthrodesis in tuberculosis and chronic relaxation and for drainage in osteomyelitis. A curved incision is made along the iliac crest, from the posterior superior spine forward to about two thirds of the distance to the anterior superior spine, and carried down to the bone. Subperiosteal reflexion of the flap is started. The incision is next continued from the posterior superior spine downward in the direction of the fibers of the gluteus maximus for 3 or 4 inches (7.6 or 10.2 cm.). The fibers of the gluteus maximus are separated by blunt dissection down to the bone; some of the branches of the superior gluteal nerve and artery are encountered and must be divided. The whole flap thus outlined is reflected subperiosteally, exposing the posterior portion of the lateral surface of the ilium. If the sacro-iliac joint is projected on the lateral surface of the ilium, it will be found that the inferior border corresponds with the sacro-sciatic notch and the anterior border with the median gluteal line. A rectangular window is then cut through the ilium within the projected area of the joint. In the tuberculous cases it is made about in the center of the joint surface and in the osteomyelitic cases parallel with, and close to, the sacrosciatic notch. Roughly, its size is usually 4 by 2 cm. The thickness of the ilium just above the sacrosciatic notch is considerable, sometimes 2 cm. +; but if care is taken, the plug of bone comprising the window can be removed en bloc and the joint surface is exposed. In cases of tuberculosis, the surface of the joint is curetted and all available tuberculous tissue removed; the window is continued into the sacrum, and the plug of bone cut in these cases on a slight bevel driven into it and set like a nail beneath the surface of the ilium. He reports seven successful cases of tuberculosis of the joint in the last three years, apparently firmly arthrodesed with the disease arrested, and six cases of relaxation of the joint, three successful end-results and three recent but apparently successful cases.

[Ed. Note.—These new approaches of Gaenslen and Smith-Petersen to the sacro-iliac joint seem to us to represent real advances in bone and joint surgery. Heretofore, the only approach of which we

107. Smith-Petersen: J. Orthop. Surg. **3**:400 (Aug.) 1921.

have knowledge and which was not very mutilating was Painter's,[108] which turned back a flap consisting of the whole posterior portion of ilium. This is a difficult and serious operation. Of the two methods herein proposed we can speak with first hand knowledge of only the Smith-Petersen approach; but it seems to us the simpler of the two and sufficiently complete to accomplish its purposes. In Smith-Petersen's hands the operation is a fairly rapid one, with little loss of blood and practically no postoperative shock. There has been no mortality and in cases of tuberculosis the late roentgenograms have shown what appears to be a complete bony ankylosis and an arrest of the disease. The functional results have been as completely satisfactory as the anatomic.]

Arthrodesis of the Hip for Nontuberculous Affections.—Spiers[109] has reviewed the end-results (four years or more) in twenty-five cases of nontuberculous affections of the hip joint from the Orthopedic Clinic of the Massachusetts General Hospital, in which arthrodesis of the hip joint has been attempted. In the painful hips resulting from old injuries, with only a few degrees of motion persisting, the results were satisfactory. In the cases of hypertrophic or degenerative arthritis, the improvement was not so great, and complete ankylosis was much harder to obtain. The convalescence in a long spica should be continued for a year, as the tendency to a recurrence of the adduction deformity is great. Of the twenty-five cases, union was firm in seventeen, questionable or weak in three, and incomplete in five. Fourteen were completely relieved of symptoms; seven were improved, and four derived no benefit from the operation.

Operative Lengthening of the Femur.—Putti[110] advocates lengthening many femurs shortened more than 2 inches (5 cm.). He emphasizes the necessity of continuous traction after the operation. This he accomplishes by firmly fixing large metal pins in the femur before dividing the bone, one pin in the trochanter and one in the condyles. A telescoping tube containing a strong elongating spring and controlled by a screw now connects the pins outside the skin. In performing the Z-shaped osteotomy, a motor saw is employed. He reports ten cases in which he has gained from 3 to 4 inches (7.6 to 10 cm.).

[Ed. Note.—We have attempted, and observed the attempts of other surgeons, to lengthen femurs in young adults and older subjects, employing continuous skeletal traction to the distal fragment after Z-shaped osteotomies. Slight degrees of lengthening, from 1 to 2 inches (2.5 to 5 cm.) have been obtained. There has been a tendency to

108. Painter: Boston M. & S. J. **159**:207 (Aug. 13) 1908.
109. Spiers: J. Orthop. Surg. **2**:515 (Sept.) 1920.
110. Putti, V.: Operative Lengthening of Femur, J. A. M. A. **77**:934 (Sept. 17) 1921.

a bowing of the fragments in spite of very heavy traction. The operation has not been without shock and the convalescence has been stormy. There are many cases which would be benefited by such a lengthening, and if Putti's apparatus proves successful in other hands it will have a considerable range of usefulness.]

Arthrotomy of the Knee.—Putti [111] describes the details of the method of approach to the knee joint which he now employs in arthroplastic operations and for purposes of resection: First, a U-shaped incision with base downward, extending from the inner part of the articular space upward around the patella to the outer part of the articular space. From the convex part of the incision a second one is made upward for 5 or 6 cm. following the lateral margin of the quadriceps ligament. This incision includes the skin, the subcutaneous tissue, and the superficial fascia. Second, isolation of the extensor apparatus. The tendinous insertions of the two vasti are separated from the quadriceps tendon and from the patella. These two incisions are carried in depth to the articular space. Third, plastic tenotomy of the quadriceps tendon. For this he makes use of what is practically two Z-shaped tenotomies side by side, each of half the tendon which has been bisected longitudinally. Fourth, freeing and reflecting downward of the patellar flap, giving a complete view of the articular cavity. Fifth, hemostasis. Sixth, reconstruction. The two flaps of the tenoplasty of the quadriceps tendon are sutured at whatever tension is desired, his method of section making it possible to elongate the tendon as much as is desired, and then the two lateral flaps of the vasti and the capsule at the sides of the patella are sutured to the reconstructed quadriceps tendon and to the patella.

Putti [112] also describes his operative method of overcoming flexor contraction of the knee. In certain cases of flexion contracture of the knee, it is impossible to straighten the knee even after lengthening the tendons, on account of the contracture of the posterior part of the capsule. In such cases Putti divides the capsule in the following manner. It first should be understood that the popliteal part of the capsule is made up of two firm bands or infundibuli, one medial and one lateral, and an intermediate fibrous septum. For approaching the capsule Putti uses a median vertical incision through the skin and superficial fascia and exposes the layer of fat which contains the internal popliteal nerve and laterally, partly hidden by the biceps, the external popliteal nerve. Plastic lengthenings of the flexor tendons are then done after which retractors are used to expose the underlying capsule. The capsule over the external condyle is first exposed and divided by

111. Putti: Chir. d. org. di movimento **5**:1 (Feb.) 1921.
112. Putti: Chir. d. org. di movimento **5**:11 (Feb.) 1921.

a transverse incision reaching to the bone. The capsule over the internal condyle is then exposed and divided in the same manner and at the same level. Finally, the intermediate septum is divided. The knee is then extended as far as the tension in the vessels and nerves allows and the wound is closed. Entire correction can be obtained in subsequent stages.

Internal Derangements of the Knee Joint.—Billington,[113] in a paper on internal derangements of the knee joint, offers the following anatomic explanation of the commonly found longitudinal splits in the internal semilunar. These splits begin at the anterior portion when the cartilage normally divides into two bands, one of which attaches to the coronary ligament and the anterior margin of the tibia just internal to the patellar ligament. The other, or posterior, division passes across as the transverse ligament and is continuous as the anterior portion of the external cartilage. When the internal condyle rotates backward, tension is made on the anterior divided portion of the internal semilunar, which is attached as above at widely divergent points, and the split may be started. The fibers of the cartilage run in a longitudinal direction and the split may be extended toward the posterior portion of the meniscus if the splitting force is continued.

Ollerenshaw [114] adds reports of three personally observed cases to the twelve already to be found in the literature of cysts of the external semilunar cartilage. There are no cysts of the internal cartilage reported. A slight injury is followed by the development of a swelling over the external cartilage, then gradually pain and lameness increase. The swelling usually occurs at the junction of the anterior and middle of the cartilage. It is fluctuant but rather tense. Ollerenshaw believes the cysts to be developmental in origin, and due to small endothelial inclusions of the cartilage during the formation of the joint. Trauma may act as the exciting agent to further the development and growth of the cyst. They have a tendency to recur after simple excision.

[Ed. Note.—One of the Editors has removed one such cyst of the external semilunar, associated with a slipping of the cartilage. We have also seen a second, apparently typical, case, also associated with symptoms of catching.]

Cotton,[115] in an article on various knee joint lesions in ex-soldiers on which he has operated, makes the statement that for lateral and anteroposterior instability he has employed, in six cases, firm bands of fascia lata implanted in the condyles of the femur and tibia, mesially and laterally, running obliquely forward and backward, or straight, as the demands of the instability require. He believes that in rupture of the crucial ligaments very useful and stable knees may thus be secured.

113. Billington: Southern M. J. **14**:631 (Aug.) 1921.
114. Ollerenshaw: Brit. J. Surg. **8**:409 (April) 1921.
115. Cotton: Mil. Surgeon **49**:20 (July) 1921.

Nuzzi [116] has employed with satisfaction an approach to the tibio-astragaloid and subastragaloid joint through the Achilles tendon. His skin incision is curved, with the convexity proximal from the outer to the inner malleolus, and an extension upward vertically from the center of the convexity. The Achilles tendon thus exposed is divided by a Z-shaped cut; and by deeper dissection the posterior portion of the astragalus is exposed, and access to the superior and inferior articulations of the astragalus obtained for purposes of astragalectomy or arthrodesis.

New Approach to the Supraclavicular and Infraclavicular Regions.—Dobrovolskaya [117] advocates a new method of approach to the subclavian vessels and brachial plexus. His incision starts from the clavicle between the two insertions of the sternocleidomastoid muscle, running downward, and mesially, encircling the sternoclavicular joint, and continuing outward along the lower border of the clavicle. The clavicle is disarticulated from the sternum and retracted outward, with the skin flap. He maintains that the exposure of the brachial plexus thus obtained is most satisfactory.

[Ed. Note.—The approach seems to us more rational for the vessels than for the plexus.]

Manipulation of Stiff Joints.—It is the prevailing opinion that brisement forcé has little place as an operative procedure looking to an increase in the range of joint motion. A description of the methods which have enabled Sir Robert Jones [118] to obtain in so many cases so much benefit from manipulation of stiffened joints is, therefore, of great value. He has described these methods and stated the underlying principles very clearly in the article referred to above. Not forsaking the dictums of Thomas as to the value of rest and immobilization, he says we should draw a distinction between the real and the apparent, and not allow a certain timidity to prevent our taking advantage of a much ignored and little understood means of treatment.

[Ed. Note.—The Editors advise a careful perusal of this article, which is so direct and concise that it cannot be reviewed in small space.]

DISLOCATIONS

Recurrent Dislocation of the Shoulder.—Henderson [119] believes that the primary dislocation causes a tear in the anterior inferior portion of the capsule, which is the weakest and most relaxed portion and is unsupported by muscles. He conceives that the infraspinatus and supraspinatus tendons are torn by the primary injury and imperfectly

116. Nuzzi: Riforma med. **37**:701 (July 23) 1921.
117. Dobrovolskaya: Lancet **2**:129 (July 16) 1921.
118. Jones: J. Orthop. Surg. **3**:385 (Aug.) 1921.
119. Henderson: Surg., Gynec. & Obst. **33**:1 (July) 1921.

repaired by scar tissue. In certain instances the greater tuberosity is torn off. The stretching of the scar tissue takes away important muscular support and when the arm is abducted the humeral head sags downward and the action of the teres major, latissimus dorsi and pectoralis major tend to produce the dislocation by pulling the head against the weakened portion of the capsule. He reports sixteen results from the capsulorrhaphy operation which he has performed. Eight, or 50 per cent., he considers cures, and five others report great benefit from the operation.

Dislocation of the Carpal Semilunar.—C. R. McClure [120] has been able completely to reduce two recent dislocations of the carpal semilunar bone, one manually and one by the Thomas wrench. The functional results have been perfect.

Dislocation of the Sacro-Iliac Joint.—Gibson [121] reports the case of a boy of 8 years, who suffered a dislocation of the left sacro-iliac joint from a blow from a locomotive. The ilium was separated from the sacrum and a temporary paralysis of the quadriceps was present, apparently caused by a hematoma about the anterior crural nerve in the iliac fossa. In three weeks power had returned, and through a posterior incision the posterior superior spine of the ilium was divided by motor saw and the fragment implanted in the gap between the joint surfaces which were freshened. Full recovery of function followed.

Downward Dislocation of the Patella.—Rutherfurd [122] has encountered three cases of downward dislocation of the patella in three males, aged 7, 18 and 42. There was severe injury in all, the trauma being directed downward and backward, with the knee flexed. Operation brought about good results; and in two of the cases, examination of the patellar ligament and the quadriceps tendon showed both to be intact.

Dreyer [123] reports two satisfactory end-results of three years' duration following his operation for recurrent dislocation of the patella. He makes a longitudinal incision along the external border of the patella, and the iliotibial band and the insertion of the vastus externus into the patella are exposed. The insertion of the vastus externus into the patella is separated from the rest of the muscle and a flap is formed by continuing the incision about 8 cm. above the patella. This fascial flap still attached to the external border of the patella is divided above, passed beneath the rectus tendon, and fastened to the vastus internus which, when it contracts, pulls the patella inward. A capsulorrhaphy of the mesial capsule is also performed.

---

120. McClure: Northwest Med. **21**:70 (March) 1921.
121. Gibson, A.: Dislocation of Sacro-Iliac Joint, J. A. M. A. **76**:1487 (May 28) 1921.
122. Rutherfurd: Brit. J. Surg. **8**:524 (April) 1921.
123. Dreyer: Deutsch. med. Wchnschr. **46**:489 (April 29) 1920.

FRACTURES

Spontaneous Fractures in the Young.—Hass [124] has encountered five cases of spontaneous fracture or infractions of the upper metaphysis of the tibia in boys ranging from 15 to 17 years of age. There were no signs of rickets or osteomalacia, and the roentgenograms revealed apparently normal bones. There was gradual onset of pain, increased by weight bearing. Bow leg deformity and shortening ensued. Union was very slow. He attributes the lesion to some nutritional disturbance.

Fracture Services.—Ollerenshaw [125] makes a strong plea for the establishment of special fracture services in general hospitals in charge of surgeons especially interested in bone and joint lesions. The importance of the inclusion of the outpatient cases in such a service is emphasized. He considers about 6 per cent. of the total number of hospital beds necessary for such a service, and he is convinced that such a plan will avoid many of the bad results which now occur from the general treatment of fractures.

Open Reductions.—Enloe [126] has been employing a rather unusual method in open reduction of fractures. A plaster cast is applied to the limb a week before the open reduction is to be attempted and the operation is performed through an ample window cut in the cast. He considers some of the advantages to be the ease of reduction during operation, the cast providing a fulcrum for leverage. Postoperative comfort and rest are assured. He reports no infections.

[Ed. Note.—We can conceive of a very limited range of usefulness for this procedure; but our experience has been that the surgeon rarely knows before operation the exact position which is certain to hold the replaced fragments most securely in apposition. This judgment must be formed at the time of operation. If the position previously determined and maintained by a cast should not prove suitable to best retain the alinement, the removal of the cast in the presence of the open wound would be difficult without jeopardizing aseptic technic.]

Fracture of the Cervical Vertebrae with Cord Injury.—Osnato [127] reviews the operative mortality of four different surgeons of wide experience in cases of fracture of the cervical vertebrae with cord injury. He finds that this mortality ranges from 64 to 85 per cent. He reports four cases of his own treated conservatively, with only one death and three good recoveries. He urges nonoperative methods of treatment.

---

124. Hass: Wien. klin. Wchnschr., 1919; abstr. Ztschr. f. orthop. Chir **41**: 366, 1921.

125. Ollerenshaw: Brit. M. J. **1**:559 (April 16) 1921.

126. Enloe: California State J. M. **19**:199 (May) 1921.

127. Osnato, M. L.: Nonoperative Treatment of Fractures of the Cervical Vertebrae with Cord Injury. J. A. M. A. **76**:1737 (June 18) 1921.

Fractures of the Elbow in Children.—Stone [128] gives definite rules for treatment of some of the more common fractures of the elbow in children. In transverse supracondylar fracture, reduction should be attempted with the elbow fully extended or hyperextended. Traction should be exerted on the supinated forearm and the fragment reduced by rocking the arm, alternately, to the radial and to the ulnar side. Next, the elbow should be fully flexed under traction, and if no block occurs, reduction is usually satisfactory. This full flexion with the hand half way between supination and pronation is maintained for two weeks, and then a right angle splint is applied. After two weeks it is difficult to reduce this fracture without open operation. Stone emphasizes the fact that failure to regain full extension is often due to muscle spasm induced by too early use or too many attempts at passive motion. Further rest will cause the spasm to disappear and motion to return. Considerable degrees of deformity will in children often afford a functionally good result. Stone believes that operation is demanded in those cases in which the epiphysis of the external condyle has been detached and has "turned turtle." This operation yields good results up to six weeks after the injury. The roentgen-ray examination is often negative. In general, Stone says that the more skilled a surgeon becomes in closed reduction, the less often he will operate.

Forearm Fractures.—Seitz [129] points out the well known fact that the insertion of the pronator radii teres exerts a very definite influence on the position in which radial fractures should be immobilized. If the fracture is in the upper third above the insertion, the upper third is uncontrolled and supinates; therefore, the arm should be fixed in full supination. In fractures below the insertion, the opposite obtains, because the upper fragment is pronated by the action of the muscle. Therefore, the arm should be fixed in semipronation.

Grossman [130] has reviewed 200 cases of fracture of the forearm in children at the orthopedic clinic of the Lebanon Hospital. In only one of these cases was there a typical Colles' fracture and in 6.5 per cent. there was separation of the epiphysis. Twenty per cent. of the patients were below 5 years of age; 47 per cent. between 6 and 10; 31.5 per cent. from 11 to 13. Fracture of both bones was more common between 6 and 10, of one single bone more common between 11 and 13, and there was an equal number of fractures of single and double bones in the patients below 5 years of age.

Meyerding [131] reports fifty-nine cases of delayed union or non-union of the radius and ulna treated at the Mayo Clinic. He has found the massive graft from the tibia fixed with bone screws to

128. Stone: J. Orthop. Surg. **3**:395 (Aug.) 1921.
129. Seitz: München. med. Wchnschr. **68**:425 (April 8) 1921.
130. Grossman: J. Orthop. Surg. **3**:217 (May) 1921.
131. Meyerding: Minnesota Med. **4**:223 (April) 1921.

yield the most satisfactory result. In the series reported, metal plates were employed in six cases and bone grafts in thirty-one. Thirty-four results have been tabulated, with good union in twenty-five, failures in seven, and improvement in two.

[Ed. Note.—We note with interest Meyerding's championing of the massive graft in nonunion of the radius and ulna. It has been the experience of Chutro, Leriche, and others that, especially in these forearm bones, the thin osteoperiosteal transplant has best served the purpose, stimulating osteogenesis, and at the same time has easily nourished itself. The report of several observers has been that large grafts inserted in this region seem prone to late absorption or fracture.]

Fractures of the Carpal Scaphoid.—Todd,[132] in a valuable article, discusses fractures of the carpal scaphoid. He shows that the symptoms are characteristic and that the well marked symptoms and signs should make early diagnosis almost always possible. On early diagnosis depends the successful treatment of these fractures and probably also the chances of obtaining union. Todd pleads for prolonged fixation, three or four weeks, in a long "cock up" splint, holding the hand and fingers in dorsal flexion, with preservation of the carpal arch. A more or less permanently crippled wrist may be expected if treatment is not instituted early; and Todd points out that in the important series of cases reported by Codman and Chase[133] the only two cases which obtained union were those which were early immobilized for a long period. In old unrecognized cases with fibrous union or displacement, removal of one of the fragments has frequently greatly benefited the condition, the result sometimes amounting to an almost perfect functional recovery.

Fractures of the Femur.—Murphy and Dorrance[134] are enthusiastic over the results obtained by the abduction plaster-of-Paris spica treatment of intracapsular fractures of the neck of the femur. Eighteen of their twenty patients were between 60 and 80 years old. The ease of handling and the relief of pain was often very striking. There were two deaths, one patient being admitted in an unconscious condition. The two patients under 50 obtained bony union; the others showed firm fibrous union in the roentgenograms. Nine patients obtained full function; eight have only slight impairment of function; five use a cane; but all are capable of walking about.

Royal and Armitage Whitman[135] describe Royal Whitman's so-called reconstruction operation for ununited fracture of the neck

132. Todd: Brit. J. S. **9**:7 (July) 1921.
133. Codman and Chase: Ann. Surg. **41**:321 (March) 1905.
134. Murphy and Dorrance: Ann. Surg. **73**:752 (June) 1921.
135. Whitman: Surg., Gynec. & Obst. **32**:479 (June) 1921; End-Results of Reconstruction for Ununited Fracture of Neck of Femur, J. A. M. A. **77**:913 (Sept. 17) 1921.

of the femur. The incision is vertical, beginning 1½ inches (3.8 cm.) posterior to the posterior superior spine of the ilium, extending downward to below the level of the trochanter and then backward, horizontally across the shaft. The fibers of the gluteus medius and of the tensor fasciae femoris are separated and the capsule is exposed and opened. The head of the femur is removed. Following the upper border of the gluteus minimus muscle, the base of the trochanter is reached and the trochanter with its attached muscles is chiseled off in a direction outward, downward, and slightly backward, so that the bone surface left by its removal corresponds to the inclination of the surviving portion of the neck. The outer surface of the shaft is then denuded of cortical bone, the neck placed in the acetabulum, the limb abducted, and the trochanter approximated to the shaft and fastened with kangaroo tendon, nail, graft, or peg. The plaster is left on six weeks. It is then removed and the patient is encouraged in the use of active and passive motion. When a fair degree of voluntary control has been established, the patient may get up. The first operation was performed Oct. 10, 1916. It has since been performed on nine other patients and there has been one death (embolism). All of the patients are free from pain and can bear weight on the hip. The amount of function varies. The operation is particularly applicable to old people, who have poor osteogenetic power, because it does not depend for success on the powers of bone union of the patient. It is aiso applicable in disease of the acetabulum. The pegging operation is not applicable when there is absorption of the neck, Whitman believes. "The Brackett operation is more difficult technically, union may not be obtained, and function is limited."

[Ed. Note.—We see little difference in the technical difficulties of the Brackett and the Whitman operations. Whitman's point in relation to the osteogenetic powers of the patient may be well taken in older and more feeble subjects. Brackett's operation, which, briefly, consists of removing the trochanter and the remains of the neck and placing the rounded upper femoral end in the freshly prepared cuplike capital fragment, and transplanting the trochanter with its muscles attached lower down on the femoral shaft, while the position is maintained in abduction, seems to offer the more perfect anatomic result. The clinical results as we have seen them seem entirely to justify the anatomic expectation.]

Eikenbary [136] reports three cases of avulsion fracture of the lesser trochanter occurring at the adolescent period. He believes they fall into the class of lesions to which the partial avulsions of the tibial tubercle and the apophysitis of the os calcis belong. The powerful iliopsoas is attached to an epiphysis which begins to develop its center of ossifica-

136. Eikenbary: J. Orthop. Surg. 3:464 (Sept.) 1921.

tion about the fourteenth year. A powerful contraction of this muscle might be expected partially to separate this growing center. Quite severe injury had occurred in all of Eikenbary's cases. There was a tendency toward flexion, resistance to extreme extension, pain on pressure over the region of the lesser trochanter, a decided limp, and a lordosis. The treatment consisted of anesthetization, and correction of the deformity by applying a plaster spica in full extension for six weeks. He reports complete recovery in all three cases.

Fracture of the Femoral Diaphysis Under Twelve Years.—Speed [137] has been impressed with the excellent functional results in the sixty-seven cases he has examined, regardless of the special method of treatment employed. Direct overhead traction he considers most useful up to 3 years of age and Thomas splints with overhead suspension of the splint and continuous traction in older cases. Caliper or pin traction was employed in a few cases.

Results of Fracture of Shaft of Femur.—Eliason [138] advocates direct overhead traction in fracture of the femoral shaft up to 8 years of age. Impressed with the unsatisfactory primary reductions in patients over 10 and with the uncertain results of even internal fixation when the limb is fixed with the thigh in extension, Eliason has come to believe that open operation and metal plate and screw fixation, with temporary wound drainage and immobilization in plaster and traction and thigh flexion, is the best method. He reports 90 per cent. of perfect results and 10 per cent. of good results from these procedures. The basis of his report is a study of 115 cases from the University of Pennsylvania Hospital.

[Ed. Note.—We shall be surprised if many surgeons find it necessary to adopt Eliason's rather radical procedures as a routine in fractures of the femoral shaft. There is a generally expressed satisfaction with the results of skeletal traction combined with the Thomas splint after the method of Pearson, and our own observations are in accord with this expression. Metal plates and nonabsorbable material probably have a field of usefulness, but the field seems to be growing smaller as the technic of other, and as it seems to us more rational, methods becomes standardized. Complete access to the seat of fracture, the avoidance of open operation, and the escape from the use of nonabsorbable material surely make treatment safer and simpler.]

Fracture of the Spine of the Tibia.—Kurlander [139] has found only three cases of fracture of the spine of the tibia in 1,000 fractures. The mechanism of the injury he believes to be either violent hyperextension

137. Speed: Surg., Gynec. & Obst. **32**:527 (June) 1921.
138. Eliason: Ann. Surg. **74**:206 (Aug.) 1921.
139. Kurlander, J. J.: Fracture of Spine of Tibia, J. A. M. A. **77**:855 (Sept. 10) 1921.

of the knee or violence applied while the knee is flexed, abducted, and usually externally rotated. There is sudden severe pain, swelling, and blocking of extension. The differential diagnosis from lesions of the semilunar cartilages can only be certainly made by roentgenograms. He advises for treatment manipulation until complete extension is obtained, followed by immobilization in plaster for six weeks. If full extension is blocked and cannot be obtained by manipulation, open operation by means of the midpatella splitting approach is advised, with the removal of the offending fragment. If there is evidence of rupture of the crucial ligaments, immobilization should be continued for three months.

Fracture of the Os Calcis.—Straus [140] estimates that fractures of the os calcis represent about 2 per cent. of all fractures. The chief deformities consist of (1) the upward displacement of the posterior fragment of the os calcis where it is held by the pull of the Achilles tendon; (2) the obliteration of the longitudinal arch of the foot resulting in traumatic flatfoot. Any treatment to succeed must overcome these two conditions. Under ether anesthesia, Straus first tenotomizes the Achilles tendon and introduces a pin (unscrewing in the middle) over the top of the posterior fragment in front of the tendon. Traction is then exerted downward on the pin, which pulls the posterior fragment into position. A plaster cast is then applied while traction is still in force and any lateral displacement molded into position. At the same time the fore foot is pressed downward to restore the longitudinal arch and after the plaster is set the pin is unscrewed and pulled out from either side.

[Ed. Note.—The Editors consider the method well conceived and have found it satisfactory in application.]

Fractures of the Metatarsal Bones.—Alexander [141] calls attention to the very crippling character of fractures of the metatarsal bones unless accurate alinement and reduction of the frequently associated dislocations can be secured. He believes such accurate readjustment cannot in the majority of cases be obtained without open operation; and he urges the procedure as a routine in all of the common severe traumas which usually produce these injuries. The restoration of the normal arc, especially of the second and third metatarsal shafts, is of great importance if painful flatfoot is to be avoided.

Infraction of the Second Metatarsal Head.—Painter [142] reports the operative findings in three cases of this rather peculiar condition, well

140. Straus, D. C.: New Method of Treating Recent Fracture of the Os Calcis, J. A. M. A. **77**:176 (July 16) 1921.
141. Alexander: Ann. Surg. **74**:214 (Aug.) 1921.
142. Painter: Boston M. & S. J. **184**:533 (May 26) 1921.

described by Freiberg,[143] and consisting of pain referred to this point following sometimes a trivial injury and a subsequent quite marked flattening of the head, as revealed by the roentgenogram. All of Painter's cases were caused by stubbing the toe. One showed a thin sliver of cartilage separated from the head; the second showed a fracture extending part way into the epiphysis and including nearly the whole cartilage. These two were fairly recent cases. The third was of three years' duration; and at operation a loose ossicle, the size of a pea, was found between the flattened articular surfaces of the phalanx and the metatarsal. The metatarsal head had almost no cartilage on it and the phalangeal end was spiculated. The injury and the more or less characteristic later changes are probably much more common than is generally appreciated.

INDUSTRIAL SURGERY

Industrial Fractures.—Bassin[144] has reviewed the end-results of 442 fractures caused by industrial accidents. He compares these to the injuries of the war, stating that from 75 per cent. to 85 per cent. of the returning surgical cases in the Canadian Army and 65 per cent. in the American Army required further orthopedic and reconstructive surgery. Of the first thousand cases of industrial accidents presented before the workman's compensation courts, 76.3 per cent. required further treatment, though they supposedly represented end-results and 442 of these cases were end-results of fractures. The poorest results were those of simple fractures about the wrist and ankle. There had been also great lack of persistent traction on the fingers and toes, misinterpretation of roentgenograms in carpal and tarsal fractures, lack of immobilization, and too little physiotherapeutic after-treatment.

[Ed. Note.—These are startling facts and figures and we fear quite true. They are exactly in line with the following review of the problems of traumatic surgery by an able industrial surgeon of wide experience during the war and in civil practice.]

Morehead[145] makes a plea for standardization of treatment in various types of traumatic surgery and illustrates his own practice. For example, in wounds of the soft parts he follows the final regulation war method, namely, débridement, primary or delayed primary suture, or chemical sterilization and secondary suture. In burns he first sterilizes with iodin and then employs moist dressings of sodium bicarbonate. When they begin to cicatrize he treats them with sunlight or electric light radiation. In dealing with the question of fractures, Morehead says the two important considerations are reduction and function.

---

143. Freiberg: Surg., Gynec. & Obst. **19**:191 (Aug.) 1914.

144. Bassin: J. M. Soc. New Jersey **18**:115 (April) 1921.

145. Morehead, J. J.: Traumatic Surgery Problems, J. A. M. A. **76**:1642 (June 11) 1921.

Sixty per cent. consideration should be given to function and 20 per cent. each to union and contour. He employs skeletal traction whenever it is possible in the lower limb.

Osgood,[146] writing on the standardization of methods of treatment in orthopedic surgery and industrial surgery of the extremities and spinal column, has attempted to outline the methods now generally accepted, with special reference to early return of function and wage earning capacity. The article is sketchy but strives to be suggestive.

Eloesser [147] has been studying the problem of the severely, but not totally, disabled patient with special reference to the loss of an arm. Compensation, he believes, should be based on both the physical impairment of the injury and the previous occupation. All severely injured patients should be given the opportunity for vocational training and the new career should be based on the patient's previous knowledge and experience. Its continuation should depend on his intelligence and fitness. Only progress made warrants this. Agricultural laborers should be offered compensation in land and not in money.

RESEARCH

Development of Tendons.—Faldino [148] has made a very careful study of the development of tendons and arrives at the following conclusions: (1) The tendons and the synovial tendon sheaths are developed through various histologic modifications from a cellular cord which originally is differentiated from the mesenchyme which constitutes the original form of the extremities. (2) The original differentiation of the tendons occurs at two distinct points—one proximal, in connection with the muscle tissue, the other distal, in connection with the movable skeletal segment. (3) All the tendons do not appear at the same epoch. The tendons develop first where function is most necessary for the life of the embryo, thus the flexor tendons of the hands and feet develop first. (4) In human embryos of 18 mm. these tendons are outlined and there exists at this stage of development the early form of the tendon sheath. (5) The primitive form of the extensor tendons of the digits of the hand and foot are found in sections of the wrist and ankle in embryos of 25 mm. and not before. (6) The synovial sheath of the tendon must be considered as the matrix of the tendon, since at the time of its differentiation the tendon is seen to take its origin from the inner layer of the synovia. (7) In the early stages of development, the tendons are all placed in one layer. The deep tendons of the muscles of the same name and function are differentiated much later. (8) The tendons of the common superficial flexor

146. Osgood: Illinois M. J. **39**:342 (April) 1921.
147. Eloesser: Boston M. & S. J. **184**:489 (May 12) 1921.
148. Faldino: Chir. d. org. di movimento **5**:43 (Feb.) 1921.

muscles of the digits and the common superficial extensor muscles of the digits are formed from the already differentiated homologous muscles. (9) In the case of muscles having multiple tendons, these are formed from an original single connective tissue segment. (10) The endothelial layer that covers the inner surface of the synovia constitutes, previous to the entire detachment of the tendon, the endothelial covering of the tendon itself. (11) The development of the tendons, thus differentiated, can be said to be complete after the fifth month. Tendons that are free in the synovia can be found, nevertheless, earlier in embryos of 130 mm. (12) The nutrition of the tendon is derived from the synovial sheath. (13) On the tendon sheaths of very early embryos (from 35 to 75 mm.) can be observed a great quantity of blood vessels, some of which pass into the tendon tissue itself. These vessels become smaller with the progress of the development and finally disappear in the greater part of the sheaths. (14) In the first stages of development and up to the fourth month, the tendon sheath is noticeably thick in comparison with the contained tendon, which is very small. (15) Synovial cavities are found only after a considerable degree of differentiation (25 mm.). (16) The origin of the synovial cavities is independent of activity. (17) Bursae in connection with tendons are found in human embryos of 41 mm. as little cushions, which at this stage are without demonstrable cavities which only appear later.

Repair of Injury of Joint Cartilages.—Ciociola,[149] on account of the discordant reports in the literature regarding the repair of cartilage wounds, undertook a series of experiments on eleven dogs, using the cartilage of the femorotibial joint. The animals were kept alive from two to sixty days. From a very careful microscopic study of the tissues removed, he arrived at the following conclusions: (1) Wounds of the articular cartilage involving the underlying bony layers, as such wounds occasionally do, are healed through activity of the bone tissues, giving rise to a young connective tissue. (2) This tissue of repair, after a certain time, presents indications of transformation into hyaline cartilage. (3) Superficial wounds made in a tangential direction and which do not pass through the thin hyaline cartilage show no reaction even after two months and remain as small wounds.

Ossification Centers of Wrist, Knee, and Ankle at Birth.—Adair and Scammon [150] have found the inferior femoral epiphysis to be present in 98 per cent. of all new-born children, the superior tibial epiphysis in 81 per cent., the cuboid in about 60 per cent., and two carpal centers, the os capitatum (os magnum) and os hamatum (unciform), occasionally present. There is a close relation between total body length and the presence of the centers at birth.

149. Ciociola: Policlinico **28**:229 (June 15) 1921.
150. Adair and Scammon: Am. J. Obst. & Gynec. **2**:35 (July) 1921.

Epiphyses at the Elbow.—Cohn [151] believes that there are four centers of ossification of the lower end of the humerus: (1) the capitellum, which is first to appear and is alone present up to 5 years; (2) the internal epicondyle, which appears next; (3) the trochlea, and (4) the external epicondyle, occasionally. At 14 years of age, these centers have all joined the shaft except the internal epicondyle, which may remain ununited even at the age of 17.

Bone Atrophy.—Allison [152] has made an experimental study of the phenomena of bone atrophy. In these experiments, in which nonuse was produced by nerve paralysis, injury to joints, and simple fixation, the changes observed in the bone were the same. The degree of atrophy of the bone was directly proportional to the degree of nonuse, regardless of the method used to produce the nonuse. Simple fixation produced as rapidly developing and as marked bone atrophy as nonuse due to section of nerves or injury to joints. Complete fixation of a dog's extremity is so difficult that this method was not extensively employed. There is no evidence warranting the assumption that any disease process plays any rôle in the production of bone atrophy other than its effect on use. That bone atrophy is not the result of diminished circulation of blood is shown by the fact that bone atrophy rapidly develops in the acute inflammatory diseases which limit the function of an extremity. They have also observed a patient in whom the popliteal artery was ligated and in whom there was a diminution of blood supply to the leg sufficient to cause a complete ischemic paralysis and a slowly developing gangrene, yet the tibia showed no evident atrophy after a period of four months. Bone absorption is an active process and the circulation of the blood is necessary to its progress. The process of bone atrophy is not a change in the characteristics of bone as a tissue. The process of bone atrophy is a change in the amount of bone present. This affects the size, shape, thickness, length, weight, and texture of the whole bone and accounts for its changes in gross anatomy, roentgenograms, breaking strength, and chemical composition. The chemical composition, breaking strength, and regeneration of bone remain unchanged.

MISCELLANEOUS

Giant Cell Tumor of the Knee Joint.—Blanco [153] adds another case of a giant cell tumor of the xanthic type to the seventeen reported from the Mayo Clinic. Blanco removed this tumor from the capsule of the knee joint and found it to be intimately connected with the infrapatellar fat pad. These tumors are benign and are considered as

151. Cohn, Isidore: Observations on the Normally Developing Elbow, Arch. Surg. **2**:455 (May) 1921.
152. Allison and Brooks: Surg., Gynec. & Obst. **33**:250 (Sept.) 1921.
153. Blanco: J. Orthop. Surg. **3**:156 (April) 1921.

a type of granulation tissue resulting from hemorrhage. They are usually located on the extremities and are commonly associated with a tendon or its sheath. To the author's knowledge their presence in the joints has not been hitherto reported.

Kondoléon Operation for Elephantiasis.—Henry[154] and Green[155] have both discussed the Kondoléon operation and report distinct benefit from it in cases of elephantiasis. Lanz, in 1911, first recognized that the deep fascia was a barrier to lymph absorption and Kondoléon of Athens, as a result of operation and experiment, concluded that small slits in the deep fascia were inadequate for deep drainage. Kondoléon, therefore, in 1912, devised the operation which bears his name. His basic idea is to remove sufficient strips of fascia lata to produce a series of wide muscle hernias, as it were. The alternate bulging and withdrawal serves to aspirate the fluid from the subcutaneous tissue into the muscle strata. Scar tissue naturally forms in the gaps; but anastomosing lymphatics and veins also form. In the operation performed by Green, two long wedge shaped strips of skin, subcutaneous fat, and fascia lata were excised from the lateral and mesial aspects of the thigh from the level of the trochanter and just below the perineum to the malleoli. The tissue removed weighed 6 pounds (2.7 kg.). The operation was followed by some shock. Elastic bandages were applied and in a week softening was noted and ultimate recovery was complete. Kondoléon reported eight successful cases and seventeen others have been reported with improvement. Green is certain that filariasis is more common in the southern United States than is supposed. Johnson found 19 per cent. in 400 persons examined. Probably not over 5 per cent. of the persons infected develop elephantiasis. Nearly all of them have attacks of erysipelas. The pathologic changes in elephantiasis are: (1) mechanical obstruction of the veins and lymphatics from a progressive lymphangitis; (2) hyperplasia of the collagenous connective tissue of the hypoderm; (3) gradual disappearance of the elastic fibers of the skin; (4) the presence of a coagulable dropsy; (5) a chronic reticular lymphangitis caused by the secondary repeated invasion of micro-organisms.

Orthostatic Albuminuria.—An Editorial in the *Journal of the American Medical Association*[156] outlines the theories of etiology of the intermittent albuminurias associated with the faulty posture of exaggerated lumbar lordosis. The explanation has been offered by Jehle that this position of the spine causes in the erect position a mechanical interference with renal function. The arrangement of the renal veins

154. Henry, A. H.: Brit. J. Surg. **9**:111 (July) 1921.
155. Green: Virginia M. Monthly **48**:196 (July) 1921.
156. An Explanation of Orthostatic Albuminuria, Editorial, J. A. M. A. **77**:127 (July 9) 1921.

varies on the two sides, and Sonne of Copenhagen has seemed to prove the correctness of Jehle's explanation by finding in six cases of typical orthostatic albuminuria by ureteral catheterization albuminous urine from the left kidney alone. This is in harmony with the belief that the abnormally lordotic spine in the upright position may cause compression of the left renal vein.

Care of Crippled Children.—Girdlestone [157] estimates that England and Wales need 10,000 beds for the care of crippled children and that the expenditure necessary to provide for these and for the education of these children would be entirely justified by the economic results. In the city of Birmingham, for example, out of 1,001 cripples only 111 were self-supporting. He believes with proper hospital treatment 90 per cent. can be made wage-earning. The great groups include congenital deformities, paralytic deformities, and those following tuberculous bone and joint disease. Nearly all these deformities are preventable and correctable. Girdlestone advocates a central committee to take the matter in hand.

[Ed. Note.—Girdlestone is surely right in voicing this economic and humanitarian demand. This great need has been recognized in America by the Order of the Mystic Shrine, which by an equal annual assessment on its entire membership is placing in the hands of its trustees for the Shriners Hospitals for Crippled Children more than a million dollars a year. Hospitals are being built in different parts of this country and Canada, and an advisory board of orthopedic surgeons has been requested to nominate the chief surgeons of these hospitals and to make suggestions as to their conduct. They are to be teaching hospitals so far as possible, and they are to receive only needy patients up to 14 years of age, irrespective of race or religion. The movement is continental in its scope and should yield far-reaching results. This great annual fund becomes a light burden when divided equally and placed on many strong shoulders.]

The Teaching of Orthopedic Surgery.—A most valuable and onlooking article on this subject has been written by Allison.[158] He believes that so-called orthopedic surgery differs in none of its principles from so-called general surgery. He suggests that orthopedic surgery should not be taught to undergraduates as orthopedic surgery, but that the orthopedic surgeon teach them certain phases and problems of surgery. To the question, What is orthopedic surgery? Allison answers, "The surgery of the extremities and spinal column, which has the reestablishment of function as its guiding principle." He believes that the didactic lecture ought to be less and less used

157. Girdlestone: Brit. M. J. **1**:697 (May 22) 1920; Lancet **1**:74 (Jan. 8) 1921.

158. Allison: J. Orthop. Surg. **3**:448 (Sept.) 1921.

and that demonstrations ought to be demonstrations of some principle, and not of the skill of the operator. The student must be taught how to develop proper thinking. He considers the properly conducted clinical conference of great value both to the student and to the teacher.

[ED. NOTE.—We find ourselves in essential accord with Allison's point of view. As he says, the part cannot be greater than the whole. Orthopedic surgeons must train themselves to the highest points of surgical skill and judgment, in closest contact with general surgery, seeking to contribute to its needs, and happiest when its methods become the property and the practice of the general surgeon and the internist. Unless the specialty thus seeks closest contact, giving and taking, its field of usefulness will be small and its labor dull.]

BOOK REVIEW

INJURIES AND DISEASES OF THE BONES AND JOINTS: THEIR DIFFERENTIAL DIAGNOSIS BY MEANS OF THE ROENTGEN RAY. By FREDERICK H. BAETJER and CHARLES A. WATERS. Cloth. Price, $10.00 net. Pp. 349, with 333 illustrations. New York: Paul B. Hoeber, 1921.

This book may be best described as an atlas of roentgenograms of various bone and joint conditions with accompanying text describing the pathologic, clinical and roentgenologic findings. It is handsomely published in royal octavo of 349 pages, with 333 large, clear illustrations. An idea of its scope may be gained from the following tabulation of the contents. Normal bone and epiphyses, thirty-three pages; fractures, 100 pages; dislocations, congenital and acquired, twenty-six pages; bone infections, twenty-four pages; joint lesions, fifty-eight pages; bone tumors, forty-eight pages; spine, twenty-two pages; abnormalities, twelve pages; dystrophies, ten pages. The chapters on bone tumors and joint lesions are excellent; those on the epiphyses, bone repair, nonunion and bone grafting might perhaps be amplified. There is little mention made of variations in normal anatomy, particularly that of the spine. The authors have compiled a very excellent book and one that fills a long felt need of the general practitioner, the general surgeon, and the medical student.

INDEX TO VOLUME 4

Ankle, classification and mechanism of fractures of leg bones involving ankle, based on a study of 300 cases from Episcopal Hospital; A. P. C. Ashhurst and R. S. Bromer..... 51

Apfelbach, C. W.: Studies in traumatic fractures of cranial bones: I. Edema of brain. II. Bruises of brain..... 434

Ashhurst, A. P. C.: Classification and mechanism of fractures of leg bones involving ankle, based on a study of 300 cases from Episcopal Hospital 51

Barney, E. L.: A detailed bacteriologic study of a case of gas gangrene following a compound fracture; studies on pathogenic anaerobes.. 470

Barron, M.: Carcinoma of lung: a study of its incidence, pathology and relative importance, with a report of 13 cases studied at necropsy.. 624

Behrend, M.: Comparative results of ligation of hepatic artery in animals; its application to man..... 661

Bladder, technic of treatment of carcinoma of bladder and prostate by a combination of surgery, electrocoagulation, radium implantation and roentgen ray; B. A. Thomas and G. E. Pfahler..... 451

Bone, sarcoma of, review and classification of; J. Ewing..... 485

Brain, edema of, studies in traumatic fractures of cranial bones. I. Edema of brain. II. Bruises of brain; C. W. Apfelbach..... 434

Breitstein, M. L.: Papilloma of larynx in children, report of 11 cases.... 275

Bromer, R. S.: Classification and mechanism of fractures of leg bones involving ankle, based on a study of 300 cases from Episcopal Hospital 51

Bursitis, radiohumeral bursitis, epicondylitis, epicondylalgia (tennis elbow), a personal experience; R. B. Osgood..... 420

Cannon, W. B.: Studies in experimental traumatic shock. V. Critical level in a falling blood pressure..... 300
Studies in experimental traumatic shock. IV. Evidence of a toxic factor in wound shock..... 1

Carcinoma of lung: a study of its incidence, pathology and relative importance, with a report of 13 cases studied at necropsy; M. Barron.... 624

Cattell, McK.: Studies in experimental traumatic shock. V. Critical level in a falling blood pressure..... 300

Chest wall, open pneumothorax in its relation to extirpation of tumors of bony chest wall; C. A. Hedblom..... 588

Cholecystitis, further observations on lymphatic origin of cholecystitis, choledochitis and associated pancreatitis; E. A. Graham and M. G. Peterman 23

Choledochitis, further observations on lymphatic origin of cholecystitis, choledochitis and associated pancreatitis; E. A. Graham and M. G. Peterman 23

Cranium, studies in traumatic fractures of cranial bones. I. Edema of brain. II. Bruises of brain; C. W. Apfelbach..... 434

Crile, G. W.: Studies in exhaustion. III. Emotion..... 130

Crowe, S. J.: Papilloma of larynx in children, report of 11 cases..... 275

Cutler, E. C.: Relaxed pelvic floor: end-result in 60 cases..... 175

Emotion, studies in exhaustion. III. Emotion; G. W. Crile..... 130

Ewing, J.: A review and classification of bone sarcomas..... 485

Exhaustion, studies in exhaustion. III. Emotion; G. W. Crile..... 130

Fractures, classification and mechanism of fractures of leg bones involving ankle, based on a study of 300 cases from Episcopal Hospital; A. P. C. Ashhurst and R. S. Bromer..... 51

Gangrene, a detailed bacteriologic study of a case of gas gangrene following a compound fracture: studies on pathogenic anaerobes, III; E. L. Barney and H. H. Heller..... 470

Graham, E. A.: Further observations on lymphatic origin of cholecystitis, choledochitis and associated pancreatitis..... 23

Harrison, P. W.: Inguinal hernia: a study of principles involved in surgical treatment 680

Hedblom, C. A.: Open pneumothorax in its relation to extirpation of tumors of bony chest wall..... 588

Heller, H. H.: A detailed bacteriologic study of a case of gas gangrene following a compound fracture; studies on pathogenic anaerobes.. 470

Hepatic artery, comparative results of ligation of hepatic artery in animals; its application to man; M. Behrend, H. E. Radasch and A. G. Kershner..... 661

Hernia, inguinal: study of principles involved in surgical treatment; P. W. Harrison..... 680

postoperative intra-abdominal hernia; G. H. Mayo and J. A. H. Magoun, Jr. 324

Hibbs, R. A.: Fracture-dislocation of spine treated by fusion..... 598

Hinman, F.: Structural results of prostatectomy with reference to methods of enucleation, based on a study of 136 cases..... 154

Intestinal obstruction, unusual case; A. M. Willis..... 690

Jackson, C.: Ventriculocardectomy, a new operation for cure of goitrous paralytic laryngeal stenosis..... 257

Jameson, C. H.: Relaxed pelvic floor: end-result in 60 cases..... 175

Kershner, A. G.: Comparative results of ligation of hepatic artery in animals; its application to man..... 661

Larynx, papilloma of larynx in children, report of 11 cases; S. J. Crowe and M. L. Breitstein..... 275

stenosis, ventriculocardectomy, a new operation for cure of goitrous paralytic laryngeal stenosis; C. Jackson..... 257

Lung, carcinoma of lung: a study of its incidence, pathology and relative importance, with a report of 13 cases studied at necropsy; M. Barron 624

Magoun, J. A. H., Jr.: Postoperative intra-abdominal hernia..... 324

Mayo, C. H.: Postoperative intra-abdominal hernia..... 324

Morton, J. J.: Generalized type of osteitis fibrosa cystica; von Recklinghausen's disease 534
Orthopedic surgery, seventeenth report of progress in orthopedic surgery; R. B. Osgood, R. Soutter, H. C. Low, M. S. Danforth, L. T. Brown and P. D. Wilson..... 693
sixteenth report of progress in orthopedic surgery; R. B. Osgood, R. Soutter, H. C. Low, M. S. Danforth, C. H. Bucholz, L. T. Brown and P. D. Wilson..... 200
Osgood, R. B.: Radiohumeral bursitis, epicondylitis, epicondylalgia (tennis elbow), a personal experience..... 420
and others: Seventeenth report of progress in orthopedic surgery..... 693
and others: Sixteenth report of progress in orthopedic surgery..... 200
Osteitis fibrosa cystica, generalized type of osteitis fibrosa cystica; von Recklinghausen's disease; J. J. Morton..... 534
Osteomyelitis, acute, hematogenous; C. L. Starr..... 567
Pancreatitis, further observations on lymphatic origin of cholecystitis, choledochitis and associated pancreatitis; E. A. Graham and M. G. Peterman 23
Papilloma of larynx in children, report of 11 cases; S. J. Crowe and M. L. Breitstein..... 275
Pelvic floor, relaxed pelvic floor: end-result in 60 cases; E. C. Cutler and C. H. Jameson..... 175
Peterman, M. G.: Further observations on lymphatic origin of cholecystitis, choledochitis and associated pancreatitis..... 23
Pfahler, G. E.: Technic of treatment of carcinoma of bladder and prostate by a combination of surgery, electrocoagulation, radium implantation and roentgen ray..... 451
Pneumothorax, open, in its relation to extirpation of tumors of bony chest wall; C. A. Hedblom..... 588
Prostate cancer, technic of treatment of carcinoma of bladder and prostate by a combination of surgery, electrocoagulation, radium implantation and roentgen ray; B. A. Thomas and G. E. Pfahler..... 451
Prostatectomy, structural results of prostatectomy with reference to methods of enucleation, based on a study of 136 cases; F. Hinman..... 154
Radasch, H. E.: Comparative results of ligation of hepatic artery in animals; its application to man..... 661
Recklinghausen's disease, generalized type of osteitis fibrosa cystica; von Recklinghausen's disease; J. J. Morton..... 534
Sarcoma, review and classification of bone sarcomas; J. Ewing..... 485
Seminal tract, radical cure of tuberculosis of seminal tract. I. Brief survey of literature; H. H. Young..... 334
Shock, studies in experimental traumatic shock. IV. Evidence of a toxic factor in wound shock; W. B. Cannon..... 1
studies in experimental traumatic shock. V. Critical level in a falling blood pressure; W. B. Cannon and McK. Cattell..... 300
Spine, fracture-dislocation of spine treated by fusion; R. A. Hibbs..... 598
Starr, C. L.: Acute hematogenous osteomyelitis..... 567

Tennis elbow (radiohumeral bursitis, epicondylitis, epicondylalgia), a personal experience; R. B. Osgood..... 420

Thomas, B. A.: Technic of treatment of carcinoma of bladder and prostate by a combination of surgery, electrocoagulation, radium implantation and röentgen ray..... 451

Tuberculosis, radical cure of tuberculosis of seminal tract: I. Brief survey of literature; H. H. Young..... 334

Ventriculocardectomy, a new operation for cure of goitrous paralytic laryngeal stenosis; C. Jackson..... 257

Willis, A. M.: Unusual case of intestinal obstruction..... 690

Young, H. H.: Radical cure of tuberculosis of seminal tract. I. Brief survey of literature..... 334